



# Safety and efficacy of topical tacrolimus 0.03% in the management of vernal keratoconjunctivitis: a non-randomized controlled clinical trial

Mahmoud Eltagoury<sup>1</sup>, Waleed Abou Samra<sup>2</sup> and Ehab Ghoneim<sup>3</sup>

<sup>1</sup> Damietta Ophthalmology Hospital, Damietta, Egypt

<sup>2</sup> Faculty of Medicine, Mansoura University, Mansoura, Egypt

<sup>3</sup> Faculty of Medicine, Port said University, Port said, Egypt

## ABSTRACT

**Background:** Vernal keratoconjunctivitis (VKC) is a bilateral, recurrent, chronic conjunctival inflammatory disease with seasonal exacerbations. This study aimed to assess the efficacy and safety of tacrolimus 0.03% eye ointment in the management of chronic VKC.

**Methods:** This was an open-label, prospective, non-randomized, comparative interventional study that enrolled 50 patients with chronic VKC, who were allocated to one of two groups. The first group was treated with tacrolimus 0.03% eye ointment twice daily for 2 months then once daily for 2 months, followed by once every other day for another 2 months. The control group was treated with standard anti-allergic drugs, topical fluorometholone 0.1% eye drops three times daily for 2 weeks and gradually tapered for another 2 weeks, with topical olopatadine 0.1% administered twice daily during the follow-up period. Disease severity was assessed using a four-point scale for symptoms and signs. Treatment efficacy was assessed by analyzing changes in symptoms and signs, and by clinical photography.

**Results:** Fifty patients with bilateral chronic VKC completed the follow-up. The mean (standard deviation) ages of the tacrolimus and control groups were comparable (16.20 [5.10] years versus 16.48 [4.19] years,  $P > 0.05$ ). The most commonly reported symptom was itching, and the most common signs were papillary hypertrophy and conjunctival hyperemia. All symptoms and signs were significantly reduced after treatment in both groups. The tacrolimus group showed a more significant improvement at 3 and 6 months in the mean composite symptom score (both  $P < 0.05$ ) and in the mean composite sign score (both  $P < 0.05$ ). Regarding complications, one case of increased intraocular pressure occurred in the control group (4%) after 2 weeks of steroid treatment, while there were no complications in the tacrolimus group, except for some reports of stinging sensation, which was well tolerated.

**Conclusions:** Treatment of chronic bilateral VKC with tacrolimus 0.03% eye ointment is effective and safe. It could be considered an alternative treatment to reduce steroid-associated complications in patients with chronic VKC. Future double-blinded clinical trials with a longer follow-up period are necessary to confirm our findings and to determine the long-term safety of topical tacrolimus 0.03% ointment in VKC.

## KEY WORDS


steroid, fluorometholone, tacrolimus anhydrous, vernal keratoconjunctivitis, prospective study

**Correspondence:** Mahmoud Eltagoury, Mosharafh Street, Mecca Tower, Second Floor, Damietta 34511, Egypt. Email: [mahmoud.eltagoury@gmail.com](mailto:mahmoud.eltagoury@gmail.com). ORCID iD: <https://orcid.org/0000-0003-0471-2753>

**How to cite this article:** Eltagoury M, Abou Samra W, Ghoneim E. Safety and efficacy of topical tacrolimus 0.03% in the management of vernal keratoconjunctivitis: a non-randomized controlled clinical trial. Med Hypothesis Discov Innov Ophthalmol. 2022 Summer; 11(2): 52-63. <https://doi.org/10.51329/mehdiophthal1446>

Received: 22 June 2022; Accepted: 09 September 2022



Copyright © Author(s). This is an open-access article distributed under the terms of the Creative Commons Attribution-NonCommercial 4.0 International License (<https://creativecommons.org/licenses/by-nc/4.0/>) which permits copy and redistribute the material just in noncommercial usages, provided the original work is properly cited. 

## INTRODUCTION

Vernal keratoconjunctivitis (VKC) is a bilateral, recurrent, chronic conjunctival inflammatory disease with seasonal exacerbations [1]. It affects children, may continue to adulthood, and is commonly seen in male individuals [2]. It is categorized into three types: *tarsal*, *limbal*, and *mixed*. Patients with VKC complain of itching, watering, burning, perceived redness, foreign-body sensation, discharge, and photophobia. Signs include inflamed limbus, tarsal papillae, punctate keratitis, hyperemia, and Horner-Trantas dots [3].

Immunoglobulin E (IgE)- and T-cell-mediated allergic reactions are responsible for the pathogenesis of VKC. Eosinophils, mast cells, and other inflammatory mediators have a key role in producing tarsal papillae, limbal inflammation, conjunctival hyperemia, and congestion [4, 5].

Treatments for VKC include topical corticosteroids, mast cell stabilizers, antihistaminic agents, and immunomodulatory agents. Antiallergic medications are effective for symptom relief but are less effective for tarsal papillae [6]. Although steroids are effective, excessive and prolonged use frequently results in complications, such as cataracts and glaucoma [7, 8]. To avoid steroid-induced complications, immunomodulators such as tacrolimus are currently used to treat VKC [9, 10].

Tacrolimus is a macrolide immunomodulator produced by *Streptomyces tsukubaensis* [11]. It inhibits calcineurin activity and the production of T helper 1 (Th1) and Th2 cytokine production. It also suppresses histamine release by mast cells. It is 100-fold more potent than cyclosporine [12]. Studies have shown that tacrolimus (0.02%–0.1%) ointment is effective in the management of VKC, atopic keratoconjunctivitis, and giant papillary conjunctivitis [13–16].

This study aimed to assess the efficacy and safety of tacrolimus 0.03% ointment for the management of chronic VKC.

## METHODS

In this prospective, non-randomized, interventional study, 50 patients with chronic VKC were enrolled and allocated to one of two groups. The first group was treated with tacrolimus 0.03% eye ointment, and the control group was treated with standard anti-allergic medications (Figure 1). This study was conducted at the Damietta Ophthalmology Hospital in Damietta, Egypt. Ethical approval for this study was obtained from the ethical committee of the Faculty of Medicine of Port Said University, and the study was registered in the Pan-African Clinical Trials Registry (PACTR). We followed the tenets of the Declaration of Helsinki and obtained written informed consent from all participants.

We included patients with newly diagnosed, chronic, bilateral VKC with no treatment for at least 1 month, regardless of severity. We excluded patients with coexisting eye infections, age less than 3 years, contact lens use, and history of systemic comorbidities, systemic immunosuppressive drug use, herpes keratitis, ocular surgery, known hypersensitivity to tacrolimus, cataracts, glaucoma, and congenital eye anomalies.

All included patients underwent best-corrected distance visual acuity (BCDVA) measurement using a Snellen chart (auto chart projector ACP 1800 L; Chongqing Vision Star Optical Co., Ltd., Chongqing, China), slit-lamp biomicroscopy examination (Photo-Slit Lamp 30 GL; Takagi Seiko Co., Ltd., Japan), fluorescein staining, measurement of intraocular pressure (IOP) using a Goldmann applanation tonometer (KAT R-Type Keeler, USA) [17], and fundus examination during each visit.

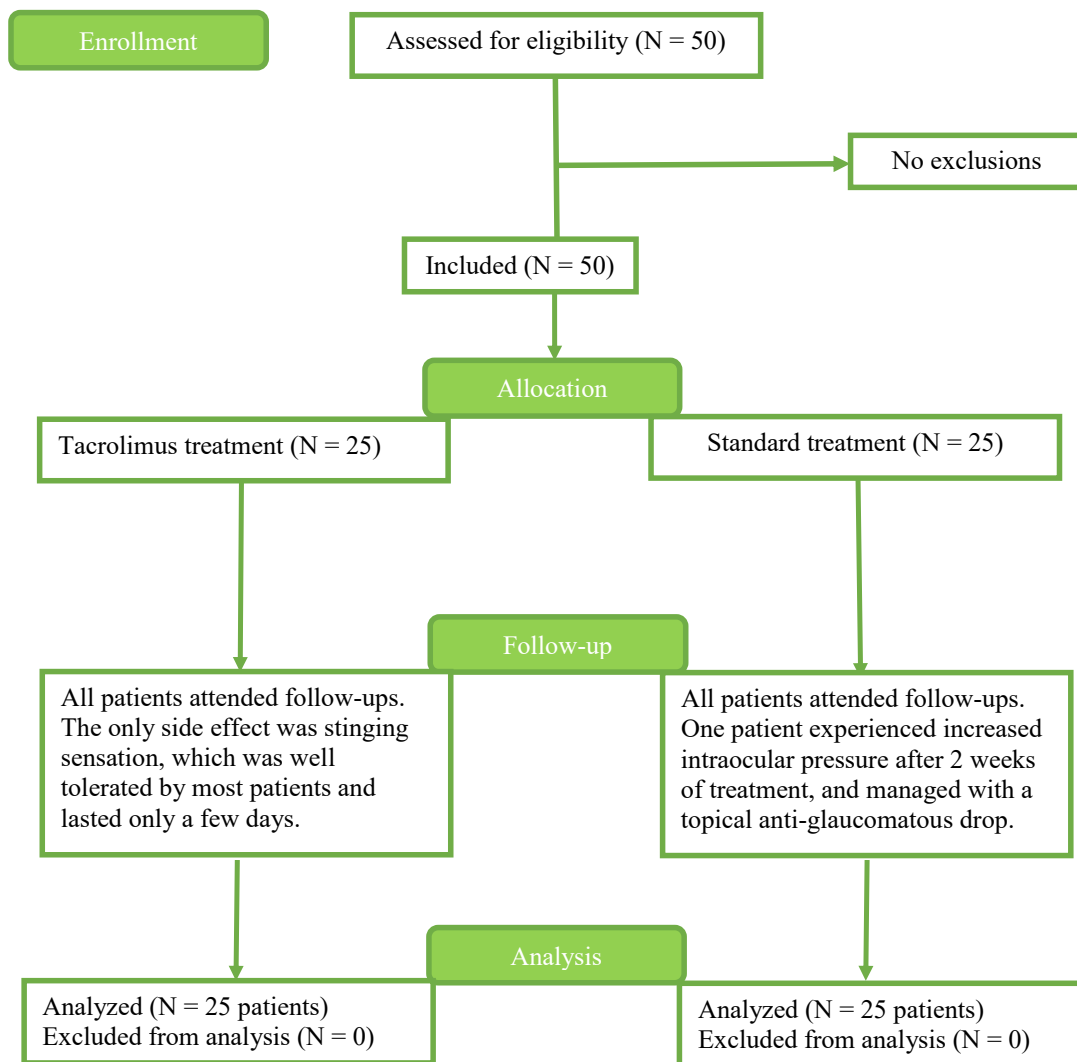
VKC was diagnosed based on the presence of seven symptoms [6] (discharge, watering, photophobia, redness, itching, burning, and foreign-body sensation) and five signs [3] (papillary hypertrophy, Horner-Trantas dots, hyperemia, limbal inflammation, and corneal affection).

We applied the quasi-random allocation method to assign patients to the control or intervention group by allocating alternate participants. The intervention group was treated with tacrolimus 0.03% ophthalmic ointment (Entrak Soothe 0.03% eye ointment; Entod Pharmaceuticals Ltd., Mumbai, India) twice daily for 2 months and then once daily for 2 months, followed by once every other day for 2 months. This treatment schedule was adopted from a previous publication [2]. The control group received topical fluorometholone 0.1% eye drops (Flucon; Novartis Pharma AG, Basel, Switzerland) three times daily for 2 weeks and tobramycin 0.3% with dexamethasone 0.1% eye ointment (Tobradex Ophthalmic Ointment; Novartis Pharma AG, Basel, Switzerland) and topical olopatadine 0.1% (Patanol; Novartis Pharma AG, Basel, Switzerland) twice daily. Steroids were gradually tapered in the control group after 2 weeks. If symptoms resolved, maintenance therapy with topical olopatadine 0.1% was administered twice daily during the follow-up period; if exacerbation occurred, treatment with corticosteroids was reinstated. The follow-up visits were at 1 week, 1 month, 3 months, and 6 months. When starting treatment, we advised patients with symptoms such as severe irritation, marked redness, blurred

vision, and pain to return earlier than the scheduled follow-up. Treatment efficacy was primarily assessed by analyzing the changes in symptoms and signs according to the four-point scale and by clinical photography at baseline and follow-up visits.

Each patient was offered a symptom questionnaire, graded on a four-point scale by a single examiner (M.E.), at baseline and at each follow-up visit. Clinical signs were also graded by a single observer (M.E.) according to a four-point scale (Tables 1, 2) [3, 6]. The total score (symptoms + signs) was calculated at baseline and at each follow-up visit.

Data were analyzed using IBM SPSS Statistics for Windows (version 20.0; IBM Corp., Armonk, NY, USA). Continuous data were assessed for normality using the Shapiro–Wilk test. Data are expressed as range (minimum and maximum), mean, standard deviation (SD), and median. For normally distributed variables, Student's *t*-test was used to compare the two groups, while analysis of variance (ANOVA) with repeated measures was used to compare multiple periods, followed by the post hoc test (Bonferroni adjusted) for pairwise comparisons. For non-normally distributed variables, the Mann–Whitney U test was used to compare the two groups, while the Friedman test was used to compare multiple periods, followed by the post hoc test (Dunn's test) for pairwise comparisons. The significance of the results was determined at the 5% level.



**Figure 1.** Allocation of study participants to the tacrolimus treatment and standard treatment groups. Abbreviation: N, number. Note: The intervention group was treated with tacrolimus 0.03% ophthalmic ointment (Entrak Soothe 0.03% eye ointment; Entod Pharmaceuticals Ltd., Mumbai, India) twice daily. The control group received topical fluorometholone 0.1% eye drops (Flucon; Novartis Pharma AG, Basel, Switzerland) three times daily for 2 weeks and tobramycin 0.3% with dexamethasone 0.1% eye ointment (Tobradex Ophthalmic Ointment; Novartis Pharma AG, Basel, Switzerland) and topical olopatadine 0.1% (Patanol; Novartis Pharma AG, Basel, Switzerland) twice daily.

Table 1. Symptom scores [6] in vernal keratoconjunctivitis

Symptom	Severity	Score
<b>Burning</b>	Absent	0
	Mild	1
	Moderate	2
	Marked	3
<b>Discharge</b>	Absent	0
	Mucus in the lower fornix	1
	Moderate	2
	Lashes are matted	3
<b>Itching</b>	Absent	0
	Occasional rubbing of the eyes	1
	Frequent rubbing of the eyes	2
	Constant rubbing of the eyes	3
<b>Photophobia</b>	Absent	0
	Sensitivity to sunlight with ability to open eyes	1
	Inability to open eyes for an extended time	2
	Unable to open eyes	3
<b>Perceived redness</b>	Absent	0
	Visible on close observation only	1
	Visible from near distance	2
	Visible from far distance	3
<b>Watering</b>	Normal	0
	Waterlogged sensation	1
	Infrequent lacrimation	2
	Constant or nearly constant lacrimation	3
<b>Foreign-body sensation</b>	Absent	0
	Mild	1
	Moderate	2
	Marked	3

Table 2. Clinical sign scores [3, 6] in vernal keratoconjunctivitis

Clinical signs	Severity	Score
<b>Hyperemia</b>	Absent	0
	Some dilated blood vessels	1
	Several dilated blood vessels	2
	Generalized vascular dilation	3
<b>Horner-Trantas dots</b>	Absent	0
	1–3	1
	4–6	2
	> 6	3
<b>Limbal inflammation</b>	Absent	0
	Neovascularization in 1 quadrant	1
	Neovascularization in 2 quadrants	2
	Neovascularization in 3–4 quadrants	3
<b>Punctate keratitis</b>	Intact epithelium	0
	Punctate in one-third of the cornea	1
	Punctate in two-thirds of the cornea	2
	Diffusely punctate	3
<b>Papillae</b>	No papillae	0
	Size of papillae: 0.1–0.2 mm	1
	Size of papillae: 0.3–0.5 mm	2
	Size of papillae: ≥ 0.6 mm	3

## RESULTS

Fifty patients with VKC completed all follow-up visits. The means for age, sex, and VKC type were comparable between the tacrolimus 0.03% and control groups (all  $P > 0.05$ ) (Table 3).

Tables 4 and 5 show the mean composite symptom scores of the two groups. At baseline and the 1-month follow-up visit, the mean composite symptom scores were comparable between the groups (both  $P > 0.05$ ) (Table 4). However, improvement in the composite symptom score between the baseline and 1-month visit was significant in both groups (both  $P < 0.05$ ) (Table 5). At 3 months, the mean composite symptom score of the tacrolimus group was significantly better than that of the control group ( $P < 0.05$ ) (Table 4), and scores in both groups were also significantly improved compared to those of the baseline and 1-month visits (all  $P < 0.05$ ) (Table 5). At 6 months, the mean composite symptom score of the tacrolimus group was significantly better than that of the control group ( $P < 0.05$ ), and the improvement in both groups between the baseline and 6-month, 3- and 6-month, and the 1- and 6-month visits was also significant (all  $P < 0.05$ ) (Table 5).

Tables 6 and 7 present the mean composite sign scores. At baseline and the 1-month visit, the mean composite sign scores were comparable between groups (both  $P > 0.05$ ) (Table 6). However, the improvement in the composite sign score between the baseline and 1-month visits in both groups was statistically significant (both  $P < 0.05$ ). At 3 months, the mean composite sign score of the tacrolimus group was significantly better than that of the control group ( $P < 0.001$ ) (Table 6). Moreover, the improvement in both groups between the baseline and 3-month, as well as the 1- and 3-month visits, was significant (all  $P < 0.05$ ) (Table 7). Likewise, at 6 months, the mean composite sign score of the tacrolimus group was significantly better than that of the control group ( $P < 0.05$ ), and the improvement in both groups between the baseline and 6-month, 1- and 6-month, and 3- and 6-month visits was also significant (all  $P < 0.05$ ) (Table 7).

**Table 3. Demographic and clinical features of the two study groups**

Variable	Tacrolimus (n = 25)	Control (n = 25)	P-value
Sex (Male / Female), n (%)	22 (88.0) / 3 (12.0)	21 (84.0) / 4 (16.0)	1.000
Age (y), Mean $\pm$ SD.	16.20 $\pm$ 5.10	16.48 $\pm$ 4.19	0.833
Tarsal Form type of VKC, n (%)	21 (84.0)	20 (80.0)	1.000
Mixed Form type of VKC, n (%)	4 (16.0)	5 (20.0)	

Abbreviations: n, number; %, percentage; y, years, SD, standard deviation; Tarsal VKC, a pure palpebral type of vernal keratoconjunctivitis; Mixed VKC, limbal with palpebral type of vernal keratoconjunctivitis. Fisher's exact P-value for comparing groups.

**Table 4. Composite symptom scores of the two study groups**

Composite symptom score	Tacrolimus (n = 25)	Control (n = 25)	P-value
Baseline, Mean $\pm$ SD	17.44 $\pm$ 2.14	17.52 $\pm$ 1.29	0.775
1 Month, Mean $\pm$ SD	8.60 $\pm$ 2.53	7.56 $\pm$ 1.26	0.128
3 Month, Mean $\pm$ SD	4.04 $\pm$ 1.95	4.84 $\pm$ 1.11	<b>0.021</b>
6 Month, Mean $\pm$ SD	1.96 $\pm$ 0.73	3.04 $\pm$ 0.79	<b>&lt; 0.001</b>

Abbreviations: n, number; SD: Standard deviation. P-values  $< 0.05$  are shown in bold (Mann-Whitney U test).

**Table 5. Comparison between the different study periods based on composite symptom scores in each group**

Group	Total symptoms score				P-value
	Baseline	1 Month	3 Month	6 Month	
Tacrolimus (n = 25), Mean $\pm$ SD	17.44 $\pm$ 2.14	8.60 $\pm$ 2.53	4.04 $\pm$ 1.95	1.96 $\pm$ 0.73	<b>&lt; 0.001</b>
$P_0$	-	<b>0.006</b>	<b>&lt; 0.001</b>	<b>&lt; 0.001</b>	-
Significance between periods.	-	$P_1 = 0.003, P_2 < 0.001, P_3 = 0.028$			-
Control (n = 25), Mean $\pm$ SD	17.52 $\pm$ 1.29	7.56 $\pm$ 1.26	4.84 $\pm$ 1.11	3.04 $\pm$ 0.79	<b>&lt; 0.001</b>
$P_0$	-	<b>0.005</b>	<b>&lt; 0.001</b>	<b>&lt; 0.001</b>	-
Significance between periods.	-	$P_1 = 0.006, P_2 < 0.001, P_3 = 0.010$			-

Abbreviations: n, number; SD: Standard deviation. Post hoc test (Dunn's test). P-values  $< 0.05$  are shown in bold.  $P_0$ , P-value for comparison between baseline and each visit.  $P_1$ , P-value between 1- and 3-month visits.  $P_2$ , P-value between 1- and 6-month visits.  $P_3$ , P-value between 3- and 6-month visits.

Table 6. Composite sign scores of the two study groups

Composite sign score	Tacrolimus (n = 25)	Control (n = 25)	P-value
Baseline, Mean ± SD	8.76 ± 1.45	8.60 ± 1.41	0.600
1 Month, Mean ± SD	4.72 ± 0.98	4.24 ± 1.05	0.081
3 Month, Mean ± SD	2.52 ± 0.51	3.28 ± 0.74	<b>&lt; 0.001</b>
6 Month, Mean ± SD	1.32 ± 0.63	1.80 ± 0.65	<b>0.005</b>

Abbreviations: n, number; SD: Standard deviation. P-values < 0.05 are shown in bold (Mann–Whitney U test).

Table 7. Composite sign scores in each group for different study periods

Study Group	Composite sign score				P-value
	Baseline	1 Month	3 Month	6 Month	
Tacrolimus (n = 25), Mean ± SD	8.76 ± 1.45	4.72 ± 0.98	2.52 ± 0.51	1.32 ± 0.63	<b>&lt; 0.001</b>
P <sub>0</sub>	-	<b>0.006</b>	<b>&lt; 0.001</b>	<b>&lt; 0.001</b>	-
Significance between. periods	-	P <sub>1</sub> = <b>0.002</b> , P <sub>2</sub> < <b>0.001</b> , P <sub>3</sub> = <b>0.037</b>			-
Control (n = 25), Mean ± SD	8.60 ± 1.41	4.24 ± 1.05	3.28 ± 0.74	1.80 ± 0.65	<b>&lt; 0.001</b>
P <sub>0</sub>	-	<b>0.002</b>	<b>&lt; 0.001</b>	<b>&lt; 0.001</b>	-
Significance between. periods	-	P <sub>1</sub> = <b>0.037</b> , P <sub>2</sub> < <b>0.001</b> , P <sub>3</sub> = <b>0.004</b>			-

Abbreviations: n, number; SD: Standard deviation. Post Hoc test (Dunn's). P-values < 0.05 are shown in bold. P<sub>0</sub>, P-value for comparison between baseline and each visit; P<sub>1</sub>, P-value between 1- and 3-month visits; P<sub>2</sub>, P-value between 1- and 6-month visits; P<sub>3</sub>, P-value between 3- and 6-month visits.

Table 8. Comparison of BCDVA and IOP between the two study groups

		Tacrolimus (n = 25)	Control (n = 25)	P-value
BCDVA	Baseline, Mean ± SD	0.76 ± 0.19	0.81 ± 0.19	0.342
	1 month, Mean ± SD	0.8 ± 0.17	0.82 ± 0.17	0.620
	3 months, Mean ± SD	0.81 ± 0.16	0.82 ± 0.17	0.867
	6 months, Mean ± SD	0.81 ± 0.17	0.82 ± 0.17	0.802
IOP	Baseline, Mean ± SD	15 ± 2.8	15.6 ± 2.7	0.479
	1 month, Mean ± SD	14.8 ± 2.8	15.6 ± 2.9	0.322
	3 months, Mean ± SD	15.1 ± 2.6	15.6 ± 2.7	0.462
	6 months, Mean ± SD	15 ± 2.9	15.6 ± 2.7	0.486

Abbreviations: n, number; SD: Standard deviation; BCDVA, best-corrected distance visual acuity; IOP, intraocular pressure in millimeter of mercury. Note: BCDVA was measured using the Snellen chart and listed using the decimal notation system.

Table 9. Comparison between the different study periods according to BCDVA and IOP in each group

		Baseline	1 month	3 months	6 months	P-value
BCDVA	Tacrolimus (n = 25), Mean ± SD	0.76 ± 0.19	0.8 ± 0.17	0.81 ± 0.16	0.81 ± 0.17	<b>0.002</b>
	Significance between. periods	P <sub>1</sub> = 0.056, P <sub>2</sub> = <b>0.025</b> , P <sub>3</sub> = <b>0.014</b>				
	Control (n = 25), Mean ± SD	0.81 ± 0.19	0.82 ± 0.17	0.82 ± 0.17	0.82 ± 0.17	0.162
	Significance between. periods	P <sub>1</sub> > 0.05, P <sub>2</sub> > 0.05, P <sub>3</sub> > 0.05				
IOP	Tacrolimus (n = 25), Mean ± SD	15 ± 2.8	14.8 ± 2.8	15.1 ± 2.6	15 ± 2.9	0.235
	Significance between. periods	P <sub>1</sub> > 0.05, P <sub>2</sub> > 0.05, P <sub>3</sub> > 0.05				
	Control (n = 25), Mean ± SD	15.6 ± 2.7	15.6 ± 2.9	15.6 ± 2.7	15.6 ± 2.7	0.763
	Significance between. periods	P <sub>1</sub> > 0.05, P <sub>2</sub> > 0.05, P <sub>3</sub> > 0.05				

Abbreviations: SD: Standard deviation; BCDVA, best-corrected distance visual acuity; IOP, intraocular pressure in millimeter of mercury. Significant differences between periods were evaluated using a post-hoc test (adjusted Bonferroni). P-values < 0.05 are shown in bold. P-value, P-value for comparison between the study periods; P<sub>1</sub>, P-value for comparison between baseline and 1 month; P<sub>2</sub>, P-value for comparison between baseline and 3 months; P<sub>3</sub>, P-value for comparison between baseline and 6 months. Note: BCDVA was measured using the Snellen chart and listed using the decimal notation system.

The most commonly reported symptoms were ocular itching and redness. All symptoms significantly improved within 2 weeks in both groups; however, itching, the most reported symptom, persisted in all patients. At 1 month, itching was significantly reduced in the control group compared with that in the tacrolimus group ( $P = 0.005$ ). Moreover, the tacrolimus group showed a significant decrease in itching at the 6-month visit ( $P = 0.039$ ) (Figure 2).

Concerning the mean individual sign scores, all patients in both groups had papillary hypertrophy, and nine patients had a combination of papillary hypertrophy and limbal inflammation (four patients in the tacrolimus

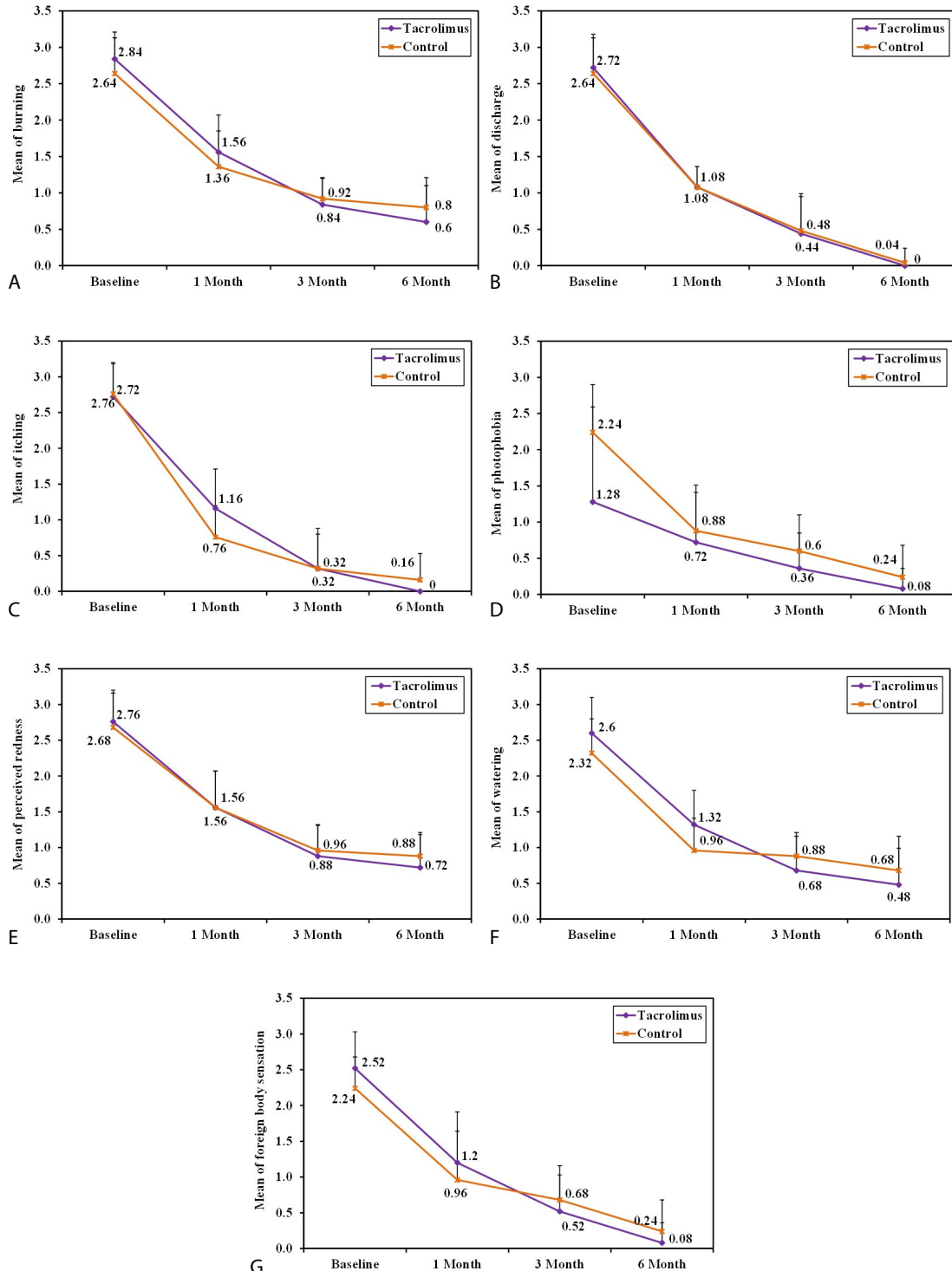


Figure 2. Mean symptom scores in the tacrolimus and control groups

group and five in the control group). The most commonly observed signs were papillary hypertrophy and conjunctival hyperemia, which were detected in all patients. Papillae were significantly reduced in the tacrolimus group compared to that in the control group at the 3-month and 6-month visits ( $P < 0.001$  and  $P = 0.039$ , respectively). Limbal inflammation was significantly reduced in the tacrolimus group compared with that in the control group at the 6-month visit ( $P = 0.020$ ). The least frequent sign was Horner-Trantas dots, which were reported in seven patients (three patients in the tacrolimus group and four patients in the control group) (Figure 3).

Tables 8 and 9 show the BCDVA and IOP in both groups at the baseline and follow-up visits. There were no significant differences between the groups at any visit (all  $P > 0.05$ ) (Table 8). However, there was a significant improvement in BCDVA in the tacrolimus group at 3 and 6 months compared to that of baseline (both  $P < 0.05$ ) (Table 9).

Figures 4 to 7 show sample photographs of cases of tarsal and mixed VKC at baseline and follow-up visits in both groups.

One case of increased IOP was detected in the control group. The patient was a 20-year-old man who experienced blurring of vision after 2 weeks of steroid treatment and returned for examination. The IOP was 32 mmHg; steroids were discontinued and the patient was administered topical anti-glaucomatous drops (betaxolol 0.5%) twice daily for 3 days, after which the IOP returned to normal and olopatadine drops were continued twice daily. In the tacrolimus group, no complications were observed, except for reports of stinging sensation in some cases, which lasted for a few days and was well tolerated.

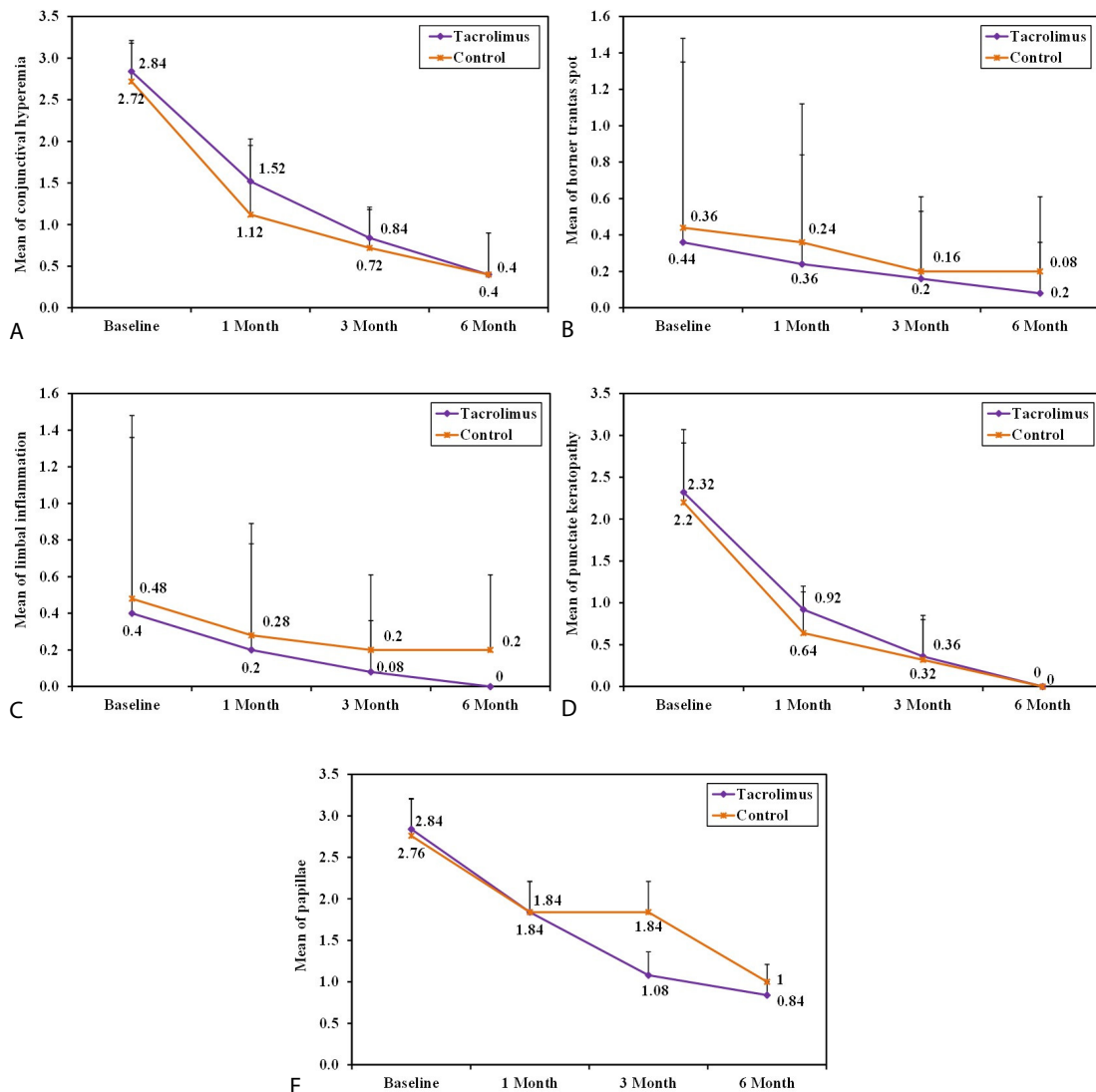


Figure 3. Mean sign scores in the tacrolimus and control groups



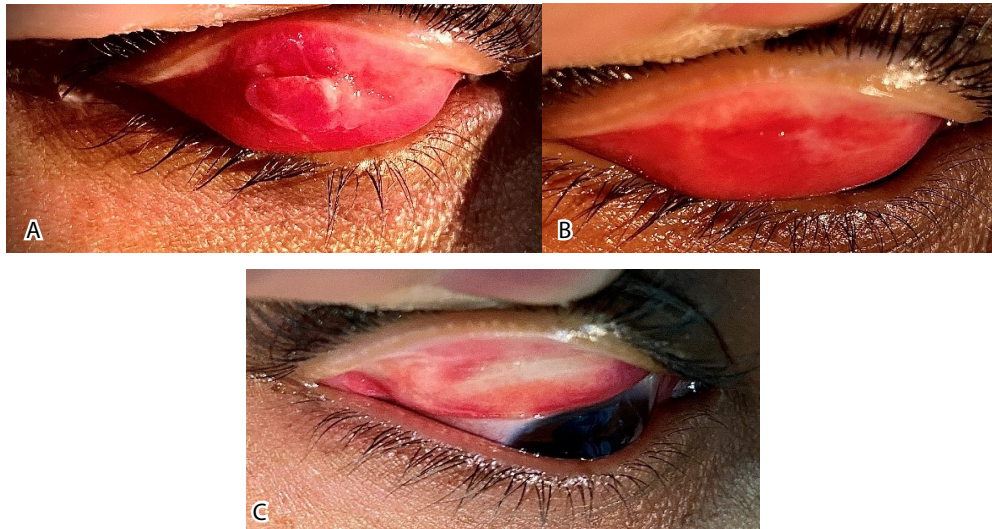


Figure 4. (A) A case of tarsal vernal keratoconjunctivitis (VKC), a purely palpebral type of VKC, with notably large papillae at the baseline examination. (B) The eye after 1 month and (C) after 6 months of tacrolimus 0.03% treatment (Entrak Soothe 0.03% eye ointment; Entod Pharmaceuticals Ltd., Mumbai, India), with complete resolution of the papillae.

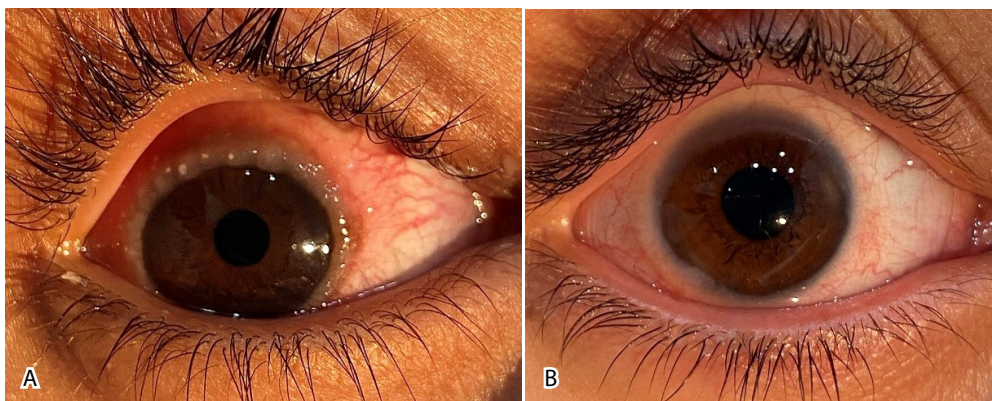


Figure 5. (A) Limbal inflammation in a case of mixed vernal keratoconjunctivitis (VKC), a limbal and palpebral type of VKC, at the baseline visit. (B) Complete resolution after 1 month of tacrolimus 0.03% treatment (Entrak Soothe 0.03% eye ointment; Entod Pharmaceuticals Ltd., Mumbai, India).

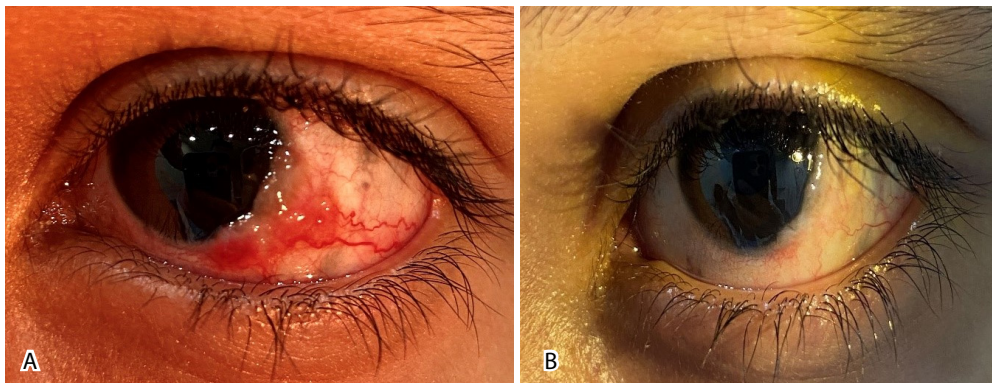
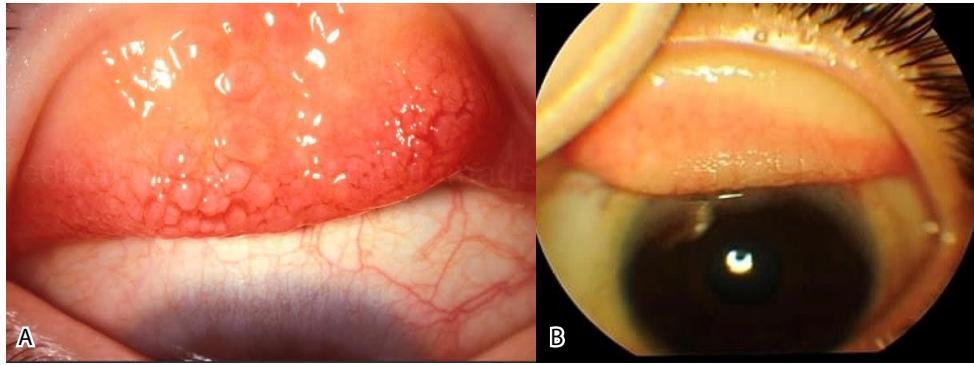


Figure 6. (A) Limbal inflammation in a case of mixed vernal keratoconjunctivitis (VKC), a limbal and palpebral type of VKC, in a control group patient at baseline. (B) Nearly complete resolution after 1 month. The control group received topical fluorometholone 0.1% eye drops (Flucon; Novartis Pharma AG, Basel, Switzerland) three times daily for 2 weeks and tobramycin 0.3% with dexamethasone 0.1% eye ointment (Tobradex Ophthalmic Ointment; Novartis Pharma AG, Basel, Switzerland) and topical olopatadine 0.1% (Patanol; Novartis Pharma AG, Basel, Switzerland) twice daily.



**Figure 7. (A) Tarsal vernal keratoconjunctivitis (VKC), a purely palpebral type of VKC, in a control group patient at baseline. (B) Improvement in papillae and conjunctival hyperemia after 6 months. The control group received topical fluorometholone 0.1% eye drops (Flucon; Novartis Pharma AG, Basel, Switzerland) three times daily for 2 weeks and tobramycin 0.3% with dexamethasone 0.1% eye ointment (Tobradex Ophthalmic Ointment; Novartis Pharma AG, Basel, Switzerland) and topical olopatadine 0.1% (Patanol; Novartis Pharma AG, Basel, Switzerland) twice daily.**

## DISCUSSION

In our study, both groups responded well to therapy. The stinging sensation was the only side effect in the tacrolimus group; however, it was well tolerated by most patients and lasted only a few days. Additionally, one case of increased IOP was observed in the control group and was successfully managed. Chatterjee et al. [10] reported that a mild stinging sensation lasting a few days was observed in their study. Similar to the current study, Imtiaz et al. [18] showed significant improvement in symptoms and signs with tacrolimus after 12 weeks of treatment compared to the baseline. Likewise, Vadivelu et al. [19] studied 30 patients randomized into two groups (tacrolimus and steroid groups) and reported that four patients in the tacrolimus group experienced mild irritation that was treated using lubricants. Four patients in the steroid group developed high IOP at the end of 6 weeks and were treated accordingly. One patient in the steroid group had punctate epithelial erosions.

In our study groups, the mean composite symptom scores were improved significantly at the 6-month visit compared with that of baseline. However, the tacrolimus group showed significantly greater improvement at 3 and 6 months compared with that of the control group. Our results coincide with those of Vadivelu et al. [19], who reported a statistically significant improvement with tacrolimus after 28 days of treatment. Rathore et al. [20] randomized 69 patients into a tacrolimus group or an olopatadine group. In the tacrolimus group, the mean (SD) symptom score at baseline was 9.0 (2.04), which decreased significantly to 0.11 (0.32) after 3 months; in the olopatadine group, the mean symptom score at baseline was 8.88 (2.18), and it decreased significantly to 1.70 (0.77) after 3 months. Similar to our findings, the difference in the mean symptom scores of the tacrolimus group was significantly greater than that of the control group at 3 months.

We recorded a significant improvement in the mean composite sign score in both groups at the 6-month visit compared with that of baseline. However, this improvement was significantly greater in the tacrolimus group at 3 and 6 months than in the control group. Our results coincide with those of Vadivelu et al. [19], who showed significant improvement with tacrolimus in the study group, and with steroids in the control group, after 28 days of treatment. In addition, Rathore et al. [20] showed that in the tacrolimus group, the mean (SD) sign score at baseline was 3.93 (1.93), which decreased significantly to 0.08 (0.28) after 3 months; in the olopatadine group, the mean (SD) sign score at baseline was 4.36 (1.90), which decreased significantly to 0.64 (0.55) after 3 months. The difference between groups at 3 months was also significantly in favor of the tacrolimus group, and these results are consistent with those of our study.

A statistically significant improvement in all symptoms was observed in both groups in the first month of treatment, except for photophobia in the tacrolimus group, which significantly improved at 3 months. Wan et al. [6] showed that the majority of symptoms improved in all patients after 1 week of treatment.

The most common symptom in our study, and the first to respond to treatment within 1 month, was itching. Samyukta et al. [3] also reported that itching was the first symptom to respond to treatment. We recorded a significant improvement in itching after 6 months of treatment in the tacrolimus group compared with that in the control group.

The most common signs in this study were conjunctival hyperemia and tarsal papillae, which were present in all patients in both groups. However, a statistically significant improvement in all signs was noted in both

groups in the first month of treatment, which was consistent with the findings of Vadivelu et al. [19], who found a significant improvement with tacrolimus in the study group, and with steroids in the control group, after 28 days of treatment.

A more significant improvement in tarsal papillae was observed in the tacrolimus group after 3 months of treatment. Similarly, a more significant improvement in limbal inflammation and tarsal papillae was noted at 6 months. Improvement in limbal inflammation and tarsal papillae was delayed in the control group. Kymionis et al. [21] revealed a complete reduction in giant papillae within 1 month in patients with giant papillary conjunctivitis treated with tacrolimus, whereas we detected nearly complete resolution of papillae in the tacrolimus group at the 6-month visit. However, some studies have found delayed or incomplete reduction in upper tarsal conjunctival papillae and cobblestone papillae [9, 14, 22].

The strength of our study was the management of VKC as a chronic eye condition using a single agent with a high success rate. In addition, corticosteroid use was avoided in the intervention group, along with its related complications. The main limitations of our study are the small sample size, no grading of cases based on disease severity, and non-randomization. Future double-blinded clinical trials involving more patients and longer follow-up periods are necessary to confirm our findings and to determine the long-term safety of topical tacrolimus 0.03% ointment in VKC.

## CONCLUSIONS

Treatment of VKC with tacrolimus 0.03% ointment revealed greater improvement in both symptoms and signs at 3 and 6 months, with enhanced BCDVA and no complications. Hence, management of chronic VKC with tacrolimus 0.03% eye ointment is effective and safe, and can be considered as an alternative to steroids, reducing the risk of steroid-related complications. Future clinical trials are needed to confirm our findings and to determine the long-term safety of topical tacrolimus 0.03% ointment in VKC.

## ETHICAL DECLARATIONS

**Ethical approval:** Ethical approval for this study was obtained from the ethical committee of the Faculty of Medicine of Port Said University, and the study was registered in the Pan-African Clinical Trials Registry (PACTR). We followed the tenets of the Declaration of Helsinki and obtained written informed consent from all participants.

**Conflict of interest:** None.

## FUNDING

None.

## ACKNOWLEDGMENTS

We offer thanks to our colleagues at the Damietta Ophthalmology Hospital.

## REFERENCES

1. Addis H, Jeng BH. Vernal keratoconjunctivitis. *Clin Ophthalmol*. 2018;12:119-123. doi: 10.2147/OPHT.S129552 pmid: 29391772
2. Fiorentini SF, Khurram D. Therapeutic effects of topical 0.03% Tacrolimus ointment in children with refractory vernal keratoconjunctivitis in Middle East. *Saudi J Ophthalmol*. 2019;33(2):117-120. doi: 10.1016/j.sjopt.2019.04.001 pmid: 31384152
3. Samyukta SK, Pawar N, Ravindran M, Allapitchai F, Rengappa R. Monotherapy of topical tacrolimus 0.03% in the treatment of vernal keratoconjunctivitis in the pediatric population. *J AAPOS*. 2019;23(1):36.e1-36.e5. doi: 10.1016/j.jaapos.2018.09.010 pmid: 30664932
4. Doan S, Amat F, Gabison E, Saf S, Cochereau I, Just J. Omalizumab in Severe Refractory Vernal Keratoconjunctivitis in Children: Case Series and Review of the Literature. *Ophthalmol Ther*. 2017;6(1):195-206. doi: 10.1007/s40123-016-0074-2 pmid: 27909980
5. Arsalan Z, Zafar O, Naqvi SAH, Ain QU. Effectiveness of steroids versus immunomodulators in treatment of vernal keratoconjunctivitis. A Study at Armed Forces Institute of Ophthalmology. *Pak Armed Forces Med J*. 2021; 71(6): 2045-2048. doi: 10.51253/pafmj.v6i6.5144
6. Wan Q, Tang J, Han Y, Wang D, Ye H. Therapeutic Effect of 0.1% Tacrolimus Eye Drops in the Tarsal Form of Vernal Keratoconjunctivitis. *Ophthalmic Res*. 2018;59(3):126-134. doi: 10.1159/000478704 pmid: 28803239
7. Al-Amri AM, Mirza AG, Al-Hakami AM. Tacrolimus Ointment for Treatment of Vernal Keratoconjunctivitis. *Middle East Afr J Ophthalmol*. 2016;23(1):135-8. doi: 10.4103/0974-9233.164616 pmid: 26957853
8. Vichyanond P, Tantimongkolsuk C, Dumrongkigchaiporn P, Jirapongsananuruk O, Visitsunthorn N, Kosrirukvongs P. Vernal keratoconjunctivitis: Result of a novel therapy with 0.1% topical ophthalmic FK-506 ointment. *J Allergy Clin Immunol*.

- 2004;113(2):355-8. doi: [10.1016/j.jaci.2003.10.065](https://doi.org/10.1016/j.jaci.2003.10.065) pmid: 14767456
9. Kheirkhah A, Zavareh MK, Farzbod F, Mahbod M, Behrouz MJ. Topical 0.005% tacrolimus eye drop for refractory vernal keratoconjunctivitis. *Eye (Lond)*. 2011;25(7):872-80. doi: [10.1038/eye.2011.75](https://doi.org/10.1038/eye.2011.75) pmid: 21475312
  10. Chatterjee S, Agrawal D. Tacrolimus in Corticosteroid-Refractory Vernal Keratoconjunctivitis. *Cornea*. 2016;35(11):1444-1448. doi: [10.1097/ICO.0000000000000918](https://doi.org/10.1097/ICO.0000000000000918) pmid: 27310883
  11. Zhai J, Gu J, Yuan J, Chen J. Tacrolimus in the treatment of ocular diseases. *BioDrugs*. 2011;25(2):89-103. doi: [10.2165/11587010-000000000-00000](https://doi.org/10.2165/11587010-000000000-00000) pmid: 21443273
  12. Tam PM, Young AL, Cheng LL, Lam PT. Topical tacrolimus 0.03% monotherapy for vernal keratoconjunctivitis--case series. *Br J Ophthalmol*. 2010;94(10):1405-6. doi: [10.1136/bjo.2009.172387](https://doi.org/10.1136/bjo.2009.172387) pmid: 20558422
  13. Miyazaki D, Fukushima A, Ohashi Y, Ebihara N, Uchio E, Okamoto S, et al. Steroid-Sparing Effect of 0.1% Tacrolimus Eye Drop for Treatment of Shield Ulcer and Corneal Epitheliopathy in Refractory Allergic Ocular Diseases. *Ophthalmology*. 2017;124(3):287-294. doi: [10.1016/j.ophtha.2016.11.002](https://doi.org/10.1016/j.ophtha.2016.11.002) pmid: 28017421
  14. Fukushima A, Ohashi Y, Ebihara N, Uchio E, Okamoto S, Kumagai N, et al. Therapeutic effects of 0.1% tacrolimus eye drops for refractory allergic ocular diseases with proliferative lesion or corneal involvement. *Br J Ophthalmol*. 2014;98(8):1023-7. doi: [10.1136/bjophthalmol-2013-304453](https://doi.org/10.1136/bjophthalmol-2013-304453) pmid: 24695688
  15. Barot RK, Shitole SC, Bhagat N, Patil D, Sawant P, Patil K. Therapeutic effect of 0.1% Tacrolimus Eye Ointment in Allergic Ocular Diseases. *J Clin Diagn Res*. 2016;10(6):NC05-9. doi: [10.7860/JCDR/2016/17847.7978](https://doi.org/10.7860/JCDR/2016/17847.7978) pmid: 27504320
  16. Sengoku T, Sakuma S, Satoh S, Kishi S, Ogawa T, Ohkubo Y, et al. Effect of FK506 eye drops on late and delayed-type responses in ocular allergy models. *Clin Exp Allergy*. 2003;33(11):1555-60. doi: [10.1046/j.1365-2222.2003.01698.x](https://doi.org/10.1046/j.1365-2222.2003.01698.x) pmid: 14616868
  17. Ghoneim EM. Red-free light for measurement of intraocular pressure using Goldmann applanation tonometer without fluorescein. *Eur J Ophthalmol*. 2014;24(1):84-7. doi: [10.5301/ejo.5000325](https://doi.org/10.5301/ejo.5000325) pmid: 23873489
  18. Imtiaz HS, Qayyum I, Iqbal U, Ali F, Sharjeel M. The Efficacy of 0.03% Dermatological Tacrolimus Ointment for Refractory Vernal Keratoconjunctivitis. *Pak J Ophthal*. 2019;35(4):229-34. doi: [10.36351/pjo.v35i4.872](https://doi.org/10.36351/pjo.v35i4.872)
  19. Vadivelu S, Mimmithi R, Arumugam S, Mohan S. A Comparative Evaluation of Tacrolimus versus Steroids in the Treatment of Vernal Keratoconjunctivitis. *J Evid Based Med Healthc*. 2020; 7(9), 429-432. doi: [10.18410/jebmh/2020/92](https://doi.org/10.18410/jebmh/2020/92)
  20. Rathore HS, Saeed S, Mukhtar MA, Ijaz U, Habib A, Ghaus I. Comparative evaluation of tacrolimus 0.03% ointment vs olopatadine 0.2% eye drops in the treatment of vernal keratoconjunctivitis. *Pak Armed Forces Med J*. 2021;71(1):34-9. doi: [10.51253/pafmj.v71i1](https://doi.org/10.51253/pafmj.v71i1)
  21. Kymionis GD, Kankariya VP, Kontadakis GA. Tacrolimus ointment 0.03% for treatment of refractory childhood phlyctenular keratoconjunctivitis. *Cornea*. 2012;31(8):950-2. doi: [10.1097/ICO.0b013e318243f69d](https://doi.org/10.1097/ICO.0b013e318243f69d) pmid: 22525784
  22. Ohashi Y, Ebihara N, Fujishima H, Fukushima A, Kumagai N, Nakagawa Y, et al. A randomized, placebo-controlled clinical trial of tacrolimus ophthalmic suspension 0.1% in severe allergic conjunctivitis. *J Ocul Pharmacol Ther*. 2010;26(2):165-74. doi: [10.1089/jop.2009.0087](https://doi.org/10.1089/jop.2009.0087) pmid: 20307214