

# Pearls & Oysters: Bilateral Mononeuropathic Neuralgic Amyotrophy Triggered by *Bartonella henselae* Infection Responsive to Immunoglobulin

Anelia Dietmann, MD, PhD, Eugénie Colin-Benoit, MD, Gerd Tinkhauser, MD, PhD, Thomas Raphael Meinel, MD, and Olivier Scheidegger, MD

*Neurology*® 2022;98:597-600. doi:10.1212/WNL.000000000200014

## Correspondence

Dr. Dietmann  
anelia.dietmann@gmail.com

## Abstract

We present a case of a cat owner with a scar on his right thenar eminence, followed by lymphadenopathy in the right axilla, general malaise and fever, and subsequent onset of bilateral neuralgic amyotrophy within one week. After a comprehensive workup, cat scratch disease caused by *Bartonella henselae* was confirmed serologically and adequately treated. Despite antibiotic treatment, the patient presented clinically with persistent bilateral, asymmetric neuropathy of the median nerve, predominantly the interosseous anterior nerve, which was confirmed by multifocal swelling and hyperintense signal of the nerves on T2-weighted MR neurography. Electrophysiological examination confirmed axonal median neuropathies bilaterally. After an unsuccessful steroid treatment trial, the patient showed an excellent and sustained response to intravenous immunoglobulin despite a delay from symptom onset to treatment of 10 months.

## Pearls

- *Bartonella henselae* infection is a rare cause of bilateral neuralgic amyotrophy.

## Oysters

- Patients with neuralgic amyotrophy, especially when bilateral, need a comprehensive workup to exclude rare infectious causes such as hepatitis E and, in case of suggestive history, *Bartonella henselae* infection.
- An intravenous immunoglobulin treatment trial may be considered, even in cases with poor clinical prognosis.

## Case Report

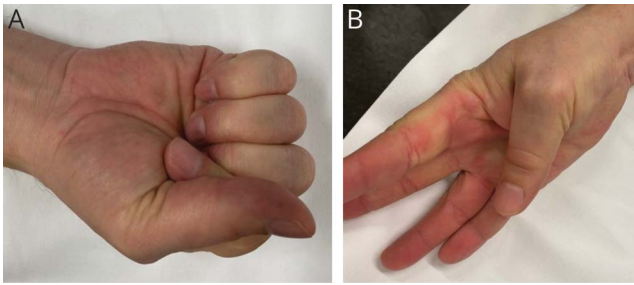
A 50-year-old cat owner with an unremarkable medical history recognized a small scratch injury on his right thenar region, without noticing a cat scratch or an insect bite. After 3 days, his thenar eminence became swollen, tender, and painful with expanding redness around the wound. He incised the wound with secretion of purulent liquid. After another 2–3 days, he developed febrile temperatures and noticed swollen but painless lymph nodes in the right axilla. Inflammatory markers were slightly elevated (CRP 18.5 mg/L, normal <5 mg/L; leucocytes 14.7 G/L, normal range 3.0–10.5 G/L; with normal differential count). An oral therapy with amoxicillin-clavulanic acid 3 × 625 mg/d was prescribed empirically by his general practitioner. Two days later, he noticed electric sensations radiating anteriorly from his right elbow to his lower arm and hand for several hours, followed by pain in his hand and paresthesia in his volar thumb and index finger. Within the next 2 days, he noted numbness in his distal thumb and index fingers bilaterally with evolving inability to flex the distal interphalangeal joints. Furthermore, he noticed patchy

From the Departments of Neurology (A.D., G.T., T.R.M., O.S.) Infectious Diseases (E.C.-B.), Inselspital, Bern University Hospital, University of Bern, Switzerland.

Go to [Neurology.org/N](https://doi.org/10.48350/174407) for full disclosures. Funding information and disclosures deemed relevant by the authors, if any, are provided at the end of the article.

This is an open access article distributed under the terms of the Creative Commons Attribution-NonCommercial-NoDerivatives License 4.0 (CC BY-NC-ND), which permits downloading and sharing the work provided it is properly cited. The work cannot be changed in any way or used commercially without permission from the journal.

**Figure 1** Clinical Presentation



The patient was asked to make a fist (A) and to flex the proximal and distal interphalangeal joints of his thumb (B). The patient was unable to flex both distal interphalangeal joints of digit I and II (MRC grad 0).

numbness over his right ventral thigh. The general practitioner took blood cultures and a serology for *B. henselae*. Blood cultures were negative, but IgG titers (by indirect fluorescence assay) were highly elevated ( $>1:1,024$ ), and IgM was negative. Antibiotic therapy was changed to azithromycin 500 mg/d on the first day, followed by 250 mg/d for 4 further days. After one week with persistent neurologic deficits, *Bartonella* serology was repeated showing even higher IgG titers of  $>1:4,096$ , and IgM was again negative. Twelve days after starting antibiotic treatment (9 days after starting azithromycin), a lumbar puncture was performed with normal cell count (4 mononuclear cells/ul) and normal values for protein (316 mg/L, normal 150–450 mg/L), glucose, and lactate. However, 2 CSF-specific oligoclonal bands were detected without signs of blood–brain barrier disturbance. A CSF culture remained negative and *Bartonella* polymerase chain reaction (PCR). Lymph node biopsy revealed an expansion of the interfollicular zone with isolated B plasma cells without signs of lymphoma, granulomas, or *Bartonella* detected by PCR. Serology tests for *Toxoplasma gondii*, *Treponema pallidum*, *Borrelia burgdorferi*, HIV, and hepatitis B, C, and E viruses were negative. No vasculitic antibodies or ganglioside antibodies were detected in the serum.

One month after onset, the patient was referred to our center for neuromuscular diseases. On examination, the patient was unable to feel light touch, temperature, and pinprick in the volar right distal thumb and index finger and the left distal thumb. The patient had a Medical Research Council's scale (MRC) muscle strength grade M0 for flexion of the distal interphalangeal joints of both thumbs (Figure 1). Flexion of the distal index finger was M0 on the right side and M4 on the left side. The muscle strength for supination of the right hand was M4. On the right thigh, he indicated decreased sensation for light touch in a patchy distribution, not corresponding to a specific nerve. Deep tendon reflexes were brisk and symmetric in all extremities.

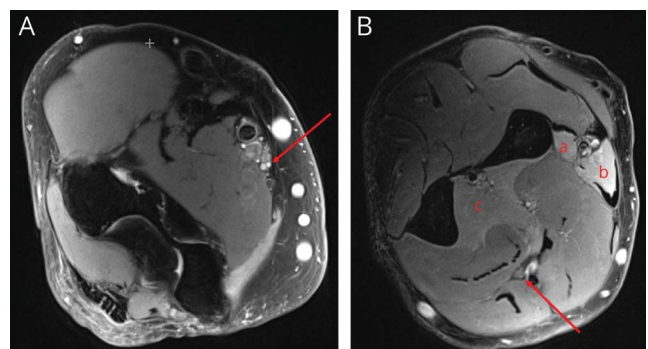
Motor nerve conduction study (NCS) of the median nerve with recording from the abductor pollicis brevis muscle showed slightly prolonged distal motor latency (right 4.4 ms,

left 5.2 ms; normal  $<4.0$  ms) with normal amplitudes and normal conduction velocity of proximal segments on both sides. Sensory NCS of the median nerve was unremarkable. Motor and sensory NCS of the ulnar nerve on both sides were normal. Needle myography of the right flexor pollicis longus muscle and pronator quadratus muscle showed a prolonged insertional activity and moderate fibrillation potentials and positive sharp waves without the detection of volitional motor activity. Needle myography of the right abductor pollicis brevis muscle and interosseous dorsalis I muscle were unremarkable.

At 6 months after disease onset, a MR neurography (3 T, Magnetom SkyraFit, Siemens, Erlangen, Germany; spine and body coils used) of the right brachial plexus and arm nerves were performed using high-resolution T2-weighted, fat-suppressed sequences. The examination revealed irregular hyperintense signal abnormalities and short segments of enlarged nerve fascicle bundles of the right median nerve in the middle and distal upper arm, corresponding somatotopically to nerve fascicle bundles of the anterior interosseous nerve and proximal muscular branches of the median nerve (Figure 2). Signs of muscle denervation (diffuse hyperintense signal abnormalities) were found in the pronator teres, flexor carpi radialis, and flexor digitorum profundus muscles. The nerve structure and signal intensity of the plexus brachialis and the distal segments of the median nerve below the elbow were normal; all other arm nerves were without pathologic imaging findings.

A treatment trial of oral prednisolone (1 mg/kg body weight per day for 1 month) one month after symptom onset was unsuccessful. Another treatment trial with intravenous immunoglobulin (IVIg; 0.4 mg/kg body weight over 5 days every 4 weeks) was started 10 months after onset because of

**Figure 2.** MRI High-Resolution T2-Weighted, Fat-Suppressed Sequences of the Right Brachial Plexus and Arm Nerves



(A) Irregular hyperintense signal abnormalities and short segments of enlarged nerve fascicle bundles of the right median nerve in the right proximal upper arm (red arrow) and (B) normal-appearing median nerve (red arrow) in the right lower arm with signs of muscle denervation (diffuse hyperintense signal abnormalities) in the right pronator teres muscle (a), flexor carpi radialis muscle (b), and flexor digitorum profundus muscle (c).

difficulty in obtaining reimbursement of IVIG treatment cost for off-label use. The patient showed a significant clinical response within the first 2 weeks after treatment, resulting in only mild residual weakness of finger flexion of distal interphalangeal joints of thumbs (right M4, left M5) and index fingers (right M5-, left M5), without any residual sensory disturbance. After another 5 cycles of IVIG, the patient achieved an almost complete recovery, showing only a minimal deficit in the flexion of the right distal thumb. The electrophysiologic follow-up assessment revealed a normalization of the motor NCS of the median nerve bilaterally. Therefore, we are now starting a tentative treatment pause.

## Discussion

Infections are suspected to cause or trigger neuralgic amyotrophy (NA) in a significant proportion of patients.<sup>1</sup> In the last 10 years it has been increasingly recognized that acute hepatitis E virus infection was associated with NA, especially bilateral NA, accounting for up to 10% of cases in recent series.<sup>2</sup> Case reports of NA in patients with acute cat-scratch disease (CSD) have also been described in literature.<sup>3</sup>

CSD is caused by the gram-negative intracellular bacteria *Bartonella henselae* and usually affects children and teenagers, typically presenting as a localized cutaneous infection, followed by adjacent lymphadenopathy and fever.<sup>4</sup> Neurologic involvement has been described in 10% of patients with CSD, presenting with encephalopathy, meningitis, myelitis, polyradiculoneuritis, neuroretinitis, and isolated optic neuritis.<sup>5,6</sup>

Because isolation of *Bartonella* species in culture is difficult (long incubation period, specific laboratory conditions), the current diagnostic workup is usually based on serologic testing, sometimes combined with PCR.<sup>7</sup> The indirect fluorescence assay (IFA) is the most frequently used serologic method. In the early stages of the disease, titers to IgG and IgM may be low, requiring a second serum sample at a later date for diagnosis. A positive IgM test strongly suggests acute disease, but the production of IgM is usually brief, and negative results do not exclude acute infection. IFA IgG titers >1:256 strongly suggest active or recent infection.<sup>4</sup> PCR for *Bartonella* is available and provides the advantages of high specificity and rapid identification; the sensitivity however ranges from approximately 65% to 76% in lymph node specimens, depending on PCR targets and selection of patients.<sup>8,9</sup> In this case, the combination of typical clinical presentation and positive serology confirmed the diagnosis of *B henselae* infection.

The mechanism by which infections trigger NA are largely uncertain and understudied. Similar to Guillain-Barré Syndrome, infections may trigger an autoimmune response that causes damage to the peripheral nervous system.<sup>1</sup> In our case, and in previously described cases, the absence of improvement of NA symptoms with antibiotic treatment is consistent with an immune-mediated reaction to CSD preceding NA.<sup>3</sup>

Our patient developed an asymmetric, bilateral NA affecting mainly the median nerves, predominantly the fascicles of the anterior interosseous nerve bilaterally, within the first week of a typical infection with *B henselae*. Interestingly, despite the electrophysiologic finding of severe axonal damage of the interosseous anterior nerve, an unsuccessful steroid therapy trial, and a long delay between diagnosis and treatment, the prompt response to IVIG within the first 2 weeks after the first treatment cycle was excellent. The patient, who was previously severely limited in their work as an electrical engineer, was able to fully resume their work after IVIG treatment. A tentative IVIG cessation is the next step. However, if the patient deteriorates after stopping IVIG treatment, the diagnosis would need to be changed to possible multifocal chronic inflammatory polyneuropathy triggered by the *B henselae* infection, with definite electrophysiologic criteria not fulfilled.<sup>10</sup>

In conclusion, we present a bilateral mononeuropathic neuralgic amyotrophy triggered by *B henselae* infection responsive to IVIG treatment. It is essential to search for infectious causes or triggers of NA. In case of persisting symptoms after treatment of antecedent infection, IVIG treatment may be an option, even in cases with poor clinical prognosis, considering the probable immune-mediated cause of disease and apparent response to IVIG.

## Study Funding

A.D. has been personally supported by research grants from the Bangerter Rhyner Stiftung and a CTU Research Grant of the University of Bern.

## Disclosure

Anelia Dietmann received funding from the following institutions: Bangerter Rhyner Stiftung, University of Bern, Medical Faculty; Eugénie Colin-Benoit has nothing to declare; Gerd Tinkhauser has nothing to declare; Thomas Raphael Meinel has nothing to declare; Olivier Scheidegger has nothing to declare. Go to [Neurology.org/N](https://www.neurology.org/N) for full disclosures.

## Appendix Authors

Name	Location	Contribution
<b>Anelia Dietmann, MD, PhD</b>	Department of Neurology, Inselspital, Bern University Hospital, University of Bern, Switzerland	Drafting/revision of the manuscript for content, including medical writing for content, major role in the acquisition of data, and study concept or design
<b>Eugénie Colin-Benoit, MD</b>	Department of Infectious Diseases, Inselspital, Bern University Hospital, University of Bern, Switz, Switzerland	Drafting/revision of the manuscript for content, including medical writing for content, and major role in the acquisition of data
<b>Gerd Tinkhauser, MD, PhD</b>	Department of Neurology, Inselspital, Bern University Hospital, University of Bern, Switzerland	Drafting/revision of the manuscript for content, including medical writing for content

Continued

---

## Appendix *(continued)*

Name	Location	Contribution
<b>Thomas Raphael Meinel, MD</b>	Department of Neurology, Inselspital, Bern University Hospital, University of Bern, Switzerland	Drafting/revision of the manuscript for content, including medical writing for content, and major role in the acquisition of data
<b>Olivier Scheidegger, MD</b>	Department of Neurology, Inselspital, Bern University Hospital, University of Bern, Switzerland	Drafting/revision of the manuscript for content, including medical writing for content, and major role in the acquisition of data

## References

1. Van Eijk JJJ, Groothuis JT, Van Alfen N. Neuralgic amyotrophy: an update on diagnosis, pathophysiology, and treatment. *Muscle Nerve*. 2016;53:337-350.

2. Ripellino P, Pasi E, Melli G, et al. Neurologic complications of acute hepatitis E virus infection. *Neurol Neuroimmunol Neuroinflamm*. 2020;7.
3. Stek CJ, van Eijk JJ, Jacobs BC, et al. Neuralgic amyotrophy associated with Bartonella henselae infection. *J Neurol Neurosurg Psychiatry*. 2011;82:707-708.
4. Florin TA, Zaoutis TE, Zaoutis LB. Beyond cat scratch disease: widening spectrum of Bartonella henselae infection. *Pediatrics*. 2008;121(5):e1413-e1425.
5. Canneti B, Cabo-López I, Puy-Núñez A, et al. Neurological presentations of Bartonella henselae infection. *Neurol Sci*. 2019;40(2):261-268.
6. Carithers HA. Cat-scratch disease. An overview based on a study of 1,200 patients. *Am J Dis Child*. 1985;139(11):1124-1133.
7. Allizond V, Costa C, Sidoti F, et al. Serological and molecular detection of Bartonella henselae in specimens from patients with suspected cat scratch disease in Italy: a comparative study. *PLoS One*. 2019;14:e0211945.
8. Hansmann Y, DeMartino S, Piémont Y, et al. Diagnosis of cat scratch disease with detection of Bartonella henselae by PCR: a study of patients with lymph node enlargement. *J Clin Microbiol*. 2005;43:3800-3806.
9. Sander A, Posselt M, Böhm N, Ruess M, Altwegg M. Detection of Bartonella henselae DNA by two different PCR assays and determination of the genotypes of strains involved in histologically defined cat scratch disease. *J Clin Microbiol*. 1999;37:993-997.
10. Van den Bergh PYK, van Doorn PA, Hadden RDM, et al. European Academy of Neurology/Peripheral Nerve Society guideline on diagnosis and treatment of chronic inflammatory demyelinating polyradiculoneuropathy: report of a Joint Task Force—second revision. *J Peripher Nerv Syst*. 2021;26:242-268.

---

## Announcing... Child Neurology: A Case-Based Approach Cases From the Neurology® Resident & Fellow Section

This collaboration between the American Academy of Neurology (AAN) and the Child Neurology Society (CNS) represents a collection of reprinted cases from the past 15 years from the Neurology Resident & Fellow Section.

An invaluable resource for both adult and pediatric neurologists and trainees! FREE download: [Npub.org/cnbook](https://www.ncbi.nlm.nih.gov/pubmed/books/NBK554448)

---

---

## Visit the Neurology® Resident & Fellow Website

Click on Residents & Fellows tab at [Neurology.org](https://www.neurology.org).

Now offering:

- Neurology Resident & Fellow Editorial team information
- “Search by subcategory” option
- E-Pearl of the Week
- Direct links to Career Planning and AAN Resident & Fellow Pages
- Recently published Resident & Fellow articles
- Commentaries by Editors and Resident & Fellow team members

 Find Neurology Residents & Fellows Section on Facebook: [facebook.com/AANResidentsAndFellows](https://www.facebook.com/AANResidentsAndFellows)

 Follow Neurology on Twitter: [@GreenJournal](https://twitter.com/GreenJournal) #NeurologyRF

 Find Neurology Residents & Fellows Section on Instagram: [@aanbrain](https://www.instagram.com/aanbrain) #NeurologyRF

---

# Neurology®

## **Pearls & Oysters: Bilateral Mononeuropathic Neuralgic Amyotrophy Triggered by *Bartonella henselae* Infection Responsive to Immunoglobulin**

Anelia Dietmann, Eugénie Colin-Benoit, Gerd Tinkhauser, et al.

*Neurology* 2022;98;597-600 Published Online before print February 10, 2022

DOI 10.1212/WNL.0000000000200014

**This information is current as of February 10, 2022**

<b>Updated Information &amp; Services</b>	including high resolution figures, can be found at: <a href="http://n.neurology.org/content/98/14/597.full">http://n.neurology.org/content/98/14/597.full</a>
<b>References</b>	This article cites 9 articles, 4 of which you can access for free at: <a href="http://n.neurology.org/content/98/14/597.full#ref-list-1">http://n.neurology.org/content/98/14/597.full#ref-list-1</a>
<b>Subspecialty Collections</b>	This article, along with others on similar topics, appears in the following collection(s): <b>Bacterial infections</b> <a href="http://n.neurology.org/cgi/collection/bacterial_infections">http://n.neurology.org/cgi/collection/bacterial_infections</a> <b>EMG</b> <a href="http://n.neurology.org/cgi/collection/emg">http://n.neurology.org/cgi/collection/emg</a> <b>MRI</b> <a href="http://n.neurology.org/cgi/collection/mri">http://n.neurology.org/cgi/collection/mri</a> <b>Peripheral neuropathy</b> <a href="http://n.neurology.org/cgi/collection/peripheral_neuropathy">http://n.neurology.org/cgi/collection/peripheral_neuropathy</a>
<b>Permissions &amp; Licensing</b>	Information about reproducing this article in parts (figures, tables) or in its entirety can be found online at: <a href="http://www.neurology.org/about/about_the_journal#permissions">http://www.neurology.org/about/about_the_journal#permissions</a>
<b>Reprints</b>	Information about ordering reprints can be found online: <a href="http://n.neurology.org/subscribers/advertise">http://n.neurology.org/subscribers/advertise</a>

*Neurology*® is the official journal of the American Academy of Neurology. Published continuously since 1951, it is now a weekly with 48 issues per year. Copyright © 2022 The Author(s). Published by Wolters Kluwer Health, Inc. on behalf of the American Academy of Neurology. All rights reserved. Print ISSN: 0028-3878. Online ISSN: 1526-632X.

