

Eur Spine J
DOI 10.1007/s00586-014-3737-5

ORIGINAL ARTICLE

Association between spondylolisthesis and L5 fracture in patients with *Osteogenesis Imperfecta*

Pietro Persiani · Jole Graci · Claudia de Cristo ·
Giovanni Noia · Ciro Villani · Mauro Celli

Received: 4 June 2014/Revised: 19 December 2014/Accepted: 21 December 2014
© Springer-Verlag Berlin Heidelberg 2014

Abstract

Purpose To investigate if an association between spondylolisthesis and L5 fracture occurs in patients affected by *Osteogenesis Imperfecta* (O.I.).

Methods Anteroposterior and lateral radiograms were performed on the sample (38 O.I. patients, of whom 19 presenting listhesis); on imaging studies spondylolisthesis was quantified according to the Meyerding classification. Genant's semiquantitative classification was applied on lateral view to evaluate the L5 fractures; skeleton spinal morphometry (MXA) was carried out on the same images to collect quantitative data comparable and superimposable to Genant's classification. The gathered information were analyzed through statistical tests (O.R., χ^2 test, Fisher's test, Pearson's correlation coefficient).

Results The prevalence of L5 fractures is 73.7 % in O.I. patients with spondylolisthesis and their risk of experiencing such a fracture is twice than O.I. patients without listhesis (OR 2.04). Pearson's χ^2 test demonstrates an association between L5 spondylolisthesis and L5 fracture, especially with moderate, posterior fractures ($p = 0.017$) and primarily in patients affected by type IV O.I.

Conclusions Spondylolisthesis represents a risk factor for the development of more severe and biconcave/posterior type fractures of L5 in patients suffering from O.I.,

especially in type IV. This fits the hypothesis that the anterior sliding of the soma of L5 alters the dynamics of action of the load forces, localizing them on the central and posterior heights that become the focus of the stress due to movement of flexion–extension and twisting of the spine. As a result, there is greater probability of developing an important subsidence of the central and posterior walls of the soma.

Keywords Osteogenesis Imperfecta · Spondylolisthesis · Vertebral fracture · Spine · Children

Introduction

Osteogenesis Imperfecta (O.I.) is an inherited skeletal disorder affecting approximately 1 in 20,000 births [1]. Characteristics of the disease are low bone mass, bone fragility and progressive skeletal deformities. In 90 % of cases, etiopathogenesis results from mutations of type 1 collagen, the main structural protein of the bone. As type 1 is an integral component of several tissues, the disease presents also extraskeletal manifestations [2, 3].

According to genetic and clinical heterogeneity, several classification systems were established. Silience classification, the most widely used, distinguishes four clinical types (type I–IV) of O.I. associated with COL1A1 or COL1A2 mutations [4]. Recently, four additional types (type V–VIII) displaying distinct features of the disease and caused by yet unknown mutations have been ascertained; they do not show any evidence of type I collagen abnormality [5, 6].

Characteristic spinal manifestations of the disorder are pathological kyphosis scoliosis, and vertebral fractures.

Spondylolisthesis is the forward displacement of one vertebra relative to the vertebrae below. Bilateral

P. Persiani · J. Graci (✉) · C. de Cristo · G. Noia · C. Villani
University Department of Anatomic, Histologic, Forensic and
Locomotor Apparatus Sciences, Section of Locomotor
Apparatus Sciences, Policlinico Umberto I, Sapienza University
of Rome, Piazzale Aldo Moro 5, 00162 Rome, Italy
e-mail: jolegraci@yahoo.it

M. Celli
University Department of Pediatrics, Policlinico Umberto I,
Sapienza University of Rome, Rome, Italy

spondylolysis, a defect or fracture of the pars interarticularis of the vertebral arch, is the most common cause of spondylolisthesis. In 90 % of cases, L5 is the most affected by listhesis because the stress load due to spine flexion, extension and rotation acts on the isthmus between L5 and S1 [7–10]. In the O.I. pediatric population, the incidence of spondylolisthesis is 10.9 %, observed at an average age of 6.5 years, of which 75 % of isthmic type, while the remaining 25 % of dysplastic type. The elongation of the vertebral pedicle was found in 40 % of patients with O.I. [11].

The aim of the study is to investigate if an association between spondylolisthesis and L5 fracture occurs in patients with type I and IV O. I.

Materials and methods

The inclusion criteria are: O.I. (type I or IV), spondylolisthesis of L5 detected by radiographs.

A total number of 195 O.I. patients followed in our department participated in this study. Among these, 19 patients (group I) met the inclusion criteria.

Belong to group I (14♂, 5♀), 13 patients with type I O.I. and 6 patients with type IV O.I. (average age 19 years, range 4–49 years).

19 O.I. patients without spondylolisthesis, homogeneous to group I for age, sex and type of O.I. were randomly selected and assigned to group II.

Belong to group II (12♂, 7♀), 16 patients with type I O.I. and 3 patients with type IV O.I. (average age 15 years, range 4–50 years).

All patients reported low back pain; nobody took specific medical treatments for O.I.

Anterior–posterior and lateral radiographs were performed on all patients.

Spondylolisthesis was quantified on lateral radiographies, according to Meyerding classification, and was expressed as a slipping percentage of the vertebra (ratio between the amount of anterior translation and the anterior–posterior width of the sacral endplate) (Fig. 1); four grades of slippage were distinguished (grade 1 < 25 %, grade 2 < 50 %, grade 3 < 75 %, grade 4 until 100 %). [12].

Applying Meyerding classification on group I, we recognized grade 1 spondylolisthesis in 13 patients and grade 2 spondylolisthesis in 6 patients.

Genant's semiquantitative grade classification method was applied on lateral view to evaluate the L5 fractures; it classifies them as mild (20–25 %), moderate (26–40 %) or severe grade (>40 %) according to the severity of the fractures, and as wedge, crush or biconcave deformity in relationship with the involvement of the anterior, posterior or both vertebral walls [13].

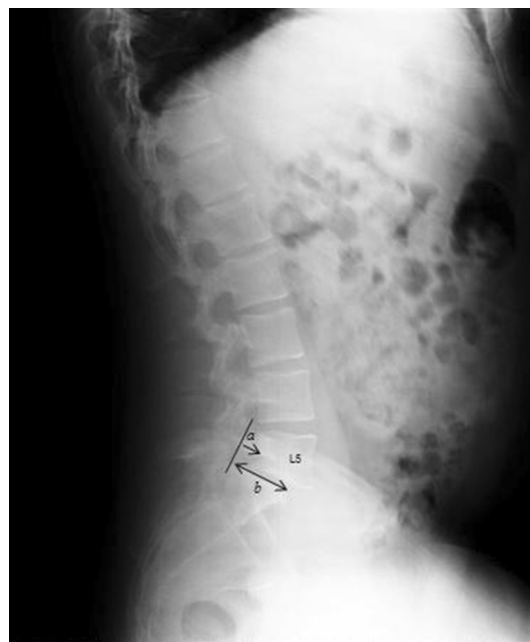

Fig. 1 Lateral radiograph of the spine of patient 11 of group I. Male, 29 years, type IV O.I., I grade listhesis, moderate biconcave fracture. The segment *a* indicates the amount of anterior translation of L5, compared to the anterior-posterior width of the sacral endplate (segment *b*)

Skeleton spinal morphometry (MXA) was carried out on lateral radiograms of the column to collect quantitative data comparable and superimposable to Genant's semiquantitative classification. It is routinely performed on L1–L4 in O.I. patients, as required by our follow-up protocol, to estimate the fracture risk. This technique first involves the placement of six points to define the shape of each vertebral body, corresponding to the four corners of the vertebral body and the two central points of the end plate. From these points, the software automatically measures the distances between the three upper and three lower, that are the three vertebral heights: anterior (*ha*), medium (*hm*) and posterior (*hp*). Vertebral deformities were quantified according to indices described by Eastell et al.: index of wedging $[(1 - ha/hp) \times 100 \text{ %}]$ and concavity index $[(1 - hm/ha) \times 100 \text{ %}]$ [14–16].

To date, there are any reference values for the indices of children vertebral deformity. In our study, we defined vertebral wedge fracture a vertebra with index of wedging $\geq 20 \text{ %}$ and concave vertebral fracture with concavity index of $\geq 20 \text{ %}$. Vertebral morphometry was carried out by the same operator twice in two different moments and the average of the two measurements was calculated.

Statistical analysis

We estimated the prevalence of L5 fractures, detected by semiquantitative method and with vertebral morphometry

in both groups; the odds ratio (OR), which expresses the relative risk of the O.I. patients with spondylolisthesis to develop a L5 fracture, and the OR of patients with listhesis >25 %.

We assessed within this subgroup the risk for fractures of mild, moderate and severe grade, and the existence of any association/correlation with the type of O.I. Finally, we verified the association between the diseases with the χ^2

test and Fisher’s test, while the correlation with the Pearson’s correlation coefficient.

Results

In the sample (38 patients) were identified 25 L5 fractures, distributed as follows: (Tables 1, 2).

Table 1 Group I

Patient	Gender	Age	Type O.I.	Meyerding grade listhesis	Genant grade fracture	Type fracture
1	M	8	I	1	Mild	Biconcave
2	M	15	I	1	Mild	Posterior
3	F	42	I	1	–	–
4	M	9	IV	2	Moderate	Biconcave
5	F	23	I	1	–	–
6	M	6	I	1	Mild	Posterior
7	F	4	I	2	–	–
8	M	6	I	1	Moderate	Posterior
9	M	10	IV	1	Moderate	Biconcave
10	M	11	I	1	Moderate	Posterior
11	M	29	IV	1	Moderate	Biconcave
12	M	49	IV	2	Severe	Posterior
13	F	11	IV	1	–	–
14	F	47	I	1	Mild	Posterior
15	M	14	I	2	Mild	Biconcave
16	M	17	I	2	Moderate	Posterior
17	M	37	IV	1	Moderate	Posterior
18	M	23	I	1	Mild	Biconcave
19	M	4	I	2	–	–

Table 2 Group II

Patient	Gender	Age	Type O.I.	Meyerding grade listhesis	Genant grade fracture	Type fracture
1	M	10	IV	–	Mild	Biconcave
2	M	4	I	–	Mild	Biconcave
3	M	9	I	–	Mild	Biconcave
4	F	8	IV	–	–	–
5	M	4	I	–	–	–
6	M	40	I	–	–	–
7	M	23	I	–	Mild	Biconcave
8	M	26	I	–	Mild	Biconcave
9	M	4	I	–	–	–
10	M	50	I	–	Mild	Biconcave
11	M	5	IV	–	–	–
12	F	4	I	–	–	–
13	F	38	I	–	Mild	Biconcave
14	F	12	I	–	Mild	Biconcave
15	F	12	I	–	–	–
16	M	4	I	–	Mild	Biconcave
17	F	10	I	–	Mild	Biconcave
18	F	12	I	–	–	–
19	M	10	I	–	Mild	Biconcave

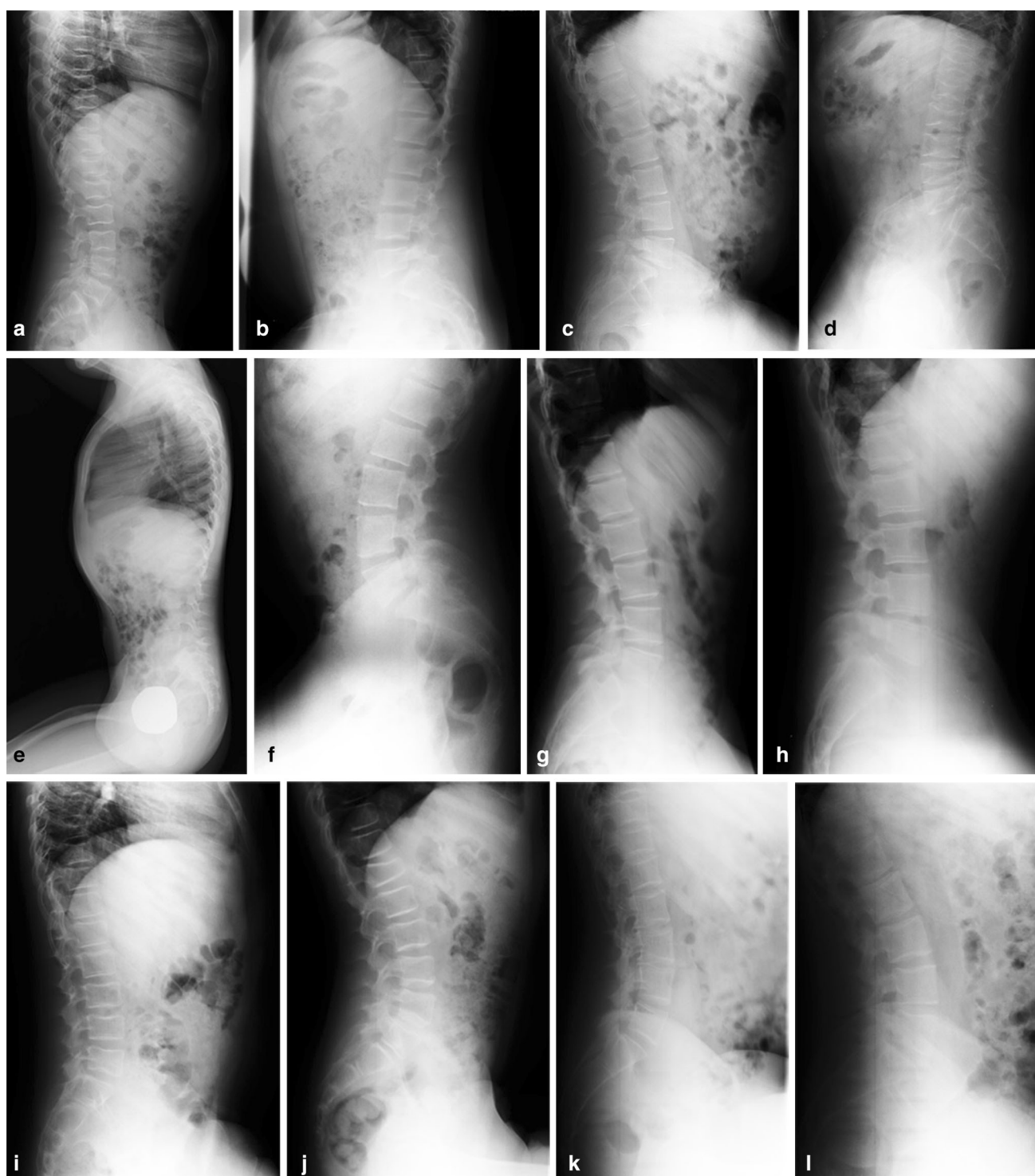


Fig. 2 Examples of images with a more severe and biconcave/posterior type L5 fracture in type IV O.I. with listhesis (a–d) compared with: mild and biconcave/posterior fracture in type I O.I. with listhesis (e–h); mild and biconcave fracture in type I O.I. without listhesis (i–l)

- Group I: 14 vertebral fractures (6 mild, 7 moderate, 1 severe); 6 fractures were biconcave type, 8 posterior type.
- Group II: 11 vertebral fractures, all mild and biconcave type.

The prevalence of L5 fractures observed in the study population (38 patients) was 65.8 %; 73.7 % in group I (42.8 % mild, 50 % moderate and 7.2 % severe), 57.9 % in group II (100 % mild and biconcave type).

Analyzing L5 fractures according to the subtype of O.I., we found out:

- Group I: 6 mild fractures and 3 moderate fractures in 13 patients with type I O.I.; 4 moderate fractures and 1 severe fracture in 6 patients with type IV O.I.
- Group II: 10 mild fractures in 16 patients with type I O.I.; 1 mild fracture in 3 patients with type IV O.I.

The risk of experiencing such a fracture in group I is twice than group II (OR 2.04). This risk, however, is not increased if slippage is >25 % (OR < 1).

The result of the Pearson's χ^2 test demonstrates an association between L5 spondylolisthesis and L5 fracture, especially with moderate-to-severe fractures ($p = 0.017$, CI 95 %). There is no correlation between percentage of listhesis and degree of vertebral fractures, and between percentage of listhesis and fracture type.

Regarding the two subclasses of the types of O.I., there is correlation (Pearson index = 0.31, $p = 0.05$, CI 95 %) between the type of O.I. and the severity of the L5 fracture, with more severe fractures in type IV O.I. than in type I; however, there is no association between the type of O.I. and fracture type, and between this and the percentage of listhesis.

Conclusions

In our population (195 O.I. patients), the prevalence of spondylolisthesis is 9.8 %. It represents a risk factor for the development of more severe L5 fractures and biconcave/posterior type in patients suffering from O.I., especially in type IV (Fig. 2a–l).

The pathogenetic hypothesis that would explain this event is that the anterior sliding of the soma of the fifth lumbar vertebra alters the dynamics of action of the load forces, localizing them on the central and posterior L5 heights that become the focus of the stress due to the movement of flexion–extension and twisting of the spine. As a result, there is greater probability of developing a subsidence of the central and posterior walls of the soma and of higher severity.

The identification of spondylolisthesis as a risk factor of L5 fracture allows an early recognition of the two diseases since the early stages, or clinically silent.

We suggest at the first visit to perform a radiographic study of the spine in anteroposterior and lateral view with focus on lumbosacral column to seek the slippage of the vertebral body; in case of spondylolisthesis the Genant's semiquantitative method and morphometric examination on lateral radiograms should follow to evaluate the existence and the severity of the L5 fracture.

Considering the difficulty in the identification of vertebral fractures with visual method, the imaging study should always proceed with the L5 quantitative morphometric analysis, which should be carried out in all cases by the same operator to reduce the risk of underestimating the pathology.

The early diagnosis would lead to the adoption of conservative treatment strategies such as orthoses, rehabilitation, physiotherapy, practices that limit load, stress and micro-trauma on the spine; these therapeutic measures are less costly for patients' health and quality of life ensuring faster recovery time and reduction of the period of immobilization.

The latter element should set itself as a priority target in O.I. patients because it reduces the risk of “disuse” bone resorption.

Data or studies concerning these conditions have not been described in the literature.

Conflict of interest None.

References

1. Smith R (1995) Osteogenesis Imperfecta: the brittle bone syndrome. *Curr Orthop* 9:28–33
2. Ivo R, Fuerderer S, Eysel P (2007) Spondylolisthesis caused by extreme pedicle elongation in osteogenesis imperfecta. *Eur Spine J* 16:1636–1640
3. D'Eufemia P, Finocchiaro R, Celli M, Zambrano A, Tetti M, Villani C, Persiani P, Mari E, Zicari A (2008) High levels of serum prostaglandin E2 in children with osteogenesis imperfecta are reduced by neridronate treatment. *Pediatr Res* 63(2):203–206
4. Sillence DO, Senn A, Danks DM (1979) Genetic heterogeneity in Osteogenesis Imperfecta. *J Med Genet* 16:101–116
5. Ward LM, Rauch F, Travers R (2002) Osteogenesis imperfecta type VII: an autosomal recessive form of brittle bone disease. *Bone* 31:12–18
6. Van Dijk FS, Pals G, Van Rijn RR, Nikkels PG, Cobben JM (2010) Classification of Osteogenesis Imperfecta revisited. *Eur J Med Genet* 53(1):1–5
7. Wang Z, Mac-Thiong JM, Parent S, Petit Y, Labelle H (2014) The relevance of sacral and sacro-pelvic morphology in developmental lumbosacral spondylolisthesis: are they equally important? *Eur Spine J* 23(1):157–162
8. Newman PH, Stone K (1963) The etiology of spondylolisthesis: with a special investigation. *J Bone Joint Surg Br* 45:39–59
9. Gutman G, Silvestre C, Roussouly P (2014) Sacral doming progression in developmental spondylolisthesis: a demonstrative case report with two different evolutions. *Eur Spine J*
10. Fürstenberg CH, Grieser T, Wiedenhöfer B, Gerner HJ, Putz CM (2010) The role of kyphoplasty in the management of osteogenesis imperfecta: risk or benefit? *Eur Spine J* 19(Suppl 2):S144–S148
11. Hatz D, Esposito PW, Schroeder B, Burke B, Lutz R, Hasley BP (2011) The incidence of spondylolysis and spondylolisthesis in children with osteogenesis imperfecta. *J Pediatr Orthop* 31:655–660
12. Meyerding HW (1932) Spondylolisthesis. *Surg Gynecol Obstet* 54:371–377

-
13. Genant HK, Wu CY, Van Kuijk C et al (1993) Vertebral fracture assessment using a semiquantitative technique. *J Bone Miner Res* 8:1137–1148
 14. Hedlund LR, Gallagher JC (1988) Vertebral morphometry in diagnosis of spinal fractures. *Bone miner* 5:59–67
 15. Mazzuoli GF, Diacinti D, Acca M et al (1998) Relationship between spine bone mineral density and vertebral body heights. *Calcif Tissue Int* 62:486–490
 16. Genant HK, Jergas M, Palermo L et al (1996) Comparison of semiquantitative visual and quantitative morphometric assessment of prevalent and incident vertebral fractures in osteoporosis. *J Bone Miner Res* 11:984–996