

КЛИНИЧЕСКИЕ СЛУЧАИ / CASE REPORTS

UDC 616.832-004-018.834.008.64-053.02-07-08

<http://dx.doi.org/10.22328/2079-5343-2022-13-2-81-84>**MULTIVOXEL 1H-MR SPECTROSCOPY AS A POTENTIAL DIAGNOSTIC TOOL IN THE COMPLEX DIAGNOSIS OF MULTIPLE SCLEROSIS TYPE CONVERSION: A CASE REPORT**

Galina G. Shkilnyuk[✉], Andrey A. Bogdan[✉], Elena V. Kryukova^{✉*}, Igor D. Stolyarov[✉], Tatyana N. Trofimova[✉]
N. P. Behtereva Institute of the Human Brain of the Russian Academy of Sciences, St. Petersburg, Russia

The onset of progressive deficit in multiple sclerosis (MS) was often determined retrospectively with difficulties in diagnostic. This is a case report with subtle MS progression. Clinical and structural MRI anamnesis was complemented with multivoxel 1H-MRS examination. The patient complained of the walking distance reducing, gradually increasing spasticity in the distal parts of lower extremities, unsteadiness when walking, clumsy movements. Choline and myoinositol levels were predominantly increased in the area of the cingulate gyrus versus other gray matter regions and the same picture was observed in adjacent white matter. Multivoxel 1H-MRS represents a diagnostic tool that can be very useful in complex diagnostic of MS progression. Measuring chemical-pathological changes diffusely in brain tissues may detect distinctive for progression metabolic patterns.

KEYWORDS: progressive multiple sclerosis, disease conversion, multivoxel 1H-MR spectroscopy, diagnostic tool

*For correspondence: Elena V. Kryukova, eldementyeva@gmail.com.

For citation: Shkilnyuk G.G., Bogdan A.A., Kryukova E.V., Stolyarov I.D., Trofimova T.N. Multivoxel 1H-mr spectroscopy as a potential diagnostic tool in the complex diagnosis of multiple sclerosis type conversion: a case report // *Diagnostic radiology and radiotherapy*. 2022. Vol. 13, No. 2. P. 81–84. DOI: <http://dx.doi.org/10.22328/2079-5343-2022-13-2-81-84>

МУЛЬТИВОКСЕЛЬНАЯ 1Н-МР-СПЕКТРОСКОПИЯ КАК ПОТЕНЦИАЛЬНЫЙ ДИАГНОСТИЧЕСКИЙ ИНСТРУМЕНТ В КОМПЛЕКСНОЙ ДИАГНОСТИКЕ ПРОГРЕССИРОВАНИЯ РАССЕЯННОГО СКЛЕРОЗА: КЛИНИЧЕСКИЙ СЛУЧАЙ

Г. Г. Шкильнюк[✉], А. А. Богдан[✉], Е. В. Крюкова^{✉*}, И. Д. Столяров[✉], Т. Н. Трофимова[✉]
Институт мозга человека имени Н. П. Бехтеревой Российской академии наук, Санкт-Петербург, Россия

В связи с трудностями диагностики момент начала накопления прогрессирующего дефицита при рассеянном склерозе (РС) часто определяется ретроспективно. Данная статья представляет собой описание клинического случая с труднораспознаваемым прогрессированием рассеянного склероза. Пациент обратился с жалобами на уменьшение дистанции ходьбы, постепенно нарастающая спастичность в дистальных отделах нижних конечностей, шаткость при ходьбе, неловкость движений. Клинический и структурный МРТ-анализ был дополнен мультिवоксельной 1H-МР-спектроскопией (1H-MPC). Уровни холина и миоинозитола были преимущественно повышены в области поясной извилины по сравнению с другими областями серого вещества, такая же картина наблюдалась в прилежащем к поясной извилине белом веществе. Мультिवоксельная 1H-MPC представляет собой диагностический инструмент, который может быть очень полезен в комплексной диагностике прогрессирования рассеянного склероза. Диффузное измерение химико-патологических изменений в тканях головного мозга может выявить характерные для прогрессирования метаболические паттерны.

КЛЮЧЕВЫЕ СЛОВА: прогрессирующий рассеянный склероз, конверсия течения заболевания, мультिवоксельная 1H-MR-спектроскопия, диагностика

*Для корреспонденции: Крюкова Елена Владимировна, eldementyeva@gmail.com.

© Авторы, 2022. Издательство ООО «Балтийский медицинский образовательный центр». Данная статья распространяется на условиях «открытого доступа», в соответствии с лицензией CCBY-NC-SA 4.0 («Attribution-NonCommercial-ShareAlike») / «Атрибуция-Некоммерчески-Сохранение Условий» 4.0), которая разрешает неограниченное некоммерческое использование, распространение и воспроизведение на любом носителе при условии указания автора и источника. Чтобы ознакомиться с полными условиями данной лицензии на русском языке, посетите сайт: <https://creativecommons.org/licenses/by-nc-sa/4.0/deed.ru>

Для цитирования: Шкильнюк Г.Г., Богдан А.А., Крюкова Е.В., Столяров И.Д., Трофимова Т.Н. Возможности магнитно-резонансной томографии в диагностике острого асептического сакроилита у детей: клинический случай // *Лучевая диагностика и терапия*. 2022. Т. 13, № 2. С. 81–84. DOI: <http://dx.doi.org/10.22328/2079-5343-2022-13-2-81-84>

Introduction. Multiple sclerosis (MS) represents a chronic inflammatory condition with concomitant axonal demyelination and neuronal degeneration.

Approximately 85% of patients with MS present with a relapsing-remitting course of the disease (RRMS), and the majority of these advancements to a progressive disease course — secondary progressive MS (SPMS).

Clinically the SPMS is characterized by the accumulation of disability in the absence of relapses [1] for ≥ 6 months following an initial RRMS; however, this definition is not always easily applied in clinical practice. The earliest indicators of SPMS may be subtle, diagnostic is uncertain.

The onset of progressive deficit was often determined retrospectively [2].

Thus, delay in definitive identification of an SPMS has a variety of implications related to patient care and research.

Using conventional MRI is difficult to differentiate PMS from RRMS. Appearing new lesions even enhancing or not stops working as define diagnostic criteria in a stage of progression. The complexity of the pathophysiological mechanisms involved in MS progression demands versatile diagnostic approaches.

¹H-MRS provides important insights into the chemical-pathological changes that take place in patients with MS, not only within focal lesions visible on conventional MRI, but also within the normal-appearing brain tissue [3].

In the current paper, we introduce a case report of a young patient with early but subtle progression from RRMS to SPMS with continuous slow worsening of the neurological picture and disputable MRI findings.

Case Report. A 35-year-old white woman was firstly diagnosed with RRMS in 2009 (at age 23) after preceding severe acute respiratory syndrome. Appropriate neurological symptoms were accomplished with an MRI picture of multiple demyelinating lesions in the brain and cervical spinal cord.

The patient underwent course methylprednisolone (1000 mg, N5). Afterward patient has gradual improvement with regress of neurological symptoms. Cerebrospinal fluid analysis showed the synthesis of oligoclonal IG.

The patient was started on Avonex and continued on it till March 2017. During this time patient had 2 exacerbations (2014 and the end of 2017 years), regressing under a high-dose GCS therapy course. As for the MRI picture: in the year 2014 — without dynamic from the year 2009; in the year 2017 — similar picture but two enhancing lesions were presented in the left lobe and parietal lobes.

After it, April 2017 Ofatumab was assumed and have been started after signing by the patient all necessary informed consent forms (retrospectively unblinded after finishing the clinical trial close phase).

From the year 2017 till the present time no clinical relapses were observed, no MRI active lesions were detected. The patient has very slow but define progression in pyramidal (from mild leg weakness to low limb paraparesis) and cerebellar functional systems. Nowadays EDSS changed from 2 to 3,5.

Possible conversion to progressive MS type was suspected.

MRS results. In December 2020 Multivoxel ¹H-MRS was performed in frontal and parietal lobes. SE FOV 220×190×30 mm, with ACQ matrix 20×16. Spectroscopy was performed before contrast enchantment administration. Spectroscopic slices were laid in parallel with transversal slices, the bottom edge of the upper SE slice touched the apical sides lateral ventricles. Ten REST (REgional Saturation Technique) bands were applied for skull fat signal suppression, protocol included second-order automated shim procedures Pencil Beam («PB-auto»), and water suppression «excitation» (window=140 Hz; second pulse angle=300). Metabolites relative amounts have been measured diffusely (without differentiated counting in plaques or other prominent areas) in gray and white matter in SE impulse sequences.

Results are presented as (median, percentiles, P<0.05). Statistical analysis was performed using SPSS 26.0 (SPSS Inc.). Results were processed using nonparametric tests, P-values below 0.05 were considered statistically significant.

As the area of interest was chosen the anterior cingulate cortex (ACC), which is a functionally heterogeneous region, represents a key compartment of the limbic system and is involved in diverse cognitive and emotional processes, such as attention and emotional control, formation of memory, cognitive function, regulation and movement planning. Impairments of the mentioned above function is often revealed in MS patients [4].

Statistical comparison of the Cho/Cr level in the area of interest (medial cortex of middle third of lobe) showed a significant increase in Cho/Cr ratio versus other gray matter regions and the same picture was observed adjacent to cingulate gyrus white matter. It is worth mentioning that in the middle third of the frontal lobes choline amount is higher than 1 in both gray and white which is reflecting membrane turnover as an indicator of inflammatory demyelination.

The same tendency was observed in the myoinositol level. There was a significant difference in white matter

Table
Cho/Cr and ml/Cr significantly different levels in medial cortex of middle third of lobe and adjacent white matter (median (percentiles)) measured by SE and PRESS sequences

Таблица

Статистически значимо различающиеся уровни Cho/Cr и ml/Cr в медиальной коре средних третей лобных долей и прилежащем белом веществе (медиана (процентиля))

	Area of interest Median (percentiles)	Area of comparison Median (percentiles)	p
GM Cho/Cr	0,915 (0,878; 0,957)	0,712 (0,623; 0,728)	0,006
WM Cho/Cr	0,808 (0,757; 0,893)	0,106 (0,941; 1,040)	0,004
WM ml/Cr	0,438 (0,399; 0,507)	0,275 (0,151; 0,323)	0,001

during comparison described area of interest with other regions, in gray matter tendency did not reach the statistical significance Table.

The levels of N-acetyl aspartate in the medial cortex of the middle third of the lobe and adjacent white matter was not significantly different in the mentioned above area. It showed equal distribution in all voxels of measured supraventricular brain slice and meaning was not far from normal age N-acetyl aspartate values.

lesion load. A decrease in the occurrence of new T2 lesions occurs concomitantly to the clinical transition between RRMS and SPMS [5].

As for discovering pathogenetic pathways, 1H-MRS seems to be more useful than conventional radiologic methods. During the relapsing stage plaque-like demyelination intense focal inflammatory component, mainly in lesions and perifocal area. With progression developing chronic inflammation appears to be diffuse-

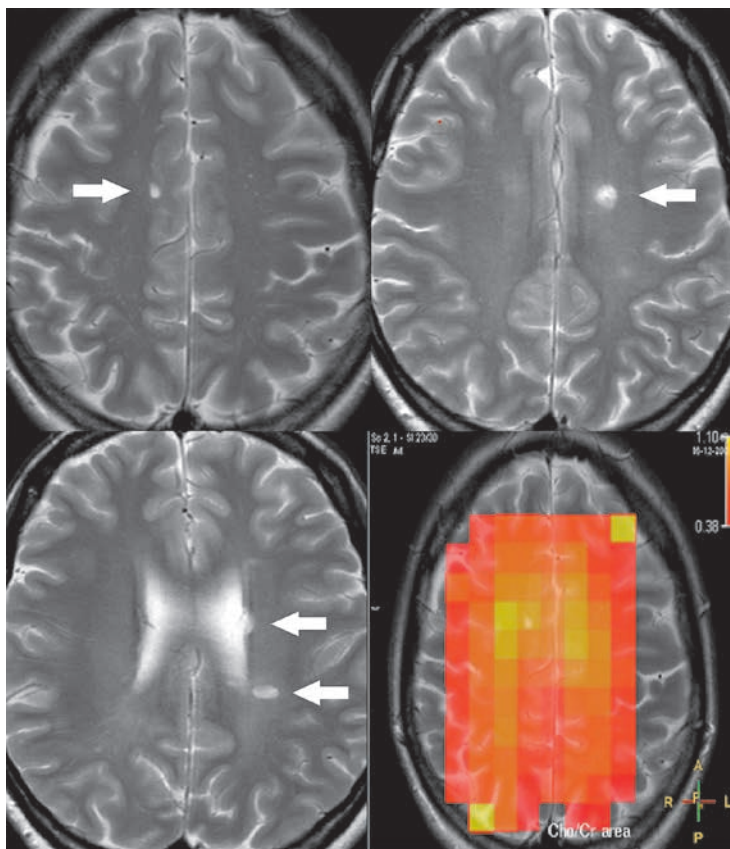


Figure. There are specific for MS lesions on MRI T2-weighted images (marked with arrows). Metabolic picture (right low corner): Cho/Cr demonstrates increasement in white matter and medial cortex middle thirds of lobes (bright yellow color)
Рисунок. На T2-взвешенных МРТ изображениях видны характерные для РС очаги демиелинизации (отмечены стрелками). Метаболическая картина (правый нижний угол) демонстрирует увеличение Cho/Cr в медиальной коре средних третей лобных долей (ярко-желтый цвет) и прилежащем белом веществе

Discussion. The pathogenesis of SPMS is not well understood and as consequence, no validated outcome metrics have been established for defining diagnosis.

Usually, RRMS patients are undergoing slowly gradient neurological worsening with no change in brain

ly in the brain [6, 7]. All brain tissues are going to be involved in MS pathogenesis, which prompts us to diffuse the multi-voxel approach of spectroscopic examination. Based on our previous research we have chosen supraventricular slice with medial cortex and

adjacent WM as areas with the most intensive changes.

A described case report showed a significant diffuse increase of Cho level in the middle part of ACC and white matter of lobes. In the described case, we report a significant increase of myoinositol level in the middle third of the frontal lobes white matter Figure.

According to our previous long-term MRS study: RRMS has a relatively uniform an increased concentration of choline distribution, mainly in the white matter of the cerebral hemispheres; SPMS has localized

increased Cho level in the white and gray matter of the middle third of the frontal lobes.

At present, there are no evidence-based guidelines for using activity assessment for management decisions in clinical practice [8].

To define conversion in MS type diagnostic procedures should be complex, including clinical anamnesis, conventional MRI, and MRS measured metabolic changes can be significantly useful in early progression diagnosis. Predicting disease evolution is becoming essential for optimizing treatment decision-making in MS.

Author names and affiliations:

Shkilnyuk Galina Gennad'evna — Cand. of Sci. (Med.), neurologist, scientific researcher of the laboratory of neuroimmunology, N. P. Bechtereva Institute of the Human Brain of the Russian Academy of Sciences, Akademika Pavlova Street, 9, St. Petersburg, 197376, Russia; e-mail: galinakima@mail.ru; ORCID 0000-0001-7175-668X;

Bogdan Andrey Aleksandrovič — Cand. of Sci. (Med.), radiologist, junior scientific researcher of the laboratory of stereotaxis, N. P. Bechtereva Institute of the Human Brain of the Russian Academy of Sciences, Akademika Pavlova Street, 9, St. Petersburg, 197376, Russia; e-mail: andrey.a.bogdan@gmail.com; ORCID 0000-0002-2836-1516;

Kryukova Elena Vladimirovna — Cand. of Sci. (Med.), scientific researcher of the laboratory of preparation intracerebral delivery, N. P. Bechtereva Institute of the Human Brain of the Russian Academy of Sciences, Akademika Pavlova Street, 9, St. Petersburg, 197376, Russia; e-mail: eldementyeva@gmail.com; ORCID 0000-0002-5395-9931;

Stolyarov Igor Dmitrievich — Dr. of Sci. (Med.), neurologist, head of the laboratory of neuroimmunology, N. P. Bechtereva Institute of the Human Brain of the Russian Academy of Sciences; e-mail: sid@ihb.spb.ru; ORCID 0000-0001-8154-9107;

Trofimova Tatiana Nikolaevna — Corresponding Member of the Russian Academy of Sciences, Dr. of Sci. (Med.), professor, radiologist, Institute of the human brain N. P. Bekhtereva of the Russian Academy of Sciences; The main specialist of the laboratory of neuroimaging; 9 Academic Pavlova st.; St. Petersburg, 197376, Russia; e-mail: TTrofimova@sogaz-clinic.ru; ORCID 0000-0003-4871-2341.

Информация об авторах:

Шкильнюк Галина Геннадьевна — кандидат медицинских наук, научный сотрудник лаборатории нейроиммунологии федерального государственного бюджетного учреждения науки «Институт мозга человека имени Н. П. Бехтеревой» Российской академии наук; 197376, Санкт-Петербург, ул. Академика Павлова, д. 9; e-mail: galinakima@mail.ru; ORCID 0000-0001-7175-668X;

Богдан Андрей Александрович — кандидат медицинских наук, младший научный сотрудник лаборатории стереотаксических методов федерального государственного бюджетного учреждения науки «Институт мозга человека имени Н. П. Бехтеревой» Российской академии наук; 197376, Санкт-Петербург, ул. Академика Павлова, д. 9; e-mail: andrey.a.bogdan@gmail.com; ORCID 0000-0002-2836-1516;

Крюкова Елена Владимировна — кандидат медицинских наук, невролог Центра РС федерального государственного бюджетного учреждения науки «Институт мозга человека имени Н. П. Бехтеревой» Российской академии наук; 197376, Санкт-Петербург, ул. Академика Павлова, д. 9; e-mail: eldementyeva@gmail.com; ORCID 0000-0002-5395-9931;

Столяров Игорь Дмитриевич — доктор медицинских наук, профессор, руководитель Центра РС федерального государственного бюджетного учреждения науки «Институт мозга человека имени Н. П. Бехтеревой» Российской академии наук; 197376, Санкт-Петербург, ул. Академика Павлова, д. 9; e-mail: sid@ihb.spb.ru; ORCID 0000-0001-8154-9107;

Трофимова Татьяна Николаевна — доктор медицинских наук, профессор, член-корреспондент РАН, ведущий научный сотрудник лаборатории нейровизуализации федерального государственного бюджетного учреждения науки «Институт мозга человека имени Н. П. Бехтеревой» Российской академии наук; 197376, Санкт-Петербург, ул. Академика Павлова, д. 9; e-mail: TTrofimova@sogaz-clinic.ru; ORCID 0000-0003-4871-2341.

Author contribution. All authors met the ICMJE authorship criteria.

Вклад авторов. Все авторы подтверждают соответствие своего авторства, согласно международным критериям ICMJE (все авторы внесли существенный вклад в разработку концепции, проведение исследования и подготовку статьи, прочли и одобрили финальную версию перед публикацией).

Disclosure. The authors declare that they have no competing interests.

Потенциальный конфликт интересов: авторы заявляют об отсутствии конфликта интересов.

Adherence to ethical standards: informed consent is obtained of the patient.

Соответствие принципам этики: информированное согласие получено от пациента.

Поступила /Received: 31.05.2022

Принята к печати/ Accepted: 16.06.2022

Опубликована/ Published: 30.06.2022

REFERENCES/ЛИТЕРАТУРА

- Faissner S., Plemel J.R., Gold R., Yong V.W. Progressive multiple sclerosis: from pathophysiology to therapeutic strategies // *Nature reviews drug discovery*. 2019. Vol. 18, No. 12. P. 905–922. doi: 10.1038/s41573-019-0035-2.
- Weinshenker B.G., Bass B., Rice G.P., Noseworthy J., Carriere W., Baskerville J., Ebers G.C. The natural history of multiple sclerosis: a geographically based study: I. Clinical course and disability // *Brain*. 1989. Vol. 112 (Pt. 1). P. 133–146. doi: 10.1093/brain/112.1.133.
- Rovira A., Auger C., Alonso J. Magnetic resonance monitoring of lesion evolution in multiple sclerosis // *Therapeutic advances in neurological disorders*. 2013. Vol. 6, No. 5. P. 298–310. doi: 10.1177/1756285613484079.
- Chiaravalloti N.D., DeLuca J. Cognitive impairment in multiple sclerosis // *Lancet Neurology*. 2008. Vol. 7, No. 12. P. 1139–1151. doi: 10.1016/S1474-4422(08)70259-X.
- Ontaneda D. Progressive Multiple Sclerosis // *Continuum (Minneapolis)*. 2019. Vol. 25, No. 3. P. 736–752. doi: 10.1212/CON.0000000000000727.
- Katz S.I., Krieger S., Farrell C., Miller A.E. Diagnostic uncertainty during the transition to secondary progressive multiple sclerosis // *Multiple sclerosis journal*. 2014. Vol. 20, No. 12. P. 1654–1657. doi: 10.1177/1352458514521517.
- Lassmann H., van Horssen J., Mahad D. Progressive multiple sclerosis: pathology and pathogenesis // *Nature reviews neurology*. 2012. Vol. 8, No. 11. P. 647–656. doi: 10.1038/nrneuro.2012.168.
- Lublin F.D., Reingold S.C., Cohen J.A., Cutter G.R., Sørensen P.S., Thompson A.J., Wolinsky J.S., Balcer L.J., Banwell B., Barkhof F., Br. B.B., Calabresi P.A., Clanet M., Comi G., Fox R.J., Freedman M.S., Goodman A.D., Inglesse M., Kappos L., Kieser B.C., Lincoln J.A., Lubetzki C., Miller A.E., Montalban X., O'Connor P.W., Petkau J., Pozzilli C., Rudick R.A., Sormani M.P., Stüve O., Waubant E., Polman C.H. Defining the clinical course of multiple sclerosis: the 2013 revisions // *Neurology*. 2014. Vol. 83, No. 3. P. 278–286. doi: 10.1212/WNL.0000000000000560.