

EMFF Operational  
Programme 2014-2020

## Marine Biodiversity

Assessment of species catch composition in  
fisheries posing a risk to biodiversity

# Supply of Vertebrate Necropsy and Sample Recovery Services

Merged Final Reports

EMFF 2014-2020

Marine Institute Report Series

Citation/Authors: Stephanie Levesque, Jim O'Donovan, Mags  
Daly, Sinéad Murphy, Mick O'Connell, Paul Jepson, Rob Deaville,  
James Barnett, and Simon Berrow.

Although every effort has been made to ensure the accuracy of the material contained in this publication, complete accuracy cannot be guaranteed. Neither the Marine Institute nor the author accepts any responsibility whatsoever for loss or damage occasioned, or claimed to have been occasioned, in part or in full as a consequence of any person acting or refraining from acting, as a result of a matter contained in this publication. All or part of this publication may be reproduced without further permission, provided the source is acknowledged.

<b>Operational Programme</b>	European Maritime and Fisheries Fund (EMFF) Operational Programme 2014-2020
<b>Priority</b>	Union Priority 1 Sustainable Development of Fisheries Union Priority 6 Fostering the implementation of the Integrated Maritime Policy
<b>Thematic Objective</b>	TO 6 - Preserving and protecting the environment and promoting resource efficiency
<b>Specific Objective</b>	UP1 SO1 - Reduction of the impact of fisheries and aquaculture on the marine environment, including the avoidance and reduction, as far as possible, of unwanted catch. UP1 SO2 - Protection and restoration of aquatic biodiversity and ecosystems. UP6 SO1 - Development and implementation of the Integrated Maritime Policy
<b>Measure</b>	Marine Biodiversity Scheme
<b>Project Reference</b>	Assessment of species catch composition in fisheries posing a risk to biodiversity MB/2017/04 & MB/2019/04
<b>EMFF Certifying Body</b>	Finance Division, Department of Agriculture, Food and the Marine
<b>Managing Authority</b>	Marine Agencies & Programmes Division, Department of Agriculture, Food and Marine
<b>Specified Public Beneficiary Body</b>	Marine Institute
<b>Grant Rate</b>	100%
<b>EU Co-Financing Rate</b>	50%
<b>Legal Basis</b>	Article 29, 40 & 80 EMFF

This project or operation is part supported by the Irish government and the European Maritime & Fisheries Fund as part of the EMFF Operational Programme for 2014-2020



An Roinn Talmhaíochta,  
Bia agus Mara  
Department of Agriculture,  
Food and the Marine



EUROPEAN UNION  
This measure is part-financed  
by the European Maritime  
and Fisheries Fund



*Foras na Mara*  
*Marine Institute*

## Background

In Ireland, monitoring of bycatch interactions of endangered and protected species with fisheries is carried out through an enhanced bycatch programme focusing on high-risk fisheries, which was launched to supplement the standard at sea catch-sampling programme that is conducted as part of The Data Collection Framework (DCF) programme. As part of this project, a Necropsy pilot study was conducted on stranded cetaceans to evaluate mortality through fisheries' bycatch. The project also aimed to provide resources not readily available through the standard sampling schemes, in the form of animal tissue samples, to facilitate the future investigation of areas of concern for marine mammals in Irish waters.

The Necropsy pilot study was established in 2017, and was conducted in two phases; the first phase ran from October 2017 until December 2018 (Tender: ITT17-024, ITT18-005), the second phase from January to November 2019 (Tender: ITT18-050). The work was contracted to the Irish Whale and Dolphin Group (IWDG) and Galway Mayo Institute of Technology (GMIT), with support from the Regional Veterinary Laboratory (RVI) in Cork and in consultation with the Institute of Zoology (IoZ) in London. The study focused on three marine mammal species of potential bycatch concern, common dolphins (*Delphinus delphis*), striped dolphins (*Stenella coeruleoalba*), and harbour porpoises (*Phocoena phocoena*), and over the course of the programme a total of 118 specimens were recovered for necropsy, the majority of which were common dolphins (71%). In addition to determining the *cause of death* (COD), tissue samples from all specimens were collected and are being used as part of ongoing contaminant, diet, aging, and stress studies. Overall, confirmed bycatch was considered to represent between approximately 10 and 20% of all CODs. The proportion of CODs attributed to bycatch varied between the two phases of the study, attributed to a number of factors including increased sampling effort and the better condition of specimens in the peak winter season of 2019.

Results of this study can assist the design of future monitoring programmes to support Ireland's reporting obligations under MSFD, OSPAR, Natura and the CFP. In addition, the sample repository collected as part of the study has the potential to further contribute to broadening our understanding of cetacean ecology and life history, to other MSFD Descriptors and to OSPAR contaminant ecosystem indicators, through independent studies carried out in both Irish universities and the Marine Institute.

Reports from IWDG from both phases of the pilot study are presented in the following sections. The Marine Biodiversity Scheme is established under Union Priority 1 (Sustainable Fisheries) and Union Priority 6 (Integrated Maritime Policy) of Ireland's Operational Programme (OP) under the EMFF and is co-funded by the Irish Government and the EU.

## Contents

Supply of Vertebrate Necropsy and Sample Recovery Services 2017-2018 Final Report.....	6
Executive Summary .....	7
Introduction.....	7
Methods .....	8
Results .....	11
Discussion .....	38
Acknowledgements .....	39
References .....	40
Appendices .....	42
Supply of Vertebrate Necropsy and Sample Recovery Services Extension - 2019 Final Report .....	63
Executive Summary .....	64
Introduction.....	64
Methods .....	65
Results .....	68
Discussion .....	84
Acknowledgements .....	87
References .....	88
Appendices .....	90



An Roinn Talmhaíochta,  
Bia agus Mara  
Department of Agriculture,  
Food and the Marine



## Supply of Vertebrate Necropsy and Sample Recovery Services 2017-2018 Final Report

*Stephanie Levesque<sup>1</sup>, Jim O'Donovan<sup>2</sup>, Mags Daly<sup>1</sup>, Sinéad Murphy<sup>3</sup>, Mick O'Connell<sup>1</sup>,  
Paul Jepson<sup>4</sup>, James Bartnett<sup>4</sup>, Rob Deaville<sup>4</sup> and Simon Berrow<sup>1</sup>*

<sup>1</sup> Irish Whale and Dolphin Group, Merchants Quay, Kilrush, Co. Clare, Ireland

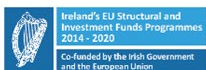<sup>2</sup> Regional Veterinary Laboratory, Model Farm Road, Co. Cork, Ireland

<sup>3</sup> Galway-Mayo Institute of Technology, Old Dublin Road, Co. Galway

<sup>4</sup> UK Cetacean Strandings Investigation Programme, Zoological Society of London, Institute of Zoology, Zoological Society of London, Regent's Park, London NW1 4RY

Reference Number: ITT17-024, ITT18-005

Clients: Marine Institute with support of the National Parks and Wildlife Service, Department of Culture, Heritage and the Gaeltacht



An Roinn Talmhaíochta,  
Bia agus Mara  
Department of Agriculture,  
Food and the Marine



EUROPEAN UNION  
This measure is part-financed  
by the European Maritime  
and Fisheries Fund



Foras na Mara  
Marine Institute



National Park &  
Wildlife Service

February 2022

## Executive Summary

The Marine Institute (MI) issued a tender for the *Supply of Vertebrate Necropsy and Sample Recovery Services* Tender to cover the period of June 2017 to December 2017 (ITT17-024). They then requested an extension of this contract to continue throughout the period of January to March 2018. Following this extension, a second contract was issued to cover the period April to December 2018 (ITT18-005). The results of these two contracts have been merged for the purposes of this report.

These tenders required i) the recovery and standardised necropsy of three cetacean species with associated case history reporting, ii) the provision of sampling kits to be used for the recovery of tissue samples collected from bycaught animals (birds, seals and cetaceans) by observers on commercial inshore and offshore fishing vessels in Irish waters in order to provide additional data to the MI's existing catch sampling programme and iii) the storage and subsequent delivery of all samples and associated databases to the client.

Recovery of 24 animals from two geographical lots was the target for the initial contract (2017) and was achieved. The contract extension (early 2018) required the collection and necropsy of a further 16 animals, which was exceeded as 19 animals were collected. A target of 30 animals to be recovered was required in the second contract (2018) and was also successfully reached. These 73 animals comprised 53 common dolphins (*Delphinus delphis*), ten striped dolphins (*Stenella coeruleoalba*) and ten harbour porpoises (*Phocoena phocoena*). Forty-one of the 73 (56%) individuals were recovered from Lot 1 from counties Clare to Donegal, while 32 (44%) individuals were recovered from Lot 2 from counties Wexford to Kerry.

Thirty-five sampling kits were assembled and delivered to the Marine Institute, and additional kits were prepared and available upon request for distribution to their panel of fishery observers. Between 24 July and 14 December 2017, two adult male grey seals were incidentally captured in tangle nets and reported to the Project Coordinator. Results from these tenders will inform the development of a long-term strategy for necropsy of stranded cetaceans and recovery of tissue samples for further biological studies.

Samples requiring long-term storage at -20°C, including those for virology, were transported in a portable refrigerator to the IWDG office in Kilrush, Co. Clare and stored at facilities on site. Formalin fixed tissues, such as reproductive organs and adrenal glands, were stored at the RVL in Cork. All samples have been delivered to the Marine Institute in Oranmore, Co. Galway along with a detailed database of samples collected.

## Introduction

The Marine Institute (MI) published two tenders for the provision of vertebrate necropsy services for cetaceans stranded on the Irish coast and for the provision of sampling kits for observers involved in Data Collection Framework (DCF) surveys. These contracts were delivered by the Irish Whale and Dolphin Group (IWDG) as the main contractor with two sub-contractors - the Regional Veterinary Laboratories (RVL) of the

Department of Agriculture, Food and the Marine (DAFM) and the Galway-Mayo Institute of Technology (GMIT).

The first task of the contract required the recovery and standardised necropsy of a targeted sample of three species of stranded cetaceans, with associated case history reporting. The second task consisted of the provision of sampling kits to be used for the recovery of tissue samples collected from bycaught animals (birds, seals and cetaceans) by Data Collection Framework (DCF) observers out on commercial fishing vessels in Irish waters. The existing catch sampling at sea programme is led by the MI for the DAFM in order to enhance and verify the accuracy of catch data as well as support the wider assessment of commercial fish/shellfish and to assess fish catches under the DCF programme (Marine Institute, 2017).

The aim of these contracts was to conduct standardized laboratory necropsies of a targeted number of common and striped dolphins, as well as harbour porpoises. Stranded cetaceans were sourced and retrieved via the IWDG Cetacean Stranding Scheme, which was established in 1991 and co-ordinates a network of trained recorders throughout Ireland.

## Methods

### NECROPSIES

Three species were targeted for collection for necropsy; common dolphin (*Delphinus delphis*), striped dolphin (*Stenella coeruleoalba*) and harbour porpoise (*Phocoena phocoena*). The area of coverage for the contract extended from County Donegal to County Wexford, which was divided into two lots. Lot 1 included coastal areas of counties Donegal to County Clare inclusive, and Lot 2 consisted of coastal areas of counties Kerry to south County Wexford inclusive. A target of 24 animals was set for the first contract, followed by 16 during the contract extension, and 30 for the subsequent contract issued by the MI and the National Parks and Wildlife Service (NPWS) to be split evenly between each lot where possible. This report covers the period from June 2017 to December 2018.

#### *Locating carcasses and assessing suitability for necropsy*

The IWDG has been co-ordinating an All-Ireland Cetacean Stranding Scheme since 1991 and has a network of recorders who visit and photograph stranded animals and record basic parameters, with over 90% of records accompanied by photographs. This network was used to locate and assess the suitability of stranded target species for necropsy.

Suitability of carcasses for post-mortem was assessed by examining available photographs and utilising descriptions of body condition as defined by the UK Cetacean Strandings Investigation Programme (CSIP) (2016). Carcasses were recovered within decomposition codes: **2a** (extremely fresh), **2b** (slight decomposition), **3** (moderate decomposition) and **4** (advanced decomposition) – see Figure 1. If no photos were available, the animal was deemed unsuitable for collection.



Decomposition code 2a. Extremely fresh



**Photo 1. A female common dolphin which live stranded at Ballylongford, Co. Kerry with a calf (Photo. Joanne O'Brien)**

Decomposition code 2b. Slight decomposition



**Photo 2. A female striped dolphin was found dead on Derrymore Strand, Co. Kerry (Photo. Annette Enright)**

Decomposition code 3. Moderate decomposition



**Photo 3. A male common dolphin in moderate condition from Ballinacourty, Co. Galway (Photo. Stephanie Levesque)**

Decomposition code 4. Advanced decomposition



**Photo 4. A female common dolphin found in Castletownbere, Co. Cork (Photo IWDG/RVL)**

**Figure 1. Examples of the four categories (extremely fresh, slight decomposition, moderate decomposition, advanced decomposition) used to determine whether a stranded cetacean was suitable for necropsy.**

### *Post-mortem protocol*

Each animal was assigned an IWDG Stranding Code Reference Number in addition to a Regional Veterinary Laboratory Post-mortem Number for tracking purposes. Necropsies were undertaken in accordance with the CSIP's *Guidelines for the Post-mortem Examination and Tissue Sampling of Cetaceans during Stranding Events* (Appendix II) and templates of the CSIP data collection sheets (Appendix III) and cetacean post-mortem report (Appendix IV) were utilised within the current project. Samples were collected as per the agreed sampling protocol outlined by the NPWS and the MI (Appendix V).

The tender team attended a two-day necropsy workshop hosted by CSIP at the Institute of Zoology (IoZ) in London in June 2017, which provided the team with expert training and technical guidance. The IoZ team made a number of presentations describing their experiences in cetacean recovery and necropsy, offering valuable knowledge on their findings and advice such as which techniques and equipment to employ when recovering an animal and carrying out a post-mortem examination. The workshop continued in the post-mortem lab where CSIP scientists led the tender team in the necropsy of a common dolphin. Methods of recording, photographing, assessing organs/overall animal health, and cause of death were covered.

Afterward, the tender team had the opportunity to lead the examinations of several cetaceans in order to attempt to determine cause of death with guidance from the CSIP scientists. Suspected causes of death included ship strike, bycatch, and seal attack.

Necropsies for this contract were carried out by a trained veterinarian from the RVL in Cork, with the assistance of biologists from the IWDG and GMIT. Detailed case history reports for each animal documenting the animal's initial gross examination, as well as the results of bacteriology and histopathology assessments (if available) and any other significant findings, were prepared. The IoZ was contracted to review the individual Case History Reports to provide guidance on standardised reporting with external schemes and to validate cause of death. Biological samples were collected, labelled and stored for future studies. Samples for bacteriology and general histopathology assessments were processed by the RVL through their existing lab facilities at the Cork RVL and in Back Weston, Co. Kildare. All samples requiring long-term storage at -20°C, including those for virology, were transported in a portable refrigerator to the IWDG office in Kilrush, Co. Clare and stored at facilities on site. Formalin fixed tissues, such as reproductive organs and adrenal glands, were stored at the RVL in Cork. A database was created detailing all samples collected, their storage requirement and location.

#### *Case history reporting*

For each completed necropsy on an individual animal, a comprehensive digital Case History was produced in accordance with the post-mortem examination reporting protocol. The individual Case History file included a presentation of factual evidence as observed and documented during the post-mortem examination, as well as photographic evidence and charts of external lesions. The full detailed Case History Report was completed by the Project Lead Scientist carrying out the necropsy, and reviewed by a second project Lead Scientist. Following internal sign off by the Principal Investigator, 2017 and 2018 Case History files were submitted electronically to a panel of veterinary experts led by the IoZ for independent validation of the necropsy results. Case History files were then submitted to the Project Steering Group upon completion.

#### **DATA COLLECTION FRAMEWORK**

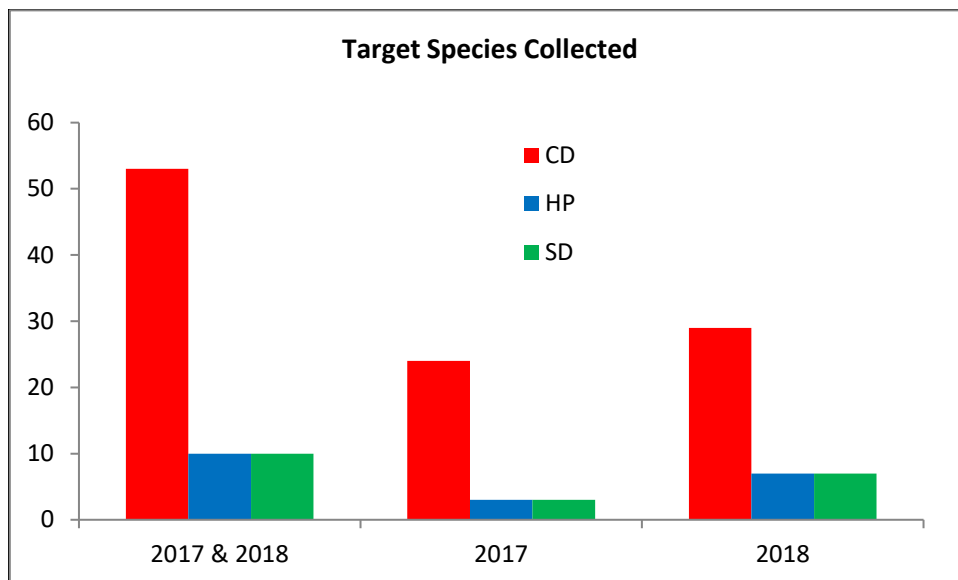
The contract also included the provision of bycatch sampling kits to the Irish Data Collection framework (DCF) programme, and the retrieval of samples collected at sea from DCF observers. Bycatch sampling kits were assembled and delivered to the DCF Observer Programme Co-ordinator at the MI for distribution to the at-sea observers when required. Kits included a bycatch sampling protocol leaflet (see Appendix VI). Contents of the bycatch sampling kits are presented in Appendix VII. If a bycatch incident was to occur and animals sampled, observers were to notify the DCF Programme Co-ordinator who would then liaise with the Necropsy Project Co-ordinator. Samples were then to be retrieved and stored at the IWDG office.

## Results

### NECROPSIES

#### *Cetacean Collection and Reporting*

A total of 73 animals were collected between 21 June 2017 and 31 December 2018 comprising 53 common dolphins, ten striped dolphins and ten harbour porpoises (Figure 2).



**Figure 2. Total number of target species collected between 21 June 2017 and December 2018. Four animals were collected before the start of the first tender during the months of March, May and early June 2017 – they are included in this chart.**

Overall, 56% (41/73) of animals were recovered from Lot 1 and 44% (32/73) from Lot 2. Lots 1 and 2 can be distinguished in Figure 3a. Out of the nine counties from which animals were collected, most (30%) were from county Kerry, followed by counties Clare (22%), Donegal and Galway (each with 14%), Cork (10%), Mayo (4%), Sligo and Wexford (3%) and Waterford (1%) (Figure 3a). Of the animals necropsied during this contract, the majority were common dolphins (72.6%, n=53) followed by harbour porpoises (13.6%, n=10) and striped dolphins (13.6%, n=10).

In order to explore the proportion of strandings reported to the IWDG and recovered for post-mortem we accessed all strandings data available from the IWDG. The three target species were recorded from 16 counties throughout the whole of Ireland during 2017 and 2018 (Figure 3b). Again, most strandings (23%), were reported from Co. Kerry.

Of those individuals collected for post-mortem whose sex was known, 46% (33/72) were female and 54% (39/72) were male. The sex of one common dolphin was unknown due to extensive scavenger damage.

Of the animals recovered 79% (58/73) were found dead, while 21% (15/73) were reported as live strandings. Four mass stranding events resulted in the collected of five animals, all involving common dolphins. A mass stranding is defined as “two or more cetaceans (excluding cow/calf pairs) stranding at the same time and place” (NOAA Fisheries).

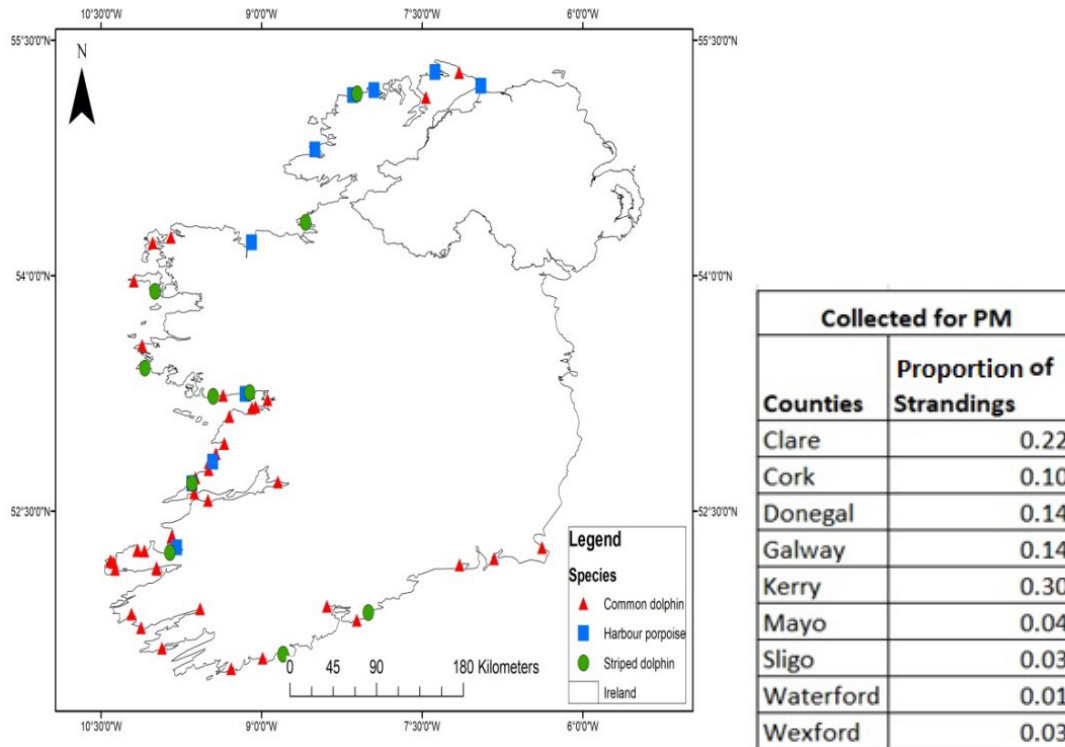


Figure 3. (a) Map of all animals collected for post-mortem examination from 21 June 2017 to 31 December 2018 accompanied by a table representing the percentage of strandings reported per county.

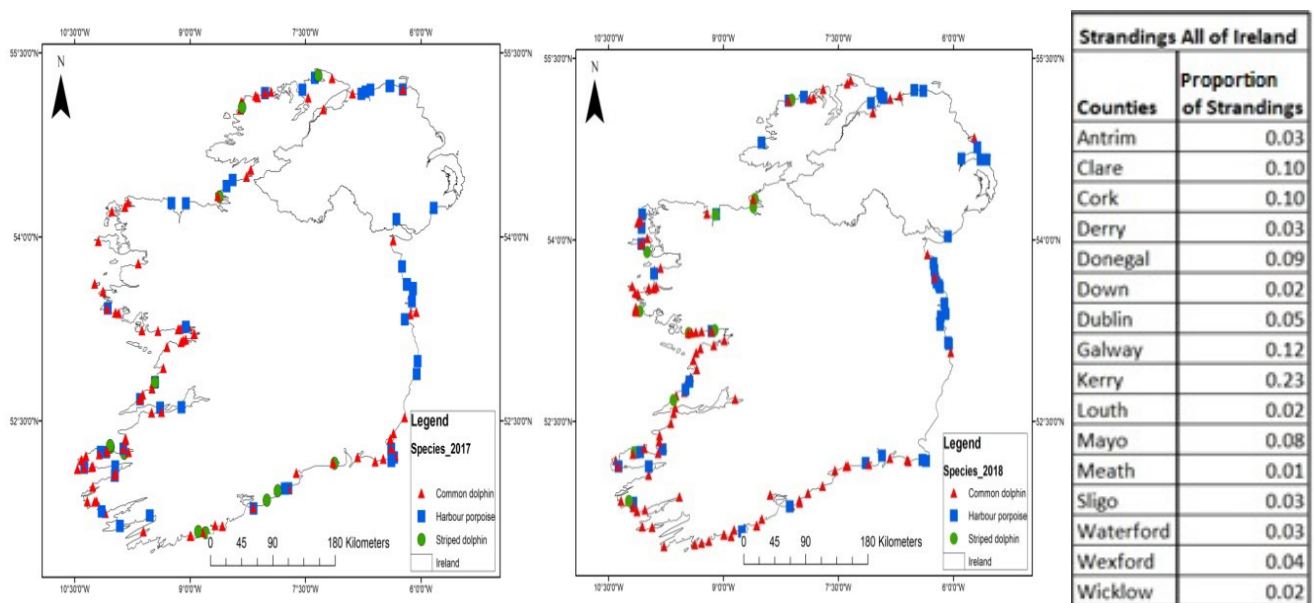


Figure 3. (b) Location of stranded animals within the whole of Ireland from 1 January to 31 December 2017 on the left, map representing location of stranded animals from 1 January to 31 December 2018 on the right, accompanied by a table representing percentage of strandings per county.

Of the single live strandings, nine were common dolphins, of which one was a mother and calf pair, and one was a striped dolphin. Details of animals recovered for post-mortem examination are presented in Table 1.

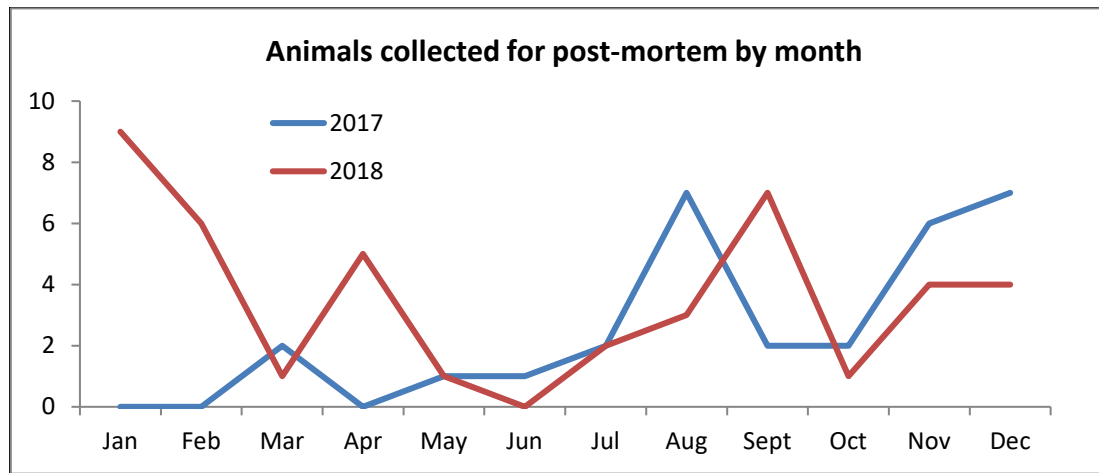
**Table 1. Details of animals recovered for post-mortem examination.**

<b>Lot</b>	<b>IWDG code</b>	<b>Species</b>	<b>Location</b>	<b>Stranding type when found</b>
1	IWDG 2017_067	CD	Flaggy Shore, Co. Clare	Single, Dead
1	IWDG 2017_112	CD	Silver Strand, Co. Galway	Single, Dead
1	IWDG 2017_121	CD	Doughmore, Co. Clare	Single, Live
1	IWDG 2017_128	HP	Quilty, Co. Clare	Single, Dead
2	IWDG 2017_145	SD	Donaghmore, Eastern Beach, Co. Cork	Single, Dead
2	IWDG 2017_146	SD	Derrymore Strand, Co. Kerry	Single, Dead
2	IWDG 2017_156	CD	Cloghane, Cappah Beach, Co. Kerry	Single, Live
1	IWDG 2017_158	CD	Bellmullet, Co. Mayo	Mass, Live (2 adults)
1	IWDG 2017_161	CD	Ballinacourty, Co. Galway	Single, Dead
2	IWDG 2017_162	CD	Cloghane, Cappah Beach, Co. Kerry	Single, Dead
2	IWDG 2017_163	CD	Ballylongford, Co. Kerry	Single, Live (2: mother/calf)
2	IWDG 2017_163a	CD	Ballylongford, Co. Kerry	Single, Live (2: mother/calf)
2	IWDG 2017_168	CD	Derrymore Strand, Co. Kerry	Single, Dead
1	IWDG 2017_182	CD	Culdaff Beach, Inishowen, Co. Donegal	Single, Dead
2	IWDG 2017_189	CD	Rosslare, Co. Wexford	Single, Live
1	IWDG 2017_191	HP	Kilkee, Co. Clare	Single, Dead
1	IWDG 2017_194	CD	Buncrana Beach, Inishowen, Co. Donegal	Single, Dead
2	IWDG 2017_198	CD	Ventry Beach, Co. Kerry	Single, Live
1	IWDG 2017_205	HP	Pollan Beach, Ballyliffin, Co. Donegal	Single, Dead
1	IWDG 2017_207	CD	Salthill, Co. Galway	Single, Dead
1	IWDG 2017_208	CD	Keem, Achill Island, Co. Mayo	Mass, Live (4 adults, 1 calf)
2	IWDG 2017_209	CD	Smerwick Harbour, Co. Kerry	Single, Dead
1	IWDG 2017_210	CD	Aughinish, Co. Clare	Mass, Live (2 adults)
2	IWDG 2017_215	CD	Reenroe, Ballinaskelligs, Co. Kerry	Single, Live
2	IWDG 2017_216	CD	Banna Beach, Co. Kerry	Single, Dead
2	IWDG 2017_217	CD	Smerwick Harbour, Co. Kerry	Single, Dead
1	IWDG 2017_224	CD	Kilkee, Co. Clare	Single, Dead
1	IWDG 2017_225	CD	Doughmore, Co. Clare	Single, Dead
1	IWDG 2017_226	CD	Killahoey, Co. Donegal	Single, Dead
2	IWDG 2017_230	SD	Garryvoe, Ballycotton Bay, Co. Cork	Single, Dead
2	IWDG 2017_233	CD	Smerwick Harbour, Co. Kerry	Single, Dead
2	IWDG 2018_005	CD	Tramore, Co. Waterford	Single, Dead
1	IWDG 2018_006	CD	Fanore, Co. Clare	Single, Dead
2	IWDG 2018_014	HP	Ballygarron, Tralee, Co. Kerry	Single, Dead
1	IWDG 2018_023	CD	Falcarragh, Co. Donegal	Single, Live
1	IWDG 2018_024	CD	Inverin, Co. Galway	Single, Dead
2	IWDG 2018_027	CD	Smerwick Harbour, Co. Kerry	Mass, Live (2)
2	IWDG 2018_027a	CD	Smerwick Harbour, Co. Kerry	Mass, Live (2)
1	IWDG 2018_029	CD	Cleggan Bay, Co. Galway	Single, Dead
2	IWDG 2018_030	CD	Inch, Dingle Bay, Co. Kerry	Single, Dead
2	IWDG 2018_039	CD	Cloghane, Cappah Beach, Co. Kerry	Single, Dead
1	IWDG 2018_042	CD	Saints Island, Shannon, Co. Clare	Single, Dead

1	IWDG 2018_043	CD	Farrihy Bay, Co. Clare	Single, Dead
2	IWDG 2018_053	CD	Derrynane Bay, Co. Kerry	Single, Dead
2	IWDG 2018_066	CD	Kenmare, Co. Kerry	Single, Dead
2	IWDG 2018_068	CD	Castletownbere, Co. Cork	Single, Dead
1	IWDG 2018_097	CD	Doughmore, Co. Clare	Single, Dead
1	IWDG 2018_108	HP	Rosbeg, Co. Donegal	Single, Dead
2	IWDG 2018_111	CD	Brandon Bay, Co. Kerry	Single, Dead
2	IWDG 2018_112	CD	TragumnaBay, Co. Cork	Single, Dead
1	IWDG 2018_116	HP	Greencastle, Co. Donegal	Single, Dead
1	IWDG 2018_122	HP	Freeport, Barna, Co. Galway	Single, Dead
1	IWDG 2018_131	SD	Rusheen Bay, Barna, Co. Galway	Single, Live
1	IWDG 2018_150	SD	Lisadell, Co. Sligo	Single, Dead
1	IWDG 2018_154	CD	Barna, Co. Galway	Single, Dead
1	IWDG 2018_161	SD	Bunowen, Co. Galway	Single, Dead
1	IWDG 2018_168	CD	Spanish Point, Co. Clare	Single, Dead
1	IWDG 2018_181	CD	Lahinch, Co. Clare	Single, Dead
1	IWDG 2018_194	HP	Enniscrone, Co. Sligo	Single, Dead
2	IWDG 2018_195	CD	Banna Strand, Co. Kerry	Single, Dead
2	IWDG 2018_199	CD	Cork City, Co. Cork	Single, Live
1	IWDG 2018_206	CD	Querrin, Co. Clare	Single, Dead
1	IWDG 2018_207	CD	Seafield, Co. Clare	Single, Dead
1	IWDG 2018_216	HP	Magheroarty Beach, Co. Donegal	Single, Dead
2	IWDG 2018_217	CD	Inch Beach, Co. Kerry	Single, Dead
1	IWDG 2018_221	SD	Falcaragh Beach, Co. Donegal	Single, Dead
1	IWDG 2018_229	SD	An TraMhor, Co. Galway	Single, Dead
2	IWDG 2018_232	CD	Fethard, Co. Wexford	Single, Dead
1	IWDG 2018_237	HP	Killahoey, Co. Donegal	Single, Dead
1	IWDG 2018_243	SD	Kilkee, Co. Clare	Single, Dead
2	IWDG 2018_244	CD	Ballycraheen Beach, Co. Cork	Single, Dead
2	IWDG 2018_247	CD	Owenahincha Beach, Co. Cork	Single, Dead
1	IWDG 2018_231	SD	Achill Island, Co. Mayo	Single, Dead

The combined sampling period covered June 2017 to December 2018. The month with the highest number of strandings in a single year was January 2018 (n=9) (Figure 4) which is consistent with the peak stranding period for common dolphins.

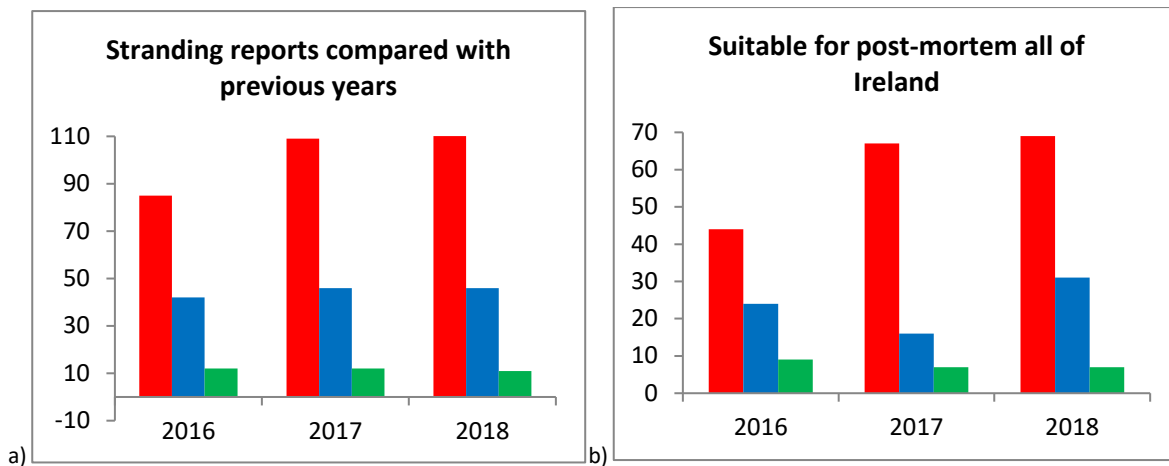
In order to determine whether stranding patterns during the tender periods were consistent with previous years, the IWDG Stranding Database was interrogated using data collected over the period from 2016 to 2018 for the relevant species (see Figures 5 and 6). Stranding numbers for common dolphins appear to be on the rise year on year (Figure 5a).



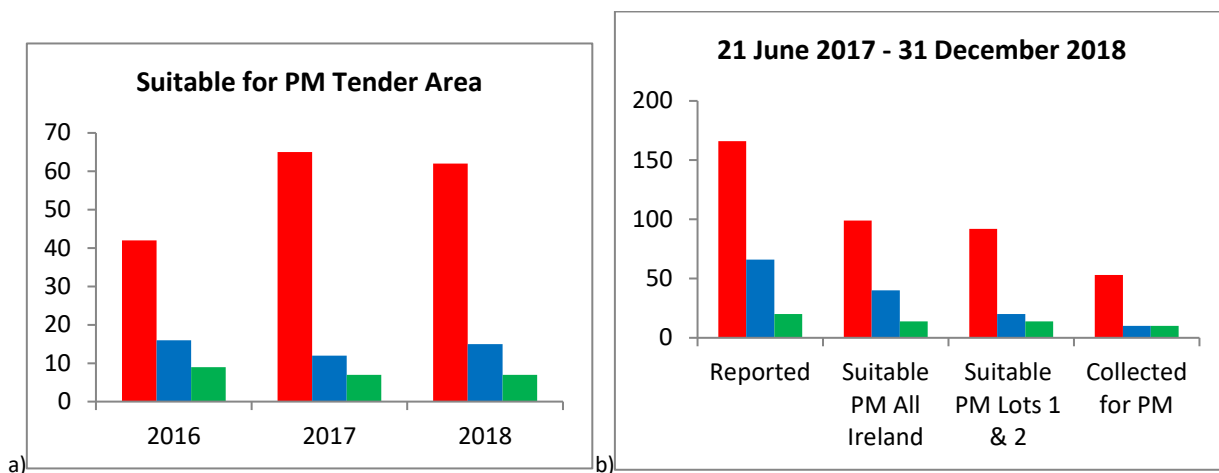
**Figure 4. Months during which animals were collected for necropsy between 21 June 2017 and 31 December 2018. Four animals were collected prior to June 2017 and were kept in frozen storage to be necropsied upon the start of the contract in June.**

The common dolphin was the most frequently reported species stranded on Irish coastlines during the sampling period in all three years, while striped dolphins were the least frequently reported of the three target species (Figure 5a). We also compared the suitability of stranded cetaceans for post-mortem over the three years by examining body condition from stranding record photos using the CSIP body condition categories. Using records from the whole of Ireland (Figure 5b), and those from Lots 1 and 2 only (Figure 6a), there was an overall increase in the number of common dolphins suitable for necropsy over the period 2016 to 2018, but a drop in numbers of harbour porpoises in 2017 compared to 2016 and 2018. Within the tender area, when compared to 2016 and 2018, there was a peak in common dolphin strandings suitable for post-mortem and a consistent decrease in harbour porpoise numbers during 2017.

We also compared the number of each species reported during the tender periods to the number of animals suitable for post-mortem from the whole of Ireland and the tender area, and the number of each species collected for post-mortem (Figure 6b).



**Figure 5. (a) Strandings reported for the three target species compared between 1 January and 31 December 2016, 2017 and 2018. (b) Total suitable for post-mortem examination in whole of Ireland between the dates of 1 January and 31 December 2016, 2017 and 2018. Common dolphin = red, harbour porpoise = blue, striped dolphin = green.**



**Figure 6. (a) Total suitable for post-mortem examination from Tender Lots 1 and 2 between January and December 2016, 2017 and 2018. (b) Comparisons for animals reported between June and December 2018. Common dolphin = red, harbour porpoise = blue, striped dolphin = green.**

Animals suitable for post-mortem but which were not collected was mainly due to animals being reported at a later date, being washed away, or due to severe deterioration of carcasses over a short period of time due to scavenging and extreme weather conditions experienced during the summer of 2018. All animals necropsied were within decomposition codes 1 to 4 and thus were suitable for inclusion within the contract. On average, animals were collected within a day of being reported and necropsied within five days from delivery to RVL Cork.



### *Post-Mortem Results*

Full necropsies were undertaken at RVL Cork. Although outside the requirements of the tender, routine bacteriological analysis of samples was undertaken at RVL Cork. If bacteria of significance were observed, the isolate was referred to the National Reference Laboratory in Back Weston for confirmation. General histopathological assessment of tissues was also undertaken by one of the lead scientists (JO'D).

A probable cause of death (COD) was described wherever possible based on collective findings from post-mortem and other diagnostic investigations undertaken. Criteria used to establish selected COD were based on those defined by the CSIP (2016) (see Appendix VIII). As per the first contract (Levesque *et al.* 2017), in the case of live strandings this COD was attributed to those animals known or suspected (from post-mortem examination) to have live-stranded in '*apparent good health and nutritional status and excluded severely diseased or emaciated animals that stranded alive*'. Where applicable, COD of starvation is attributed to animals that were '*severely emaciated and, following post-mortem examination, ascertained to have no other significant disease processes that could explain the poor nutritional status*'. Whereas bycatch was ascribed as a COD '*using established pathological criteria for by-catch diagnosis*' (Kuiken *et al.* 1994; Kuiken 1996).

### *Case History Reporting*

Case History reports for all 73 animals from the first contract have been reviewed by the IoZ to provide independent oversight on each case, and submitted to the Project Steering Group. Results from the two contracts can be seen below in Table 2.

**Table 2. Summary of Cause of Death of necropsied cetaceans.**

IWDG code	Species	Sex	Length	Tentative age/maturity Category	Preliminary COD categories	Significant disease or conditions	Incidental diseases or conditions	Validated COD	Finalised COD categories
IWDG 2017_067	CD	Male	177	Juvenile	Infectious disease	<i>Brucella ceti</i> infection Heavy gastric parasitism	Chronic granulomatous bronchointerstitial pneumonia with intralesional nematode profiles	Yes	Infectious disease
IWDG 2017_112	CD	Male	147	Juvenile	Not established	Moderate-to-poor nutritional state	Mild gastric parasitism Light pulmonary parasitism Multifocal lesions in blubber	Yes	Starvation/hypothermia (pending histology)
IWDG 2017_121	CD	Male	162.5	Juvenile	Infectious disease	Live stranding & Euthanasia Non-suppurative meningitis	Pulmonary parasitism Gastric parasitism 'Pox-like' epidermal lesions	Yes	Infectious disease
IWDG 2017_128	HP	Female	102.5	Juvenile	Not established	NA	Acute pulmonary oedema chronic parasitic pneumonia	Yes	Not established
IWDG 2017_145	SD	Male	198	sub-adult	Starvation	Suspected live stranding	NA	Yes	Starvation/hypothermia (pending histology)
IWDG 2017_146	SD	Female	184	sub-adult	Not established	Lung abnormality	NA	Yes Possible pneumonia or bronchopneumonia (pending histopathology)	Infectious disease (pending histopathology)

IWDG code	Species	Sex	Length	Tentative age/maturity Category	Preliminary COD categories	Significant disease or conditions	Incidental diseases or conditions	Validated COD	Finalised COD categories
IWDG 2017_156	CD	Male	210	Adult	Starvation	Live stranding	Very light pulmonary and gastric parasitism. Three small foci of suppurative pneumonia. Focal pyonecrotic hepatitis	Yes	Starvation/hypothermia
IWDG 2017_158	CD	Male	230	Adult	Live stranding	Moderate-to-poor nutritional condition	Gastric and pulmonary parasitism.	Yes Starvation/hypothermia dolphin live stranded and died <i>in extremis</i> (as a terminal event)	Starvation/hypothermia
IWDG 2017_161	CD	Male	211	sub-adult/adult	Other?	Suspected intussusception in intestine Suspect lesions that may be attributed to bycatch Multifocal gastric ulceration & haemorrhage in the cardiac stomach	NA	Yes	Not established
IWDG 2017_162	CD	Female	171.5	Juvenile	Infectious disease	<i>Brucella ceti</i> meningitis (pending full confirmation on)	Gastric parasitism & ulceration	Yes	Infectious disease

IWDG code	Species	Sex	Length	Tentative age/maturity Category	Preliminary COD categories	Significant disease or conditions	Incidental diseases or conditions	Validated COD	Finalised COD categories
IWDG 2017_163	CD	Female	200	Adult	Live stranding or infectious disease	Live stranding Poor body condition associated with gastric parasitism and ulceration	Mild pulmonary parasitism	Yes Ulcerative and verminous gastritis, moderate-heavy	Infectious disease
IWDG 2017_163a	CD	Female	104	Calf	Live stranding	Unweaned calf	NA	Yes	Live stranding (with lactating mother)
IWDG 2017_168	CD	Female	205	Adult	Infectious disease	Very poor body condition associated with a. heavy gastric parasitism with gastric ulceration; b. moderate pulmonary parasitism c. very thin blubber layer, increasing susceptibility of hypothermia	<i>Phyllobothrium</i> sp. parasitism of the blubber	Yes Very severe gastric parasitism with associated ulceration	Infectious disease
IWDG 2017_182	CD	Female	202	Sub-adult/Adult	Not established	Not determined	Pulmonary parasitism/pneumonia. Enlarged adrenal glands and spleen (with capsular haemorrhage) dental loss	Yes	Not established

IWDG code	Species	Sex	Length	Tentative age/maturity Category	Preliminary CODcategories	Significant disease or conditions	Incidental diseases or conditions	Validated COD	Finalised COD categories
IWDG 2017_189	CD	Female	117.5	Calf	Starvation	Live stranding Calf	NA	Yes	Starvation/hypothermia (neonate)
IWDG 2017_191	HP	Male	100	Juvenile	Infectious disease	Erysipelas	NA	Yes Generalised bacterial infection ( <i>Erysipelothrixrhusiopathiae</i> )	Infectious disease
IWDG 2017_194	CD	Male	122	Calf	Starvation?	Moderate to poor body condition Abscess on tail stock	NA	Yes Abscess	Infectious disease

IWDG code	Species	Sex	Length	Tentative age/maturity Category	Preliminary COD categories	Significant disease or conditions	Incidental diseases or conditions	Validated COD	Finalised COD categories
IWDG 2017_198	CD	Male	226	Adult	NA	Live stranding Very poor body condition Severe pediculosis (ulcerative dermatitis) Arthritis/DJD of the atlantooccipital joint Heavy gastric parasitism and ulceration	Light pulmonary parasitism	Yes Ulcerative dermatitis and heavy gastric parasitism with associated ulceration	Infectious disease
IWDG 2017_205	HP	Male	149	Adult	Other	Suspected testicular infraction Suspect "atypical Salmonella" isolate Moderate-to-poor nutritional condition	Pulmonary and gastric parasitism Missing teeth	Yes Testicular enlargement	Gas embolism and infectious disease
IWDG 2017_207	CD	Male	215	sub-adult/adult	Suspected bycatch	NA	Moderate-to-poor nutritional condition 'Pox-like' epidermal lesions	Yes	Bycatch
IWDG 2017_208	CD	Female	182	sub-adult	Live stranding	Mass live stranding event	NA	Yes	Live stranding

IWDG code	Species	Sex	Length	Tentative age/maturity Category	Preliminary COD categories	Significant disease or conditions	Incidental diseases or conditions	Validated COD	Finalised COD categories
IWDG 2017_209	CD	Male	215	adult	NA	Hepatophy	Gastric & pulmonary parasitism Wear/loss of teeth	Yes Subacute-chronic hepatic gas embolism/ chronic form of cetacean decompression sickness	Gas embolism
IWDG 2017_210	CD	UNK	212	sub-adult/adult	Live stranding	Live stranding	Gastric parasitism	Yes	Live stranding
IWDG 2017_215	CD	Male	175	juvenile	NA	Live stranding Pulmonary hypostatic congestion and oedema	Gastrooesophageal parasitism - moderate. Pulmonary parasitism – mild	Yes Gastric impaction	Other

IWDG code	Species	Sex	Length (cm)	Tentative age/maturity category	Preliminary COD categories	Significant disease or conditions	Incidental diseases or conditions	Validated COD	Finalised COD categories
IWDG 2017_216	CD	M	161	Juvenile	Infectious disease	Brucella ceti isolated from multiple organs Emaciation Verminous bronchitis and pneumonia Verminous gastritis and ulceration		Infectious disease	Infectious disease
IWDG 2017_217	CD	M	228	Adult	Infectious Disease	Extensive verminous gastritis with gastric ulceration Emaciation	<i>Streptococcus equi</i> subsp. <i>equi</i> isolated from organs, significant unknown Verminous bronchitis and pneumonia Missing and/or broken dentition	Infectious disease	Infectious disease
IWDG 2017_224	CD	F	152	Juvenile	Other	Gastric impaction in cardiac stomach Emaciation Verminous gastritis	Verminous pneumonia and bronchitis (mild to moderate)	Other (Gastric Impaction)	Other (Gastric impaction)
IWDG 2017_225	CD	F	147	Juvenile	Starvation	Emaciation/hypothermia Verminous gastritis with ulceration		Starvation/hypothermia (pending histology)	Starvation/hypothermia (pending histology)
IWDG 2017_230	SD	F	163	Juvenile	Starvation	Suspected live stranded Emaciation	Mild verminous gastritis Mild chronic verminous pneumonia	Not established (Suspected live stranding)	Not established (Suspected live stranding)



IWDG code	Species	Sex	Length (cm)	Tentative age/maturity category	Preliminary COD categories	Significant disease or conditions	Incidental diseases or conditions	Validated COD	Finalised COD categories
IWDG 2017_233	CD	F	205	Adult	Infectious disease	Cellulitis lesion – right mandible Heavy Anisakis sp. burden (verminous gastritis)	Macerated foetal skeletal remnant in the uterus. Minor haemorrhaging around head and thorax	Infectious disease (suspected live stranded)	Infectious disease
IWDG 2018_005	CD	F	203	Adult	Starvation/hypothermia	Emaciation	Vaginal calculus Verminous gastritis and ulceration Verminous pneumonia and bronchitis	Starvation/hypothermia	Starvation/hypothermia
IWDG 2018_006	CD	M	171	Juvenile	Infectious disease (Suspected bycatch)	Emaciation Verminous gastritis Verminous bronchitis and pneumonia Extensive haemorrhaging around head and thorax Clean, straight cuts to tail flukes	Rostrum fractured – query caused by post mortem storm damage to carcass or bycatch	Infectious disease (Verminous gastritis)	Infectious disease (Verminous gastritis)

IWDG code	Species	Sex	Length (cm)	Tentative age/maturity category	Preliminary COD categories	Significant disease or conditions	Incidental diseases or conditions	Validated COD	Finalised COD categories
IWDG 2017_226	CD	M	222	Adult	Infectious disease	Severe arthrodesis of the atlanto-occipital and atlantoaxial joints (associated with suspected Brucella sp. infection of these joints, kidney and liver).  Starvation  Gastric ulceration and verminous gastritis	Verminous bronchitis	Infectious disease	Infectious disease
IWDG 2018_014	HP	M	162	Adult	Infectious disease	Verminous pneumonia	Parasitic gastritis and gastric ulceration. Dental loss – only one tooth present Parasitic hepatitis – trematode burden. Well circumscribed tumour in the liver	Not established (missing photos for confirmation)	Infectious disease
IWDG 2018_023	CD	M	201	Adult	Live stranding	Live stranded	Proctitis and constipation  Very minor burden of parasites in the lungs, cardiac stomach, blubber and abdominal musculature	Live stranding	Live stranding
IWDG 2018_024	CD	F	194.5	Adult	Suspected bycatch	Sudden death, possible by-catch or oesophageal impaction following feeding	Severe ulcerative verminous gastritis Mild verminous pneumonia Heavy Monorygma sp. Burden	Not Established	Not Established

IWDG code	Species	Sex	Length (cm)	Tentative age/maturity category	Preliminary COD categories	Significant disease or conditions	Incidental diseases or conditions	Validated COD	Finalised COD categories
IWDG 2018_027	CD	F	199	Adult	Infectious disease	Hepatitis with abscessation and emphysema – due to, tentatively, <i>Brucella sp.</i> infection. Confirmation awaited from reference laboratory  Live stranded  Emaciated	Chronic-active pericarditis associated with <i>Enterococcus avium</i> infection Moderate verminous gastritis and ulceration	Possible infectious disease pending further assessment	Infectious disease (suspect Brucella)
IWDG 2018_027 a	CD	F	224	Adult	Live stranding	Live stranded	Verminous gastritis with ulceration  Dental loss	Live stranding	Live stranding
IWDG 2018_029	CD	M	230	Adult	Infectious disease	Emaciation/hypothermia Severe verminous gastritis	None	Infectious disease (Verminous ulcerative gastritis)	Infectious disease (Verminous ulcerative gastritis)
IWDG 2018_030	CD	F	166.5	Juvenile	Infectious disease	Emaciation Severe verminous gastritis	Verminous bronchitis and pneumonia	Infectious disease (Verminous gastritis)	Infectious disease (Verminous gastritis)
IWDG 2018_039	CD	M	205	Adult	Possible live stranding	Possible live stranding Hypostatic congestion of lungs	Verminous gastritis Multifocal pulmonary granulomas	Not available	Not established (Suspected live stranding)

IWDG code	Species	Sex	Length (cm)	Tentative age/maturity category	Preliminary COD categories	Significant disease or conditions	Incidental diseases or conditions	Validated COD	Finalised COD categories
IWDG 2018_042	CD	M	205	Adult	Not Established	None	None	Not available	Not established
IWDG 2018_043	CD	M	211	Adult	Not Established	Not Established	Mild verminous gastritis of cardiac stomach with mucosal ulceration	Not Established	Not Established
IWDG 2018_053	CD	F	169	Juvenile	Starvation/hypothermia	Starvation/hypothermia	Gastric ulcer (cardiac stomach) Mild verminous bronchitis	Starvation/hypothermia	Starvation/hypothermia
IWDG 2018_066	CD	M	207	Sub-adult/Adult	Infectious disease (possible live stranding)	Severe verminous ulcerative gastritis Hepatomegaly – type of enlargement to be determined by histopathology. Possibly live stranded - marked pulmonary congestion and oedema of the right lung	None	Infectious disease (Verminous ulcerative gastritis)	Infectious disease (Verminous ulcerative gastritis)
IWDG 2018_068	CD	F	163	Juvenile	Infectious disease	Verminous ulcerative gastritis Verminous bronchitis and pneumonia (moderately severe)	Emaciation/hypothermia	Not established (missing photos for confirmation)	Infectious disease

IWDG code	Species	Sex	Length (cm)	Tentative age/maturity category	Preliminary COD categories	Significant disease or conditions	Incidental diseases or conditions	Validated COD	Finalised COD categories
IWDG 2018_097	CD	M	211	Adult	Not Established	None	None	Not available	Not Established
IWDG 2018_108	HP	M	163	Adult	Not Established Suspected infectious disease	Not established - Verminous bronchitis and pneumonia may have been a contributing factor	Verminous gastritis	Not Established	Not established – Suspected infectious disease
IWDG 2018_111	CD	M	175	Sub-adult	Infectious disease	Severe, diffuse verminous bronchitis and pneumonia	Verminous gastritis	Infectious disease Possible live stranding	Infectious disease
IWDG 2018_112	CD	F	156	Sub-adult	Other - Gastric impaction	Poor body condition associated with gastric impaction.	Verminous bronchitis and pneumonitis Verminous gastritis.	Other – Gastric impaction	Other – Gastric impaction
IWDG 2018_116	HP	F	179	Adult	Infectious disease	Ill thrift associated with severe trematodal gastritis Verminous pneumonia with abscessation	Mild chronic liver fluke infection	Infectious disease	Infectious disease
IWDG 2018_122	HP	F	107	Juvenile	Infectious disease	Verminous gastritis –severe. Verminous bronchitis – heavy burden in trachea. Poor body condition	None	Infectious disease	Infectious disease

IWDG code	Species	Sex	Length (cm)	Tentative age/maturity category	Preliminary COD categories	Significant disease or conditions	Incidental diseases or conditions	Validated COD	Finalised COD categories
IWDG 2018_131	SD	F	185	Juvenile	Live stranding	Live stranding Poor body condition Emphysema of perirenal connective tissue/renal capsule	Verminous ulcerative gastritis Trematodal gastritis	Live stranding	Live stranding
IWDG 2018_150	SD	F	215	Adult	Not established	None	Verminous gastritis. Pregnancy Fair body condition	Not established Possible dystocia	Not established
IWDG 2018_154	CD	F	205	Adult	Bycatch	Impression marks around head, haematoma over thorax Good body condition with evidence of recent feeding.	Gastric ulceration with scarring	Bycatch	Bycatch
IWDG 2018_161	SD	M	160	Juvenile	Not established Possible bycatch	None	Verminous gastritis with ulceration	Possible bycatch	Possible bycatch
IWDG 2018_168	CD	F	190	Adult	Bycatch	Fluke amputation	None	Bycatch	Bycatch

IWDG code	Species	Sex	Length (cm)	Tentative age/maturity category	Preliminary COD categories	Significant disease or conditions	Incidental diseases or conditions	Validated COD	Finalised COD categories
IWDG 2018_181	CD	F	159	Juvenile	Infectious disease	Septic pleurisy and pneumonia Verminous bronchopneumonitis Poor body condition	Verminous gastritis Multifocal ulcerative dermatitis	Infectious disease	Infectious disease
IWDG 2018_194	HP	M	131	Adult	Infectious disease	Very poor body condition Trematodal gastritis focally extensive Verminous bronchitis and pneumonia.	None	Infectious disease	Infectious disease
IWDG 2018_195	CD	M	214	Adult	Gas embolism	Emphysematous change in the liver and other tissues. Very poor body condition (parasitism will have contributed to this, particularly verminous gastritis)	Verminous gastritis. Verminous pneumonia.	Possible gas embolism	Gas embolism

IWDG code	Species	Sex	Length (cm)	Tentative age/maturity category	Preliminary COD categories	Significant disease or conditions	Incidental diseases or conditions	Validated COD	Finalised COD categories
IWDG 2018_199	CD	F	213	Adult	Infectious disease	Extremely thin Severe verminous gastritis Chronic verminous pneumonia Palatine ulceration	Cystic anomaly of left kidney	Infectious disease	Infectious disease
IWDG 2018_206	CD	F	204	Adult	Physical trauma (boat/ship strike) and Possible bycatch	Severe trauma to skull resulting in comminuted fractures of calvarium and occipital condyles & intracranial haematoma formation Amputation of tip of tail fluke appears to have been done by a sharp tool	Gastric ulceration. Verminous bronchopneumonitis	Physical trauma (unknown origin)	Physical trauma (boat/ship strike) and Possible bycatch
IWDG 2018_207	CD	M	227	Adult	Infectious disease	Peritonitis and perihepatitis secondary to perforated ulcer in fundic stomach Ulcer associated with attached parasites Very poor body condition	Verminous gastritis of cardiac stomach & multifocal ulceration. Mild verminous bronchitis/pneumonia Moderate degenerative joint disease of atlantooccipital joint	Infectious disease Other (degenerative joint disease)	Infectious disease



IWDG code	Species	Sex	Length (cm)	Tentative age/maturity category	Preliminary COD categories	Significant disease or conditions	Incidental diseases or conditions	Validated COD	Finalised COD categories
IWDG 2018_216	HP	F	152.5	Adult	Infectious disease	Bronchopneumonia (with consolidated lung tissue) Very poor nutritional state	Verminous bronchopneumonitis Bile duct fibrosis	Infectious disease	Infectious disease
IWDG 2018_217	CD	M	214	Adult	Not established	Trauma – fractured rostrum; Possibly ante-mortem	Mild verminous gastritis	Not established	Not established
IWDG 2018_221	SD	M	193	Juvenile	Not established	Very poor nutritional condition No evidence of recent feeding	Mild verminous bronchopneumonitis Light <i>Monorygma sp.</i> and <i>Phyllobothrium sp.</i> burdens.	Not established	Not established
IWDG 2018_229	SD	M	161	Juvenile	Physical Trauma (possible bycatch)	Suspect beak fracture was antemortem	Severe osteoarthritis of atlantooccipital joint with fusion and restricted motion of joint Moderate gastric parasitism Mild verminous bronchopneumonitis.	Physical trauma (possible boat strike)	Physical trauma (possible bycatch)

IWDG code	Species	Sex	Length (cm)	Tentative age/maturity category	Preliminary COD categories	Significant disease or conditions	Incidental diseases or conditions	Validated COD	Finalised COD categories
IWDG 2018_231	SD	M	185	Juvenile	Bycatch	Suspect beak fracture was antemortem	Thin nutritional condition Mild pulmonary nematode parasite burden Mild gastric nematode and trematode parasite burdens	Bycatch	Bycatch
IWDG 2018_232	CD	M	215	Adult	Bycatch	Found entangled in net	Catarrhal bronchitis, verminous bronchitis/pneumonia Resolved peritonitis	Bycatch	Bycatch
IWDG 2018_237	HP	M	119	Juvenile	Bycatch	Impression marks and lacerations on head and tail fluke	None	Bycatch	Bycatch
IWDG 2018_243	SD	F	177	Sub-adult	Bycatch	Trauma - spinal and skull fractures	Very mild verminous pneumonia and gastritis	Bycatch	Bycatch
IWDG 2018_244	CD	F	193	Adult	Infectious disease	Severe verminous gastritis Chronic verminous pneumonia Poor body condition	<i>Monorygmaspp.</i> and <i>Phyllobothriumsp</i> infections. Pregnancy	Infectious disease	Infectious disease

IWDG code	Species	Sex	Length (cm)	Tentative age/maturity category	Preliminary COD categories	Significant disease or conditions	Incidental diseases or conditions	Validated COD	Finalised COD categories
IWDG 2018_247	CD	M	218	Adult	Not established	None	Verminous bronchitis & pneumonia (moderately severe)	Not established Possible infectious disease	Not established

### Common dolphin

Of the 53 common dolphins collected for necropsy, the sex of one animal could not be determined due to extensive scavenger damage. For the remaining 52 animals, 46% (24/52) were female and 54% (28/52) male. Lengths for females and males ranged from 103 to 224 cm and 122 to 230 cm, respectively.

Common dolphins were collected from four separate mass strandings events. Three of these events involved two animals. IWDG 2017-158 and IWDG 2017-210 were each collected from two separate stranding events, while IWDG 2018-027 and IWDG 2018-027 who live-stranded together and were both collected for post-mortem. The next event involved four adults, of which one was collected for post-mortem (IWDG 2017-208).

One individual swam into the River Lee in Cork City and was found floating in the river the following day (IWDG 2018-199). There were nine other cases of single live strandings collected for post-mortem.

The most common cause of death for common dolphins was found to be **infectious disease** representing 42% of the sample. This was followed by **not established** (15%), **starvation/hypothermia** (11%), and **bycatch** (7%). An adult male in county Wexford was found entangled in fishing gear (IWDG 2018-232) (Photo. 1). There were two cases of **gas embolism**, and three cases of **gastric impaction**. All remaining cause of death categories can be found in Table 3 below.



**Photo 1. Adult male common dolphin entangled in fishing gear in Co. Wexford. Photo. Dierdre Slevin.**

### Striped dolphin

Five male and five female striped dolphins were collected for necropsy. One female live-stranded in Rusheen Bay, Barna, Co. Galway (IWDG 2018-131). Another female was pregnant and found dead in Lisadell, Co. Sligo (IWDG 2018-150). Male and female lengths ranged from 160 to 198 cm and 163 to 215 cm, respectively.

The two most common cause of death categories for striped dolphins were **bycatch** and **not established**, both representing 20% of the sample. All remaining cause of death categories can be found in Table 3 below.

### Harbour porpoise

Six male and four female harbour porpoises were collected for necropsy. Male and female lengths ranged from 100 to 190 cm and 102.5 to 169 cm, respectively. The most common cause of death among harbour porpoises was infectious disease, representing 60% of the sample. There was one case of confirmed **bycatch**, and one case of **gas embolism**. All remaining cause of death categories can be found in Table 3 below.

**Table 3. Cause of death categories for all necropsied animals.**

COD Categories	Species			Total
	CD	SD	HP	
Bycatch	4	2	1	7
Physical Trauma (boat/ship strike) and Possible bycatch	1	0	0	1
Physical Trauma (possible bycatch)	0	1	0	1
Possible bycatch	0	1	0	1
Gas embolism	2	0	0	2
Infectious disease	22	1	6	29
Live stranding	4	1	0	5
Live stranding (with lactating mother)	1	0	0	1
Starvation/hypothermia	6	1	0	7
Starvation/hypothermia (neonate)	1	0	0	1
Gas embolism & Infectious disease	0	0	1	1
Other (Gastric impaction)	3	0	0	3
Not established	8	2	1	11
Not established - suspected live stranding	1	1	0	2
Not established - suspected infectious disease	0	0	1	1
<b>Total</b>	<b>53</b>	<b>10</b>	<b>10</b>	<b>73</b>

### DATA COLLECTION FRAMEWORK

Between 24 July and 14 December 2017 two animals were sampled at sea by DCF observers; both adult male grey seals (total body lengths of 140 cm and 110 cm) incidentally captured in tangle nets (Table 4).

**Table 4. Samples recovered from DCF observers**

Date	Species	Sex	Total Body Length/ Standard Body Length	Samples	Type of net	Lat/Long
24/07/2017	Grey seal	Male	140cm/130cm	2 biopsies (skin and blubber)	Tangle net	52.1615, -10.4562
14/12/2017	Grey seal	Male	110cm/105cm	2 biopsies (skin and blubber)	Tangle net	52.2385, -10.5803

## Discussion

Seventy-three stranded dolphins and porpoise were recovered and necropsied under two contracts during 2017 and 2018. The majority of the animals collected for necropsy were recovered from County Kerry most likely due to the high number of strandings reported to the IWDG Cetacean Strandings network from this county.

**Common dolphins** represented 73% of the animals recovered. Prior to 2011, numbers of common dolphin strandings were similar to those of harbour porpoises, being either the first or second most frequently reported species each year (McGovern *et al.* 2016). During the last seven years, however, recorded strandings for common dolphins have increased out of proportion with other species. Between 2006 and 2010 the IWDG received 134 records of common dolphins; an average of 27 animals per year. However, during the years 2013 to 2018, 503 common dolphin strandings were recorded. One-hundred and eighteen were reported from 2018 alone representing a large increase on previous years (O'Connell and Berrow 2019). The reason for this remains unclear, although interactions with pelagic trawl fisheries have been identified (Anon 2013). Although this could in part be due to increased observer effort over the years, if this were the only explanation, we would expect a similar increase to be reported for other dolphin species. Common dolphin strandings occur mainly on the west and south coasts and peak in the winter months of January to March and December (McGovern *et al.* 2016).

**Harbour porpoise** are consistently the second most frequently stranded cetacean species in Ireland, having only recently been surpassed by the common dolphins. They have been recorded stranded on all coasts, although higher rates along the south and east coasts with peaks from December to March, (McGovern *et al.* 2016); the latter region was outside the scope of the current study. Stranding records have been consistent with around 30 reported per year in Ireland (O'Connell and Berrow 2018; 2019).

**Striped dolphins** are less frequently stranded relative to other cetacean species, accounting for around 5% of all strandings in a typical year (McGovern *et al.* 2016). In the ten years up to and including 2018, 121 striped dolphin stranding records were received; an annual average of slightly more than 12 animals. This varied from a low of eight records in 2012 to a peak of 18 in 2014. Small numbers of strandings were recorded throughout the year, mainly from the south and west coasts (McGovern *et al.* 2016).

The proportion of each species recovered for post-mortem was therefore consistent with the relative number of individuals stranded during the study period.

Bacteriological and histopathological analyses undertaken by the RVL are ongoing and case histories will be updated with results from these assessments when available. Samples collected during the necropsies were stored at the IWDG office in Kilrush, Co. Clare and the RVL in Cork during the contract and then transferred to the MI with their associated databases where they may later be used to facilitate a variety of future investigations into marine mammal ecology.

This scheme has demonstrated that it is possible to recover a sample of stranded dolphins and porpoises and transport to a regional veterinary lab in a timely manner for post-mortem examination. In addition, it has demonstrated an effective collaboration between a state agency, third level institute and a non-government organisation. This can support a continuation of necropsies of stranded

cetaceans to provide a greater sample size, especially of species other than common dolphin, and provide robust data with which to inform management. Consideration should be given to extend this programme to include **bottlenose dolphins** (*Tursiops truncatus*), an Annex II species requiring special conservation measures, and other species which, although strand infrequently, would be of ecological interest (e.g. **Atlantic white-sided dolphin** (*Lagenorhynchus acutus*), **white-beaked dolphin** (*Lagenorhynchus albirostris*)). It would also be advisable to include the east coast in the sampling area as this is where many harbour porpoises tend to strand.

Further recommendations for future work would include the provision of additional resources in order to continue providing bacteriology and histopathology assessment services, as one of the most common causes of death reported here was **infectious disease**. For several cases, this was generously carried out by the RVL, and was instrumental in determining causes of death for those animals.

A delay with reporting arose due to constrained resources at the Regional Veterinary Laboratory in Cork, specifically available personnel. As the involvement of the RVL was voluntary and in addition to their ongoing obligations, this put significant pressure on one pathologist to carry out and report on all of the post-mortem examinations. If the post mortem scheme was to continue, IWDG recommends there be multiple pathologists formally dedicated to the scheme to ensure reports are returned in an appropriate timeframe, and that a contract be negotiated to provide these pathological services.

## Acknowledgements

The Marine Biodiversity Scheme is established under Union Priority 1 (Sustainable Fisheries) and Union Priority 6 (Integrated Maritime Policy) of Ireland's Operational Programme (OP) under the EMFF and is co-funded by the Irish Government and the EU. We would like to thank the Contracting Management and Steering Group, especially Drs. Leonie O'Dowd, Helen McCormick and Oliver Tully of the Marine Institute and Drs Oliver Ó Cadhla, Ferdia Marnell and David Tierney of the NPWS. We would like to thank Barry Keane and Sean O'Callaghan for providing indispensable assistance to the project coordinator in recovering animals, as well as Mark Reader, Graham Cooper, Don Cotton, Gary Kett, Nick Massett, Louise Overy, Tony Murray, Gareth Doherty, Patrick Molloy, Sorsha Kennedy, Brian O'Callaghan, Irene O'Brien and Frances Bermingham for assistance on the beach.

We would like to thank the IWDG stranding network members whose records made this contract possible, and the DCHG for funding the IWDG Stranding Scheme. Finally, we would like to thank the support of Michéal Casey and the RVL staff at RVL Cork for providing additional support during necropsy examinations.

## References

- Anonymous (2013) Results of post-mortem examinations on five common dolphins (*Delphinus delphis*) from Mayo, February 2013.
- De Quirós, B., Yara, González-Díaz, Ó., Saavedra, P., Arbelo, M., Sierra, E., Sacchini, S., Jepson, P., Mazzariol, S., Di Guardo, G., Fernández, A. (2011) Methodology for *in situ* gas sampling, transport and laboratory analysis of gases from stranded cetaceans. *Scientific Reports* 1 DOI: 10.1038/srep0019.
- CSIP (2016) Annual Report for the period 1st January – 31st December 2015. Defra and the Devolved Administrations contract MB0111 (2011-2016).
- Davison, N.J., Cranwell, M.P., Perrett, L.L., Dawson, C.E., Deaville, R., Stubberfield, E.J., Jarvis, D.S. and Jepson, P.D. (2009) Meningoencephalitis associated with *Brucella* species in a live-stranded striped dolphin (*Stenellacoeruleoalba*) in south-west England. *Veterinary Record* 165, 86-89.
- González, L., Patterson, I.A., Reid, R.J., Foster, G., Barberán, M., Blasco, J.M., Kennedy, S., Howie, F.E., Godfroid, J., MacMillan, A.P., Schock, A., Buxton, D. (2002) Chronic meningoencephalitis associated with *Brucella* sp. infection in live-stranded striped dolphins (*Stenellacoeruleoalba*). *Journal of Comparative Pathology* 126(2-3):147-52.
- Irish Whale and Dolphin Group. Accessed 2 Jan 2017. [www.iwdg.ie/conservation/?speciesed=2217](http://www.iwdg.ie/conservation/?speciesed=2217).
- Jepson, P.D., Arbelo, M., Deaville, R., Patterson, I.A.R., Castro, P., Baker, J.R., Degollada, E., Ross, H.M., Herráez, P., Pocknell, A.M., Rodriguez, E., Howie, F.E., Espinosa, A., Reid, R.J., Jaber, J.R., Martin, V., Cunningham, A.A., and Fernandez, A. (2003) Gas-bubble lesions in stranded cetaceans. *Nature* 425:575-576
- Jepson, P.D., Deaville, R., Patterson, I.A.R., Pocknell, Ross, H.M., Baker, J.R., Howie, F.E., Reid, R.J., Colloff, A. and Cunningham, A.A. (2005) Acute and chronic gas bubble lesions in cetaceans stranded in the United Kingdom. *Veterinary Pathology* 42: 291-305
- Kuiken, T. and Garcia Hartmann, M. (eds.) 1991. Proceedings of the first European Cetacean Society workshop on cetacean pathology: dissection techniques and tissue sampling. ECS newsletter 17, Special issue: 39pp
- Kuiken T, Simpson VR, Allchin CR, Bennet PM, Codd GA, Harris EA, Howes GJ, Kennedy S, Kirkwood JK, Law RJ, Merrett NR, Phillips S (1994) Mass mortality of common dolphins (*Delphinus delphis*) in south west England due to incidental capture in fishing gear. *Veterinary Record* 134:81-89
- Kuiken, T. (editor) (1996) Diagnosis of By-catch in cetaceans. Proceedings of the Second ECS Workshop on cetacean pathology, Montpellier, France, 2 March 1994.
- Levesque, S., O'Donovan, J., Daly, M., Murphy, S., O'Connell, M., Jepson, P., Deaville, R., Berrow, S. (2017) Supply of Vertebrate Necropsy and Sample Recovery Services. Report to the Marine Institute and the National Parks and Wildlife Service. ref: ITT17-005, ITT17-024.
- Marine Institute (2017) Invitation to Tender to the Supply of Vertebrate Necropsy and Sample Recovery services to the Marine Institute, Rinville, Oranmore, Co. Galway. Ref: ITT17-024

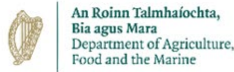

- Murphy, S. (2004) The biology and ecology of the common dolphin *Delphinus delphis* in the North-east Atlantic. PhD thesis, University College Cork, Ireland.
- Murphy, S., Pinn, E., and Jepson, P. (2013) The short-beaked common dolphin (*Delphinus delphis*) in the North-eastern Atlantic: distribution, ecology, management and conservation status. *Oceanography and Marine Biology: An Annual Review* 51: 193-280.
- McGovern, B., Culloch, R.M., O'Connell, M and Berrow S. (2016) Temporal and spatial trends in strandings records of cetaceans on the Irish coast, 2002-2014. *Journal of the Marine Biological Association of the United Kingdom*. DOI: <https://doi.org/10.1017/S0025315416001594>
- O'Connell, M. and Berrow, S. (2018) Records from the Irish Whale and Dolphin Group for 2016. *Irish Naturalists Journal* 36(1):75-81.
- O'Connell, M. and Berrow, S. (2019) Records from the Irish Whale and Dolphin Group for 2017. *Irish Naturalists Journal* 36(2):175-183.
- Westgate A.J., Read A.J. (2007) Reproduction in short-beaked common dolphins (*Delphinus delphis*) from the western North Atlantic. *Marine Biology* 150:1011-1024.

# Appendices

## Appendix I:

### IWDG Necropsy Case History Cover Page



# Case History Report

IWDG Stranding Code: \_\_\_\_\_

Species: \_\_\_\_\_

Date of Necropsy: \_\_\_\_\_

Pathologist(s): \_\_\_\_\_

**Case History** (Provide brief summary of where/how the animal was initially found and necropsy results):

**Cover photo:**

Approved by SB: \_\_\_\_\_ Date: \_\_\_\_\_

Approved by IoZ: \_\_\_\_\_ Date: \_\_\_\_\_

## Appendix II:

### CSIP Guidelines for the Postmortem Examination and Tissue Sampling of Cetaceans during Stranding Events

#### CONTENTS

- a) Introduction
- b) Basic measurements
- c) External examination
- d) Examination of abdominal organs (except G.I. tract, pancreas, and spleen)
- e) Examination of organs of head, neck and thorax
- f) Examination of the G.I. tract, pancreas and spleen

#### a) Introduction

These guidelines are meant primarily as an aid to veterinary surgeons carrying out post-mortem examinations on stranded cetaceans involved in the UK. Post-mortem examinations are carried out under the aegis of the UK Cetacean Strandings Investigation Programme, which is jointly funded by Defra and the Devolved Administrations. This protocol is based partly on guidelines written by Dr John Baker and Dr Thijs Kuiken and partly on the protocol produced at the European Cetacean Society workshop on cetacean pathology, held in Leiden, The Netherlands, in September 1991<sup>1</sup>.

All structures must be examined visually and by palpation, making incisions into the organs. A full post-mortem record must be kept, preferably on the standard "Cetacean Post-mortem Report" form for recording animals involved in a stranding.

Lesions in any organs should be described, photographed and sampled. The description should include the size, location, colour, texture, shape, and the nature of the transition from normal to abnormal tissue. Photographs should include a ruler, scale bar or similar object to indicate the size of the lesion. According to the suspected aetiology of the lesion, samples should be collected for bacteriological examination (especially if the lesion is of a purulent nature) or for virological examination. In all cases, a sample of the lesion should be preserved for histopathological examination.

The post-mortem examination need not take place in the order described below. However, samples for bacteriological and virological examination need to be taken as early as possible. Also, examination of the G.I. tract should be left until last to prevent cross-contamination with enteric micro-organisms.

Paul Jepson and Rob Deaville  
London, January 2010

---

<sup>1</sup>Kuiken, T. and Garcia Hartmann, M. (eds.) (1991) Proceedings of the first European Cetacean Society workshop on cetacean pathology: dissection techniques and tissue sampling. ECS newsletter 17, Special issue: 39pp

## b) Basic measurements

<b>photographs</b>	Photographs should be taken of the lateral views of the whole body, from both sides. Particularly in bottle-nosed dolphins, photographs should be taken of the dorsal fin, also from both sides. In baleen whales, the ventral side of the tail flukes should be photographed. Photographs should also be taken of any lesions of interest found during the post-mortem, including the use of a scalebar.
<b>body condition</b>	Estimate the body condition- that is the state of decomposition of the carcass, using the categories of the condition code <sup>2</sup> . Where possible, note the presence and extent of rigor mortis.
<b>body weight</b>	If recording the body weight is impossible, collect the heart weight so that the body weight can be estimated <sup>3</sup> .
<b>body length</b>	Measure the body length by placing the carcass on its belly, holding a measuring tape or ruler next to the carcass in a straight line parallel to the longitudinal body axis and measuring the distance between the notch in the tail flukes and the tip of the upper jaw.
<b>body girth</b>	Measure the body girth at the level of the anterior insertion of the dorsal fin. If it is impossible to move the carcass, a half circumference measurement may be taken and doubled.

## c) External examination

<b>nutritional state</b>	Indicate the nutritional state of the carcass, using one of the following three categories: -good: the aspect of the upper flanks on either side of the dorsal fin is rounded; -moderate: the aspect of the upper flanks on either side of the dorsal fin is sloping; -poor: the aspect of the upper flanks on either side of the dorsal fin is hollow (in these animals, one can make out the transverse processes of the lumbar vertebrae, and there is an indentation dorsally just behind the head).
<b>body orifices</b>	

---

<sup>2</sup>The body condition, or state of decomposition of a carcass, can be described using the following condition code:

- 1) **live** (*becomes code 2 at death*)
- 2a) **extremely fresh** (*as if just died, no bloating, meat is considered by most to be edible*)
- 2b) **slight decomposition** (*slight bloating, blood imbibition visible*)
- 3) **moderate decomposition** (*bloating, skin peeling, penis may be extended in males, organs still intact, excluding postmortem damage*)
- 4) **advanced decomposition** (*major bloating, skin peeling, penis extended in males, organs beyond recognition, bones exposed due to decomposition*)
- 5) **indeterminate** (*mummified carcass or skeletal remains, no organs present*)

<sup>3</sup> The body weight can be estimated from the heart weight using the formula  $\log W = (\log H + 2.2) / 0.984$ , with H = heart weight and W = body weight, both in kg.

Examine the body orifices (mouth, eyes, ear openings, blow-hole, anus, genital slit and mammary slits) for lesions and any discharge. Collect and preserve left and right eyes separately in 10% formalin if lesions are noted.

**epidermis** Examine the animal for external lesions, including evidence of physical trauma and/or fresh contra- or con-specific rakemarks and photograph and sample these accordingly. Examine the skin carefully for any ectoparasites. These are most likely to be found in or near the body orifices and next to the fins and flukes. Take a 4 cm<sup>2</sup> piece of **milk** epidermis down to the blubber for DNA-studies, and freeze.

**blubber** Massage the skin in the area cranial to the mammary slits in a caudal direction to express any fluid present in the mammary glands. Note the volume, colour, and consistency of the fluid.

Cut a transverse strip of blubber about 2 cm wide from the anterior insertion of the dorsal fin, from the mid-dorsal to the mid-ventral region. Make sure to cut at right-angles to the surface of the skin. Measure the thickness of the blubber strip with a ruler 2cm lateral to the dorsal mid-line, mid-laterally, and 2cm lateral to the ventral mid-line. (Using this method, the tension of the blubber tissue is relieved before measuring.)

**muscle** Cut a strip of blubber a few cm wide and a few cm long at the level of the caudal insertion of the dorsal fin. Make sure to cut at right-angles to the surface of the skin. From this blubber strip, take 2x20 g cross-sectional samples of blubber for organochlorine analysis. It is important to take samples of the whole layer, from the skin to the muscle. Wrap them in hexane-washed aluminium foil and freeze. Alternatively, they can be placed in Sovirel glass tubes.

Take 2x20 g muscle samples for toxicological analysis, at the same location as and directly below the blubber sample, at the level of the caudal insertion of the dorsal fin. Wrap them in hexane-washed aluminium foil and freeze. Alternatively, they can be placed in Sovirel glass tubes. Take a 1 cm<sup>3</sup> sample of both the longissimus dorsi and abdominal muscle in 10% formalin (for histopathology).

**mammary gland** With the animal on its right side (if possible) make a mid-line ventral incision from the symphysis of the mandible to a short distance posterior of the anus, circumventing the genital slit and anus. From the posterior end of the ventral incision make a second one almost to the dorsal mid-line. Reflect the skin and blubber off the uppermost side. Any parasites in the blubber should be noted. They may occur as white cysts less than 1 cm in diameter, often in the ano-genital region or the dorsal aspect of the chest wall.

**subcutaneous tissue** In females, examine the mammary gland for pathological changes and parasites. Collect a cross-sectional slice of about 1 cm thick from halfway along the length of the **scapula** left mammary gland for histopathological examination, and place in 10% formalin.

Examine the subcutaneous tissue for the presence of bruises and parasites.

Remove the left scapula.

**d) Examination of abdominal organs (except G.I. tract, pancreas, and spleen)**

<b>virology samples</b>	Remove the left abdominal wall, freeing the testis or ovary and uterus. Any parasites in the abdominal wall (for instance cysts under the peritoneum) should be noted. Remove the left thoracic wall, for example with bone shears.
<b>bacteriology samples</b>	Before handling the internal organs, take a 1 cm <sup>3</sup> sample of lung tissue from the cranio-ventral part of the left lung and a 1cm <sup>3</sup> sample of kidney tissue from the left kidney for virological examination. Also take a sample of lung tissue from the cranio-ventral part of the left lung, a sample of kidney tissue from the left kidney and a sample of liver tissue from the left lobe of the liver for bacteriological examination.
<b>gas bubbles in the mesentery</b>	Examine the gastrointestinal tract for any abnormalities including gas bubbles in the mesenteric and intestinal veins. If any are present, take photos with a scalebar and sample tissue for histological examination.
<b>pericardial fluid/serum</b>	Sever the intestine close to the anus and the oesophagus close to the diaphragm. Working forward along the dorsal aspect of the abdominal cavity, remove the stomach, intestines, pancreas, spleen and mesenteric lymph node, attached to each other, from the carcass. Leave the examination of the G.I. tract to the end of the postmortem examination to prevent cross-contamination of other tissues with enteric micro-organisms.
<b>urinary bladder</b>	Collect sample of pericardial fluid after incising the pericardial sac. Collect any blood present in the heart lumen, to obtain serum for serological examination. Even if it is haemolytic, it is still of value.
<b>female reproductive tract</b>	Open and examine the bladder in situ, noting the contents, if any. Preserve a 1cm <sup>3</sup> sample of the bladder in 10% formalin (for histopathology).
<b>foetus</b>	In females remove the entire reproductive tract, open the vagina and uterus, note any corpora lutea, corpora albicantia or follicles on each ovary and then place the ovaries separately in 10% formalin for reproduction studies. Preserve a 1cm <sup>3</sup> sample of the uterus in 10% formalin (for histopathology). Describe the state of sexual maturity.
<b>male reproductive tract</b>	If a foetus is present, record the weight, length, sex and the state of decomposition. The whole foetus and its placenta can be wrapped in hexane-washed aluminium foil and stored frozen for organochlorine analysis.
<b>adrenal glands</b>	In males remove the testes and weigh them separately after removing the epididymis. After incision and examination, place the testes in 10% formalin for reproductive studies. Place a cross-sectional slice about 1 cm thick from mid-way along the length in 10% formalin. Examine the penis and preputium. Describe the state of sexual maturity where possible, final confirmation may be dependent on histological examination.
<b>kidneys</b>	Remove and examine the adrenal glands, and place a cross-sectional slice about 1 cm thick from the middle of the left adrenal gland in 10% formalin.  Examine the peri-renal vasculature for any gas bubbles. Describe and photograph if present and take samples of any associated lesions for histological examination.

**liver** Remove the kidneys from the body cavity and weigh them. Incise both kidneys longitudinally, and if possible, strip the capsule. Then, take 2x20 g samples for toxicological analysis from halfway the length of the left kidney. These samples should be cross-sectional and include both medullary and cortical tissue. Wrap them in hexane-washed aluminium foil and freeze. Alternatively, they can be placed in Sovirel glass tubes. Preserve 1 cm<sup>3</sup> from a kidney in 10% formalin for histopathological examination.

**thyroid** Examine the liver for any evidence of gas cavities beneath the capsule. Describe and photograph if present. Remove and weigh the liver. Examine both surfaces and make multiple incisions into the substance. Examine the parenchyma for the presence of any gas cavities. Describe and photograph if present and take samples of any associated lesions for histological examination. Examine the bile ducts for parasites. Then, take 2x20 g for trace metal analysis. Wrap them in hexane-washed aluminium foil and freeze. Alternatively, they can be placed in Sovirel glass tubes. Place 1 cm<sup>3</sup> of liver tissue in 10% formalin for histopathological examination.

#### **e) Examination of organs of head, neck and thorax**

Carefully remove the superficial muscles overlying the trachea and larynx to expose the thyroid gland. Examine this tissue and preserve 1 cm<sup>3</sup> of tissue in 10% formalin for histopathological examination.

**tongue** Incise along the internal aspects of both mandibles and free the tongue. Once the tongue is free reflect it backwards and cut the hyoid bones close to the skull.

**oesophagus**

**respiratory tract**

Free the larynx from the sphincter muscle holding it in place and pulling the tongue backwards incise along the neck to free the trachea and oesophagus. Then, incising dorsally and ventrally in the thoracic cavity, free the heart and lungs. Note any attachments of the lungs to the thoracic walls. This procedure should give you the tongue, larynx, trachea, oesophagus, thymus, heart and lungs all still fastened together.

Examine the surface of the tongue.

Open the oesophagus longitudinally and check for lesions or parasites.

**thymus** Look for evidence of pulmonary hypostasis and photograph if present. Open the larynx, trachea and major bronchi longitudinally. Look for evidence of aspiration of seawater, mud or beach material. Photograph if present. Make multiple incisions into the substance of both lungs. Any parasites may be collected. Two pieces of lung (about 1 cm<sup>3</sup>) from the hilus and periphery of the left lung, and the same from the right lung, should be collected in 10% formalin for histopathological examination. The samples should include part of the major bronchial tree. Open all major branches of the pulmonary veins and examine for the presence of parasites. Examine the bronchial and so-called "pulmonary associated" lymph nodes. The latter can be found about halfway along the ventral edges of each lung. Cut a 1 cm thick cross-sectional slice from the middle of the left pulmonary associated lymph node, and place it in 10% formalin for histopathological examination.

**heart**

<b>acoustic fat and tympanic bullae</b>	Examine the thymus, if present (noting the presence of any macroscopic cysts). Place 1 cm <sup>3</sup> of thymus in 10% formalin for histopathological examination.
<b>teeth (baleen plates)</b>	Separate the heart from the lungs by cutting through the major blood vessels where they enter the heart. Open the left and right ventricles and atria for examination and to take out any blood clots present. Any parasites should be noted. Weigh the heart. Cut a 1 cm thick slice of heart tissue, to include a piece of the wall of the left ventricle and of the atrioventricular septum, and place it in 10% formalin for histopathological examination.
<b>spinal cord</b>	Examine acoustic fats and note and photograph any haemorrhages. Take a 1 cm <sup>3</sup> section and place in 10% formalin. Examine the tympanic bullae if possible (which in cetaceans are not part of the skull but lie free just behind the mandibles). Carefully dissect each tympanic bulla (and associated cochlea) free of their connective tissue attachments to the skull. Examine the internal cavity of each bulla and note the presence of any nematodes or abnormalities. Preserve the left tympanic bulla/cochlea and right tympanic bulla/cochlea separately in 10% formalin if the carcass is in a suitable condition.
<b>skull</b>	If possible, remove two sets of (at least) 4 teeth from the middle of the lower jaw for ageing, and store frozen (separately). (In baleen whales, cut off 2 baleen plates as near as possible to their basis and store frozen.)
<b>brain</b>	Remove the head at the atlanto-occipital joint; collect a sample of cervical spinal cord and fix in 10% formalin.  If possible, open the skull, and examine the brain. The skull can be opened by making a vertical cut parallel and about 2 cm posterior to the transverse dorsal ridge which is clearly visible and palpable on top of the skull. The second cut should be made in the horizontal plane, through the occipital condyles, making sure to leave the posterior portion of the condyles on the skull, so that the condylo-basal length can still be measured. Both cuts should be extended until they meet each other. The separated piece of skull can then be pried loose using a chisel or flat-bladed screwdriver, and the brain can be removed.  Examine for the presence of bubbles within the vasculature in areas of the brain not damaged during skull excision. Describe and photograph any suspected bubbles/lesions. Take a 1 cm <sup>3</sup> sample of brain for virological examination and bacteriology and morbillivirus samples as described previously. Where possible, place the rest of the brain in 10% formalin for at least a week. To allow faster fixation, a longitudinal incision can be made in the cerebrum to expose the lateral ventricles. When it is fixed, make multiple slices into the tissue to look for pathological lesions, including the presence of parasites. Take 1 cm <sup>3</sup> samples of the cortex, cerebellum, and medulla for histopathological examination. Where possible, dissect the pituitary gland from the pituitary fossa (located in the cranial floor) and preserve in 10% formalin.
<b>spleen</b>	
<b>pancreas</b>	
<b>mesenteric lymph node</b>	Skulls may be stored frozen for morphometrics studies or museum archive. However, examination of the brain and spinal cord takes precedence.
<b>stomach</b>	<b>f) Examination of the G.I. tract, pancreas and spleen</b>



Examine and weigh the spleen and put a piece (about 1 cm<sup>3</sup>), including a section of capsule, in 10% formalin for histopathological examination. One often finds smaller accessory spleens near to the main spleen.

Examine the pancreas. Look for parasites, particularly in the pancreatic ducts. Place a 1 cm<sup>3</sup> piece of pancreas tissue in 10% formalin for histopathological examination.

**intestine**

Examine the mesenteric lymph node and put a 1 cm thick cross-sectional slice from halfway its length in 10% formalin for histopathological examination.

Open the cardiac section of the stomach. Note and photograph if watery fluid or ingested beach material is present in the lumen. Collect any fish bones, otoliths and other food remains and preserve in 70% ethanol or freeze for prey studies. Any parasites should be noted and the approximate burden described. Describe any lesions, including the distribution and size of any ulcers. Open the fundic and pyloric sections of the stomach. Any food material should be preserved for prey studies as for the cardiac section. Any nodules in the walls of the fundic and pyloric sections should be noted and, if they are found, attempts should be made to express the contents. Any parasites found in the contents should be noted.

Open the intestinal tract at several points along its length. Make note of any contents and/or lesions and any parasites that are found.

## Appendix III:

### CSIP PM Data collection sheets

# CETACEAN POSTMORTEM REPORT

When this report has been completed, please send a copy to: UK Cetacean Strandings Investigation Programme, The Wellcome Building, Institute of Zoology, Regent's Park, London, NW1 4RY, UK. Tel: 020 7449 6672 or 6691 Fax: 020 7483 2237 email: [rob.deaville@ioz.ac.uk](mailto:rob.deaville@ioz.ac.uk) or [paul.jepson@ioz.ac.uk](mailto:paul.jepson@ioz.ac.uk)

SW NO. : ..... PM NO. : .....  
SPECIES : ..... SEX : .....  
LOCATION FOUND : .....  
DATE FOUND : .. FOUND BY : .....  
.....  
PATHOLOGIST : ..... DATE OF PM : .....

FROZEN?: Y / N

## 1. BASIC MEASUREMENTS

### BODY CONDITION USING CONDITION CODE :

Condition code:

- |  |   |
|--|---|
| 1) <b>live</b> (becomes code 2 at death)   | 4) <b>advanced decomposition</b> (major bloating, skin peeling, penis extended in males, organs beyond recognition, bones exposed due to decomposition) |
| 2a) <b>extremely fresh</b> (as if just died, no bloating, meat is considered by most to be edible)   | 5) <b>indeterminate</b> (mummified carcass or skeletal remains, no organs present)  |
| 2b) <b>slight decomposition</b> (slight bloating, blood imbibition visible)  |   |
| 3) <b>moderate decomposition</b> (moderate bloating, skin peeling, penis may be extended in males, organs still intact, excluding postmortem damage) |   |

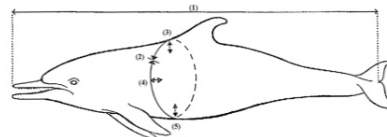
### PHOTOGRAPHS TAKEN

- lateral views whole body, both sides: Y/N  
-lateral views dorsal fin, both sides: Y/N  
-baleen whales: ventral view tail flukes: Y/N  
-other photographs (list):  
-  
-

### LENGTH, GIRTH AND BLUBBER THICKNESS (see diagram below):

- tip upper jaw to tail notch (cm) (1): .....  
-girth in front of dorsal fin (cm) (2): .....  
-blubber thickness in front of dorsal fin:  
-dorsal mid-line (mm) (3): .....  
-lateral (mm) (4): .....  
-ventral mid-line (mm) (5): .....

BODY WEIGHT (kg): .....



## 2. GROSS PATHOLOGICAL EXAMINATION

Encircle the appropriate category:

NE = not examined

NAD = nothing abnormal detected

A = abnormal (describe fully in section 5)

## **EXTERNAL EXAMINATION**

NE NAD A -body orifices  
NE NAD A -fins and flukes  
nutritional state: good / moderate / poor

## **INTEGUMENT**

NE NAD A -epidermis  
NE NAD A -blubber  
NE NAD A -subcutaneous tissue  
NE NAD A -mammary glands

## **MUSCULOSKELETAL SYSTEM**

NE NAD A -skull  
NE NAD A -other bones  
NE NAD A -back muscle mass  
NE NAD A -other muscles

## **NERVOUS SYSTEM**

NE NAD A -brain  
NE NAD A -spinal cord  
NE NAD A -peripheral nerves

## **CARDIOVASCULAR SYSTEM**

NE NAD A -pericardial sac  
NE NAD A -myocardium  
NE NAD A -valves  
NE NAD A -arteries, veins

## **RESPIRATORY SYSTEM**

NE NAD A -nasal cavity  
NE NAD A -sinuses  
NE NAD A -trachea, bronchi  
NE NAD A -lungs  
NE NAD A -pleura/pleural cavity

## **ALIMENTARY SYSTEM**

NE NAD A -mouth  
NE NAD A -oesophagus  
NE NAD A -cardiac section stomach  
NE NAD A -fundic section stomach  
NE NAD A -pyloric section stomach  
NE NAD A -intestine  
NE NAD A -anus  
NE NAD A -liver  
NE NAD A -pancreas  
NE NAD A -peritoneum/peritoneal cavity

## **UROGENITAL SYSTEM**

NE NAD A -kidneys  
NE NAD A -ureters  
NE NAD A -urinary bladder  
NE NAD A -urethra  
NE NAD A -ovaries/testes  
NE NAD A -uterus  
NE NAD A -vagina/penis  
NE NAD A -vulva/preputium

## **LYMPHATIC AND ENDOCRINE SYSTEMS**

NE NAD A -adrenal glands  
NE NAD A -thyroid gland  
NE NAD A -spleen  
NE NAD A -thymus  
NE NAD A -lymph nodes

### 3. CHECKLIST OF STANDARD SAMPLES

In each square, enter:  = sample taken

Blank = sample not taken or not present

Record any extra samples taken in section 4.

#### Weights (optional)

left testis (g): .....

right testis (g): .....

heart (g): .....

cardiac section stomach (g): .....

#### S/C's and Parasites

<input type="checkbox"/> food remains		Frozen	<input type="checkbox"/> lung	1 cm <sup>3</sup>
	Ethanol			
from:		<input type="checkbox"/>	<input type="checkbox"/>	
.....	<input type="checkbox"/>	<input type="checkbox"/>		
.....	<input type="checkbox"/>	<input type="checkbox"/>		
.....				

parasites from: (pref. all- stored in ethanol)

.....  
 .....  
 .....  
 .....  
 .....  
 .....

#### Freeze at -20°C

<input type="checkbox"/> epidermis	4 cm <sup>2</sup>
<input type="checkbox"/> blubber	2 x 20g
<input type="checkbox"/> liver	2 x 20g
<input type="checkbox"/> muscle	2 x 20g
<input type="checkbox"/> serum or PCF	up to 20 ml
<input type="checkbox"/> teeth	>4 (2 sets)
<input type="checkbox"/> baleen plates	>4 plates
<input type="checkbox"/> urine	up to 10 ml
<input type="checkbox"/> faecal material	up to 50 ml

<input type="checkbox"/> brain (RNA later)	0.5 cm <sup>3</sup>
<input type="checkbox"/> spleen (RNA later)	0.5 cm <sup>3</sup>
<input type="checkbox"/> lung (RNA later)	0.5 cm <sup>3</sup>

#### Virology (freeze at -80°C)

<input type="checkbox"/> brain	1 cm <sup>3</sup>
<input type="checkbox"/> spleen	1 cm <sup>3</sup>

10% Formalin

<input type="checkbox"/> adrenal glands	both
<input type="checkbox"/> bladder	1 cm <sup>3</sup>
<input type="checkbox"/> cerebrum	1 cm slice
<input type="checkbox"/> cerebellum	1 cm slice
<input type="checkbox"/> heart	1 cm <sup>3</sup>
<input type="checkbox"/> kidney	1 cm <sup>3</sup>
<input type="checkbox"/> liver	1 cm <sup>3</sup>
<input type="checkbox"/> lung	1 cm <sup>3</sup> x
<input type="checkbox"/> mammary gland	1 cm slice
<input type="checkbox"/> mesenteric ln.	1 cm slice
<input type="checkbox"/> pancreas	1 cm <sup>3</sup>
<input type="checkbox"/> pulm. ass. ln.	1 cm slice
<input type="checkbox"/> skin and blubber	1 cm <sup>3</sup>
<input type="checkbox"/> spinal cord	1 cm <sup>3</sup>
<input type="checkbox"/> spleen	1 cm <sup>3</sup>
<input type="checkbox"/> testes	both/slices
<input type="checkbox"/> thymus	1 cm <sup>3</sup>
<input type="checkbox"/> thyroid	1 cm <sup>3</sup>
<input type="checkbox"/> uterus	1 cm <sup>3</sup>
<input type="checkbox"/> brain	whole (in 15% formol saline)
<input type="checkbox"/> ovaries	both
(separately if immature)	

Bacteriology

<input type="checkbox"/> brain	swab/block
<input type="checkbox"/> kidney	swab/block
<input type="checkbox"/> liver	swab/block
<input type="checkbox"/> lung	swab/block
<input type="checkbox"/> spleen	swab/block
<input type="checkbox"/> CSF	swab/fluid

#### 4. LIST OF EXTRA SAMPLES

Extra samples of lesions taken for histological examination (list):

-  
-  
-  
-  
-  
-

Extra samples of lesions taken for bacteriological examination (list):

-  
-  
-  
-  
-  
-

Other extra samples taken (list):

-  
-  
-  
-  
-  
-

Optional (if time and storage allows)

Freeze at -20°C

- |  |             |
|--|-------------|
| <input type="checkbox"/> foetus/placenta | whole       |
| <input type="checkbox"/> scapula         | whole       |
| <input type="checkbox"/> skull           | whole       |
| <input type="checkbox"/> milk            | up to 20 ml |
| <input type="checkbox"/> eyes            | both        |

Virology (freeze at -80°C) or RNAlater (freeze at -20°C)

- |  |         |
|--|---------|
| <input type="checkbox"/> pituitary     | section |
| <input type="checkbox"/> cranial nerve | section |

Fixed tissue)

- |   |                            |
|---|----------------------------|
| <input type="checkbox"/> pituitary                        | whole                      |
| <input type="checkbox"/> tympanic bullae/cochlea          | both (only in 2a cases)    |
| <input type="checkbox"/> <i>longissimus dorsii</i> muscle | slice (held under tension) |
| <input type="checkbox"/> <i>rectus abdominus</i> muscle   | slice (held under tension) |

**5. DESCRIPTION OF ABNORMALITIES ON GROSS PATHOLOGICAL EXAMINATION**

(add extra pages if necessary)

PRELIMINARY DIAGNOSIS OF GROSS PATHOLOGICAL EXAMINATION (in order of importance):

- a.
- b.
- c.
- d.
- e.

**6. RESULTS OF HISTOLOGICAL EXAMINATION** (add extra pages if necessary)

**7. RESULTS OF BACTERIOLOGICAL EXAMINATION**

Heart blood: . . . . .

Lung: . . . . .

Liver: . . . . .

Kidney: . . . . .

Other: . . . . .

. . . . .

**8. MISCELLANEOUS RESULTS**

**9. FINAL DIAGNOSIS** (in order of importance):

- a.
- b.
- c.
- d.

## Appendix IV: Final Cetacean Post-Mortem Report

REFERENCE NUMBER: SW2017/  
POST-MORTEM NUMBER:  
HISTOLOGY NUMBER:  
SPECIES:  
SEX:  
DATE FOUND:  
LOCATION FOUND:  
NATIONAL GRID NUMBER:  
DATE OF POSTMORTEM:  
PATHOLOGIST: Rob Deaville

### **1. BASIC MEASUREMENTS**

FROZEN:  
CARCASS CONDITION:  
BODY WEIGHT: kg  
LENGTH, GIRTH AND BLUBBER THICKNESS:

-blubber thickness in front of dorsal fin:

-tip upper jaw to tail notch: cm  
-girth in front of dorsal fin: cm

-dorsal mid-line: mm  
-lateral: mm  
-ventral mid-line: mm

### **2. GROSS POSTMORTEM**

#### External examination

Nutritional state:  
Body orifices:  
Ectoparasites:  
Fins and flukes:

#### Integument

Epidermis:  
Blubber:  
Subcutaneous tissue:  
Mammary glands:

#### Musculoskeletal system

Skull:  
Other bones:  
Back muscle mass:  
Other muscles:

#### Nervous system

Brain:  
Spinal cord:  
Peripheral nerves:

#### Cardiovascular system

Pericardial sac:  
Myocardium:  
Valves:  
Arteries, veins:

#### Respiratory system

Nasal cavity:  
Sinuses:  
Trachea, bronchi:  
Lungs:  
Pleura/pleural cavity:



Alimentary system

Mouth:  
Oesophagus:  
Cardiac section stomach:  
Fundic section stomach:  
Pyloric section stomach:  
Duodenum/small intestine:  
Large intestine:  
Anus:  
Liver:  
Pancreas:  
Peritoneum/peritoneal cavity:

Urogenital system

Ovaria/testes:  
Uterus:  
Vagina/penis:  
Kidneys:  
Ureters:  
Urinary bladder:  
Urethra:  
Lymphatic and endocrine systems  
Adrenals:  
Thyroid:  
Spleen:  
Thymus:  
Lymph nodes:

**3. HISTOLOGY**

**4. BACTERIOLOGY**

**5. MISCELLANEOUS**

**DIAGNOSIS**

I *Significant diseases or conditions* thought to contribute to the death of the animal

II *Incidental diseases or conditions* not thought to contribute to the death or condition causing it

Comments:

**6. INSTITUTE OF ZOOLOGY REVIEW PANEL**

Comments:

## Appendix V:

### IWDG-RVL-GMIT Sample Collection Form

#### MI-NPWS PRIORITY SAMPLE CHECK-LIST

ANIMAL ID: \_\_\_\_\_

**Storage notes:**

PARASITES: Whole (70% ethanol)

LESIONS: Histology (1cm<sup>3</sup>) – x1 10% Formalin, Bacteriology (swab/block) – x1 Fridge

TOXICOLOGY: Wrapped in aluminum dull side up

SKIN (4cm<sup>2</sup>):

- x1 Frozen -20°C

BLUBBER:

- Toxicology (20g) – x2 Frozen -20°C

MUSCLE:

- Toxicology (20g) – x2 Frozen -20°C

KIDNEY:

- Toxicology (20g) – x2 Frozen -20°C

- Histology (1cm<sup>3</sup>) – x1 10% Formalin

- Virology (1cm<sup>3</sup>) – x1 Frozen -80°C

- Bacteriology (swab/block) – x1 Fridge

LIVER:

- Toxicology (20g) – x2 Frozen -20°C

- Histology (1cm<sup>3</sup>) – x1 10% Formalin

- Bacteriology (swab/block) – x1 Fridge

LUNG:

- Histology (4 x 1cm<sup>3</sup>) – 10% Formalin

- Bacteriology (swab/block) – x1 Fridge

- Virology (1cm<sup>3</sup>) – 1x Frozen -80°C

MAIN SPLEEN:

- Virology (1cm<sup>3</sup>) – x1 Frozen -80°C

- Bacteriology (swab/block) – x1 Fridge

SERUM OR PCF (Up to 20ml):

- PCF  OR Serum

URINE (Up to 20ml):

- Toxicology – x1 Freeze -20°C

STOMACH:

- Whole (Frozen -20°C)

TEETH (5-10):

- Frozen -20°C

REPRODUCTIVE SYSTEMS:

- R+L testes + epi (5 cm<sup>2</sup> from mid-testes and epi and store in separate labelled pots) Formalin 10%

OR R+L ovaries (whole in separate labelled pots or note differences in external appearance) - Formalin 10%

BRAIN:

- Virology (1cm<sup>3</sup>) – x1 Frozen -80°C

**REQUESTED ADDITIONAL SAMPLES/INFORMATION**

**SPLEEN**

- Histology (1cm<sup>3</sup>) – x1 10% Formalin

**GLANDS – HISTOLOGY (10% Formalin):**

- Prescapular lymph node (1cm<sup>3</sup>)
- Thymus (1cm<sup>3</sup>)
- Thyroid (1cm<sup>3</sup>)
- Pulmonary associated lymph node L+R (nick L) (1 cm<sup>3</sup>)
- Adrenal R+L (nick L) (Whole)
- Mammary R+L (nick L) (1cm<sup>3</sup>)

**INTESTINE**

- Last 10 cm (Frozen -20°C)

**FEMALE REPRODUCTIVE TRACT (excl. ovaries)**

- Whole (Formalin 10%)

**MILK (Up to 20ml):**

- Toxicology – x1 Freeze -20°C

**BRAIN**

- Bacteriology (swab/block) – 1x Fridge
- Histology (1cm<sup>3</sup>) – x4 10% Formalin

**ADDITIONAL INFORMATION:**

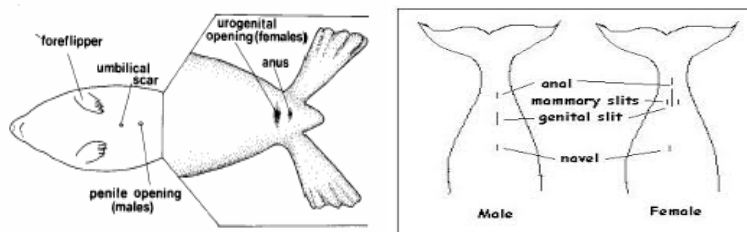
POST-ANAL HUMPH: Photograph + Blubber thickness (mm) \_\_\_\_\_ Muscle thickness (mm) \_\_\_\_\_  
 \_\_\_\_\_ (measurements from where hump is thickest)

**ADDITIONAL SAMPLES:**

<b>SAMPLE</b>	<b>STORAGE (frozen, ethanol etc.)</b>	<b>PURPOSE (B,H,V,T,O)</b>	<b>NO. OF SAMPLES/SIZE</b>	<b>LOCATION (if parasites/lesions)</b>

## Appendix VI: Bycatch Sample Collection Protocol

1. Wear clean non-powdered vinyl gloves provided. To avoid cross-contamination, clean gloves should be used for each carcass.
2. **For birds:** Birds are to be double bagged using the black plastic bags. Fill out one of the labels for the birds and place it on the outside bag. Record details on the bycatch record form.
3. Ask crew where it can be stored (in ice or in freezer (preferable)).
4. **For cetaceans:** Measure the length (in cm) by placing it on its belly and holding the tape measure down parallel to the carcass in a straight line. Measure the distance between the notch in the tail fluke and the tip of the upper jaw - record on the bycatch record form.
5. **For seals:** Place animal on belly and measuring tape parallel to carcass in a straight line. Measure (in cm) from the tip of the snout to the tip of the tail – record on the bycatch record form.
6. **For cetaceans and seals:** For species and sex verification, if possible, take photos of the animal's genital area as well as full side views of cetaceans and head profile pictures for seals. Determine the sex and record on the bycatch record form.



7. Complete labels on the zip-lock sample bags (as below) using a permanent pen.
8. Take a sample using the biopsy punch tool immediately in front of dorsal fin for cetaceans, or from the sternal region on the seals. Push it in far enough so the entire metal end of the tool is full of blubber when removed – when pulling the tool out of the animal hold it at an angle and twist it so the entire sample comes out within the tool. Discard and repeat if the tool is not full - a full cross section of the blubber layer must be obtained with skin attached to the outer layer, and muscle attached to the inner blubber layer. The tools are sterile before use so must be handled carefully when sampling in order to avoid cross-contamination.
9. Remove the blubber/skin sample with forceps from the biopsy punch tool, place and wrap in the tin foil (dull side up) square provided and place into the zip-lock bag you have labelled. Repeat steps - you should have two biopsy samples per animal. Two aluminum squares each containing one sample will go into the same plastic bag for the one animal.
10. Disinfect the biopsy tool and forceps between samples in tube of ethanol.
11. Ask crew where it can be stored (in ice or in freezer (preferable)).
12. When leaving the vessel, place all cetacean and bird samples into your box of iced fish/nephrops samples coming ashore. Inform the Catch Sampling Manager that you have samples and they will arrange to have them collected along with your normal samples.
13. If you require any more sampling equipment, please contact the Catch Sampling Manager.

### Label on cetacean sample bag:

Animal ID:  
Date:  
Species:  
Length:  
Sex:  
Sample: Skin+ Blubber

### Label on bird bag:

Animal ID:  
Date:  
Species:

## **Appendix VII:**

### **Bycatch sampling kit contents**

Twenty-five bycatch sampling kits were assembled for the at sea observers which contained the following items:

1. Sample protocol sheet (see below)
2. Eight pairs of disposable gloves
3. One permanent waterproof pen
4. Five disposable biopsy punch tools for skin/blubber sample collection
5. Ten squared of aluminium foil for samples to be wrapped in
6. One pair of forceps for sample extraction from biopsy tool
7. One tube of ethanol for disinfection of biopsy tool and forceps
8. Five pre-labelled zip-lock bags for samples to be kept in
9. One measuring tape for marine mammal length measurements
10. Six large black bags for seabird collection
11. Three pre-written labels for seabird bags
12. One bottle of hand sanitizer.

**Appendix VIII:**  
**Criteria used to establish selected causes of death are described below (CSIP, 2016).**

- **By-catch (entanglement in fishing gear)** was ascribed as a cause of death in cetacean carcasses using established pathological criteria for by-catch diagnosis
- **Infectious Disease**- a broad category consisting of a number of causes of death of infectious origin
- **Live Stranding**- attributed as the cause of death in cetaceans that were known or suspected (from post-mortem examination) to have live-stranded in apparent good health and nutritional status. This category excluded severely diseased or emaciated animals that stranded alive
- **Starvation**- given as the cause of death in animals that were severely emaciated and, following post-mortem examination, ascertained to have no other significant disease processes that could explain the poor nutritional status
- **Starvation (neonate)**- given as the cause of death in neonates that were severely emaciated and, following post-mortem examination, ascertained to have no other significant disease processes that could explain the poor nutritional status. Some of these animals may have become maternally separated
- **Fatal attack from one or more bottlenose dolphins**- ascribed as a cause of death in cetacean carcasses using established pathological criteria
- **Grey seal attack**- ascribed as a cause of death in individuals presenting with pathology potentially consistent with grey seal attack, as recently described
- **Physical trauma (boat/ship strike)**- physical trauma consistent with impact from a boat or ship. Includes blunt trauma to dorsal/lateral aspect of body wall and/or injuries consistent with propeller strike
- **Dystocia & Stillborn**- attributed as the cause of death in animals which have died during the act or process of giving birth (mothers or calves)
- **Physical trauma (unknown origin)**- where evidence of physical trauma is found at post-mortem, but no obvious origin or other significant underlying factors. This category is likely to include some undiagnosed cases of boat/ship strike, by-catch or bottlenose dolphin attack.
- **Gas embolism**- intravascular gas bubble formation that obstructs circulation and causes associated tissue injury
- **Entanglement**- a cause of death category largely confined to minke whales. Denotes evidence of entanglement in rope (creel etc.) or discarded fishing gear/marine litter
- **Cold stunned**- a cause of death category specific to hard shelled species of marine turtle, resulting from exposure to cold water around the UK coast, leading to immobility, hypothermia and eventual starvation
- **Neoplasia**- where the cause of death is due to the formation of a tumour
- **Others**- a broad category covering causes of death that cannot be categorised using existing criteria



An Roinn Talmhaíochta,  
Bia agus Mara  
Department of Agriculture,  
Food and the Marine



## Supply of Vertebrate Necropsy and Sample Recovery Services Extension - 2019 Final Report

*Stephanie Levesque<sup>1</sup>, Jim O'Donovan<sup>2</sup>, Mags Daly<sup>1</sup>, Sinéad Murphy<sup>3</sup>, Mick O'Connell<sup>1</sup>, Paul Jepson<sup>4</sup>, Rob Deaville<sup>4</sup>, James Barnett<sup>5</sup>, and Simon Berrow<sup>1</sup>*

<sup>1</sup> Irish Whale and Dolphin Group, Merchants Quay, Kilrush, Co. Clare, Ireland

<sup>2</sup> Regional Veterinary Laboratory, Model Farm Road, Co. Cork, Ireland

<sup>3</sup> Galway-Mayo Institute of Technology, Old Dublin Road, Co. Galway

<sup>4</sup> UK Cetacean Strandings Investigation Programme, Zoological Society of London, Institute of Zoology, Zoological Society of London, Regent's Park, London NW1 4RY

<sup>5</sup> Environment and Sustainability Institute, University of Exeter, Cornwall, United Kingdom

Reference Number: ITT18-050

Clients: Marine Institute with support of the National Parks and Wildlife Service, Department of Culture, Heritage and the Gaeltacht



An Roinn Talmhaíochta,  
Bia agus Mara  
Department of Agriculture,  
Food and the Marine



EUROPEAN UNION  
This measure is part-financed  
by the European Maritime  
and Fisheries Fund



Foras na Mara  
Marine Institute



National Park &  
Wildlife Service

December 2019

## Executive Summary

The Marine Institute (MI) contract *Supply of Vertebrate Necropsy and Sample Recovery Services* required i) the recovery and standardised necropsy of three cetacean species with associated case history reporting; ii) the provision of sampling kits to be used for the recovery of tissue samples collected from bycaught animals (birds, seals and cetaceans) by observers on commercial inshore and offshore fishing vessels in Irish waters in order to provide additional data to the MI's existing catch sampling programme; and iii) the storage and subsequent delivery of all samples and associated databases to the client.

During this contract, a total of 45 individual cetaceans were recovered for necropsy from two geographical lots between 1 January and 12 November 2019, exceeding the target goal of 44 specified in the contract. These 45 animals comprised 31 common dolphins (*Delphinus delphis*), five striped dolphins (*Stenella coeruleoalba*) and nine harbour porpoises (*Phocoena phocoena*). Twenty-two of the 45 (49%) individuals were recovered from Lot 1 from counties Clare to Donegal, and 23 (51%) individuals were recovered from Lot 2 from counties Wexford to Kerry (Figure 1).

Seven sampling kits were assembled and delivered to the MI as well as 50 biopsy punches for distribution to their panel of fishery observers. No bycaught animals were reported by the DCF programme to the Project Coordinator.

Results from this contract will inform the development of a long-term strategy for necropsy of stranded cetaceans and recovery of tissue samples for further biological studies.

Samples requiring long-term storage at -20°C, including those for virology, were transported in a portable refrigerator to the IWDG office in Kilrush, Co. Clare and stored at facilities on site. Formalin fixed tissues, such as reproductive organs and adrenal glands were stored at the RVL in Cork. All samples were delivered to the Marine Institute in Oranmore, Co. Galway, along with a detailed database of samples collected.

## Introduction

The Marine Institute published a tender for the provision of vertebrate necropsy services for cetaceans stranded on the Irish coast and for the provision of sampling kits for observers involved in Data Collection Framework (DCF) surveys. The first task required the recovery and standardised necropsy of a targeted sample of three species of stranded cetaceans with associated case history reporting. The second task consisted of the provision of sampling kits to be used for the recovery of tissue samples collected from bycaught animals (birds, seals and cetaceans) by DCF observers out on commercial fishing vessels in Irish waters. The existing catch sampling at sea programme is led by the MI for the Department of Agriculture, Food and the Marine (DAFM) in order to enhance and verify the accuracy of catch data as well as support the wider assessment of commercial fish/shellfish and to assess fish catches under the DCF programme (Marine Institute, 2017).



The aim of this contract was to conduct standardized laboratory necropsies of a targeted number of common and striped dolphins, as well as harbour porpoises. The Irish Whale and Dolphin Group (IWDG) were the main contractor with two sub-contractors, the Regional Veterinary Laboratories (RVL) of the DAFM and the Galway-Mayo Institute of Technology (GMIT). Stranded cetaceans were sourced and retrieved via the IWDG Cetacean Stranding Scheme, which was established in 1991 and co-ordinates a network of trained recorders.

## Methods

### NECROPSIES

Three species were targeted for collection for necropsy; common dolphin (*Delphinus delphis*), striped dolphin (*Stenella coeruleoalba*) and harbour porpoise (*Phocoena phocoena*). The area of coverage for the contract extended from County Donegal to County Wexford, which was divided into two lots. Lot 1 included coastal areas of counties Donegal to County Clare inclusive, and Lot 2 consisted of coastal areas of counties Kerry to south County Wexford inclusive. A target of 44 animals was set by the MI and the National Parks and Wildlife Service (NPWS) consisting of 22 animals from each lot. For the purposes of this report, the time period of animal collection was set from 1 January to 1 December 2019.

#### *Locating carcasses and assessing suitability for necropsy*

The IWDG has been co-ordinating an All-Ireland Cetacean Stranding Scheme since 1991 and has a network of recorders who visit and photograph stranded animals and record basic parameters, with over 90% of records accompanied by photographs. This network was used to locate and assess the suitability of stranded target species for necropsy.

Suitability of carcasses for post-mortem was assessed by examining available photographs and utilising descriptions of body condition as defined by the UK Cetacean Strandings Investigation Programme (CSIP) (2016). Carcasses were recovered within decomposition codes: **2a** (extremely fresh), **2b** (slight decomposition), **3** (moderate decomposition) and **4** (advanced decomposition) – see Figure 1. If no photos were available, the animal was deemed unsuitable for collection.



Photo 1. Decomposition code 2a. Extremely fresh. A female common dolphin which live stranded at Ballylongford, Co. Kerry with a calf (Photo. Joanne O'Brien).



Photo 2. Decomposition code 2b. Slight decomposition. A female striped dolphin was found dead on Derrymore Strand, Co. Kerry (Photo. Annette Enright).



Photo 3. Decomposition code 3. Moderate decomposition. A male common dolphin in moderate condition from Ballinacourty, Co. Galway (Photo. Stephanie Levesque)



Photo 4. Decomposition code 4. Advanced decomposition. A female common dolphin found in Castletownbere, Co. Cork (Photo IWDG/RVL)

**Figure 1. Examples of the four categories (extremely fresh, slight decomposition, moderate decomposition, advanced decomposition) used to determine whether a stranded cetacean was suitable for necropsy.**

### *Post-mortem protocol*

Each animal was assigned an IWDG stranding code reference number in addition to a Regional Veterinary Laboratory post-mortem number. Necropsies were undertaken in accordance with the CSIP's *Guidelines for the Post-mortem Examination and Tissue Sampling of Cetaceans during Stranding Events* (Appendix II). Templates of the CSIP data collection sheets (Appendix III) and cetacean post-mortem report (Appendix IV) were utilised within the current project. Samples were collected as per the agreed sampling protocol outlined by the NPWS and the MI (Appendix V).

The tender team attended a two-day necropsy workshop hosted by CSIP at the Institute of Zoology (IoZ) in London in June 2017, which provided the team with expert training and technical guidance. The IoZ team made a number of presentations describing their experiences in cetacean recovery and necropsy, offering valuable knowledge on their findings and advice such as which techniques and equipment to employ when recovering an animal and carrying out a post-mortem examination. The workshop continued in the post-mortem lab where CSIP scientists led the tender team in the necropsy

of a common dolphin. Methods of recording, photographing, assessing organs/overall animal health and cause of death were covered. Afterward, the tender team had the opportunity to lead the examinations of several cetaceans in order to attempt to determine cause of death with guidance from the CSIP scientists. Suspected causes of death included ship strike, bycatch, and seal attack.

Necropsies for this contract were carried out by a trained veterinarian from the RVL in Cork with the assistance of biologists from GMIT and IWDG. Detailed case history reports for each animal documenting the animal's initial gross examination, as well as the results of bacteriology and histopathology assessments (if available) and any other significant findings, were prepared. The IoZ was contracted to review the individual Case History reports to provide guidance on standardised reporting with external schemes and validation of causes of death. Biological samples were collected, labelled and stored for future studies. Samples for bacteriology and general histopathology assessments were processed by the RVL through their existing lab facilities at Cork RVL and Back Weston, Co. Kildare. All samples requiring long-term storage at -20°C, including those for virology, were transported in a portable refrigerator to the IWDG office in Kilrush, Co. Clare and stored at facilities on site. Formalin fixed tissues, such as reproductive organs and adrenal glands, were stored at the RVL in Cork. A database was created detailing all samples collected, their storage requirement and location.

#### *Case history reporting*

For each completed necropsy on an individual animal, a comprehensive digital Case History was produced in accordance with the post-mortem examination reporting protocol. The individual Case History file includes a presentation of factual evidence as observed and documented during the post-mortem examination, as well as photographic evidence and charts of external lesions. The full detailed Case History report was completed by the project Lead Scientist leading the necropsy, and reviewed by a second project Lead Scientist. Following internal sign off by the Principal Investigator, Case History files were submitted electronically to a panel of veterinary experts led by the IoZ for independent validation of the necropsy results. Case History files were then submitted to the project Steering Group.

#### **DATA COLLECTION FRAMEWORK**

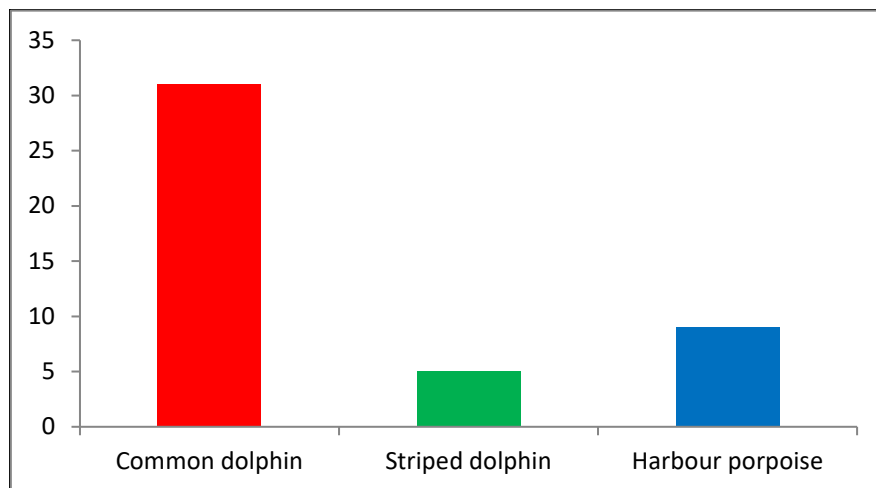
The contract also included the provision of bycatch sampling kits to the Irish DCF programme, and the retrieval of samples collected at sea from DCF observers. Seven bycatch sampling kits were assembled for the at-sea observers, which included a bycatch sampling protocol leaflet (see Appendix VI). All sampling kits, along with 50 additional biopsy punches, were delivered to the DCF Observer Programme Co-ordinator for distribution. Contents of the bycatch sampling kits may be found in Appendix VII. If a bycatch incident occurred and animals were sampled, observers were to notify the DCF Programme Co-ordinator, who then liaised with the Necropsy Project Co-ordinator. Samples were then to be retrieved and stored at the IWDG office.

## Results

### NECROPSIES

#### *Cetacean Collection and Reporting*

A total of 45 animals were collected for this contract comprising 31 common dolphins, five striped dolphins and nine harbour porpoises (Figure2).



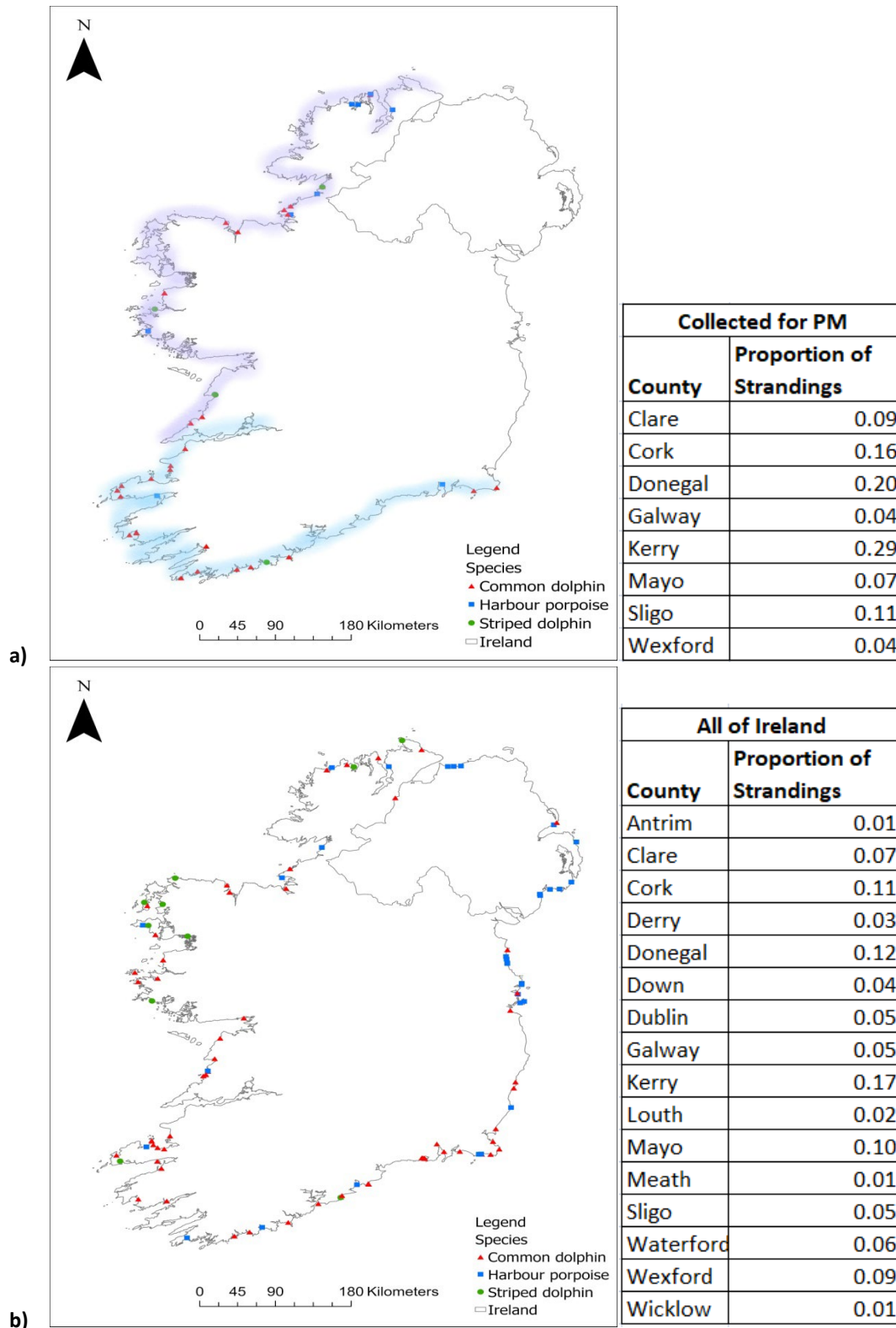
**Figure 2. Total number of target species collected for this contract.**

Overall, 49% (22/45) of animals were recovered from Lot 1 and 51% (23/45) from Lot 2 (Figure 3a). Out of the eight counties from which animals were collected, most (29%) were collected from County Kerry, followed by Donegal (20%), Cork (16%), Mayo (11%), Clare (9%), Sligo (7%), Galway (4%) and Wexford (4%) (Figure 3a).

On review of all available strandings data, these three species were recorded stranded in a total of 16 counties throughout the whole of Ireland over the 2019 tender period (Figure 3b). Again, most strandings (17%) were reported from Co. Kerry (Figure 3b).

Of the animals necropsied during this contract, the majority were common dolphins (69%) followed by harbour porpoises (20%) and striped dolphins (11%). All animals necropsied were within decomposition codes 1 to 4 and thus suitable for inclusion within the contract.

Of the 44 animals collected whose sex could be determined, 57% (25/45) were male and 43% (19/45) were female. The sex for one individual was undetermined due to extensive scavenger damage.



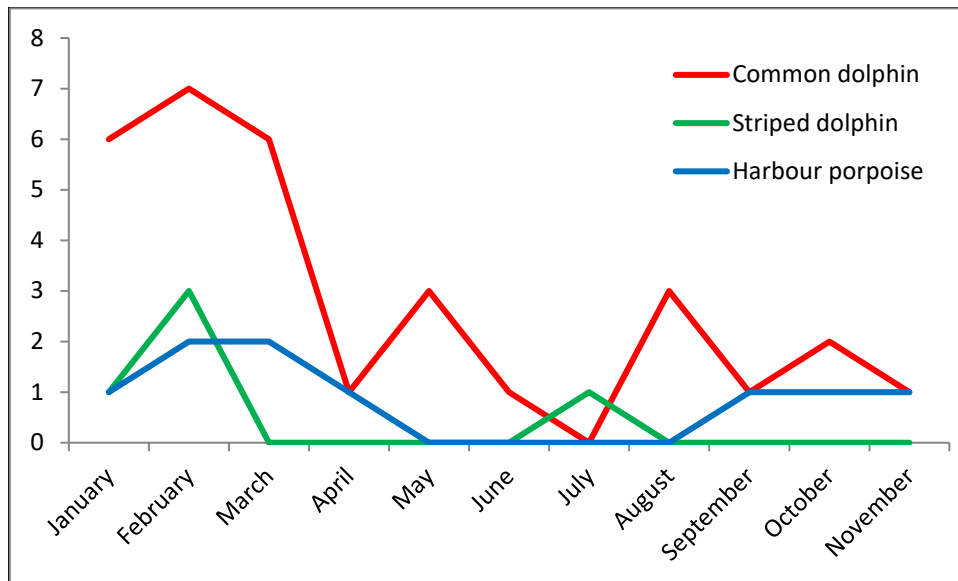
**Figure 3. (a) Location of stranded animals collected for necropsy. Shaded region in purple represents Lot 1 covering the coastal areas of counties Donegal to County Clare inclusive, and shaded region in blue represents Lot 2 covering the coastal areas of counties Kerry to south County Wexford inclusive, accompanied by table representing percentage of strandings reported per county (b) Location of stranded animals within the whole of Ireland over the tender period accompanied by table representing percentage of strandings reported by county.**

Of the animals recovered during this tender, 98% (44/45) were found dead, while only one (2%) was reported as a live stranding. This was an adult male striped dolphin in County Clare. Details of all animals recovered for post-mortem examination can be found in Table 1.

**Table 1. Details of animals recovered for post-mortem examination.**

Lot	Code	Species	Sex	Stranding Location
1	IWDG 2019_002	CD	Female	Rosstown Beach, Co. Donegal
1	IWDG 2019_003	SD	Male	Rosstown Beach, Co. Donegal
2	IWDG 2019_004	CD	Female	Banna Strand, Co. Kerry
1	IWDG 2019_007	CD	Female	Carrowinsky Beach, Co. Mayo
2	IWDG 2019_009	CD	Female	Kilmore Quay, Co. Wexford
2	IWDG 2019_010	CD	Female	Wine Strand, Smerwick Harbour, Co. Kerry
2	IWDG 2019_011	HP	Female	Inch Beach, Co. Kerry
1	IWDG 2019_012	CD	Male	Carrowinsky Beach, Co. Mayo
1	IWDG 2019_014	SD	Male	Renvyle, Co. Galway
1	IWDG 2019_015	HP	Female	Bunowen Beg, Ballyconneely, Co. Galway
2	IWDG 2019_018	CD	Female	Waterville, Co. Kerry
2	IWDG 2019_021	CD	Female	Ballybunnion, Co. Kerry
1	IWDG 2019_022	HP	Male	Buncrana Beach, Lough Swilly, Co. Donegal
2	IWDG 2019_023	CD	Male	Carne, Co. Wexford
2	IWDG 2019_039	CD	Female	Waterville, Co. Kerry
2	IWDG 2019_040	CD	Female	Bantry Bay, Snaive Beach, Co. Cork
2	IWDG 2019_044	SD	Male	Lahinch, Co. Clare
2	IWDG 2019_045	CD	Male	Schull, Co. Cork
2	IWDG 2019_046	SD	Female	Ballinglanna Bay, Seven Heads - Co. Cork
2	IWDG 2019_047	CD	Male	Union Hall, Carrigillihy, Co. Cork
2	IWDG 2019_049	CD	Male	Ventry Beach, Co. Kerry
2	IWDG 2019_050	CD	Male	Ballinaskelligs, Co. Kerry
2	IWDG 2019_051	CD	Male	Waterville, Co. Kerry
1	IWDG 2019_058	CD	Male	Fanad Head, Co. Donegal
1	IWDG 2019_059	CD	Male	Farrihy Bay, Co. Clare
1	IWDG 2019_061	CD	Female	Streedagh Beach, Co. Sligo
1	IWDG 2019_063	HP	Female	Tullan Strand, Bandoran, Co. Donegal
1	IWDG 2019_065	HP	Male	Ballyhiernan Bay, Fanad - Co. Donegal
1	IWDG 2019_078	HP	Male	Lisadell, Co. Sligo
2	IWDG 2019_088	CD	Female	Ballyheigue, Co. Kerry
2	IWDG 2019_092	CD	Male	Feoghanagh, Co. Kerry
2	IWDG 2019_093	CD	Male	Smerwick Harbour, Co. Kerry
1	IWDG 2019_104	CD	Male	Lislary, Co. Sligo
1	IWDG 2019_120	CD	Female	Doughmore, Co. Clare
1	IWDG 2019_127	SD	Male	Lahinch, Co. Clare
1	IWDG 2019_146	CD	UNK	Enniscrone, Kilalla Bay, Co. Sligo
2	IWDG 2019_147	CD	Male	Garrylucas Beach, Co. Cork
1	IWDG 2019_151	CD	Male	Lackan Bay, Nr. Kilcummin, Co. Mayo
1	IWDG 2019_158	HP	Female	Marble Hill Beach, Dunfanaghy, Co. Donegal
1	IWDG 2019_159	CD	Male	Lisdell, Co. Sligo
2	IWDG 2019_176	CD	Female	Crookhaven, Co. Cork
2	IWDG 2019_177	CD	Male	Long Strand, Castlefreke, Co. Cork
1	IWDG 2019_180	HP	Male	Sheephaven Bay, Co. Donegal
2	IWDG 2019_181	CD	Male	Brandon Bay, Co. Kerry
1	IWDG 2019_184	HP	Female	Shroove, Inishowen Head

The sampling period for this contract was set from 1 January to 1 December 2019. The majority of animals were collected during the month of January (Figure4).



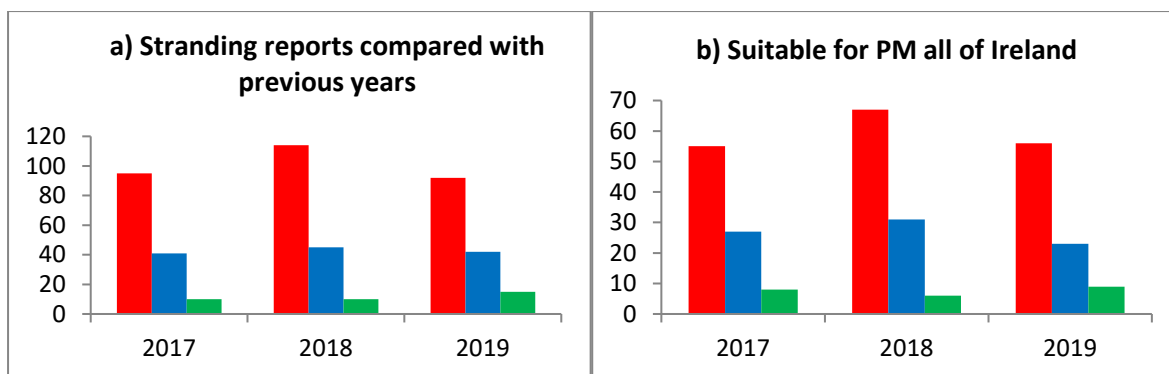
**Figure 4. Months during which animals were collected for necropsy. A peak occurred in February. Collection numbers for November could have been higher as collection ceased mid-November when the final animal was recovered. This is also why December was not included in this chart.**

In order to determine whether stranding patterns during this contract were consistent with previous years, the IWDG Stranding Database was interrogated to examine stranding patterns over the last three years for the relevant species (see Figures 5 and 6). Strandings during the 2019 sampling period were similar to those in 2017 for common dolphins and harbour porpoises – both species had lower stranding numbers compared to 2018, more so for common dolphins. There appears to have been a slight increase in striped dolphin strandings in 2019 compared to the previous two years (Figure 5a).

Common dolphins were the most frequently reported species during the sampling period in all three years, while striped dolphins were the least frequently stranded species reported of the three target species (Figure 5a). We also compared the suitability of stranded cetaceans for post-mortem over the previous two years by examining body condition from stranding record photos using CSIP body condition categories mentioned previously. Using records from the whole of Ireland (Figure 5b), and those from Lots 1 and 2 only (Figure 6a), once again, we see the peak in 2018 common dolphin strandings and a slight rise in the number of striped dolphins. Harbour porpoise numbers appear to have remained somewhat relatively consistent.

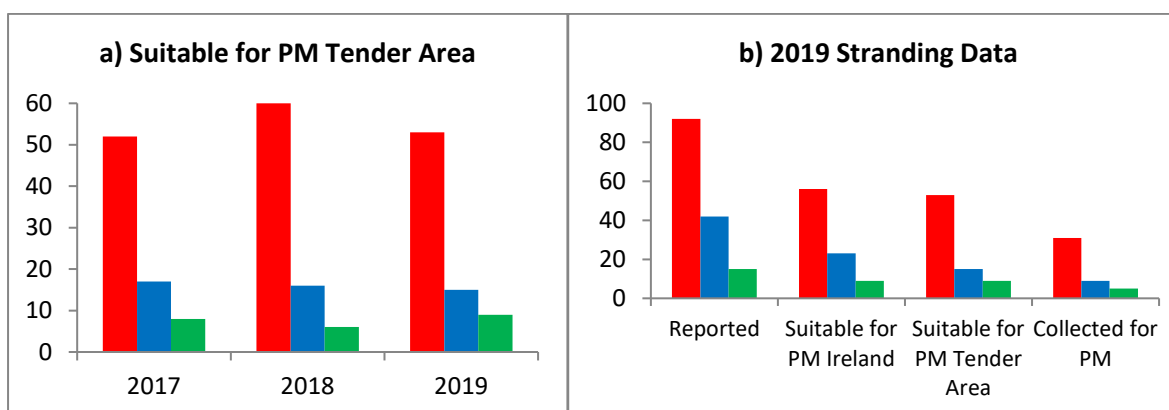
Figure 6b presents the total number of the three species reported with the total number suitable for post-mortem from the whole of Ireland, the two tender lots, and total number of each species collected in the current contract.

On average, animals were collected within a day of being reported and necropsied within five days from delivery to RVL Cork.



**Figure 5. (a) Strandings reported for the three target species compared between 1 January and 1 December 2017, 2018 and 2019.**

**(b) Total suitable for post-mortem examination in whole of Ireland between the dates of 1 January and 1 December 2017, 2018 and 2019. Common dolphin = red, harbour porpoise = blue, striped dolphin = green.**



**Figure 6. (a) Total suitable for post-mortem examination from Tender Lots 1 and 2 between the dates of 1 January and 1 December 2017, 2018 and 2019.**

**(b) Comparisons for animals reported between the dates of 1 January and 1 December 2019. Common dolphin = red, harbour porpoise = blue, striped dolphin = green.**

### Post-Mortem Results

Full necropsies were undertaken at RVL in Cork. Although outside the requirements of the tender, routine bacteriological analysis of samples is ongoing and undertaken by RVL staff in Cork City. If bacteria of significance were observed, the isolate was referred to the National Reference Laboratory for confirmation. General histopathological assessment of tissues is also ongoing and being undertaken by one of the lead scientists (JO'D).

A probable cause of death (COD) was described wherever possible based on collective findings from post-mortem and other diagnostic investigations. Criteria used to establish COD were based on those defined by the CSIP (2016) (see Appendix VIII). As per the previous contract, in the case of live strandings, this COD was attributed to those animals known or suspected (from post-mortem



examination) to have live-stranded in *'apparent good health and nutritional status and excluded severely diseased or emaciated animals that stranded alive'*. Where applicable, COD of starvation is attributed to animals that were *'severely emaciated and, following post-mortem examination, ascertained to have no other significant disease processes that could explain the poor nutritional status'*. Whereas bycatch was ascribed as a COD *'using established pathological criteria for by-catch diagnosis'* (Kuiken *et al.* 1994; Kuiken 1996).

A table of representing a summary of significant and incidental diseases from the necropsied animals for this are presented in Table 2 below. As adult common dolphin collected from county Sligo (IWDG 2019\_146) was too decomposed at time of necropsy, and therefore has been excluded from the table and post-mortem results analyses.

**Table 2. Summary of Cause of Death of necropsied cetaceans.**

IWDG code	Species	Sex	Length	Tentative age/maturity Category	Preliminary COD categories	Significant disease or conditions	Incidental diseases or conditions	Validated COD	Finalised COD categories
IWDG 2019_002	CD	Female	157	Juvenile	Malnutrition / Hypothermia	Poor body condition /hypothermia Possible brucellosis –isolate ID pending	Moderate verminous bronchopneumonia	Malnutrition / Hypothermia. Potentially due to Verminous bronchopneumonia and suspected Brucella infection	Starvation
IWDG 2019_003	SD	Male	167	Juvenile	Not established	Not apparent	Verminous gastritis Marked granulomatous mural gastritis	Not established – possible live stranding. Histopathology required	Not established– Suspected live stranding
IWDG 2019_004	CD	Female	194	Adult	Bycatch	Bycatch- PUE Severe cavitation/gas bubble lesions in liver and retroperitoneum	Poor body condition Severe gastric parasitism with ulceration. Mild verminous bronchitis	Suspected Gas embolism Live stranding	Bycatch
IWDG 2019_007	CD	Female	154.5	Sub-adult	Illthrift and endoparasitism	Very poor body condition. Severe verminous gastritis with ulceration and verminous bronchitis and pneumonia	None	Infectious disease - Endoparasitism.	Infectious Disease
IWDG 2019_009	CD	Female	207	Adult	Not established Suspected Infectious Disease	Suspected <i>Morganellamorganiise</i> pticaemia	Verminous gastritis with ulceration	Suspected infectious disease - Histopathology required	Not established - Suspected Infectious Disease
IWDG 2019_010	CD	Female	179	Adult	Probable bycatch	Fractured rostrum, shallow lacerations / impression marks	Verminous bronchitis. Verminous gastritis with mucosal ulceration	Probable bycatch	Not established - Suspected Bycatch

IWDG code	Species	Sex	Length	Tentative age/maturity Category	Preliminary COD categories	Significant disease or conditions	Incidental diseases or conditions	Validated COD	Finalised COD categories
IWDG 2019_011	HP	Female	135	Adult	Infectious disease	Severe, diffuse, chronic-active, verminous pneumonia Poor body condition likely due to endoparasitic lesions.	Severe, parasitic granulomatous gastritis. Nematodes in fundic stomach and trematodes in pyloric stomach. Focal dermatitis.	Infectious disease - Parasitic bronchopneumonia	Infectious disease
IWDG 2019_012	CD	Male	219	Adult	Bycatch	Marked congestion of the liver and dorsal lungs. Intraocular haemorrhage, erythema of sclera and haemorrhage in thoracic rete mirabile  Indentation mark on tail stock  Recently ingested prey	Focal gastritis  Verminous pneumonia	Probable bycatch	Bycatch
IWDG 2019_014	SD	Male	172	Juvenile	Probable live stranding	Hypostatic pulmonary congestion Presence of seaweed in airways	Verminous gastritis with ulceration.  Parasitic mural gastritis ( <i>Pholeter</i> sp.)	Probable live stranding. Histopathology and Brucella culture required to confirm cause of live stranding	Not Established – Suspected live Stranding
IWDG 2019_015	HP	Female	134	Sub-adult	Trauma/bycatch	Multiple bilateral rib fractures, bilateral haemothorax, laceration of the parietal pulmonary pleura  Intraocular haemorrhages  Rope/net indentation marks around the body (cranial to the pectoral fins)	Verminous pneumonia and bronchitis  Verminous gastritis with ulceration	Bycatch	Bycatch

IWDG code	Species	Sex	Length	Tentative age/maturity Category	Preliminary COD categories	Significant disease or conditions	Incidental diseases or conditions	Validated COD	Finalised COD categories
IWDG 2019_018	CD	Female	196	Adult	Physical trauma (unknown origin)	Pulmonary haemorrhage Pleural rupture	Verminous gastritis with ulceration	Physical trauma - Possible bottlenose dolphin attack - Pulmonary haemorrhage/ Pleural rupture	Physical trauma – Suspected bottlenose dolphin attack
IWDG 2019_021	CD	Female	176	Sub-adult	Infectious disease	Verminous bronchitis and pneumonia Poor nutritional state/hypothermia	Verminous gastritis	Infectious disease - Verminous bronchitis and pneumonia Possible terminal livestranding	Infectious disease
IWDG 2019_022	HP	Male	131	Juvenile	Infectious disease	Verminous bronchitis Pneumonia Obstruction of airways by clotted blood and nematode worms	Moderate verminous gastritis and ulceration Chronic trematodal gastritis with mural fibrosis Terematodalcholangiohepatitis with bile duct fibrosis.	Infectious disease - Verminous bronchitis and pneumonia	Infectious disease
IWDG 2019_023	CD	Male	138	Juvenile	Not established	Not determined	Verminous pneumonia Trematodal gastritis	Not established – Histopathology required	Not established
IWDG 2019_039	CD	Female	198	Adult	Infectious disease	Multifocal abscessation ( <i>Photobacterium damsela</i> ) Septic peritonitis Verminous gastritis, gastric ulceration	Verminous pneumonia	Infectious disease	Infectious disease

IWDG code	Species	Sex	Length	Tentative age/maturity Category	Preliminary COD categories	Significant disease or conditions	Incidental diseases or conditions	Validated COD	Finalised COD categories
IWDG 2019_040	CD	Female	138.5	Juvenile	Starvation Probable live stranding	Moderate/poor nutritional state Ill thrift with no evidence of recent feeding Hypostatic congestion of lung	None	Starvation Probable terminal live stranding	Starvation
IWDG 2019_044	SD	Male	151	Sub-adult	Not established	Poor body condition	Verminous bronchitis Verminous gastritis	Not established due to level of decomposition and scavenger damage	Not established
IWDG 2019_045	CD	Male	196	Adult	Not established	Evidence of chronic thoracic/pulmonary pathology Haemorrhage over one scapula, loss of mandible, evidence of recent feeding	Verminous bronchitis/pneumonia Verminous gastritis	Not established due to level of decomposition and post mortem damage to the skin Possible bycatch	Not Established – Suspected Bycatch
IWDG 2019-046	SD	Female	152.5	Sub-adult	Probable live stranding	Poor body condition	None	Probable live stranding. Histopathology required to confirm	Not Established – Suspected Live Stranding Starvation
IWDG 2019_047	CD	Male	205.5	Adult	Live stranding	Ingestion of sand, stones Hypostatic pattern of congestion in lungs. <i>Photobacterium damselae</i> isolated from lungs	Verminous gastritis Verminous bronchitis/pneumonia	Live stranding	Live stranding
IWDG 2019_049	CD	Male	c160	Juvenile	Bycatch	Amputated tail stock	Verminous gastritis Verminous pneumonia	Bycatch	Bycatch

IWDG code	Species	Sex	Length	Tentative age/maturity Category	Preliminary COD categories	Significant disease or conditions	Incidental diseases or conditions	Validated COD	Finalised COD categories
IWDG 2019_050	CD	Male	191	Sub-adult	Bycatch	Net marks on fins Recently ingested prey / chyle	Verminous gastritis with ulceration. Verminous bronchitis/pneumonia	Bycatch	Bycatch
IWDG 2019_051	CD	Male	220	Adult	Live stranding Infectious disease	Live stranding (hypostatic congestion of lungs). Septic ureteritis Verminous bronchitis and pneumonia	Verminous gastritis Other parasitic infections	Infectious disease Possible live stranding	Infectious disease
IWDG 2019_058	CD	Male	134	Juvenile	Infectious disease Starvation	Verminous bronchitis and pneumonia Poor body condition Lack of recent feeding	Mild trematodal( <i>Pholeter</i> sp.) gastritis	Infectious disease - pneumonia Poor body condition	Infectious disease
IWDG 2019_059	CD	Male	155	Juvenile	Not established	Not apparent	Verminous gastritis Verminous bronchitis	Not established - histopathology required	Not established
IWDG 2019_061	CD	Female	150	Sub-adult	Live stranding	Hypostatic congestion of lungs Ventral erythema	Trematodal gastritis Verminous bronchopneumonia	Live stranding	Live stranding
IWDG 2019_063	HP	Female	107.5	Juvenile	Starvation	Poor body condition	Endoparasitism	Starvation - histopathology required to establish cause	Starvation

IWDG code	Species	Sex	Length	Tentative age/maturity Category	Preliminary COD categories	Significant disease or conditions	Incidental diseases or conditions	Validated COD	Finalised COD categories
IWDG 2019_065	HP	Male	147	Adult	Not established	Not apparent	<p>Verminous gastritis with ulceration.</p> <p>Chronic trematodal mural gastritis</p> <p>Chronic trematodal hepatitis with bile duct fibrosis.</p> <p>Dental wear/decay</p>	Not established – High level of scavenging and relatively autolysed	Not established
IWDG 2019_078	HP	Male	111	Juvenile	Starvation	Poor nutritional condition	<i>Pholetergastrophila</i> gastritis	Starvation - histopathology required to establish cause	Starvation
IWDG 2019_088	CD	Female	174	Juvenile	Not Established - Suspected Bycatch	Intravascular gas bubble formation	<p>Verminous bronchitis and pneumonia</p> <p>Parasitic gastritis</p>	<p>Not established</p> <p>Possible bycatch</p>	Not Established - Suspected Bycatch
IWDG_2019_092	CD	Male	200	Sub-adult	Bycatch	Laceration to tail stock/tail fluke	<p>Verminous gastritis</p> <p>Verminous bronchitis and pneumonia</p>	Bycatch – Multifilament net (trawler)	Bycatch
IWDG 2019_093	CD	Male	198	Sub-adult	Bycatch	Linear lacerations on rostrum / pectoral fins.	Verminous gastritis	Bycatch – Multifilament net (trawler)	Bycatch
IWDG 2019_104	CD	Male	133	Juvenile	Starvation	Poor body condition	Verminous bronchitis	Starvation - histopathology required to establish cause	Starvation

IWDG code	Species	Sex	Length	Tentative age/maturity Category	Preliminary COD categories	Significant disease or conditions	Incidental diseases or conditions	Validated COD	Finalised COD categories
IWDG 2019_120	CD	Female	189	Adult	Bycatch	Lacerations and partial amputation of dorsal fin Gas bubbles present throughout	Verminous gastritis with ulceration Verminous bronchitis and pneumonitis	Bycatch	Bycatch
IWDG 2019_127	SD	Male	215	Adult	Probable live stranding	None	None	Live stranding	Live stranding
IWDG 2019_147	CD	Male	93	Neonate	Maternal separation	Separation from the dam and consequent starvation/hypoglycaemia	<i>Acinetobacter lwoffii</i> isolate significance unknown without histopathology	Maternal separation. Histopathology required to confirm significance of <i>Acinetobacter lwoffii</i> isolate	Starvation (neonate)
IWDG 2019_151	CD	Male	238	Adult	Poor body condition	Very poor body condition Verminous gastritis Arthritis – atlanto-occipital joint	Verminous bronchitis	Infectious disease Degenerative joint disease Poor body condition	Infectious disease
IWDG 2019-158	HP	Female	111	Juvenile	Bycatch	Found entangled in fishing nets	None – marked decomposition	Bycatch - entanglement	Bycatch
IWDG 2019_159	CD	Male	96	Calf	Live stranding Maternal separation	Erythema/bruising to ventral surface	None	Maternal separation Possible terminal live stranding – histopathology required to confirm	Maternal separation



IWDG code	Species	Sex	Length	Tentative age/maturity Category	Preliminary COD categories	Significant disease or conditions	Incidental diseases or conditions	Validated COD	Finalised COD categories
IWDG 2019_176	CD	Female	199	Adult	Infectious disease Possible live stranding	Stenosis of pyloric stomach Asymmetrical congestion of lungs indicative of possible live stranding Moderate-poor body condition	Verminous gastritis Verminous pneumonia and bronchitis <i>Phyllobothrium</i> sp. burden <i>Monorygma</i> sp. burden	Stenosis presumably associated with parasitic burden of stomach wall.  Extensive ulceration of cardiac stomach & parasitic gastritis likely contributors to poor body condition	Infectious disease
IWDG 2019_177	CD	Male	Adult	229	Possible live stranding	Erythema/bruising on ventral surface, asymmetrical congestion of lungs Moderate-poor body condition	Verminous gastritis with ulceration Focal suppurative pneumonia <i>Aeromonas bestiarum</i> isolated from purulent matter	Possible live stranding	Live stranding
IWDG 2019_180	HP	Male	123	Sub-adult	Physical trauma (possible bycatch)	Severe trauma resulting in multiple/extensive fracturing of ribs, lacerations on dorsal fin, redsclera, retroperitoneal gas bubbles	Verminous pneumonia and bronchitis	Physical trauma	Physical Trauma – Suspected Bycatch
IWDG 2019-181	CD	Male	198	Adult	Hepatic gas bubble disease	Severe hepatic gas bubble lesions  Mild and more acute retroperitoneal gas bubbles	Verminous bronchitis and gastritis <i>Phyllobothrium</i> sp. and <i>Monorygma</i> sp infections	Hepatic gas lesions	Other - Hepatic gas bubble disease
IWDG 2019_184	HP	Female	153	Adult	Physical trauma (bottlenose dolphin attack)	Multiple fractures, haemothorax, pneumothorax, rake marks consistent with bottlenose dolphin	Verminous bronchitis, gastritis, and hepatitis	Physical trauma (bottlenose dolphin attack)	Physical trauma - Bottlenose Dolphin Attack

### *Case history reporting*

Case history reports from the 44 individuals and their associated material were submitted to the IoZ to provide independent oversight on each case. One common dolphin was found to be in an advanced state of decomposition at time of necropsy and was therefore excluded from post-mortem analyses.

### Common dolphin

Of the 30 common dolphins collected for necropsy, 57% (17/30) were sexed as male and 43% (13/30) as female. Males and females ranged in total body length from 93-238 cm and 107.5-207 cm, respectively.

One of the two most common causes of death for common dolphins was ‘**infectious disease**’, representing 23% of the sample size. The other most common cause of death was “**bycatch**”, also 23%. There were three additional cases of “**not established (suspected bycatch)**”.

There was one case of “**physical trauma (suspected bottlenose dolphin attack)**” which was quite interesting, as IWDG have recently documented several cases of bottlenose dolphins interacting in a seemingly aggressive manner with common dolphins. This was historically reported occurring in Irish waters (Murphy et al. 2005)

“**Hepatic gas bubble disease**” was found to be the cause of death for one adult male. For all cause of death categories, see Table 3.



**Figure 7. Adult common dolphin with tail cut off. Photo Nick Massett.**

### Striped dolphin

Five striped dolphins were retrieved for post-mortem examination comprising four males and one female. Of the five individuals, one adult male was a known live stranding (IWDG 2019-127).

The length of the female was 152 cm, and the lengths of the males ranged from 151 – 215 cm.

Cause of death for two of these animals was found to be “**suspected live stranding**”, with another case found to be “**suspected live stranding due to starvation**” as the animal was in very poor nutritional

condition. One additional case was a confirmed live stranding. The fifth animals' cause of death was not established.

#### Harbour porpoise

Nine harbour porpoises were retrieved for post-mortem examination during the sampling period. One female was found entangled in a monofilament net (IWDG 2019-158) (Figure 8). Lengths for males and females ranged from 111 – 147 cm, and 108 – 153 cm respectively.

The top three cause of death categories for harbour porpoises were “**bycatch**” (n=2), “**infectious disease**” (n=2), and “**starvation**” (n=2), followed by “**physical trauma (suspected bottlenose dolphin attack)**” (n=1), **physical trauma (suspected bycatch)** (n=1), and one case was **not established**.



**Figure 8. Harbour porpoise in monofilament netting. Photo. James Kenny.**

**Table 3. Cause of death categories for all necropsied animals.**

COD Categories	Species			Total
	CD	SD	HP	
Bycatch	7	0	2	<b>9</b>
Live Stranding	3	1	0	<b>4</b>
Infectious Disease	7	0	2	<b>9</b>
Starvation	3	0	2	<b>5</b>
Starvation – Neonate	1	0	0	<b>1</b>
Maternal Separation	1	0	0	<b>1</b>
Physical Trauma - Suspected Bottlenose attack	1	0	1	<b>2</b>
Physical Trauma - Suspected Bycatch	0	0	1	<b>1</b>
Other - Hepatic Gas Bubble Disease	1	0	0	<b>1</b>
Not Established - Suspected Infectious Disease	1	0	0	<b>1</b>
Not Established - Suspected Live Stranding	0	2	0	<b>2</b>
Not Established - Suspected Bycatch	3	0	0	<b>3</b>
Not Established – Suspected live Stranding due to Starvation	0	1	0	<b>1</b>
Not Established	2	1	1	<b>4</b>
<b>Total</b>	<b>30</b>	<b>5</b>	<b>9</b>	<b>44</b>

## DATA COLLECTION FRAMEWORK

No bycaught animals were reported by the DCF observers to the Project Coordinator during from 1 January to 1 December 2019.

## Discussion

We successfully recovered and necropsied the target of 44 animals, as well as the supplied seven biopsy kits and 50 biopsy punches to DCF observers. The case history reports of all 44 animals were sent to the Institute of Zoology, London for review and returned with associated comments.

One of the two most frequent cause of death (CoD) categories for all animals was **infectious disease**, representing 20% of all cases. In the future, if this project is to continue, it would be advisable to carry out further analyses of those with this CoD to examine these cases in more depth, such as undertaking histopathological assessment. This would allow researchers to gain insight into any pathological trends of concern.

The other most frequent CoD was **bycatch**, also representing 20% of those sampled. The majority involved common dolphins (n=7). In addition, there were three cases of **suspected bycatch** and one case of **physical trauma (suspected bycatch)**, bringing the total of both **confirmed and suspected bycatch** cases to 30% for the whole sample.

The majority of the animals collected for necropsy were recovered from County Kerry, most likely due to the well-established network of IWDG members reporting from that area and the high number of strandings in this county.

**Common dolphins** represented 69% of the animals recovered. Prior to 2011, numbers of common dolphin strandings were similar to those of harbour porpoises, being either the first or second most frequently reported species each year (McGovern *et al.* 2016). Since 2011, recorded strandings for this species have increased out of proportion with other cetaceans. Between 2006 and 2010, the IWDG received 134 records for this species; an average of 27 animals per year. However, in the years 2013 to 2019, 595 common dolphin strandings were recorded averaging 85 per year (IWDG Stranding Network). The reason for this remains unclear, although interactions with pelagic trawl fisheries have been identified (Anon 2013). Common dolphin strandings occur mainly on the west and south coasts and peak in the months of January, February, March and December (McGovern *et al.* 2016). Although this could in part be due to increased observer effort over the years, if this were the only explanation, we would expect a similar increase to be reported for other dolphin species. There is recent evidence of an increase in common dolphin abundance in inshore waters to the south of Ireland in the Bay of Biscay (Astarloa *et al.* 2021), which has been associated with changes in climate indices and prey biomass. If a similar increase has occurred further north off Ireland, this may in some part explain increased stranding rates as strandings would increase with increased abundance. In recent years, a large scale increase in the abundance of common dolphins was reported in the North-east Atlantic, with more than 467,673 common dolphins observed throughout the North-east Atlantic in July 2016 during the SCANS-III survey, in addition to 13,632 dolphins in Irish waters, as part of the ObSERVE project; compared to 56,221 common dolphins reported for shelf waters for the year 2005, and 116,709 common dolphins for offshore waters for the year 2007. This may be due to a large-scale re-

distribution in the region, include latitudinal or offshore–inshore movements, or a mixture of the two (Murphy et al. 2019).

**Harbour porpoises** are consistently the second most frequently stranded cetacean species in Ireland, only recently been surpassed by the common dolphins. They have been recorded stranded on all coasts, although higher rates along the south and east coasts have been reported with peaks in strandings from December to March (McGovern *et al.* 2016). The east coast was not sampled during this project as it was excluded from the tender area. Stranding records have shown a consistent trend with around 30 reported per year in Ireland (IWDG, 2017).

**Striped dolphin** strandings are less frequent relative to other cetacean species, accounting for around 5% of all strandings in a typical year. Since 2010, 118 stranding records were received for this species; an annual average of slightly more than 11 animals. This varied from a low of 8 records in 2012 to a peak of 18 in 2014. Small numbers of strandings are recorded throughout the year, mainly from the south and west coasts (IWDG Stranding Network).

**Table 4. Summary of animals collected from 2017 to 2019.**

	2017	EXTENTION	2018	2019	TOTAL
Lot 1	13	7	21	22	63
Lot 2	11	12	9	23	55
Male	14	8	17	25	64
Female	9	11	13	19	52
CD	19	17	17	31	84
SD	2	1	7	5	15
HP	3	1	6	9	19
Found dead	14	16	28	44	102
Found alive	10	3	2	1	16

A rise in the number of confirmed and suspected bycatch cases in 2019 is apparent when comparing results from 2017 and 2018. In 2017/2018 we reported 13.7% of CoD as bycatch, compared to 29.5% in 2019. There are several possible explanations for this, the first one being that more animals were sampled in 2019 at the height of the winter peak from January to March (n=28) compared to the previous year (n=19) and over half of all bycatch cases in 2019 were collected during this peak stranding period. In addition, the animals collected during the winter peak in 2019 were overall in better condition compared to those in 2017/2018. This was most likely due to the fact that there was far less pressure to collect a target number of animals in a much shorter period of time as was the case during 2017 and 2018. Carcass condition can significantly affect the pathologist’s ability to identify bycatch, as the evidence can be quite subtle, and become increasingly difficult to observe and diagnose as decomposition progresses. The pressure to reach a target number of animals in a shorter period of time during 2017/2018 also led to the use of frozen animals which were collected outside of the tender period, as well as the collection of more live stranded individuals; 15 known cases compared to just one in 2019. It is generally assumed that live stranded animals are far less likely to have stranded due to interaction with fishing gear.

This scheme has demonstrated that it is possible to recover a sample of stranded dolphins and porpoises and transport to a Regional Veterinary Lab in a timely manner for post-mortem examination. It has also demonstrated an effective collaboration between a state agency, third level institute and a non-government organisation. This reflects well for a continuation of necropsies of stranded cetaceans to provide a longer time series including inter-annual and seasonal coverage and a significant sample size.

Consideration should be given to extend this programme to include **bottlenose dolphins** (*Tursiops truncatus*), an Annex II species requiring special conservation measures, and other species which, although strand infrequently, would be of ecological interest (e.g. **Atlantic white-sided dolphin** (*Lagenorhynchus acutus*), **white-beaked dolphin** (*Lagenorhynchus albirostris*)).

In addition, the geographic scope of sampling should be extended to include the east coast, in order to increase the number of harbour porpoises obtained for necropsy. Two porpoises management units/assessment units have been proposed for Irish waters, west Scotland/Ireland and Celtic and Irish Seas (NAMMCO & IMR, 2019). Thus, sampling of the east coast would be required for a full assessment of the Celtic and Irish Seas management unit/assessment unit.

Further recommendations for future work would include the provision of additional resources in order to continue providing bacteriology and histopathology assessment services, as one of the most common causes of death for this contract was **infectious disease**. For several cases, this was generously carried out by the RVL, and was instrumental in determining causes of death for those animals.

The number of animals presenting with signs of bycatch was quite high and worthy of further investigation. We recommend the establishment of a long term post-mortem scheme in order to examine the trend in causes of death, including the contribution from fisheries bycatch, by gathering the necessary evidence to advise government on potential mitigation efforts. It is advisable to monitor and examine a certain percentage of stranded cetacean species in order to monitor the general health of Ireland's cetaceans, and identify, as this project has done, any trends which need to be addressed.

A delay with reporting arose due to constrained resources at the Regional Veterinary Laboratory in Cork, specifically available personnel. As the involvement of the RVL was voluntary and in addition to their ongoing obligations, this put significant pressure on one pathologist to carry out and report on all of the post-mortem examinations. If the post mortem scheme was to continue, we recommend there be multiple pathologists formally dedicated to the scheme to ensure reports are returned in an appropriate timeframe, and that a contract be negotiated to provide these pathological services.

## Acknowledgements

The Marine Biodiversity Scheme is established under Union Priority 1 (Sustainable Fisheries) and Union Priority 6 (Integrated Maritime Policy) of Ireland's Operational Programme (OP) under the EMFF and is co-funded by the Irish Government and the EU. We would like to thank the Contracting Management and Steering Group, especially Drs Leonie O'Dowd, Helen McCormick and Oliver Tully of the Marine Institute and Drs Oliver Ó Cadhla, Ferdia Marnell and David Tierney of the NPWS.

We would like to thank Barry Keane, Mark Reader, Gary Kett, Meadhbh Quinn, Nick Massett, Louise Overy, Tony Murray and Frances Bermingham for providing assistance in recovering animals. We would like to thank the IWDG stranding network members whose records made this contract possible, and the DCHG for funding the IWDG Stranding Scheme. Finally, we would like to acknowledge the support of Michéal Casey and the RVL staff at RVL Cork, Cosme Sanchez and Aideen Kennedy, for providing additional support during necropsy examinations.

## References

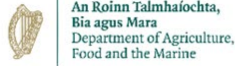- Anonymous (2013) Results of post-mortem examinations on five common dolphins (*Delphinus delphis*) from Mayo, February 2013.
- Astarloa, A., Louzao, M., Andrade, J., Babey, L., Berrow, S., Boisseau, O., Brereton, T., Dorémus, G., Evans, P.G.H., Hodgins, N.K., Lewis, M., Martínez-Cedeira, J., Pinsky, M.L., Ridoux, V., Saavedra, C., Santos, M.B., Thorson, J.T., Waggitt, J.J., Wall, D. and Chust, G. (2021) The Role of Climate, Oceanography, and Prey in Driving Decadal Spatio-Temporal Patterns of a Highly Mobile Top Predator. *Front. Mar. Sci.* 8:665474. DOI: 10.3389/fmars.2021.665474
- De Quirós, B., Yara, González-Díaz, Ó., Saavedra, P., Arbelo, M., Sierra, E., Sacchini, S., Jepson, P., Mazzariol, S., Di Guardo, G., Fernández, A. (2011) Methodology for *in situ* gas sampling, transport and laboratory analysis of gases from stranded cetaceans. *Scientific Reports* 1 DOI: 10.1038/srep00193
- CSIP (2016) Annual Report for the period 1st January – 31st December 2015. Defra and the Devolved Administrations contract MB0111 (2011-2016).
- Davison, N.J., Cranwell, M.P., Perrett, L.L., Dawson, C.E., Deaville, R., Stubberfield, E.J., Jarvis, D.S. and Jepson, P.D. (2009) Meningoencephalitis associated with *Brucella* species in a live-stranded striped dolphin (*Stenellacoeruleoalba*) in south-west England. *Veterinary Record* 165, 86-89.
- González, L., Patterson, I.A., Reid, R.J., Foster, G., Barberán, M., Blasco, J.M., Kennedy, S., Howie, F.E., Godfroid, J., MacMillan, A.P., Schock, A., Buxton, D. (2002) Chronic meningoencephalitis associated with *Brucella* sp. infection in live-stranded striped dolphins (*Stenellacoeruleoalba*). *Journal of Comparative Pathology* 126(2-3):147-52.
- Irish Whale and Dolphin Group. Accessed 02 January 2017.  
[www.iwdg.ie/conservation/?speciesed=2217](http://www.iwdg.ie/conservation/?speciesed=2217).
- Jepson, P.D., Arbelo, M., Deaville, R., Patterson, I.A.R., Castro, P., Baker, J.R., Degollada, E., Ross, H.M., Herráez, P., Pocknell, A.M., Rodríguez, E., Howie, F.E., Espinosa, A., Reid, R.J., Jaber, J.R., Martin, V., Cunningham, A.A., and Fernandez, A. (2003) Gas-bubble lesions in stranded cetaceans. *Nature*, 425, 575-576.
- Jepson, P.D., Deaville, R., Patterson, I.A.R., Pocknell, Ross, H.M., Baker, J.R., Howie, F.E., Reid, R.J., Colloff, A. and Cunningham, A.A. (2005) Acute and chronic gas bubble lesions in cetaceans stranded in the United Kingdom. *Veterinary Pathology* 42: 291-305
- Kuiken, T. and Garcia Hartmann, M. (eds.) (1991) Proceedings of the first European Cetacean Society workshop on cetacean pathology: dissection techniques and tissue sampling. ECS newsletter 17, Special issue: 39pp
- Kuiken T, Simpson VR, Allchin CR, Bennet PM, Codd GA, Harris EA, Howes GJ, Kennedy S, Kirkwood JK, Law RJ, Merrett NR, Phillips S (1994) Mass mortality of common dolphins (*Delphinus delphis*) in south west England due to incidental capture in fishing gear. *Veterinary Record* 134:81-89
- Kuiken, T. (editor). (1996) Diagnosis of By-catch in cetaceans. Proceedings of the Second ECS Workshop on cetacean pathology, Montpellier, France, 2 March 1994.



- Marine Institute. (2017) Invitation to Tender to the Supply of Vertebrate Necropsy and Sample Recovery services to the Marine Institute, Rinville, Oranmore, Co. Galway. Ref: ITT17-024
- McGovern, B., Culloch, R.M., O'Connell, M and Berrow S. (2016) Temporal and spatial trends in strandings records of cetaceans on the Irish coast, 2002-2014. *Journal of the Marine Biological Association of the United Kingdom*. DOI: <https://doi.org/10.1017/S0025315416001594>
- Murphy, S. (2004) The biology and ecology of the common dolphin *Delphinus delphis* in the North-east Atlantic. PhD thesis, University College Cork, Ireland.
- Murphy, S., Mirimin, L., Englund, A., and M. Mackey. 2005. Evidence of a violent interaction between *Delphinus delphis* L. and *Tursiops truncatus* (Montagu). *Irish Naturalists' Journal* 28(1): 42-43.
- Murphy, S., Pinn, E., and Jepson, P. (2013) The short-beaked common dolphin (*Delphinus delphis*) in the North-eastern Atlantic: distribution, ecology, management and conservation status. *Oceanography and Marine Biology: An Annual Review* 51: 193-280.
- Murphy, S., Evans, P.G.H., Pinn, E., and G.J. Pierce. 2019. Conservation management of common dolphins: lessons learned from the North-east Atlantic. *Aquatic Conservation: Marine and Freshwater Ecosystems* 1-30.
- NAMMCO, & IMR. (2019) North Atlantic Marine Mammal Commission and the Norwegian Institute of Marine Research. Report of Joint IMR/NAMMCO International Workshop on the Status of Harbour Porpoises in the North Atlantic. Tromsø, Norway.
- National Oceanic and Atmospheric Administration. Accessed 01 December 2017. [http://www.nmfs.noaa.gov/pr/health/commondolphins\\_massachusetts2012.htm](http://www.nmfs.noaa.gov/pr/health/commondolphins_massachusetts2012.htm)
- Westgate AJ, Read AJ (2007) Reproduction in short-beaked common dolphins (*Delphinus delphis*) from the western North Atlantic. *Marine Biology* 150:1011-1024

## Appendices

### Appendix I: IWDG Case History Cover Page



# Case History Report

IWDG Stranding Code: \_\_\_\_\_

Species: \_\_\_\_\_

Date of Necropsy: \_\_\_\_\_

Pathologist(s): \_\_\_\_\_

**Case History** (Provide brief summary of where/how the animal was initially found and necropsy results):

**Cover photo:**

Approved by PI: \_\_\_\_\_ Date: \_\_\_\_\_

Approved by IoZ: \_\_\_\_\_ Date: \_\_\_\_\_

## **Appendix II: CSIP Guidelines for the Postmortem Examination and Tissue Sampling of Cetaceans during Stranding Events**

### **CONTENTS**

- a) Introduction**
- b) Basic measurements**
- c) External examination**
- d) Examination of abdominal organs (except G.I. tract, pancreas, and spleen)**
- e) Examination of organs of head, neck and thorax**
- f) Examination of the G.I. tract, pancreas and spleen**

### **a) Introduction**

These guidelines are meant primarily as an aid to veterinary surgeons carrying out post-mortem examinations on stranded cetaceans involved in the UK. Post-mortem examinations are carried out under the aegis of the UK Cetacean Strandings Investigation Programme, which is jointly funded by Defra and the Devolved Administrations. This protocol is based partly on guidelines written by Dr John Baker and Dr Thijs Kuiken and partly on the protocol produced at the European Cetacean Society workshop on cetacean pathology, held in Leiden, The Netherlands, in September 1991<sup>4</sup>.

All structures must be examined visually and by palpation, making incisions into the organs. A full post-mortem record must be kept, preferably on the standard "Cetacean Post-mortem Report" form for recording animals involved in a stranding.

Lesions in any organs should be described, photographed and sampled. The description should include the size, location, colour, texture, shape, and the nature of the transition from normal to abnormal tissue. Photographs should include a ruler, scale bar or similar object to indicate the size of the lesion. According to the suspected aetiology of the lesion, samples should be collected for bacteriological examination (especially if the lesion is of a purulent nature) or for virological examination. In all cases, a sample of the lesion should be preserved for histopathological examination.

The post-mortem examination need not take place in the order described below. However, samples for bacteriological and virological examination need to be taken as early as possible. Also, examination of the G.I. tract should be left until last to prevent cross-contamination with enteric micro-organisms.

Paul Jepson and Rob Deaville  
London, January 2010

---

<sup>4</sup>Kuiken, T. and Garcia Hartmann, M. (eds.) (1991) Proceedings of the first European Cetacean Society workshop on cetacean pathology: dissection techniques and tissue sampling. ECS newsletter 17, Special issue: 39pp

## b) Basic measurements

<b>photographs</b>	Photographs should be taken of the lateral views of the whole body, from both sides. Particularly in bottle-nosed dolphins, photographs should be taken of the dorsal fin, also from both sides. In baleen whales, the ventral side of the tail flukes should be photographed. Photographs should also be taken of any lesions of interest found during the post-mortem, including the use of a scalebar.
<b>body condition</b>	Estimate the body condition- that is the state of decomposition of the carcass, using the categories of the condition code <sup>5</sup> . Where possible, note the presence and extent of rigor mortis.
<b>body weight</b>	If recording the body weight is impossible, collect the heart weight so that the body weight can be estimated <sup>6</sup> .
<b>body length</b>	Measure the body length by placing the carcass on its belly, holding a measuring tape or ruler next to the carcass in a straight line parallel to the longitudinal body axis and measuring the distance between the notch in the tail flukes and the tip of the upper jaw.
<b>body girth</b>	Measure the body girth at the level of the anterior insertion of the dorsal fin. If it is impossible to move the carcass, a half circumference measurement may be taken and doubled.

## c) External examination

<b>nutritional state</b>	Indicate the nutritional state of the carcass, using one of the following three categories: -good: the aspect of the upper flanks on either side of the dorsal fin is rounded; -moderate: the aspect of the upper flanks on either side of the dorsal fin is sloping; -poor: the aspect of the upper flanks on either side of the dorsal fin is hollow (in these animals, one can make out the transverse processes of the lumbar vertebrae, and there is an indentation dorsally just behind the head).
--------------------------	---

---

<sup>5</sup>The body condition, or state of decomposition of a carcass, can be described using the following condition code:

- 1) **live** (*becomes code 2 at death*)
- 2a) **extremely fresh** (*as if just died, no bloating, meat is considered by most to be edible*)
- 2b) **slight decomposition** (*slight bloating, blood imbibition visible*)
- 3) **moderate decomposition** (*bloating, skin peeling, penis may be extended in males, organs still intact, excluding postmortem damage*)
- 4) **advanced decomposition** (*major bloating, skin peeling, penis extended in males, organs beyond recognition, bones exposed due to decomposition*)
- 5) **indeterminate** (*mummified carcass or skeletal remains, no organs present*)

<sup>6</sup> The body weight can be estimated from the heart weight using the formula  $\log W = (\log H + 2.2) / 0.984$ , with H = heart weight and W = body weight, both in kg.

**body orifices** Examine the body orifices (mouth, eyes, ear openings, blow-hole, anus, genital slit and mammary slits) for lesions and any discharge. Collect and preserve left and right eyes separately in 10% formalin if lesions are noted.

**epidermis** Examine the animal for external lesions, including evidence of physical trauma and/or fresh contra- or con-specific rakemarks and photograph and sample these accordingly. Examine the skin carefully for any ectoparasites. These are most likely to be found in or near the body orifices and next to the fins and flukes. Take a 4 cm<sup>2</sup> piece of epidermis down to the blubber for DNA-studies, and freeze.

**milk** Massage the skin in the area cranial to the mammary slits in a caudal direction to express any fluid present in the mammary glands. Note the volume, colour, and consistency of the fluid.

**blubber** Cut a transverse strip of blubber about 2 cm wide from the anterior insertion of the dorsal fin, from the mid-dorsal to the mid-ventral region. Make sure to cut at right-angles to the surface of the skin. Measure the thickness of the blubber strip with a ruler 2cm lateral to the dorsal mid-line, mid-laterally, and 2cm lateral to the ventral mid-line. (Using this method, the tension of the blubber tissue is relieved before measuring.)

Cut a strip of blubber a few cm wide and a few cm long at the level of the caudal insertion of the dorsal fin. Make sure to cut at right-angles to the surface of the skin. From this blubber strip, take 2x20 g cross-sectional samples of blubber for organochlorine analysis. It is important to take samples of the whole layer, from the skin to the muscle. Wrap them in hexane-washed aluminium foil and freeze. Alternatively, they can be placed in Sovirel glass tubes.

**muscle** Take 2x20 g muscle samples for toxicological analysis, at the same location as and directly below the blubber sample, at the level of the caudal insertion of the dorsal fin. Wrap them in hexane-washed aluminium foil and freeze. Alternatively, they can be placed in Sovirel glass tubes. Take a 1 cm<sup>3</sup> sample of both the longissimus dorsi and abdominal muscle in 10% formalin (for histopathology).

With the animal on its right side (if possible) make a mid-line ventral incision from the symphysis of the mandible to a short distance posterior of the anus, circumventing the genital slit and anus. From the posterior end of the ventral incision make a second one almost to the dorsal mid-line. Reflect the skin and blubber off the uppermost side. Any parasites in the blubber should be noted. They may occur as white cysts less than 1 cm in diameter, often in the ano-genital region or the dorsal aspect of the chest wall.

**mammary gland** In females, examine the mammary gland for pathological changes and parasites. Collect a cross-sectional slice of about 1 cm thick from halfway along the length of the left mammary gland for histopathological examination, and place in 10% formalin.

**subcutaneous tissue** Examine the subcutaneous tissue for the presence of bruises and parasites.

**scapula** Remove the left scapula.

**d) Examination of abdominal organs (except G.I. tract, pancreas, and spleen)**

Remove the left abdominal wall, freeing the testis or ovary and uterus. Any parasites in the abdominal wall (for instance cysts under the peritoneum) should be noted. Remove the left thoracic wall, for example with bone shears.

**virology samples**

Before handling the internal organs, take a 1 cm<sup>3</sup> sample of lung tissue from the cranio-ventral part of the left lung and a 1cm<sup>3</sup> sample of kidney tissue from the left kidney for virological examination. Also take a sample of lung tissue from the cranio-ventral part of the left lung, a sample of kidney tissue from the left kidney and a sample of liver tissue from the left lobe of the liver for bacteriological examination.

**bacteriology samples**

**gas bubbles in the mesentery**

Examine the gastrointestinal tract for any abnormalities including gas bubbles in the mesenteric and intestinal veins. If any are present, take photos with a scalebar and sample tissue for histological examination.

**pericardial fluid/serum**

Sever the intestine close to the anus and the oesophagus close to the diaphragm. Working forward along the dorsal aspect of the abdominal cavity, remove the stomach, intestines, pancreas, spleen and mesenteric lymph node, attached to each other, from the carcass. Leave the examination of the G.I. tract to the end of the post-mortem examination to prevent cross-contamination of other tissues with enteric micro-organisms.

**urinary bladder**

Collect sample of pericardial fluid after incising the pericardial sac. Collect any blood present in the heart lumen, to obtain serum for serological examination. Even if it is haemolytic, it is still of value.

**female reproductive tract**

Open and examine the bladder in situ, noting the contents, if any. Preserve a 1cm<sup>3</sup> sample of the bladder in 10% formalin (for histopathology).

**foetus**

In females remove the entire reproductive tract, open the vagina and uterus, note any corpora lutea, corpora albicantia or follicles on each ovary and then place the ovaries separately in 10% formalin for reproduction studies. Preserve a 1cm<sup>3</sup> sample of the uterus in 10% formalin (for histopathology). Describe the state of sexual maturity.

**male reproductive tract**

If a foetus is present, record the weight, length, sex and the state of decomposition. The whole foetus and its placenta can be wrapped in hexane-washed aluminium foil and stored frozen for organochlorine analysis.

**adrenal glands**

In males remove the testes and weigh them separately after removing the epididymis. After incision and examination, place the testes in 10% formalin for reproductive studies. Place a cross-sectional slice about 1 cm thick from mid-way along the length in 10% formalin. Examine the penis and preputium. Describe the state of sexual maturity where possible, final confirmation may be dependent on histological examination.

**kidneys**

Remove and examine the adrenal glands, and place a cross-sectional slice about 1 cm thick from the middle of the left adrenal gland in 10% formalin.

Examine the peri-renal vasculature for any gas bubbles. Describe and photograph if present and take samples of any associated lesions for histological examination. Remove the kidneys from the body cavity and weigh them. Incise both kidneys longitudinally, and if possible, strip the capsule. Then, take 2x20 g samples for toxicological analysis

**liver**

from halfway the length of the left kidney. These samples should be cross-sectional and include both medullary and cortical tissue. Wrap them in hexane-washed aluminium foil and freeze. Alternatively, they can be placed in Sovirel glass tubes. Preserve 1 cm<sup>3</sup> from a kidney in 10% formalin for histopathological examination.

Examine the liver for any evidence of gas cavities beneath the capsule. Describe and photograph if present. Remove and weigh the liver. Examine both surfaces and make multiple incisions into the substance. Examine the parenchyma for the presence of any gas cavities. Describe and photograph if present and take samples of any associated lesions for histological examination. Examine the bile ducts for parasites. Then, take 2x20 g for trace metal analysis. Wrap them in hexane-washed aluminium foil and freeze. Alternatively, they can be placed in Sovirel glass tubes. Place 1 cm<sup>3</sup> of liver tissue in 10% formalin for histopathological examination.

**thyroid**

**e) Examination of organs of head, neck and thorax**

Carefully remove the superficial muscles overlying the trachea and larynx to expose the thyroid gland. Examine this tissue and preserve 1 cm<sup>3</sup> of tissue in 10% formalin for histopathological examination.

Incise along the internal aspects of both mandibles and free the tongue. Once the tongue is free reflect it backwards and cut the hyoid bones close to the skull.

**tongue**

Free the larynx from the sphincter muscle holding it in place and pulling the tongue backwards incise along the neck to free the trachea and oesophagus. Then, incising dorsally and ventrally in the thoracic cavity, free the heart and lungs. Note any attachments of the lungs to the thoracic walls. This procedure should give you the tongue, larynx, trachea, oesophagus, thymus, heart and lungs all still fastened together.

**oesophagus**

**respiratory tract**

Examine the surface of the tongue.

Open the oesophagus longitudinally and check for lesions or parasites.

**thymus**

Look for evidence of pulmonary hypostasis and photograph if present. Open the larynx, trachea and major bronchi longitudinally. Look for evidence of aspiration of seawater, mud or beach material. Photograph if present. Make multiple incisions into the substance of both lungs. Any parasites may be collected. Two pieces of lung (about 1 cm<sup>3</sup>) from the hilus and periphery of the left lung, and the same from the right lung, should be collected in 10% formalin for histopathological examination. The samples should include part of the major bronchial tree. Open all major branches of the pulmonary veins and examine for the presence of parasites. Examine the bronchial and so-called "pulmonary associated" lymph nodes. The latter can be found about halfway along the ventral edges of each lung. Cut a 1 cm thick cross-sectional slice from the middle of the left pulmonary associated lymph node, and place it in 10% formalin for histopathological examination.

**heart**

Examine the thymus, if present (noting the presence of any macroscopic cysts). Place 1 cm<sup>3</sup> of thymus in 10% formalin for histopathological examination.

**acoustic fat and tympanic bullae**

Separate the heart from the lungs by cutting through the major blood vessels where they enter the heart. Open the left and right ventricles and atria for examination and to take out any blood clots present. Any parasites should be noted. Weigh the heart. Cut a 1 cm thick slice of heart tissue, to include a piece of the wall of the left ventricle and of the atrioventricular septum, and place it in 10% formalin for histopathological examination.

**teeth (baleen plates)**

Examine acoustic fats and note and photograph any haemorrhages. Take a 1 cm<sup>3</sup> section and place in 10% formalin. Examine the tympanic bullae if possible (which in cetaceans are not part of the skull but lie free just behind the mandibles). Carefully dissect each tympanic bulla (and associated cochlea) free of their connective tissue attachments to the skull. Examine the internal cavity of each bulla and note the presence of any nematodes or abnormalities. Preserve the left tympanic bulla/cochlea and right tympanic bulla/cochlea separately in 10% formalin if the carcass is in a suitable condition.

**spinal cord**

If possible, remove two sets of (at least) 4 teeth from the middle of the lower jaw for ageing, and store frozen (separately). (In baleen whales, cut off 2 baleen plates as near as possible to their basis and store frozen.)

**skull**

Remove the head at the atlanto-occipital joint; collect a sample of cervical spinal cord and fix in 10% formalin.

**brain**

If possible, open the skull, and examine the brain. The skull can be opened by making a vertical cut parallel and about 2 cm posterior to the transverse dorsal ridge which is clearly visible and palpable on top of the skull. The second cut should be made in the horizontal plane, through the occipital condyles, making sure to leave the posterior portion of the condyles on the skull, so that the condylo-basal length can still be measured. Both cuts should be extended until they meet each other. The separated piece of skull can then be pried loose using a chisel or flat-bladed screwdriver, and the brain can be removed.

Examine for the presence of bubbles within the vasculature in areas of the brain not damaged during skull excision. Describe and photograph any suspected bubbles/lesions. Take a 1 cm<sup>3</sup> sample of brain for virological examination and bacteriology and morbillivirus samples as described previously. Where possible, place the rest of the brain in 10% formalin for at least a week. To allow faster fixation, a longitudinal incision can be made in the cerebrum to expose the lateral ventricles. When it is fixed, make multiple slices into the tissue to look for pathological lesions, including the presence of parasites. Take 1 cm<sup>3</sup> samples of the cortex, cerebellum, and medulla for histopathological examination. Where possible, dissect the pituitary gland from the pituitary fossa (located in the cranial floor) and preserve in 10% formalin.

**spleen**

Skulls may be stored frozen for morphometrics studies or museum archive. However, examination of the brain and spinal cord takes precedence.

**pancreas**

**f) Examination of the G.I. tract, pancreas and spleen**



**mesenteric lymph node**

Examine and weigh the spleen and put a piece (about 1 cm<sup>3</sup>), including a section of capsule, in 10% formalin for histopathological examination. One often finds smaller accessory spleens near to the main spleen.

**stomach**

Examine the pancreas. Look for parasites, particularly in the pancreatic ducts. Place a 1 cm<sup>3</sup> piece of pancreas tissue in 10% formalin for histopathological examination.

Examine the mesenteric lymph node and put a 1 cm thick cross-sectional slice from halfway its length in 10% formalin for histopathological examination.

**intestine**

Open the cardiac section of the stomach. Note and photograph if watery fluid or ingested beach material is present in the lumen. Collect any fish bones, otoliths and other food remains and preserve in 70% ethanol or freeze for prey studies. Any parasites should be noted and the approximate burden described. Describe any lesions, including the distribution and size of any ulcers. Open the fundic and pyloric sections of the stomach. Any food material should be preserved for prey studies as for the cardiac section. Any nodules in the walls of the fundic and pyloric sections should be noted and, if they are found, attempts should be made to express the contents. Any parasites found in the contents should be noted.

Open the intestinal tract at several points along its length. Make note of any contents and/or lesions and any parasites that are found.

## Appendix III: CSIP PM Data collection sheets

### CETACEAN POSTMORTEM REPORT

When this report has been completed, please send a copy to: UK Cetacean Strandings Investigation Programme, The Wellcome Building, Institute of Zoology, Regent's Park, London, NW1 4RY, UK. Tel: 020 7449 6672 or 6691 Fax: 020 7483 2237 email: [rob.deaville@ioz.ac.uk](mailto:rob.deaville@ioz.ac.uk) or [paul.jepson@ioz.ac.uk](mailto:paul.jepson@ioz.ac.uk)

SW NO. : ..... PM NO. : .....  
 SPECIES : ..... SEX : .....  
 LOCATION FOUND : .....  
 DATE FOUND : .. FOUND BY : .....  
 .....  
 PATHOLOGIST : ..... DATE OF PM : .....

FROZEN?: Y / N

#### 1. BASIC MEASUREMENTS

BODY CONDITION USING CONDITION CODE :

Condition code:

- |   |   |
|---|---|
| 1) <b>live</b> (becomes code 2 at death)<br>2a) <b>extremely fresh</b> (as if just died, no bloating, meat is considered by most to be edible)<br>2b) <b>slight decomposition</b> (slight bloating, blood imbibition visible)<br>3) <b>moderate decomposition</b> (moderate bloating, skin peeling, penis may be extended in males, organs still intact, excluding postmortem damage) | 4) <b>advanced decomposition</b> (major bloating, skin peeling, penis extended in males, organs beyond recognition, bones exposed due to decomposition)<br>5) <b>indeterminate</b> (mummified carcass or skeletal remains, no organs present) |
|---|---|

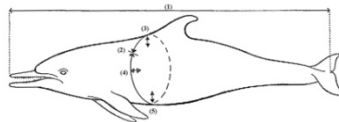
PHOTOGRAPHS TAKEN

- lateral views whole body, both sides: Y/N
- lateral views dorsal fin, both sides: Y/N
- baleen whales: ventral view tail flukes: Y/N
- other photographs (list):
- 
- 

LENGTH, GIRTH AND BLUBBER THICKNESS (see diagram below):

- tip upper jaw to tail notch (cm) (1): . . . . .
- girth in front of dorsal fin (cm) (2): . . . . .
- blubber thickness in front of dorsal fin:
- dorsal mid-line (mm) (3): . . . . .
- lateral (mm) (4): . . . . .
- ventral mid-line (mm) (5): . . . . .

BODY WEIGHT (kg): . . . . .



#### 2. GROSS PATHOLOGICAL EXAMINATION

Encircle the appropriate category:

- NE = not examined
- NAD = nothing abnormal detected
- A = abnormal (describe fully in section 5)

## **EXTERNAL EXAMINATION**

NE NAD A -body orifices  
NE NAD A -fins and flukes  
nutritional state: good / moderate / poor

## **INTEGUMENT**

NE NAD A -epidermis  
NE NAD A -blubber  
NE NAD A -subcutaneous tissue  
NE NAD A -mammary glands

## **MUSCULOSKELETAL SYSTEM**

NE NAD A -skull  
NE NAD A -other bones  
NE NAD A -back muscle mass  
NE NAD A -other muscles

## **NERVOUS SYSTEM**

NE NAD A -brain  
NE NAD A -spinalcord  
NE NAD A -peripheralnerves

## **CARDIOVASCULAR SYSTEM**

NE NAD A -pericardialsac  
NE NAD A -myocardium  
NE NAD A -valves  
NE NAD A -arteries, veins

## **RESPIRATORY SYSTEM**

NE NAD A -nasalcavity  
NE NAD A -sinuses  
NE NAD A -trachea, bronchi  
NE NAD A -lungs  
NE NAD A -pleura/pleuralcavity

## **ALIMENTARY SYSTEM**

NE NAD A -mouth  
NE NAD A -oesophagus  
NE NAD A -cardiacsectionstomach  
NE NAD A -fundic section stomach  
NE NAD A -pyloric section stomach  
NE NAD A -intestine  
NE NAD A -anus  
NE NAD A -liver  
NE NAD A -pancreas  
NE NAD A -peritoneum/peritonealcavity

## **UROGENITAL SYSTEM**

NE NAD A -kidneys  
NE NAD A -ureters  
NE NAD A -urinarybladder  
NE NAD A -urethra  
NE NAD A -ovaries/testes  
NE NAD A -uterus  
NE NAD A -vagina/penis  
NE NAD A -vulva/preputium

## **LYMPHATIC AND ENDOCRINE SYSTEMS**

NE NAD A -adrenal glands  
NE NAD A -thyroid gland  
NE NAD A -spleen  
NE NAD A -thymus  
NE NAD A -lymph nodes

### 3. CHECKLIST OF STANDARD SAMPLES

In each square, enter:  = sample taken

Blank = sample not taken or not present

Record any extra samples taken in section 4.

#### Weights (optional)

left testis (g):.....  
 right testis (g):.....  
 heart (g):.....  
 cardiac section stomach (g):.....

#### S/C's and Parasites

food remains                      Frozen

lung

1 cm<sup>3</sup>

Ethanol

from:                           

.....                           

.....                           

.....

parasites from: (pref. all- stored in ethanol)

.....

.....

.....

.....

.....

.....

#### Freeze at -20°C

epidermis                      4 cm<sup>2</sup>

blubber                      2 x 20g

liver                      2 x 20g

muscle                      2 x 20g

serum or PCF                      up to 20 ml

teeth                      >4 (2 sets)

baleen plates                      >4 plates

urine                      up to 10 ml

faecal material                      up to 50 ml

brain (RNAlater)                      0.5 cm<sup>3</sup>

spleen (RNAlater)                      0.5 cm<sup>3</sup>

lung (RNAlater)                      0.5 cm<sup>3</sup>

#### Virology (freeze at -80°C)

brain                      1 cm<sup>3</sup>

spleen                      1 cm<sup>3</sup>

### 10% Formalin

<input type="checkbox"/> adrenal glands	both
<input type="checkbox"/> bladder	1 cm <sup>3</sup>
<input type="checkbox"/> cerebrum	1 cm slice
<input type="checkbox"/> cerebellum	1 cm slice
<input type="checkbox"/> heart	1 cm <sup>3</sup>
<input type="checkbox"/> kidney	1 cm <sup>3</sup>
<input type="checkbox"/> liver	1 cm <sup>3</sup>
<input type="checkbox"/> lung	1 cm <sup>3</sup> x
<input type="checkbox"/> mammary gland	1 cm slice
<input type="checkbox"/> mesenteric ln.	1 cm slice
<input type="checkbox"/> pancreas	1 cm <sup>3</sup>
<input type="checkbox"/> pulm. ass. ln.	1 cm slice
<input type="checkbox"/> skin and blubber	1 cm <sup>3</sup>
<input type="checkbox"/> spinal cord	1 cm <sup>3</sup>
<input type="checkbox"/> spleen	1 cm <sup>3</sup>
<input type="checkbox"/> testes	both/slices
<input type="checkbox"/> thymus	1 cm <sup>3</sup>
<input type="checkbox"/> thyroid	1 cm <sup>3</sup>
<input type="checkbox"/> uterus	1 cm <sup>3</sup>
<input type="checkbox"/> brain	whole (in 15% formol saline)
<input type="checkbox"/> ovaries	both
(separately if immature)	

### Bacteriology

<input type="checkbox"/> brain	swab/block
<input type="checkbox"/> kidney	swab/block
<input type="checkbox"/> liver	swab/block
<input type="checkbox"/> lung	swab/block
<input type="checkbox"/> spleen	swab/block
<input type="checkbox"/> CSF	swab/fluid

#### 4. LIST OF EXTRA SAMPLES

Extra samples of lesions taken for histological examination (list):

-  
-  
-  
-  
-  
-

Extra samples of lesions taken for bacteriological examination (list):

-  
-  
-  
-  
-  
-

Other extra samples taken (list):

-  
-  
-  
-  
-  
-

Optional (if time and storage allows)

Freeze at -20°C

- |  |             |
|--|-------------|
| <input type="checkbox"/> foetus/placenta | whole       |
| <input type="checkbox"/> scapula         | whole       |
| <input type="checkbox"/> skull           | whole       |
| <input type="checkbox"/> milk            | up to 20 ml |
| <input type="checkbox"/> eyes            | both        |

Virology (freeze at -80°C) or RNA later (freeze at -20°C)

- |  |         |
|--|---------|
| <input type="checkbox"/> pituitary     | section |
| <input type="checkbox"/> cranial nerve | section |

Fixed tissue)

- |   |                            |
|---|----------------------------|
| <input type="checkbox"/> pituitary                        | whole                      |
| <input type="checkbox"/> tympanic bullae/cochlea          | both (only in 2a cases)    |
| <input type="checkbox"/> <i>longissimus dorsii</i> muscle | slice (held under tension) |
| <input type="checkbox"/> <i>rectus abdominus</i> muscle   | slice (held under tension) |

**5. DESCRIPTION OF ABNORMALITIES ON GROSS PATHOLOGICAL EXAMINATION**

(add extra pages if necessary)

PRELIMINARY DIAGNOSIS OF GROSS PATHOLOGICAL EXAMINATION (in order of importance):

- a.
- b.
- c.
- d.
- e.

**6. RESULTS OF HISTOLOGICAL EXAMINATION** (add extra pages if necessary)

**7. RESULTS OF BACTERIOLOGICAL EXAMINATION**

Heart blood: .....

Lung: .....

Liver: .....

Kidney: .....

Other: .....

.....

**8. MISCELLANEOUS RESULTS**

**9. FINAL DIAGNOSIS** (in order of importance):

- a.
- b.
- c.
- d.

## Appendix IV: Final Cetacean Post-Mortem Report

REFERENCE NUMBER: SW2017/  
POST-MORTEM NUMBER:  
HISTOLOGY NUMBER:  
SPECIES:  
SEX:  
DATE FOUND:  
LOCATION FOUND:  
NATIONAL GRID NUMBER:  
DATE OF POSTMORTEM:  
PATHOLOGIST: Rob Deaville

### **1. BASIC MEASUREMENTS**

FROZEN:  
CARCASS CONDITION:  
BODY WEIGHT: kg  
LENGTH, GIRTH AND BLUBBER THICKNESS:

-blubber thickness in front of dorsal fin:

-tip upper jaw to tail notch: cm  
-girth in front of dorsal fin: cm

-dorsal mid-line: mm  
-lateral: mm  
-ventral mid-line: mm

### **2. GROSS POSTMORTEM**

#### External examination

Nutritional state:  
Body orifices:  
Ectoparasites:  
Fins and flukes:

#### Integument

Epidermis:  
Blubber:  
Subcutaneous tissue:  
Mammary glands:

#### Musculoskeletal system

Skull:  
Other bones:  
Back muscle mass:  
Other muscles:

#### Nervous system

Brain:  
Spinal cord:  
Peripheral nerves:

#### Cardiovascular system

Pericardial sac:  
Myocardium:  
Valves:  
Arteries, veins:

#### Respiratory system

Nasal cavity:  
Sinuses:  
Trachea, bronchi:  
Lungs:  
Pleura/pleural cavity:



### Alimentary system

Mouth:  
Oesophagus:  
Cardiac section stomach:  
Fundic section stomach:  
Pyloric section stomach:  
Duodenum/small intestine:  
Large intestine:  
Anus:  
Liver:  
Pancreas:  
Peritoneum/peritonealcavity:

### Urogenital system

Ovaria/testes:  
Uterus:  
Vagina/penis:  
Kidneys:  
Ureters:  
Urinary bladder:  
Urethra:  
Lymphatic and endocrine systems

Adrenals:  
Thyroid:  
Spleen:  
Thymus:  
Lymph nodes:

### **3. HISTOLOGY**

### **4. BACTERIOLOGY**

### **5. MISCELLANEOUS**

### **DIAGNOSIS**

I *Significant diseases or conditions* thought to contribute to the death of the animal

II *Incidental diseases or conditions* not thought to contribute to the death or condition causing it

Comments:

### **6. INSTITUTE OF ZOOLOGY REVIEW PANEL**

Comments:

## Appendix V: IWDG-RVL-GMIT Sample Collection Form

### MI-NPWS PRIORITY SAMPLE CHECK-LIST

ANIMAL ID: \_\_\_\_\_

**Storage notes:**

PARASITES: Whole (70% ethanol)

LESIONS: Histology (1cm<sup>3</sup>) – x1 10% Formalin, Bacteriology (swab/block) – x1 Fridge

TOXICOLOGY: Wrapped in aluminum dull side up

**SKIN (4cm<sup>2</sup>):**

- x1 Frozen -20°C

**BLUBBER:**

- Toxicology (20g) – x2 Frozen -20°C

**MUSCLE:**

- Toxicology (20g) – x2 Frozen -20°C

**KIDNEY:**

- Toxicology (20g) – x2 Frozen -20°C

- Histology (1cm<sup>3</sup>) – x1 10% Formalin

- Virology (1cm<sup>3</sup>) – x1 Frozen -80°C

- Bacteriology (swab/block) – x1 Fridge

**LIVER:**

- Toxicology (20g) – x2 Frozen -20°C

- Histology (1cm<sup>3</sup>) – x1 10% Formalin

- Bacteriology (swab/block) – x1 Fridge

**LUNG:**

- Histology (4 x 1cm<sup>3</sup>) – 10% Formalin

- Bacteriology (swab/block) – x1 Fridge

- Virology (1cm<sup>3</sup>) – 1x Frozen -80°C

**MAIN SPLEEN:**

- Virology (1cm<sup>3</sup>) – x1 Frozen -80°C

- Bacteriology (swab/block) – x1 Fridge

**SERUM OR PCF (Up to 20ml):**

- PCF  OR Serum

**URINE (Up to 20ml):**

- Toxicology – x1 Freeze -20°C

**STOMACH:**

- Whole (Frozen -20°C)

**TEETH (5-10):**

- Frozen -20°C

**REPRODUCTIVE SYSTEMS:**

- R+L testes + epi (5 cm<sup>2</sup> from mid-testes and epi and store in separate labelled pots) Formalin 10%

OR R+L ovaries (whole in separate labelled pots or note differences in external appearance) - Formalin 10%

**BRAIN:**

- Virology (1cm<sup>3</sup>) – x1 Frozen -80°C

**REQUESTED ADDITIONAL SAMPLES/INFORMATION**

**SPLEEN**

- Histology (1cm<sup>3</sup>) – x1 10% Formalin

**GLANDS – HISTOLOGY (10% Formalin):**

- Prescapular lymph node (1cm<sup>3</sup>)
- Thymus (1cm<sup>3</sup>)
- Thyroid (1cm<sup>3</sup>)
- Pulmonary associated lymph node L+R (nick L) (1 cm<sup>3</sup>)
- Adrenal R+L (nick L) (Whole)
- Mammary R+L (nick L) (1cm<sup>3</sup>)

**INTESTINE**

- Last 10 cm (Frozen -20°C)

**FEMALE REPRODUCTIVE TRACT (excl. ovaries)**

- Whole (Formalin 10%)

**MILK (Up to 20ml):**

- Toxicology – x1 Freeze -20°C

**BRAIN**

- Bacteriology (swab/block) – 1x Fridge
- Histology (1cm<sup>3</sup>) – x4 10% Formalin

**ADDITIONAL INFORMATION:**

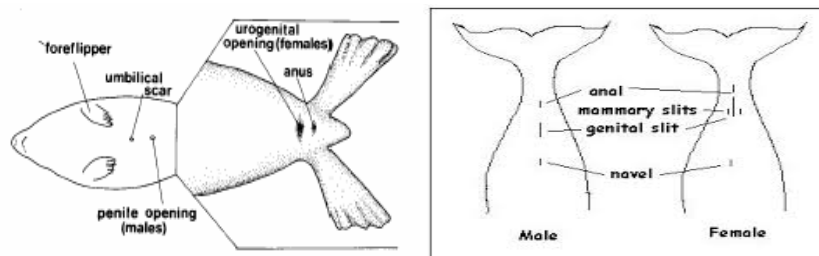
POST-ANAL HUMPH: Photograph + Blubber thickness (mm) \_\_\_\_\_ Muscle thickness (mm) \_\_\_\_\_  
(measurements from where hump is thickest)

**ADDITIONAL SAMPLES:**

<b>SAMPLE</b>	<b>STORAGE (frozen, ethanol etc.)</b>	<b>PURPOSE (B, H, V,T,O)</b>	<b>NO. OF SAMPLES/SIZE</b>	<b>LOCATION (if parasites/lesions)</b>

## Appendix VI: Bycatch Sample Collection Protocol

14. Wear clean non-powdered vinyl gloves provided. To avoid cross-contamination, clean gloves should be used for each carcass.
15. **For birds:** Birds are to be double bagged using the black plastic bags. Fill out one of the labels for the birds and place it on the outside bag. Record details on the bycatch record form.
16. Ask crew where it can be stored (in ice or in freezer (preferable)).
17. **For cetaceans:** Measure the length (in cm) by placing it on its belly and holding the tape measure down parallel to the carcass in a straight line. Measure the distance between the notch in the tail fluke and the tip of the upper jaw - record on the bycatch record form.
18. **For seals:** Place animal on belly and measuring tape parallel to carcass in a straight line. Measure (in cm) from the tip of the snout to the tip of the tail – record on the bycatch record form.
19. **For cetaceans and seals:** For species and sex verification, if possible, take photos of the animals genital area as well as full side views of cetaceans and head profile pictures for seals. Determine the sex and record on the bycatch record form.



20. Complete labels on the zip-lock sample bags (as below) using a permanent pen.
21. Take a sample using the biopsy punch tool immediately in front of dorsal fin for cetaceans, or from the sternal region on the seals. Push it in far enough so the entire metal end of the tool is full of blubber when removed – when pulling the tool out of the animal hold it at an angle and twist it so the entire sample comes out within the tool. Discard and repeat if the tool is not full - a full cross section of the blubber layer must be obtained with skin attached to the outer layer, and muscle attached to the inner blubber layer. The tools are sterile before use so must be handled carefully when sampling in order to avoid cross-contamination.
22. Remove the blubber/skin sample with forceps from the biopsy punch tool, place and wrap in the tin foil (dull side up) square provided and place into the zip-lock bag you have labelled. Repeat steps - you should have two biopsy samples per animal. Two aluminum squares each containing one sample will go into the same plastic bag for the one animal.
23. Disinfect the biopsy tool and forceps between samples in tube of ethanol.
24. Ask crew where it can be stored (in ice or in freezer (preferable)).
25. When leaving the vessel, place all cetacean and bird samples into your box of iced fish/nephrops samples coming ashore. Inform the Catch Sampling Manager that you have samples and they will arrange to have them collected along with your normal samples.
26. If you require any more sampling equipment, please contact the Catch Sampling Manager.

### Label on cetacean sample bag:

Animal ID:  
Date:  
Species:  
Length:  
Sex:  
Sample: Skin+ Blubber

### Label on bird bag:

Animal ID:  
Date:  
Species:

## **Appendix VII: Bycatch sampling kit contents**

Twenty-five bycatch sampling kits were assembled for the at sea observers which contained the following items:

13. Sample protocol sheet (see below)
14. Eight pairs of disposable gloves
15. One permanent waterproof pen
16. Five disposable biopsy punch tools for skin/blubber sample collection
17. Ten squared of aluminium foil for samples to be wrapped in
18. One pair of forceps for sample extraction from biopsy tool
19. One tube of ethanol for disinfection of biopsy tool and forceps
20. Five pre-labelled zip-lock bags for samples to be kept in
21. One measuring tape for marine mammal length measurements
22. Six large black bags for seabird collection
23. Three pre-written labels for seabird bags
24. One bottle of hand sanitizer.

## Appendix VIII:

Criteria used to establish selected causes of death are described below (CSIP, 2016).

- **By-catch (entanglement in fishing gear)** was ascribed as a cause of death in cetacean carcasses using established pathological criteria for by-catch diagnosis
- **Infectious Disease**- a broad category consisting of a number of causes of death of infectious origin
- **Live Stranding**- attributed as the cause of death in cetaceans that were known or suspected (from post-mortem examination) to have live-stranded in apparent good health and nutritional status. This category excluded severely diseased or emaciated animals that stranded alive
- **Starvation**- given as the cause of death in animals that were severely emaciated and, following post-mortem examination, ascertained to have no other significant disease processes that could explain the poor nutritional status
- **Starvation (neonate)**- given as the cause of death in neonates that were severely emaciated and, following post-mortem examination, ascertained to have no other significant disease processes that could explain the poor nutritional status. Some of these animals may have become maternally separated
- **Fatal attack from one or more bottlenose dolphins**- ascribed as a cause of death in cetacean carcasses using established pathological criteria
- **Grey seal attack**- ascribed as a cause of death in individuals presenting with pathology potentially consistent with grey seal attack, as recently described
- **Physical trauma (boat/ship strike)**- physical trauma consistent with impact from a boat or ship. Includes blunt trauma to dorsal/lateral aspect of body wall and/or injuries consistent with propeller strike
- **Dystocia & Stillborn**- attributed as the cause of death in animals which have died during the act or process of giving birth (mothers or calves)
- **Physical trauma (unknown origin)**- where evidence of physical trauma is found at post-mortem, but no obvious origin or other significant underlying factors. This category is likely to include some undiagnosed cases of boat/ship strike, by-catch or bottlenose dolphin attack.
- **Gas embolism**- intravascular gas bubble formation that obstructs circulation and causes associated tissue injury
- **Entanglement**- a cause of death category largely confined to minke whales. Denotes evidence of entanglement in rope (creel etc.) or discarded fishing gear/marine litter
- **Cold stunned**- a cause of death category specific to hard shelled species of marine turtle, resulting from exposure to cold water around the UK coast, leading to immobility, hypothermia and eventual starvation
- **Neoplasia**- where the cause of death is due to the formation of a tumour
- **Others**- a broad category covering causes of death that cannot be categorised using existing criteria

Further details available on [www.emff.marine.ie](http://www.emff.marine.ie)

Managing Authority EMFF 2014-2020	Specified Public Beneficiary Body
<p data-bbox="248 786 740 862">Department of Agriculture Food &amp; the Marine</p> <p data-bbox="220 907 769 943">Clogheen, Clonakilty, Co. Cork. P85 TX47</p> <p data-bbox="320 983 671 1019">Tel: (+)353 (0)23 885 9500</p> <p data-bbox="312 1061 679 1097"><a href="http://www.agriculture.gov.ie/emff">www.agriculture.gov.ie/emff</a></p>	<p data-bbox="997 786 1201 822">Marine Institute</p> <p data-bbox="818 907 1380 943">Rinville, Oranmore, Co. Galway, H91 R673</p> <p data-bbox="911 983 1287 1019">Phone: (+)353 (0)91 38 7200</p> <p data-bbox="1002 1061 1197 1097"><a href="http://www.marine.ie">www.marine.ie</a></p>