

<https://helda.helsinki.fi>

Successful eradication of chronic myeloid leukemia in a child despite allogeneic graft rejection

Vuorenoja, Susanna

2022-10

Vuorenoja , S , Vettenranta , K & Lohi , O 2022 , ' Successful eradication of chronic myeloid leukemia in a child despite allogeneic graft rejection ' , Cancer reports , vol. 5 , no. 10 , 1663 . <https://doi.org/10.1002/cnr2.1663>

<http://hdl.handle.net/10138/350348>
<https://doi.org/10.1002/cnr2.1663>

cc_by
publishedVersion

Downloaded from Helda, University of Helsinki institutional repository.

This is an electronic reprint of the original article.

This reprint may differ from the original in pagination and typographic detail.

Please cite the original version.

CASE REPORT

Successful eradication of chronic myeloid leukemia in a child despite allogeneic graft rejection

Susanna Vuorenoja¹  | Kim Vetteranta² | Olli Lohi¹

¹Tampere Center for Child, Adolescent and Maternal Health Research, Tays Cancer Centre, Tampere University Hospital, Tampere University, Tampere, Finland

²Pediatric Research Center, University of Helsinki, Helsinki University Central Hospital, University of Helsinki, Helsinki, Finland

Correspondence

Susanna Vuorenoja, Department of Pediatric Hematology and Oncology, Tampere University Hospital, Elamanaukio 2, 33520 Tampere, Finland.
Email: susanna.vuorenoja@pshp.fi

Abstract

Background: Chronic myeloid leukemia (CML) is a rare disease in children and treated with tyrosine kinase inhibitors (TKI) and with allogeneic hematopoietic stem cell transplantation (HSCT) still in many cases.

Case: We describe an 8-year-old patient with CML treated with two different TKIs before proceeding to allogeneic HSCT. Despite successful engraftment, prompt rejection of the graft was followed by autologous reconstitution. TKI therapy was reintroduced post-rejection in anticipation of relapse but shortly discontinued due to low white blood cell and neutrophil counts. The patient has remained disease-free over 5 years after graft rejection and without further therapy.

Conclusion: This case suggests that even a short antileukemic effect by an allogeneic transplant may succeed in eradicating CML.

KEYWORDS

CML, eradication, graft rejection, HSCT, reconstitution

1 | INTRODUCTION

Chronic myeloid leukemia (CML) is a myeloproliferative neoplasm rare in children and accounts for only 2%–3% of pediatric leukemias among the 1–15-year-old and 9% of adolescents aged 15–19 years.¹ CML is characterized by the presence of the Philadelphia chromosome (Ph+) leading to the generation of the Bcr-Abl1 fusion gene. Allogeneic hematopoietic stem cell transplantation (HSCT) has traditionally been regarded as a treatment of choice for CML.² Since 1990s, targeted therapy with tyrosine kinase inhibitors (TKI) has become the mainstay of treatment and around half of the adult patients can discontinue TKI without a relapse.^{3–6} Likewise, in children with a sustained, deep, molecular remission (DMR) TKI therapy can be continued and HSCT avoided.^{7,8}

Here, we describe a child with CML who rapidly rejected the allogeneic graft but has remained disease-free for over 5 years without a second transplant or further TKI therapy.

2 | CASE

An 8-year-old patient was referred to a tertiary hospital (Tampere University Hospital, Finland) due to pain in the abdomen and limbs. The laboratory results showed an elevated white blood cell count (WBC) of $207 \times 10^9/L$ (normal range $4.5\text{--}13.5 \times 10^9/L$) with a predominance of myelocytes in the blood smear, thrombocytosis of up to $716 \times 10^9/L$ (normal range $180\text{--}400 \times 10^9/L$), and low hemoglobin of 87 g/L (normal range 110–155 × g/L). Bone marrow aspiration displayed expansion of the myeloid compartment. Fluorescence in situ hybridization and molecular genetics analyses revealed the presence of the major form (p210) of the Bcr-Abl1 fusion gene in 98% of the cells, confirming the diagnosis of a chronic phase CML. Except for the enlarged spleen in abdominal ultrasound examination, no additional, aberrant clinical findings were observed.

After a short pretreatment with hydroxyurea 1000 mg once a day, imatinib was commenced at a dose of 300 mg/m². The dose was

This is an open access article under the terms of the [Creative Commons Attribution](https://creativecommons.org/licenses/by/4.0/) License, which permits use, distribution and reproduction in any medium, provided the original work is properly cited.

© 2022 The Authors. *Cancer Reports* published by Wiley Periodicals LLC.

increased to 400 mg/m² but shortly lowered to 200 mg/m² to accommodate for a persisting neutropenia and pain in the legs, fingers, and wrists. The dose was, again, increased to 300 mg/m² at 14 months of therapy. The patient achieved a complete hematologic response at 3 and complete cytogenetic response at 9 months after the initiation of treatment. Measurable residual disease (MRD) in peripheral blood as measured from Bcr-Abl1 transcript by RT-PCR, plateaued at the molecular response level 2 (MR2), and with persisting leg pain and fatigue, imatinib was substituted with dasatinib 60 mg/m² at 21 months. Eight months later and 29 months since the introduction of TKI, a DMR (MR4) was achieved (Figure 1).

As allogeneic HSCT was considered the only curative therapy for CML at the time, 5 months after achieving MR4, HSCT from a 9/10 HLA-matched, unrelated, female donor was performed at MR 4.3 in

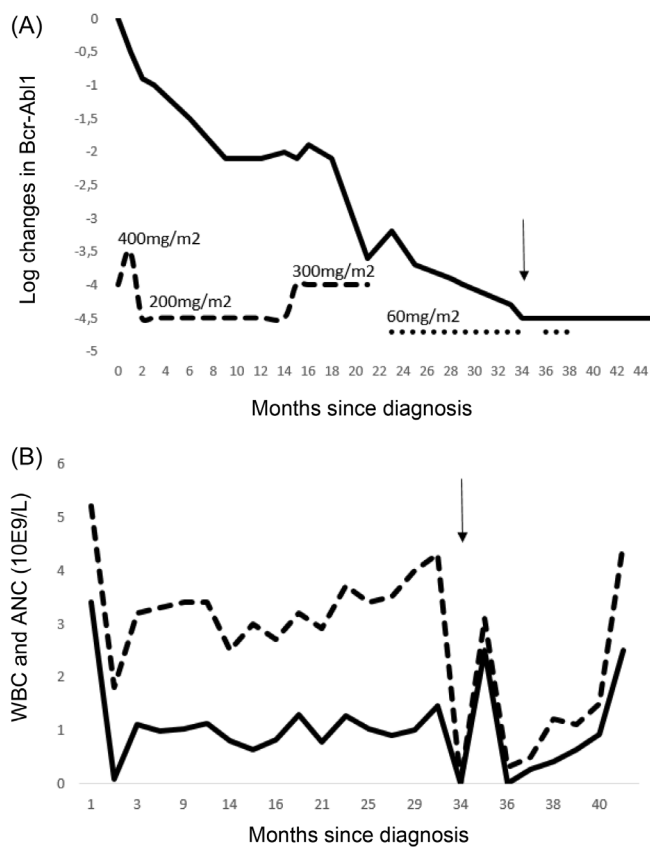


FIGURE 1 (A) The logarithmic change in peripheral blood *Bcr-Abl1* transcript level as measured by RT-PCR during treatment. The dashed line indicates the use of imatinib with different dosages, and the dotted line indicates the use of dasatinib. Timeline is shown in months, and the arrow indicates the timing of allogeneic HSCT (34 months from diagnosis). (B) Absolute neutrophil (ANC) and white blood cell (WBC) counts after initiation of imatinib therapy. There was a significant drop in the counts after 2 months of imatinib treatment and, therefore, imatinib was discontinued and later resumed at a reduced dose. HSCT was performed after 34 months of start of imatinib treatment. Two months after the HSCT, ANC dropped significantly and at 3 months post-transplantation, the graft was rejected. Timeline is shown in months, and the arrow indicates the timing of allogeneic HSCT (34 months from diagnosis).

the peripheral blood. The patient was conditioned using fludarabine and thiotepea according to the institutional protocol, and dasatinib stopped before the initiation of the conditioning therapy. There were no early adverse events post-transplant. On Day 21 post-HSCT, the patient no longer needed red blood cell or platelet transfusions, and the neutrophil count reached $1 \times 10^9/L$ on Day 32. Due to clinical signs of an engraftment syndrome, corticosteroids were initiated on Day 36. A routine GVHD prophylaxis was administered with daily cyclosporin together with methotrexate 10 mg/m² twice a week for 2 weeks.

Two months post-transplantation, the patient developed cytopenia and began needing weekly blood transfusions with a poor response. As an immunological mechanism was suspected, two doses of rituximab (375 mg/m²) were administered. However, at 3 months post-transplantation, the BM sampling indicated hypoplasia and rejection of the graft with only 2% of donor cells persisting. MRD monitoring by Bcr-Abl1 fusion PCR was negative. Pre-emptive dasatinib at 60 mg/m² was commenced in anticipation of a relapse but soon permanently discontinued due to low WBC and neutrophil counts (Figure 1B). Surprisingly, no evidence of disease has been detected by regular MRD monitoring in the peripheral blood (Figure 1A) or bone marrow. The patient has remained disease-free for over 5 years since graft rejection without the reintroduction of TKI therapy. She is currently post-pubertal with a height of +0.2 SD and weight at 10th percentile of the normal weight distribution.

3 | DISCUSSION

We report here a child with CML who received an allogeneic HSCT but rejected the graft and spontaneously reconstituted her autologous, non-leukemic hematopoiesis. The patient has remained disease-free now for over 5 years without additional interventions, suggestive of a permanent eradication of the malignant CML clone.

Many pediatric patients with CML achieve an MMR or DMR with the TKI therapy, and the current recommendation is that patients in a sustained DMR continue with the TKI.⁷⁻⁹ Our patient had a suboptimal early response but did achieve a DMR after the introduction of a second-generation TKI. She then proceeded to an allogeneic HSCT, the widely accepted curative treatment of choice for CML at the time. The recent approval and efficacy of the second-generation TKIs, dasatinib and nilotinib, for the pediatric indication has further limited the role of HSCT, currently reserved mainly for patients with a poor response or intolerance to TKI therapy.⁹ In adults, treatment with TKI alone has resulted in life-expectancies comparable to the age-matched healthy population.¹⁰

Discontinuation of the TKI is an increasingly common practice in adults.⁴ In contrast, among children only limited data are available and mainly on patients who either stopped the TKI early due to poor compliance or otherwise discontinued successfully.^{11,12} It remains unsettled whether TKI therapy is sufficient for a long-term eradication of the CML in children as leukemia stem cells are not anticipated to be killed by the TKI alone.¹³⁻¹⁶

The use of TKI therapy is accompanied with a specific set of toxicities in children. They may impair the growth and fertility and disrupt bone metabolism, thyroid function, and pubertal development.^{17,18} To minimize the adverse effects, recent data on adults and a small series in children have suggested that patients in a sustained DMR can use an intermittent dosing schedule or discontinue the drug entirely.^{12,19} Our patient experienced typical side-effects of imatinib such as bone and joint pain and low WBC counts. Substitution of imatinib with dasatinib mitigated these symptoms and despite almost 3 years of TKI use, our patient has grown normally and underwent normal pubertal development.

It is well recognized that CML cells are sensitive to the graft-versus-leukemia effect rendered by an allogeneic graft, thereby justifying the use of HSCT as a treatment.^{15,20} Prior to the TKI era, attempts were made to use autologous SCT for treatment of CML by using cells collected during remission and/or after purging of the graft.^{21,22} This approach demonstrated that hematopoiesis can be reconstituted from patient's Ph-negative cells. This is in agreement with our case, where the administration of high-dose conditioning chemotherapy was followed by graft rejection and spontaneous reconstitution of the autologous non-leukemic hematopoiesis.

Autologous hematopoietic reconstitution after allogeneic HSCT for CML has been described in adults both in the related and unrelated donor settings.^{23,24} However, all reported cases have relapsed except for one case, where only 2-year follow-up was reported.²⁵ Our case is the first child published with a successful, non-leukemic, autologous recovery after the rejection of the allogeneic graft, and the first with a sustained remission and likely cure without re-transplantation or long-term use of TKI post-transplantation.

An argument can be made on the patient not needing a transplant in the first place as she was in DMR at the time of transplantation. However, at the time of decision, an allogeneic HSCT was routine in aiming at the curative treatment of CML. It is also worth noting that her DMR had lasted no longer than 5 months before the transplantation and the first negative MRD came 3 months after transplantation. Second, we cannot entirely rule out a role for the conditioning chemotherapy in cure. With these caveats in mind, the case highlights the potent antileukemic effect of an allogeneic transplant in CML: even a short presence of immunologically active donor cells can elicit a robust immunological response to permanently eradicate the malignant CML clone.

AUTHOR CONTRIBUTIONS

Susanna Vuorenoja: Conceptualization (equal); data curation (equal); writing – original draft (equal). **Kim Vettentranta:** Conceptualization (equal); writing – review and editing (equal). **Olli Lohi:** Conceptualization (equal); data curation (equal); writing – review and editing (equal).

ACKNOWLEDGMENT

None.

CONFLICT OF INTEREST

The authors declare no conflict of interest.

DATA AVAILABILITY STATEMENT

The data that support the findings of this study are available from the corresponding author upon reasonable request.

ETHICS STATEMENT

The study was accepted by the Director of Science Center in Tampere University Hospital and informed consent was obtained from the patient and guardians before initiation of the study.

ORCID

Susanna Vuorenoja  <https://orcid.org/0000-0003-3816-0678>

REFERENCES

- Hijjiya N, Schultz KR, Metzler M, Millot F, Suttrop M. Pediatric chronic myeloid leukemia is a unique disease that requires a different approach. *Blood*. 2016;127(4):392-399. doi:10.1182/blood-2015-06-648667
- Baccarani M, Deininger MW, Rosti G, et al. European LeukemiaNet recommendations for the management of chronic myeloid leukemia: 2013. *Blood*. 2013;122(6):872-884. doi:10.1182/blood-2013-05-501569
- Claudiani S, Apperley JF. The argument for using imatinib in CML. *Hematol*. 2018;2018(1):161-167. doi:10.1182/asheducation-2018.1.161
- Saussele S, Richter J, Guilhot J, et al. Discontinuation of tyrosine kinase inhibitor therapy in chronic myeloid leukaemia (EURO-SKI): a prespecified interim analysis of a prospective, multicentre, non-randomised, trial. *Lancet Oncol*. 2018;19(6):747-757. doi:10.1016/S1470-2045(18)30192-X
- Hochhaus A, Ernst T. TKI discontinuation in CML: how do we make more patients eligible? How do we increase the chances of a successful treatment-free remission? *Hematology*. 2021;2021(1):106-112.
- Hochhaus A, Baccarani M, Silver RT, et al. European LeukemiaNet 2020 recommendations for treating chronic myeloid leukemia. *Leukemia*. 2020;34(4):966-984. doi:10.1038/s41375-020-0776-2
- Egan G, Athale U, Johnston D, et al. Outcomes of children with chronic myeloid leukemia: a population-based cohort study. *Pediatr Blood Cancer*. 2020;67(9):e28491. doi:10.1002/pbc.28491
- de la Fuente J, Baruchel A, Biondi A, et al. Managing children with chronic myeloid leukaemia (CML): recommendations for the management of CML in children and young people up to the age of 18 years. *Br J Haematol*. 2014;167(1):33-47. doi:10.1111/bjh.12977
- Hijjiya N, Suttrop M. How I treat chronic myeloid leukemia in children and adolescents. *Blood*. 2019;133(22):2374-2384. doi:10.1182/blood.2018882233
- Bower H, Björkholm M, Dickman PW, Höglund M, Lambert PC, Andersson TML. Life expectancy of patients with chronic myeloid leukemia approaches the life expectancy of the general population. *J Clin Oncol*. 2016;34(24):2851-2857. doi:10.1200/JCO.2015.66.2866
- Millot F, Claviez A, Leverger G, Corbaciglu S, Groll AH, Suttrop M. Imatinib cessation in children and adolescents with chronic myeloid leukemia in chronic phase. *Pediatr Blood Cancer*. 2014;61(2):355-357. doi:10.1002/PBC.24521
- Giona F, Saglio G, Moleti ML, et al. Treatment-free remission after imatinib discontinuation is possible in paediatric patients with chronic myeloid leukaemia. *Br J Haematol*. 2015;168(2):305-308. doi:10.1111/bjh.13103
- Copland M, Hamilton A, Elrick LJ, et al. Dasatinib (BMS-354825) targets an earlier progenitor population than imatinib in primary CML but does not eliminate the quiescent fraction. *Blood*. 2006;107(11):4532-4539. doi:10.1182/blood-2005-07-2947



14. Zhao H, Deininger M. Eradicating residual chronic myeloid leukaemia: basic research lost in translation. *Lancet Haematol*. 2021;8(2):e101-e104. doi:[10.1016/S2352-3026\(21\)00001-6](https://doi.org/10.1016/S2352-3026(21)00001-6)
15. Barrett AJ, Ito S. The role of stem cell transplantation for chronic myelogenous leukemia in the 21st century. *Blood*. 2015;125(21):3230-3235. doi:[10.1182/blood-2014-10-567784](https://doi.org/10.1182/blood-2014-10-567784)
16. Baccarani M, Gale RP. Why chronic myeloid leukaemia cannot be cured by tyrosine kinase-inhibitors. *Leukemia*. 2021;17:2199-2204. doi:[10.1038/s41375-021-01272-8](https://doi.org/10.1038/s41375-021-01272-8)
17. Giona F, Mariani S, Gnessi L, et al. Bone metabolism, growth rate and pubertal development in children with chronic myeloid leukemia treated with imatinib during puberty. *Haematologica*. 2013;98(3):e25-e27. doi:[10.3324/haematol.2012.067447](https://doi.org/10.3324/haematol.2012.067447)
18. Mariani S, Giona F, Basciani S, Brama M, Gnessi L. Low bone density and decreased inhibin-B/FSH ratio in a boy treated with imatinib during puberty. *Lancet*. 2008;372(9633):111-112. doi:[10.1016/S0140-6736\(08\)61023-5](https://doi.org/10.1016/S0140-6736(08)61023-5)
19. Giona F, Malaspina F, Putti MC, et al. Results and outcome of intermittent imatinib (ON/OFF schedule) in children and adolescents with chronic myeloid leukaemia. *Br J Haematol*. 2020;188(6):e101-e105. doi:[10.1111/bjh.16388](https://doi.org/10.1111/bjh.16388)
20. Pavlů J, Szydło RM, Goldman JM, Apperley JF. Three decades of transplantation for chronic myeloid leukemia: what have we learned? *Blood*. 2011;117(3):755-763. doi:[10.1182/blood-2010-08-301341](https://doi.org/10.1182/blood-2010-08-301341)
21. Spencer A, Granter N, Fagan K, Zaunders G, Deveridge S. Collection and analysis of peripheral blood mononuclear cells during haemopoietic recovery following PBSCT for CML: autografting as an in vivo purging manoeuvre? *Bone Marrow Transplant*. 1998;21(1):101-103. doi:[10.1038/SJ.BMT.1701042](https://doi.org/10.1038/SJ.BMT.1701042)
22. Bergamaschi G, Podestà M, Frassoni F, et al. Restoration of normal polyclonal haemopoiesis in patients with chronic myeloid leukaemia autografted with Ph-negative peripheral stem cells. *Br J Haematol*. 1994;87(4):867-870. doi:[10.1111/J.1365-2141.1994.TB06755.X](https://doi.org/10.1111/J.1365-2141.1994.TB06755.X)
23. Maury S, Belhadj K, Chami I, Kuentz M, Cordonnier C, Bories D. Autologous reconstitution combined with durable leukemic remission after allogeneic BMT for CML: absence of persistence of a donor-derived T cell effector population. *Bone Marrow Transplant*. 2001;28(7):717-720. doi:[10.1038/SJ.BMT.1703218](https://doi.org/10.1038/SJ.BMT.1703218)
24. Brunstein C, Hirsch B, Miller J, et al. Non-leukemic autologous reconstitution after allogeneic bone marrow transplantation for Ph-positive chronic myelogenous leukemia: extended remission preceding eventual relapse. *Bone Marrow Transplant*. 2000;26(11):1173-1177. doi:[10.1038/SJ.BMT.1702696](https://doi.org/10.1038/SJ.BMT.1702696)
25. Serrano J, Román J, Castillejo JA, et al. Autologous reconstitution with BCR-ABL-negative haematopoiesis after T cell-depleted allogeneic BMT for CML. *Bone Marrow Transplant*. 1998;22(6):599-601.

How to cite this article: Vuorenoja S, Vettenranta K, Lohi O. Successful eradication of chronic myeloid leukemia in a child despite allogeneic graft rejection. *Cancer Reports*. 2022;5(10):e1663. doi:[10.1002/cnr.2.1663](https://doi.org/10.1002/cnr.2.1663)