

This is an Open Access article licensed under the terms of the Creative Commons Attribution-NonCommercial-NoDerivs 3.0 License (www.karger.com/OA-license), applicable to the online version of the article only. Distribution for non-commercial purposes only.

Resolution of Persistent Cystoid Macular Edema due to Central Retinal Vein Occlusion in a Vitrectomized Eye following Intravitreal Implant of Dexamethasone 0.7 mg

Michele Reibaldi Andrea Russo Marco Zagari
Mario Toro Vittorio De Grande Valentina Cifalinò
Stefania Rametta Salvatore Faro Antonio Longo

Department of Ophthalmology, University of Catania, Catania, Italy

Key Words

Central retinal vein occlusion · Vitrectomized eye · Cystoid macular edema · Dexamethasone 0.7 mg · Ozurdex®

Abstract

We report the case of a 62-year-old woman with a history of vitreoretinal surgery for vitreous hemorrhage secondary to central retinal vein occlusion (CRVO). Because of the persistence of macular edema (ME), she received 2 intravitreal injections of bevacizumab 0.5 mg (Avastin®, Genentech/Roche) three months after vitrectomy, without functional or anatomical improvement. Six months after vitrectomy, she therefore received an intravitreal implant of dexamethasone 0.7 mg (Ozurdex®). An improvement in her best-corrected visual acuity and central macular thickness, as measured by optical coherence tomography, was detected 7 days after the injection, and complete resolution of the ME and retinal hemorrhages was observed 6 months after the injection. Dexamethasone intravitreal implant might be an effective treatment option in ME secondary to CRVO, also in vitrectomized eyes.

Introduction

Macular edema (ME) is one of the main vision-threatening complications associated with central retinal vein occlusion (CRVO) [1]. In CRVO, increased intravascular

pressure and reduced blood flow in the macular capillaries can lead to dysfunction of the endothelial blood-retinal barrier and to increased vascular permeability, both of which result in ME [2].

Recently published clinical trials have shown that intravitreal dexamethasone (Ozurdex[®]; Allergan, Irvine, Calif., USA) and ranibizumab (Lucentis[®]; Novartis Pharma) are effective in the treatment of ME secondary to CRVO [3, 4]. Neither of these studies included eyes previously treated with vitrectomy. In vitrectomized eyes, ocular pharmacokinetics and pharmacodynamics are modified with an increase in the clearance of medications from the vitreous. It has been shown that the half-life of drugs after intravitreal injection is reduced in vitrectomized eyes [5]. This result was found after injection of anti-vascular endothelial growth factor (VEGF), used for the treatment of diabetic ME [6].

To address this drawback, a biodegradable dexamethasone drug delivery system was developed (Ozurdex). Ozurdex was designed to provide sustained delivery of 700 mg of preservative-free dexamethasone to the vitreous cavity and retina for up to 180 days [3]. In vitrectomized and nonvitrectomized rabbit eyes, it has been shown that 1 month after implantation of the Ozurdex device, the concentration of dexamethasone in the vitreous cavity is similar [5].

We report a case of complete resolution of cystoid ME secondary to CRVO, refractory to previous treatments with intravitreal bevacizumab, with significant improvement of best-corrected visual acuity (BCVA), in a vitrectomized eye treated with an intravitreal implant of dexamethasone.

Case Report

A 62-year-old Caucasian woman presented at the University Eye Clinic at the Policlinico of Catania with a history of vitreoretinal surgery for vitreous hemorrhage in her right eye, secondary to CRVO. Because of the persistence of ME, three months after vitrectomy she received 2 intravitreal injections of bevacizumab 0.5 mg (Avastin[®]; Genentech/Roche), without functional or anatomical improvement after the injections.

When the patient was first examined at our clinic, 6 months after vitrectomy, she was diagnosed with cystoid ME secondary to CRVO (fig. 1a). BCVA in the right eye was 1.2 logMAR and central foveal thickness was 672 μm as measured by SD-OCT (spectral domain optical coherence tomography; Spectralis, Heidelberg Engineering, Heidelberg, Germany) (fig. 2a). Therefore, she received an intravitreal implant of dexamethasone 0.7 mg (Ozurdex).

An improvement in her BCVA to 0.9 logMAR was detected seven days after the injection; central macular thickness, measured by OCT and using the follow-up function, was 389 μm , with a reduction of 283 μm compared to the baseline value (fig. 2b).

Six months after the injection of Ozurdex, complete resolution of the ME and retinal hemorrhages was observed (fig. 1b); central macular thickness was 203 μm and BCVA improved further to 0.6 logMAR (fig. 2c).

Discussion

To our knowledge, there are no cases of intravitreal treatment of ME secondary to CRVO in vitrectomized eyes described so far in the literature. Recent studies have

evaluated the efficacy of the treatment of diabetic ME with intravitreal therapy in vitrectomized eyes: anti-VEGF failed to show a significant effect [6], while a prospective trial showed the efficacy of intravitreal Ozurdex implantation [7]. The results obtained in this latter study, as well as in our case, may have been caused by the favorable pharmacokinetics of a sustained-release dexamethasone implant.

Interestingly, in this case, the treatment with dexamethasone was effective in one eye with chronic ME refractory to repeated anti-VEGF injections; one of the main mechanisms of chronic ME is the alteration of the functionality of Müller cells. It has been experimentally shown that steroids, by reducing the osmotic swelling of Müller cells, improve the functionality of these cells and reduce ME [8]. Therefore, the dexamethasone implant (Ozurdex) may lead to anatomical and functional improvement also in patients with ME due to retinal vein occlusion, even in long-standing cases [9].

Another finding in our patient was the long-term effect, namely the absence of edema for up to 6 months. After vitrectomy, when the vitreous gel is replaced with a less viscous saline solution, the transport of all molecules and oxygen is facilitated, leading to better oxygenation of the ischemic retinal areas [10].

In conclusion, the dexamethasone implant (Ozurdex) might be an effective treatment option in ME secondary to CRVO, also in vitrectomized eyes.

Disclosure Statement

The authors have no conflicts of interest to declare.

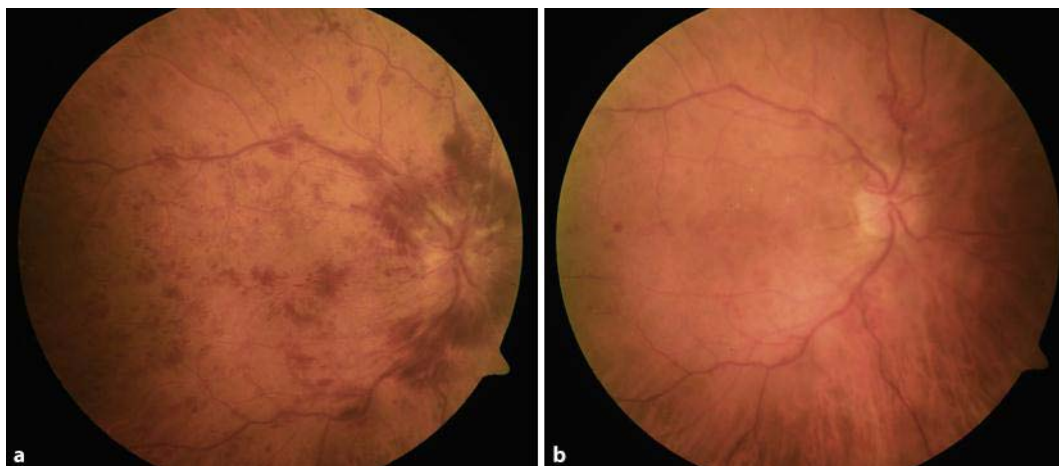


Fig. 1. **a** Fundus photography at baseline, before Ozurdex® injection, shows cystoid ME, widespread hemorrhaging and a swollen optic nerve in a vitrectomized eye. **b** Fundus photography 6 months after treatment shows a resolution of intraretinal hemorrhages and no ME.

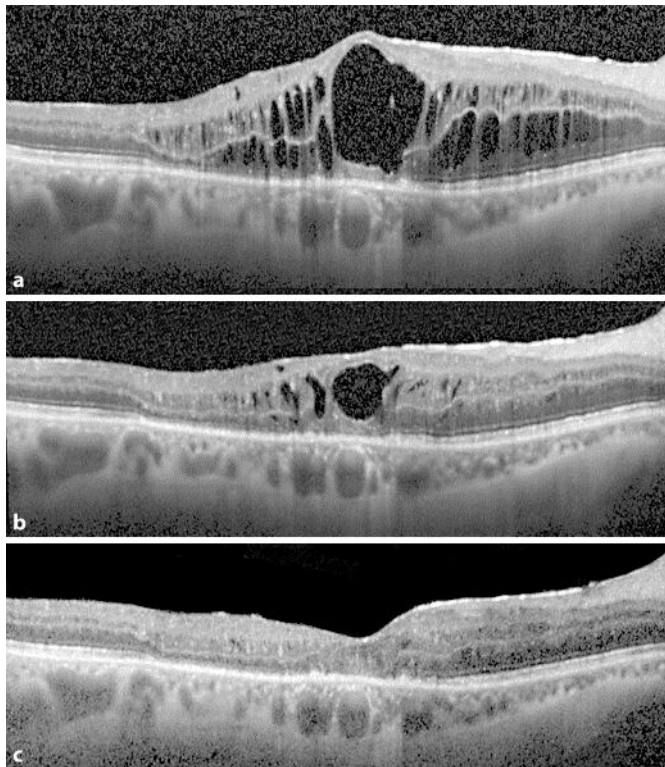


Fig. 2. **a** Baseline Spectralis OCT, before Ozurdex® injection, shows cystoid ME, refractory to 2 injections of Avastin®, in a vitrectomized eye; central retinal thickness was 672 μm . **b** Seven days after the injection of Ozurdex, using the follow-up function, OCT shows a 389- μm reduction in central retinal thickness. **c** Follow-up examination 180 days after Ozurdex injection. OCT shows the resolution of ME with a 469- μm reduction in central retinal thickness, compared to the baseline value.

References

- 1 Glacet-Bernard A, Coscas G, Chabanel A, Zourdani A, Lelong F, Samama MM: Prognostic factors for retinal vein occlusion: prospective study of 175 cases. *Ophthalmology* 1996;103:551–560.
- 2 Ota M, Tsujikawa A, Ojima Y, Miyamoto K, Murakami T, Ogino K, Akagi-Kurashige Y, Muraoka Y, Yoshimura N: Retinal sensitivity after resolution of the macular edema associated with retinal vein occlusion. *Graefes Arch Clin Exp Ophthalmol* DOI: 10.1007/s00417-011-1860-0.
- 3 Haller JA, Bandello F, Belfort R Jr, Blumenkranz MS, Gillies M, Heier J, Loewenstein A, Yoon YH, Jacques ML, Jiao J, Li XY, Whitcup SM; OZURDEX GENEVA Study Group: Randomized, sham-controlled trial of dexamethasone intravitreal implant in patients with macular edema due to retinal vein occlusion. *Ophthalmology* 2010;117:1134–1146.e3.
- 4 Brown DM, Campochiaro PA, Singh RP, Li Z, Gray S, Saroj N, Rundle AC, Rubio RG, Murahashi WY; CRUISE Investigators: Ranibizumab for macular edema following central retinal vein occlusion: six-month primary end point results of a phase III study. *Ophthalmology* 2010;117:1124–1133.
- 5 Chang-Lin JE, Burke JA, Peng Q, Lin T, Orilla WC, Ghosn CR, Zhang KM, Kuppermann BD, Robinson MR, Whitcup SM, Welty DF: Pharmacokinetics of a sustained-release dexamethasone intravitreal implant in vitrectomized and nonvitrectomized eyes. *Invest Ophthalmol Vis Sci* 2011;52:4605–4609.
- 6 Yanyali A, Aytug B, Horozoglu F, Nohutcu AF: Bevacizumab (Avastin) for diabetic macular edema in previously vitrectomized eyes. *Am J Ophthalmol* 2007;144:124–126.

- 7 Boyer DS, Faber D, Gupta S, Patel SS, Tabandeh H, Li XY, Liu CC, Lou J, Whitcup SM; Ozurdex CHAMPLAIN Study Group: Dexamethasone intravitreal implant for treatment of diabetic macular edema in vitrectomized patients. *Retina* 2011;31:915–923.
- 8 Reichenbach A, Wurm A, Pannicke T, Iandiev I, Wiedemann P, Bringmann A: Müller cells as players in retinal degeneration and edema. *Graefes Arch Clin Exp Ophthalmol* 2007;45:627–636.
- 9 Meyer LM, Schönfeld CL: Fast resolution of recurrent pronounced macular edema following intravitreal injection of dexamethasone 0.7 mg. *Case Rep Ophthalmol* 2011;2:246–250.
- 10 Stefánsson E: Physiology of vitreous surgery. *Graefes Arch Clin Exp Ophthalmol* 2009;47:147–163.