





Original article

The role of chest CT in deciphering interstitial lung involvement: systemic sclerosis versus COVID-19

Martina Orlandi¹, Nicholas Landini^{2,3}, Gianluca Sambataro^{4,5}, Cosimo Nardi², Lorenzo Tofani¹, Cosimo Bruni¹, Silvia Bellando-Randone¹, Jelena Blagojevic¹, Daniela Melchiorre¹, Michael Hughes⁶, Christopher P. Denton ⁷, Fabrizio Luppi ⁸, Barbara Ruaro⁹, Francesca della Casa¹⁰, Francesca W. Rossi¹⁰, Giacomo De Luca¹¹, Corrado Campochiaro¹¹, Michele Spinicci¹², Lorenzo Zammarchi ¹², Sara Tomassetti¹³, Antonella Caminati¹⁴, Edoardo Cavigli¹⁵, Marco Albanesi¹⁵, Fabio Melchiorre¹⁶, Stefano Palmucci¹⁷, Virginia Vegni¹⁸, Serena Guiducci¹, Alberto Moggi-Pignone¹⁹, Yannick Allanore²⁰, Alessandro Bartoloni¹², Marco Confalonieri⁹, Lorenzo Dagna¹¹, Francesco DeCobelli²¹, Amato dePaulis¹⁰, Sergio Harari^{14,22}, Dinesh Khanna²³, Masataka Kuwana ²⁴, Gloria Taliani²⁵, Federico Lavorini¹³, Vittorio Miele¹⁵, Giovanni Morana³, Alberto Pesci⁸, Carlo Vancheri⁴, Stefano Colagrande² and Marco Matucci-Cerinic^{1,11}

Abstract

Objective. The aim of this study was to identify the main CT features that may help in distinguishing a progression of interstitial lung disease (ILD) secondary to SSc from COVID-19 pneumonia.

Methods. This multicentric study included 22 international readers grouped into a radiologist group (RADs) and a non-radiologist group (nRADs). A total of 99 patients, 52 with COVID-19 and 47 with SSc-ILD, were included in the study.

Results. Fibrosis inside focal ground-glass opacities (GGOs) in the upper lobes; fibrosis in the lower lobe GGOs; reticulations in lower lobes (especially if bilateral and symmetrical or associated with signs of fibrosis) were the CT features most frequently associated with SSc-ILD. The CT features most frequently associated with COVID-19

¹Division of Rheumatology AOUC, Department of Clinical and Experimental Medicine, University of Florence, University of Florence, ²Department of Experimental and Clinical Biomedical Sciences, Radiodiagnostic Unit n. 2, University of Florence – AOUC, Florence, ³Department of Radiology, Ca' Foncello General Hospital, Treviso, ⁴Regional Referral Centre for Rare Lung Diseases, A. O. U. 'Policlinico G. Rodolico – San Marco' Department of Clinical and Experimental Medicine, University of Catania, ⁵Artroreuma SRL, Outpatient of Rheumatology Accredited with Italian National Health System, Mascalucia, Catania, Italy, ⁶Department of Rheumatology, Royal Hallamshire Hospital, Sheffield Teaching Hospitals NHS Foundation Trust, Sheffield, ⁷University College London Division of Medicine, Centre for Rheumatology and Connective Tissue Diseases, London, UK, ⁸Respiratory Unit, University of Milano-Bicocca, S. Gerardo Hospital, Monza, ⁹Department of Pulmonology, University Hospital of Cattinara, Trieste, ¹⁰Division of Autoimmune & Allergic Diseases, Department of Translational Medical Sciences, University of Naples Federico II, Napoli, ¹¹Unit of Immunology, Rheumatology, Allergy and Rare Diseases, IRCCS San Raffaele Scientific Institute, Vita Salute San Raffaele University, Milano, ¹²Department of Experimental and Clinical Medicine, University of Florence, and Infectious and Tropical Diseases Unit, AOUC, ¹³Department of Clinical and Experimental Medicine, University of Florence, Florence, ¹⁴U.O. di Pneumologia, Ospedale San Giuseppe MultiMedica, IRCCS, Milano, ¹⁵Department of Radiology, Azienda Ospedaliero-Universitaria Careggi, Florence, ¹⁶Department of

Radiology, Sant'Andrea Hospital Vercelli, ASLVC, ¹⁷Radiodiagnostic and Radiotherapy Unit, Department of Medical Surgical Sciences and Advanced Technologies 'GF Ingrassia', University of Catania, ¹⁸Radiology Unit, Rugani Hospital, Siena, ¹⁹Department of Experimental and Clinical Medicine, AOU Careggi Hospital, University of Florence Medical School, Florence, Italy, ²⁰Department of Rheumatology A, Descartes University, APHP, Cochin Hospital, Paris, France, ²¹Department of Radiology IRCCS San Raffaele Scientific Institute, Vita-Salute San Raffaele University, ²²Department of Clinical Sciences and Community Health, Università degli Studi di Milano, Milan, Italy, ²³Department of Medicine, University of Michigan, Ann Arbor, MI, USA, ²⁴Department of Allergy and Rheumatology, Nippon Medical School Graduate School of Medicine, Tokyo, Japan and ²⁵Department of Translational and Precision Medicine, Sapienza University, Rome, Italy

Submitted 28 April 2021; accepted 9 July 2021

Correspondence to: Martina Orlandi, Department of Clinical and Experimental Medicine, University of Florence, Division of Rheumatology AOUC, Padiglione 28c Ponte Nuovo, Via delle Oblate, 4, CAP 50141, Florence, Italy. E-mail: martina.orlandi@unifi.it

pneumonia were: consolidation (CONS) in the lower lobes, CONS with peripheral (both central/peripheral or patchy distributions), anterior and posterior CONS and rounded-shaped GGOs in the lower lobes. After multivariate analysis, the presence of CONS in the lower lobes ($P < 0.0001$) and signs of fibrosis in GGOs in the lower lobes ($P < 0.0001$) remained independently associated with COVID-19 pneumonia and SSc-ILD, respectively. A predictive score was created that was positively associated with COVID-19 diagnosis (96.1% sensitivity and 83.3% specificity).

Conclusion. CT diagnosis differentiating between COVID-19 pneumonia and SSc-ILD is possible through a combination of the proposed score and radiologic expertise. The presence of consolidation in the lower lobes may suggest COVID-19 pneumonia, while the presence of fibrosis inside GGOs may indicate SSc-ILD.

Key words: COVID-19, COVID-19 pneumonia, interstitial lung disease, systemic sclerosis, lung CT scan

Rheumatology key messages

- CT differential diagnosis between COVID-19 pneumonia and interstitial lung disease secondary to systemic sclerosis (SSc-ILD) is possible.
- The presence of fibrosis inside ground-glass opacities may indicate SSc-ILD.
- The presence of consolidation in the lower lobes may indicate a COVID-19 infection.

Introduction

The COVID-19 pandemic is characterized by an interstitial pneumonia and vascular damage that may lead to a severe and sometimes fatal outcome [1]. In SSc, interstitial lung disease (ILD) is one of the main features [2, 3]. During the last few months, it has clearly emerged that COVID-19 and SSc may share similar radiological features [4]. Recently, we raised the question of whether, in SSc, the onset of bilateral and subpleural lung alterations in chest high-resolution computed tomography (HRCT) were due to rapid onset, acute exacerbation or progression of SSc-ILD, or overlap with COVID-19 pneumonia [5]. In both diseases, the presence of bilateral and subpleural ground glass opacities (GGOs), with or without consolidations (CONS), are the most frequent radiological alterations [6]. In SSc-ILD, the most common radiological pattern is non-specific interstitial pneumonia (NSIP) with peripheral, bibasilar distribution of GGOs and a lower proportion of reticulation, while usual interstitial pneumonia (UIP) may be present in up to one-third of patients [3, 7–11]. In COVID-19 patients, ILD pneumonia is characterized by bilateral GGOs, evolving into CONS, with a peripheral distribution mostly involving lower lung areas [12]. Although none of the CT features of COVID-19 seem to be specific, lung CT has a fundamental role in the diagnostic algorithm for COVID-19 pneumonia. Recently, the Radiological Society of North America (RSNA) proposed a radiologic classification of COVID-19 pneumonia that focused the attention on the fact that a typical COVID-19 CT pattern may also be found in other ILDs, such as that found in CTDs [13]. Therefore, in practice, differential diagnosis of the two diseases is a real challenge. Drawing parallels between SSc-ILD and COVID-19 offers potential insight into both diseases, as well as being of practical clinical relevance.

Considering this background, the primary goal of our study was to identify the main CT features of COVID-19 pneumonia and SSc-ILD that may help in distinguishing these diseases from one another. The secondary end point was to evaluate the ability of, and the concordance between, radiologists (RADs) and non-radiologists (nRADs)/clinicians in differentiating SSc-ILD from COVID-19 pneumonia on the basis of chest CTs, based on their CT-reading expertise.

Materials and methods

Patients and images selection

COVID-19 pneumonia and SSc-ILD patients were eligible for the study. The COVID-19 group included patients with positive RT-PCR for COVID-19 and also chest CT imaging available and performed within 2 weeks of the RT-PCR diagnosis. COVID-19 patients were retrospectively recruited from Florence and Treviso Hospitals from 1 March to 30 May 2020. The COVID-19 CTs were acquired during the hospital admission (or within 3 days) to determine functional deterioration. For each COVID-19 patient, we tried to identify a SSc-ILD gender- and age-matched patient fulfilling the 2013 ACR/EULAR criteria for SSc [14] with CT images acquired before 2019. The identified CT scans were directly downloaded from the hospital Picture Archiving and Communications Systems.

All CT scans had slice thickness ranging from 1.0 to 1.5 mm. All CTs were scanned at full inspiration in a supine position. Some additional prone CTs were acquired for SSc patients, as they may occasionally be performed for ILD assessment [15]. However, these additional CTs were excluded from the analysis to avoid any lecture bias, since CTs in COVID patients were acquired only in the supine position. The images were anonymized and

randomized. Patients were identified with an alpha numeric code, in respect of the privacy rules. The CT scans were saved as DICOM files and sent to the readers through a password-protected sharing platform (Dropbox). A free DICOM viewer (Radiant DICOM Viewer 2020.1) was also suggested.

Methods and study design

This retrospective, observational, multicentric, international study was approved by the Institutional Ethics Committee of Florence Careggi Hospital (protocol number 17104_oss).

Phase I—the gold standard

Two chest RADs (N.L. and E.C.) with >5 years of experience in chest imaging evaluated all CTs: disagreements were solved by a senior chest RAD with >10 years of experience (S.C.). These evaluations were considered as the gold standard for analysis of the predictive capacity of the various CT features and elements.

Phase II—image evaluation

This multicentric study included 22 international readers (N.L., E.C., M.A., F.M., S.P., V.V., F.D.C., G.S., C.B., S.B.R., J.B., M.H., C.D., F.L., B.R., F.D.C., G.D.L., L.Z., M.S., S.T. and A.C.), including RADs and nRADs. The RADs group included 7 RADs, of whom there were 4 chest RADs, with at least 5 years of experience. The non-RADs group included 15 specialists, including 6 rheumatologists, 3 immunologists, 2 infectious disease specialists and 4 pulmonologists. Detailed information about each reader's medical speciality, location of practice, SSc-specific training, years of practice, and COVID-19-specific training are shown in [Supplementary Data S1](#), available at *Rheumatology* online. Each reader reviewed the images of all patients (using Picture Archiving and Communications Systems) independently and was blinded to diagnosis, laboratory assay results and demographic information, including patient name, hospital of origin of the CTs and date of CT examination.

Image analysis

Each reader was asked to fill an electronic database giving single (i.e. yes/no) or multiple choice (e.g. mostly anterior / mostly posterior / no prevalence) answers. The definitions of CT lesions and anatomical references used in the assessment were those of the Fleischner Society [16, 17] and are available in [Supplementary Data S2](#), available at *Rheumatology* online.

CT evaluation was performed at three different levels of detail in order to reach the study's objectives: a first basic level of analysis, common for RADs and nRADs, a second more advanced level, specific only for RADs, and a third deeper analysis, made by the 4 chest RADs only, as follows. The first level included the analysis of 56 CT features. CT images were assessed for presence/absence of lung disease, as well as for side and symmetry (monolateral/bilateral-asymmetric/bilateral-symmetric) and prevalent distribution (anterior/posterior/no prevalence, central/

peripheral/no prevalence/patchy). Parenchymal lesions assessment was also performed with the same variables, for upper and lower zones. The CT lesions were categorized as: CONs, GGOs, crazy paving (CP), reticulations (RETs) and honeycombing (HC). The prevalent localization (upper/lower/no prevalence), the involved lobes, and the most extensive lesion (CONs, GGOs, CP, RETs or HC) were also assessed. Air bronchograms inside CONs (always present/not always present/never present), were analysed, too. Lastly, pleural effusion, pericardial effusion, lymphadenopathy and oesophagus dilatation were assessed in terms of absence/presence.

The second level included 14 additional CT features, including presence/absence of aspects resembling organizing pneumonia in CONs, signs of fibrosis (defined by architectural distortions or bronchiectasis) in CONs, GGOs and RETs, and pleural thickenings in the whole-lung fields.

The third level assessed other 8 CT features: disease pattern (monofocal/multifocal/diffuse/focal and diffuse or white lung), GGOs pattern (focal, diffuse or both), presence/absence of rounded GGOs, and presence/absence of fibrosis inside focal GGOs (see [Supplementary Fig. S1](#), available at *Rheumatology* online).

Each reader was invited to propose a diagnosis of COVID-19 pneumonia or SSc-ILD.

Statistical analysis and score derivation

Each categorical variable was described in absolute and relative frequencies for each category stratified by diagnosis. In order to evaluate the interreader agreement, Cohen's Kappa (κ) adjusted for multiple readers and its 95% CI were used. A $\kappa \geq 0.4$, 0.6 and 0.8 was considered discrete, good and excellent, respectively. To assess the association between each CT feature and the diagnosis, a simple logistic regression model was used, and the odds ratio (OR) and its 95% CI were reported. According to the presence of association, the predictive capability was described by the area under the ROC curve (AUROC) and its 95% CI. An AUROC ≥ 0.8 was considered good, while an AUROC ≥ 0.9 was considered excellent. In order to reach the best predictive performance with the most economical model, a multiple logistic regression model with a backward selection method for CT features with excellent predictive capability and good interreader agreement was used. According to the multiple logistic model results, a score weighted using log (OR) of each selected CT feature was created. Using the AUROC, a cut-off was selected, and its sensibility, specificity, positive predictive value and negative predictive value were reported. No external validation of the score cut-off was performed. The significant level was set to 5% for each analysis. Once we obtained the results from the RADs' analysis, we compared them with the reference results in order to evaluate which could be the features with significant discriminating capability, and subsequently we validated this with a regression model and with multivariate analysis. Lastly, we

attempted to obtain an incremental score positively associated with a COVID-19 diagnosis.

Results

A total of 99 patients were included in this study: 52 COVID-19 pneumonia patients and 47 SSc-ILD patients. The mean age was 62.4 (± 7) and 60.3 (± 6) years in COVID-19 and SSc-ILD, respectively, with 19 female patients in the SSc-ILD group and 23 in the COVID-19 group.

Interreader agreement

The full detailed results about interreader agreement are available in [Supplementary Table S1](#), available at *Rheumatology* online.

nRADs' interreader agreement

nRADs interreader agreement for the evaluation of all the different items was very scarce (0.03–0.36). For this reason, this was not considered relevant for the subsequent evaluations ([Supplementary Table S2](#), available at *Rheumatology* online).

RADs' interreader agreement

In the RADs group, a discrete-to-good agreement for 47% of the items (33/70) was detected, with a κ Cohen ranging from 0.60 to 0.71. When readers were divided according to skill concerning chest CT, chest RADs showed better concordance for the items considered (68.4%; 52/76), and the κ Cohen between non-chest RADs and chest RADs differed significantly ($P < 0.05$) in 51.4% of items (36/70); in 35.71% of variables (25/70) the P -value was < 0.005 ([Supplementary Table S1](#), available at *Rheumatology* online). For the chest RADs, the agreement was good, with a κ Cohen value from 0.62 to 0.74. Out of 70 CT features proposed to the RADs readers for analysis, 39 showed a discrete and 33 a good intrareader agreement: only the latter were considered suitable for subsequent evaluations.

Diagnostic performance

nRADs' diagnostic performance

The nRADs made a correct diagnosis (COVID-19 pneumonia or SSc) in 77.5% (95% CI: 75.13, 79.74) of cases.

In particular, a correct diagnosis was achieved in 75.95% of COVID-19 patients (499/657 evaluations) and 78.95% of SSc patients (510/646 evaluations) ([Table 1](#)).

RADs' diagnostic performance

The RADs made a correct diagnosis in 83.92% of cases (95% CI: 80.95%, 86.59%): 86.61% of COVID-19 pneumonia patients and 81.08% of SSc subjects ([Table 1](#)). Diagnostic performances of nRADs and RADs differed statistically from one another ($P = 0.0008$) ([Table 1](#)). The correct diagnosis was made (all, COVID-19 pneumonia or SSc-ILD), respectively: chest RADs group, in 86.53% (95% CI: 83.18%, 89.43%); 88.40% (221/250); 84.58% (67/93) of patients; non-chest RADs group in 72.04% (95% CI: 70.77, 83.01%); 82.18% (82/101); 72.04% (203/240) of patients. A significant difference in diagnostic performance between chest and non-chest RADs was found ($P = 0.0034$) ([Table 1](#)).

Diagnostic predictive value of CT features

Given the scarce concordance in the nRADs group and the significant difference in concordance between chest-RADs and non-chest-RADs, only those parameters for which RADs had shown good or excellent concordance ([Table 2](#)) were considered as possible discriminating parameters and so accepted as relevant for differential diagnosis between COVID-19 and SSc-ILD. The complete CT features predictive values are available (see [Supplementary Table S2](#), available at *Rheumatology* online).

Discriminating CT features

We identified the main CT features of COVID-19 pneumonia and SSc-ILD, considering only those showing good concordance and good/excellent discriminating capability. CT features most likely associated with SSc-ILD were: fibrosis inside focal GGOs in the upper lobes; fibrosis in lower-lobe GGOs; and RETs in the lower lobes, especially if bilateral/symmetrical or with signs of fibrosis. CT features most likely associated with COVID-19 pneumonia were: CONs in the lower lobes; CONs with peripheral, both central/peripheral or patchy distributions; both anterior and posterior CONs; and rounded-shaped GGOs in the lower lobes. ([Table 2](#)).

TABLE 1 Diagnostic performance of readers

Readers	Correct diagnosis			RAD vs nRAD	Chest-RAD vs non-chest RAD
	COVID-19	SSc-ILD	TOT (95% CI)		
nRADs	75.95% (499/657)	78.95% (510/646)	77.5% (75.13%, 79.74%)	$P = 0.0008$	$P = 0.0034$
RADs	86.61% (304/351)	81.06% (270/333)	83.92% (80.95%, 86.59%)		
Chest-RADs	88.40% (221/250)	84.58% (203/240)	86.53% (83.18%, 89.43%)		
Non-chest-RAD	82.18% (83/101)	72.04% (67/93)	77.32% (70.77%, 83.01%)		

nRADs: non-radiologist clinicians; RADs: radiologists; chest-RADs: chest radiologists, with at least 5 years of experience in chest imaging; non-chest-RADs: radiologists without experience in chest imaging.

TABLE 2 Discriminating CT parameters

CT parameter	Level	COVID-19	SSc-ILD	OR (95% CI)	P-value	AUC (95% CI)	Predictive capability
Focal GGOs with fibrosis in upper zone	Absence	14 (27.45%)	34 (70.83%)	Reference	<0.0001*	0.82 (0.75, 0.90)	Good
	No	37 (72.55%)	6 (12.5%)	0.07 (0.03, 0.21)	0.2120		
	Yes	0 (0%)	8 (16.67%)	7.15 (0.33, 156.76)			
GGOs with fibrosis lower zones	Absence	5 (9.8%)	4 (8.33%)	Reference	0.0145	0.908 (0.849, 0.967)	Excellent
	No	42 (82.35%)	4 (8.33%)	0.129 (0.025, 0.667)	0.0042		
	Yes	4 (7.84%)	40 (83.33%)	11 (2.131, 56.794)			
Reticulations lower zone	No	49 (96.08%)	7 (14.58%)	Reference	<0.0001*	0.91 (0.85, 0.96)	Excellent
	Yes	2 (3.92%)	41 (85.42%)	109.59 (24.31, 494.08)			
	Absence	49 (96.08%)	7 (14.58%)	Reference	0.0712	0.91 (0.85, 0.96)	
Reticulations side lower zone	Bilateral, asymmetric	0 (0%)	2 (4.17%)	33.02 (0.74, 1474.71)	<0.0001*	0.92 (0.86, 0.97)	Excellent
	Bilateral, symmetric	2 (3.92%)	39 (81.25%)	104.28 (23.08, 471.10)			
	Absence	49 (96.08%)	7 (14.58%)	Reference	0.0563		
Reticulations with fibrosis lower zone	No	1 (1.96%)	2 (4.17%)	11 (0.94, 129.11)	<0.0001*	0.88 (0.82, 0.94)	Good
	Yes	1 (1.96%)	39 (81.25%)	173.8 (28.06, 1076.39)			
	No	8 (15.69%)	44 (91.67%)	Reference	0.0002*	0.90 (0.84, 0.96)	
Consolidation lower zone	Yes	43 (84.31%)	4 (8.33%)	0.02 (0.00, 0.07)	<0.0001*	0.89 (0.82, 0.95)	Good
	Absence	8 (15.69%)	44 (91.67%)	Reference	0.0007*		
	Unilateral	10 (19.61%)	3 (6.25%)	0.06 (0.01, 0.27)	<0.0001*		
Consolidation side lower zone	Bilateral, asymmetric	16 (31.37%)	0 (0%)	0.01 (0, 0.11)	0.0055*	0.88 (0.82, 0.94)	Good
	Bilateral, symmetric	17 (33.33%)	1 (2.08%)	0.02 (0.00, 0.11)			
	Absence	8 (15.69%)	44 (91.67%)	Reference	0.2402	0.89 (0.82, 0.95)	
Consolidation C/P distribution lower zone	Central	1 (1.96%)	0 (0%)	0.06 (0.00, 6.24)	<0.0001*	0.88 (0.82, 0.95)	Good
	Peripheral	32 (62.75%)	3 (6.25%)	0.02 (0.00, 0.08)	0.0147*		
	No prevalence	5 (9.8%)	0 (0%)	0.02 (0.00, 0.45)	0.0055*		
Consolidation A/P distribution lower zone	Patchy	5 (9.8%)	1 (2.08%)	0.05 (0.01, 0.42)	0.0242*	0.88 (0.82, 0.95)	Good
	Absence	8 (15.69%)	44 (91.67%)	Reference	<0.0001*		
	Mostly anterior	4 (7.84%)	0 (0%)	0.02 (0.00, 0.60)	0.0027*	0.81 (0.73, 0.89)	
GGOs rounded lower zone	Mostly posterior	33 (64.71%)	3 (6.25%)	0.02 (0.00, 0.08)	0.1165		Good
	No predominance	6 (11.76%)	1 (2.08%)	3.32 (0.74, 14.81)	<0.0001*		
	Absence	5 (9.8%)	4 (8.33%)	Reference			
GGOs rounded lower zone	Rounded	38 (74.51%)	9 (18.75%)	16.93 (5.96, 48.04)	<0.0001*		Good
	Non-rounded	8 (15.69%)	35 (72.92%)				

Detailed results of all CT parameters analysed. * $P < 0.05$. SSc-ILD: interstitial lung disease secondary to SSc; OR: odds ratio; AUC: area under the curve; C/P: central/peripheral; A/P: anterior/posterior; GGOs: ground glass opacities; absence: absence of the alteration for which the subanalysis should have been performed.

Model derivation

A multivariate regression model was developed to select variables independently related to the diagnosis of COVID-19 pneumonia. For the 99 patients involved, the 5 most significant associated predictors were, according to clinical decision, feasibility, good reproducibility and good/excellent predictive ability: CONs in the lower zone, rounded GGOs in the lower zone (both predictive for COVID-19 pneumonia), fibrosis in GGOs in the lower zone, inside focal GGO fibrosis in the upper zone and lower lobes RETs, all of which were predictive for SSc-ILD. Otherwise, only lower lobe CONs ($P < 0.0001$) and signs of fibrosis in GGOs in the lower lobes ($P < 0.0001$) were found to be independent predictors (Table 3). On this basis, we proposed a score that might identify a CT as associated with a COVID-19 diagnosis (OR: 2.67, 95% CI: 1.76, 4.07), as follows: CONs: 4 points if present, 0 if absent; GGOs: 5 points if present without fibrosis, 0 if present with fibrosis, 3 if absent.

This score showed an excellent predictive capability, with an AUROC of 0.97 (95% CI: 0.94, 1.00) (Table 3 and Supplementary Fig. 2, available at *Rheumatology* online). The score cut-off was 4 (chosen in order to guarantee greater sensitivity and specificity for the score), and if the score was ≥ 4 it was associated with a diagnosis of COVID-19. The score diagnostic performance had 96.1% sensitivity (95% CI: 86.5%, 99.5%) and 83.3% specificity (95% CI: 69.8%, 92.5%). The negative predictive value was 95.2% (95% CI: 83.8%, 99.4%), and the positive predictive value was 86.0% (95% CI: 74.2%, 93.7%).

Discussion

Our data show, as far as we know for the first time, that a differential diagnosis between COVID-19 and SSc-ILD is possible in practice, employing the CT images: the presence of CONs and fibrosis inside GGOs in the lower lobes are independent CT diagnostic features for COVID-19 pneumonia and SSc-ILD diagnosis, respectively (Fig. 1).

This differential diagnosis represents a new challenge for clinicians and RADs [18, 19]. Recently, the Radiological Society of North America (RSNA) [13]

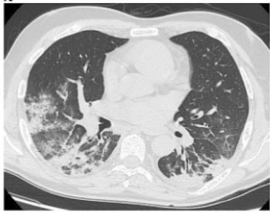


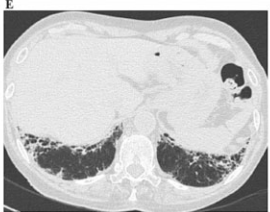


identified 3 CT patterns of COVID-19 pneumonia: peripheral and bilateral GGOs, regardless of the coexistence of CONs; CP or multifocal rounded GGOs, regardless of the coexistence of CONs or CP; and findings of organizing pneumonia. However, these features of COVID-19 pneumonia can also be found in other lung diseases, such as those related to CTDs [7, 13]. The most common radiological pattern in SSc-ILD is NSIP with peripheral, bibasilar distribution of GGOs and a lower proportion of coarse RETs [3, 4, 8–11]. In addition to the radiological similarities, the clinical presentation is similar in both diseases, although fever and rapid onset of shortness of breath are peculiar to COVID-19 pneumonia [20–22]. However, suspicion of a SARS-CoV-2 infection in symptomatic SSc patients should be raised, even in the absence of fever, since in most of these patients, fever is absent due to treatment with immunosuppressors. Thus, in the COVID-19 era, it has been hard for clinicians to provide an accurate diagnosis, and lung CT has played a pivotal role in the creation of a diagnostic algorithm for patients with suspected COVID-19 pneumonia, and a predictive CT score may be useful. We evaluated the main CT features related to COVID-19 pneumonia and SSc-ILD, trying to identify the specific lesions that could help in differential diagnosis. We decided on a multi-step evaluation of CT alterations, taking into account the relative expertise of the CT readers, to highlight the relevance of specific expertise in chest CT for imaging evaluation. Surprisingly, we found low agreement among chest RADs in distinguishing between prevalent anterior/posterior (or no prevalence) distribution of lung disease and of lower zone GGOs, regardless of the clear anatomic landmarks. The presence of more than one alteration may create confusion in the interpretation of the general disease distribution. In fact, all the CT features, when considered one-by-one by the readers, obtained a higher agreement in both lung zones for anterior/posterior distribution, except for lower zone GGOs in which the agreement was lower. In SSc-ILD, GGOs can be considered either inflammatory or fibrotic, while RET is usually interpreted as a fibrotic alteration [23]. Thus, we believe that GGOs could have been occasionally interpreted as thin RETs, and vice

TABLE 3 Multivariate analysis with backward selection method results

CT parameter	Level	OR (95% CI)	P-value	AUC (95% CI)
Consolidation Lower zone	No	Reference		0.97 (0.94, 1.00 CI)
	Yes	69.41 (7.81, 616.801)	0.0001*	
GGO with fibrosis Lower zone	Absence	21.65 (1.51, 310.0)	0.0236*	
	No	119 0.61 (12.13, 999.99)	<0.0001*	
	Yes	Reference		
Focal GGO with fibrosis Upper zone		Excluded	0.99	
Reticulations lower zone		Excluded	0.89	
Rounded GGOs lower zone		Excluded	0.97	

* $P < 0.05$. GGOs: ground glass opacities; absence: absence of the alterations for which the subanalysis should have been performed; OR: odds ratio; AUC: area under the curve.

Fig. 1 The clinical interpretation of the COVID-19 pneumonia predictive score

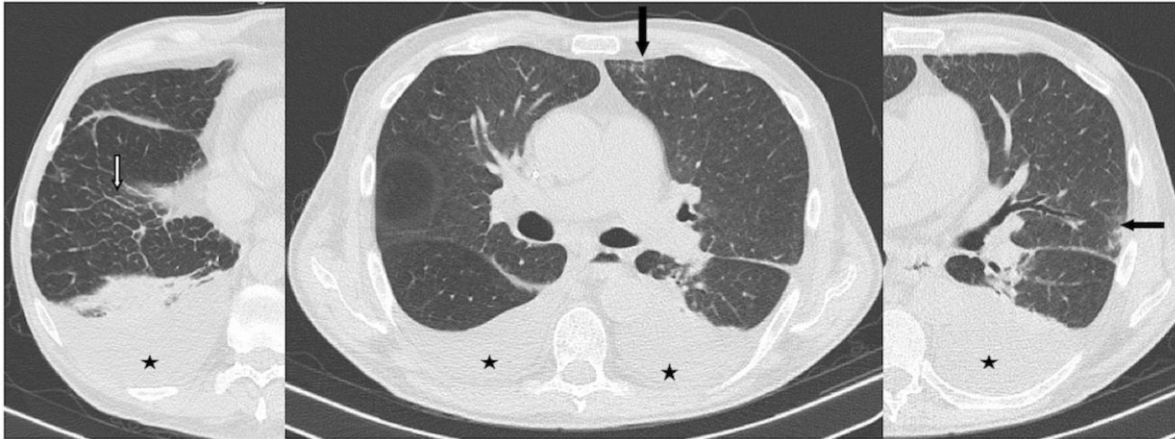CT IMAGES	LEGEND	TOTAL CT SCORE	P	CT IMAGES	LEGEND	TOTAL CT SCORE	P
	Presence of CONs in lower zone (4 points) Presence of GGOs without fibrosis in lower zone (5 points)	4 + 5 = 9	5–9 points: HIGH PROBABILITY of COVID-19 PNEUMONIA		Presence of CONs (4 points) in lower zone Presence of GGOs with fibrosis in lower zone	4	4 points: PROBABLY COVID-19 PNEUMONIA in SSc-ILD
	Presence of CONs in lower zone (4 points) Absence of GGOs in lower zone (3 points)	4 + 3 = 7			Absence of GGOs (3 points) in lower zone, presence of HC and RET.	3	0–3 points:
	Presence of GGOs without fibrosis in lower zone (5 points) Absence of CONs in lower zone	5			Absence of CONs in lower zone (0 points), GGOs with fibrosis in lower zone (0 points)	0	LOW PROBABILITY of COVID-19 PNEUMONIA

A–C: High probability of COVID-19 pneumonia; **D:** Probably COVID-19 pneumonia in SSc-ILD; **E–F:** Low probability of COVID-19 pneumonia. ILD: interstitial lung disease; GGOs: ground glass opacities; RETs: reticulations; HC: honeycombing; CONs: consolidation.

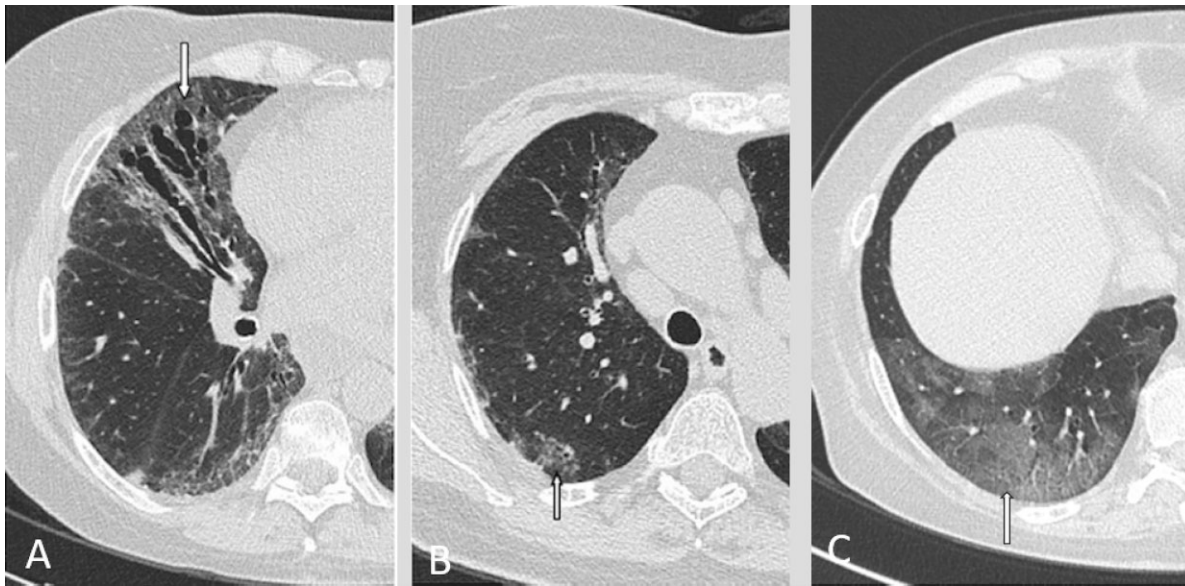versa. This could explain the low agreement about RET presence in upper zones, where fibrotic fine RETs may be less represented and considered to be GGOs. Following the same rationale, CP, defined as GGOs superimposed on RETs, may suffer from different evaluation in the lower zones, where fibrotic alterations can be more pronounced and all considered as RET, instead of CP. The definition of multifocal and diffuse pattern (Supplementary Fig. 1, available at *Rheumatology* online) that we proposed, as well as the recent identification of vessel thickening as a feature of COVID-19 pneumonia, may have partially caused the low agreement for upper zone GGO patterns and vessel thickening.

On the upper zones, where lung alterations may more frequently have a patchy-irregular distribution, distinguishing between focal and diffuse disease may represent an additional challenge. In fact, GGOs may have blurred margins, making it hard to define shape and dimensions. This could justify the lower agreement in GGO pattern assessment in the upper zones. Moreover, HC showed a low agreement in the upper fields, as expected, since HC and paraseptal emphysema are hard to distinguish and may be misinterpreted (Supplementary Fig. 3, available at *Rheumatology* online) [24]. It should be noted that the only two cases of both SSc ILD and COVID-19 pneumonia were misdiagnosed

by most of nRADs, RADs and chest RADs (Fig. 2), while in some subjects the coexistence of both diseases was wrongly suggested by chest RADs. Thus, regarding the RSNA CT patterns [13], we can assume that radiologic differential diagnosis is reliable for pure lung disease. Where there are no clinical doubts in distinguishing between COVID-19 and SSc-ILD, the relevance of CT evaluation in differential diagnosis is less significant, but it becomes relevant in the identification of lung disease in COVID-19-infected SSc patients. This was confirmed by our results, and the aspects that may help in differential diagnosis are CONs for COVID-19 pneumonia (Supplementary Fig. 4, available at *Rheumatology* online) and fibrosis inside GGOs for SSc-ILD (Fig. 3). However, CONs can be absent, especially during the early phase of COVID-19, when GGOs may be the only obvious CT feature. In this case the clinical decision may be relevant because prompt therapy is mandatory. In fact, CONs were absent in the only subject with coexistence of both diseases, and few readers made the right diagnosis. This was in line with the few reports present in the literature. Cheng *et al.* [24] observed a COVID-19 pneumonia superimposed on SSc-ILD, with GGOs being the main manifestations, suggesting specific care should be used when only GGOs are present. In fact, though associated signs of fibrosis may be suggestive of SSc-ILD alone,

Fig. 2 COVID-19 pneumonia in patient with SSc-ILD

Covid pneumonia in SSc patients. Basal smooth RET (white arrow), in presence of pleural effusion, and GGOs (black arrows), were considered as manifestations of disease other than COVID-19 pneumonia and/or SSc-ILD (pulmonary edema) by most of the readers. ILD: interstitial lung disease; GGOs: ground glass opacities; RET: reticulations.

Fig. 3 Focal fibrosis inside GGO; GGO with and without fibrosis

A: SSc-ILD, right lung, upper zone. Focal alteration with bronchiectasis at the periphery of upper lobe, configuring signs of fibrosis (white arrow). **B:** SSc-ILD, lower zone. Bilateral diffuse GGO with bronchiectasis, configuring signs of fibrosis (white arrow). **C:** COVID-19, lower right lobe: GGO without fibrosis (white arrow). ILD: interstitial lung disease; GGO: ground glass opacities.

GGOs without fibrosis may potentially represent both diseases. On the other hand, Mariano *et al.* [25] made a diagnosis of COVID-19 pneumonia on SSc-ILD, thanks to the presence of a CON superimposed on a UIP pattern in the right lower lobe. Fibrosis in focal GGOs in the upper zones and RETs in the lower zones did not result independent predictors of SSc-ILD, and neither were rounded GGOs in the lower zones predictors of COVID-19 pneumonia (Supplementary Fig. 5, available at *Rheumatology* online). In fact, in both diseases the absence of fibrosis in focal

alteration as well as lower rounded GGO may be encountered. Thus, on an SSc-ILD background, the appearance of rounded GGOs may raise the suspicion of COVID-19 pneumonia overlapping with SSc-ILD. This is because fibrotic alterations are not present during the acute phase of COVID-19 pneumonia and a diagnosis of SSc-ILD might be assumed (Fig. 3), though we cannot exclude that an acute focal manifestation of COVID-19 pneumonia may appear over focal signs of fibrosis. Furthermore, RETs are less frequent in COVID-19 pneumonia (Fig. 1).

The two principal items [presence of CONs and presence of GGOs without fibrosis (Fig. 3) in the lower lobes] were included in a predictive score positively associated with a COVID-19 diagnosis (Fig. 1), as follows: *high risk* of COVID-19 pneumonia (5–9 points); *probable overlap* of COVID-19 pneumonia in SSc-ILD (4 points); *low risk* of COVID-19 pneumonia (0–3 points).

The score showed an excellent diagnostic accuracy with high sensibility and specificity (Supplementary Fig. 2, available at *Rheumatology* online) and could therefore be useful in the clinical routine. However, we recommend considering that GGOs without fibrosis may be expressions of non-fibrotic NSIP. We strongly suggest clinicians consider the presence of both CONs and non-fibrotic GGOs as signs of COVID-19 pneumonia alone only in the presence of other suggestive signs (i.e. rounded shape) and in the absence of typical SSc-ILD abnormalities (i.e. RETs).

The strength of this study is the number of patients who were examined, and the high number of readers and considered variables. However, it is important to note that our aim was not to compare the two patterns in order to find the main features that may then help differentiating the two diseases when superimposed. In this work, only a few cases of COVID-19 superimposed on SSc-ILD were analysed, and COVID-19 and SSc-ILD CT images at different stages of the diseases with diverse disease duration and ILD stage were studied.

In conclusion, our study showed that CT differential diagnosis of COVID-19 pneumonia and SSc-ILD might be successfully achieved in practice. This could be performed by the rheumatologist, but specific expert evaluation by a RAD is always recommended, in particular if an overlap of both diseases is suspected.

Our results, and in particular the presence of CONs in the lower lobes and of fibrosis inside GGOs, may help in differentiating the diseases and drive the physician towards an early diagnosis either of SSc-ILD progression or of an overlap of COVID-19 in SSc-ILD. In the future, our results should be confirmed in a much larger cohort of patients in which both diseases coexist.

Authors Contributors: M.O., M.M.C., S.G., S.C. and A.M.P. were involved in the study design. M.O., N.L., M.M.C., E.C., V.V. and G.C. determined the methodology. N.L., G.S., C.B., S.B.R., J.B., D.M., M.H., C.P.D., F.L., B.R., F.D.C., G.D.L., M.S., L.Z., S.T., A.C., E.C., M.A., F.M., S.P., V.V., G.C., F.D.C. and C.V. were CT readers. M.O., N.L. and C.N. collected data. L.T., M.O. and N.L. undertook statistical analysis. M.O., N.L., F.W.R., C.C., G.S., L.T., S.C. and M.M.C. interpreted the results. M.O. and N.L. did the initial manuscript drafting. M.M.C. and S.C. made the first revision, and Y.A., A.B., M.C., L.D., M.D.P., S.H., D.K., M.K., G.T., F.L., V.M., G.M. and A.P. made revisions.

All authors had full access to the database and the statistical analysis.

All authors approved the final version of the manuscript.

Funding: No specific funding was received from any bodies in the public, commercial or not-for-profit sectors to carry out the work described in this article.

Disclosure statement: S.C. reports personal fees from Novartis, Sanofi, Lilly, Celther, Pfizer and Janssen, outside the submitted work;

M.K. reports grants and personal fees from Boehringer-Ingelheim, personal fees from Corbus, grants and personal fees from Chugai, grants and personal fees from Ono Pharmaceuticals, personal fees from Tanabe-Mitsubishi, personal fees from Astellas, personal fees from Gilead, personal fees from Mochida, all outside the submitted work;

S.T. reports personal fees from Boehringer Ingelheim, personal fees from Roche, both outside the submitted work;

G.S. reports personal fees from Boehringer Ingelheim, outside the submitted work;

C.B. reports personal fees from Actelion, personal fees from Eli Lilly, grants from the European Scleroderma Trial and Research (EUSTAR) group, grants from the New Horizon Fellowship, grants from the Foundation for Research in Rheumatology (FOREUM), grants from Fondazione Italiana per la Ricerca sull'Artrite (FIRA), all outside the submitted work;

C.V. reports grants and personal fees from Boehringer Ingelheim, grants and personal fees from F. Hoffmann-La Roche Ltd., outside the submitted work;

F.L. reports lecture fees from Roche and from Boehringer-Ingelheim;

C.P.D. reports grants and personal fees from GSK, personal fees from Boehringer Ingelheim, grants from Servier, grants and personal fees from Inventiva, grants and personal fees from Arxx Therapeutics, personal fees from Corbus, personal fees from Sanofi, personal fees from Roche, outside the submitted work;

F.L. reports grants and personal fees from GSK, personal fees from Boehringer Ingelheim, personal fees from Orion Pharma, personal fees from AstraZeneca, grants from MSD, personal fees from HIKMA, personal fees from Trudell International, grants and personal fees from Chiesi Farmaceutici, personal fees from Novartis Pharma, all outside the submitted work;

M.H. reports personal and speaking fees from Actelion, Eli Lilly and Pfizer, outside the submitted work;

D.K. reports personal fees from Actelion, grants and personal fees from Bayer, grants and personal fees from Boehringer Ingelheim, personal fees from CSL Behring, grants and personal fees from Horizon, grants from Pfizer, personal fees from Corbus, grants and personal fees from BMS, outside the submitted work; and D.K. is the Chief Medical officer of Eicos Sciences Inc and has stock options, outside the submitted work.

All other authors have declared no competing interests.

Data availability statement

A deidentified dataset will be made available upon request to the corresponding author at least 1 year after the publication of this study. The request must include a statistical analysis plan.

Supplementary data

Supplementary data are available at *Rheumatology* online.

References

- 1 CDC COVID-19 Response Team. Preliminary estimates of the prevalence of selected underlying health conditions among patients with coronavirus disease 2019 – United States, February 12–March 28, 2020. *MMWR Morb Mortal Wkly Rep* 2020;69:382–6.
- 2 Orlandi M, Lepri G, Damiani A *et al.* One year in review 2020: systemic sclerosis. *Clin Exp Rheumatol* 2020; 38(Suppl 125):3–17.
- 3 Volkman ER. Natural history of systemic sclerosis-related interstitial lung disease: how to identify a progressive fibrosing phenotype. *J Scleroderma Relat Disord* 2020;5:31–40.
- 4 Fujita J, Yoshinouchi T, Ohtsuki Y *et al.* Non-specific interstitial pneumonia as pulmonary involvement of systemic sclerosis. *Ann Rheum Dis* 2001;60:281–3.
- 5 Orlandi M, Lepri G, Bruni C *et al.* The systemic sclerosis patient in the COVID-19 era: the challenging crossroad between immunosuppression, differential diagnosis and long-term psychological distress. *Clin Rheumatol* 2020; 39:2043–7.
- 6 Orlandi M, Landini N, Bruni C *et al.* Infection or autoimmunity? The clinical challenge of interstitial lung disease in systemic sclerosis during the COVID-19 pandemic. *J Rheumatol* 2020;48:790–92.
- 7 Landini N, Orlandi M, Fusaro M *et al.* The role of imaging in COVID-19 pneumonia diagnosis and management: main positions of the experts, key imaging features and open answers. *J Cardiovasc Echogr* 2020;30:S25–S30.
- 8 Goldin JG, Lynch DA, Strollo DC *et al.*; Scleroderma Lung Study Research Group. High-resolution CT scan findings in patients with symptomatic scleroderma-related interstitial lung disease. *Chest* 2008;134:358–67.
- 9 Launay D, Remy-Jardin M, Michon-Pasturel U *et al.* High resolution computed tomography in fibrosing alveolitis associated with systemic sclerosis. *J Rheumatol* 2006; 33:1789–801. PMID: 16960939.
- 10 Desai SR, Veeraraghavan S, Hansell DM *et al.* CT features of lung disease in patients with systemic sclerosis: comparison with idiopathic pulmonary fibrosis and nonspecific interstitial pneumonia. *Radiology* 2004; 232:560–7.
- 11 King TE Jr. Nonspecific interstitial pneumonia and systemic sclerosis. *Am J Respir Crit Care Med* 2002;165:1578–9.
- 12 Rubin GD, Ryerson CJ, Haramati LB *et al.* The role of chest imaging in patient management during the COVID-19 pandemic: a multinational consensus statement from the Fleischner Society. *Radiology* 2020;296:172–80.
- 13 Simpson S, Kay FU, Abbara S *et al.* Radiological Society of North America Expert Consensus statement on reporting chest CT findings related to COVID-19: endorsed by the Society of Thoracic Radiology, the American College of Radiology, and RSNA – secondary publication. *J Thorac Imaging* 2020;35:219–27.
- 14 van den Hoogen F, Khanna D, Fransen J *et al.* 2013 classification criteria for systemic sclerosis: an American College of Rheumatology/European League against Rheumatism collaborative initiative. *Arthritis Rheum* 2013;65:2737–47.
- 15 Prosch H, Schaefer-Prokop CM, Eisenhuber E, Kienzl D, Herold CJ. CT protocols in interstitial lung diseases—a survey among members of the European Society of Thoracic Imaging and a review of the literature. *Eur Radiol* 2013;23:1553–63.
- 16 Nishino M, Itoh H, Hatabu H. A practical approach to high-resolution CT of diffuse lung disease. *Eur J Radiol* 2014;83:6–19.
- 17 Hansell DM, Bankier AA, MacMahon H *et al.* Fleischner Society: glossary of terms for thoracic imaging. *Radiology* 2008;246:697–722.
- 18 Bai HX, Hsieh B, Xiong Z *et al.* Performance of radiologists in differentiating COVID-19 from non-COVID-19 viral pneumonia at chest CT. *Radiology* 2020;296:E46–E54.
- 19 Calabrò L, Peters S, Soria JC *et al.* Challenges in lung cancer therapy during the COVID-19 pandemic. *Lancet Respir Med* 2020;8:542–4.
- 20 Rodriguez-Morales AJ, Cardona-Ospina JA, Gutiérrez-Ocampo E *et al.*; Latin American Network of Coronavirus Disease 2019-COVID-19 Research (LANCOVID-19). Electronic address: <https://www.lancovid.org>. Clinical, laboratory and imaging features of COVID-19: a systematic review and meta-analysis. *Travel Med Infect Dis* 2020;34:101623.
- 21 Yang J, Zheng Y, Gou X *et al.* Prevalence of comorbidities and its effects in patients infected with SARS-CoV-2: a systematic review and meta-analysis. *Int J Infect Dis* 2020;94:91–5.
- 22 Chen N, Zhou M, Dong X *et al.* Epidemiological and clinical characteristics of 99 cases of 2019 novel coronavirus pneumonia in Wuhan, China: a descriptive study. *Lancet* 2020;395:507–13.
- 23 Capobianco J, Grimberg A, Thompson BM *et al.* Thoracic manifestations of collagen vascular diseases. *Radiographics* 2012;32:33–50.
- 24 Cheng C, Li C, Zhao T *et al.* COVID-19 with rheumatic diseases: a report of 5 cases. *Clin Rheumatol* 2020;39: 2025–9.
- 25 Mariano RZ, Rio APTD, Reis F. Covid-19 overlapping with systemic sclerosis. *Rev Soc Bras Med Trop* 2020; 53:e20200450.