

Laser systems for gingival retraction in fixed prosthodontics: A narrative review

➤ **R. SORRENTINO, G. RUGGIERO, F. ZARONE**

¹Department of Neurosciences, Reproductive and Odontostomatological Sciences, Division of Prosthodontics and Digital Dentistry, University "Federico II" of Naples, Naples, Italy

TO CITE THIS ARTICLE

Sorrentino R, Ruggiero G, Zarone F. Laser systems for gingival retraction in fixed prosthodontics: A narrative review. *J Osseointegr* 2022;14(1):1-5.

DOI 10.23805 /JO.2022.14.9

KEYWORDS Gingiva displacement; Gingiva troughing; Gingiva retraction; Laser; Dental impression.

ABSTRACT

Aim The present narrative review aimed to shed light on the use of laser systems for gingival retraction procedures necessary for the exposure of iuxta- and sub-gingival finish lines before impression making in fixed prosthodontics.

Methods An extensive search of the literature was made on the electronic databases of Pubmed (Medline), Scopus, Embase, Google Scholar, Dynamed, and Open Grey. No limitations were applied to the date of publication. The following keywords and MeSH terms were used: "gingiva", "displacement", "troughing", "retraction", and "laser".

Results Out of 344 studies found, 25 records were included for review. Laser systems are efficient in gingival retraction, allowing better intraoperative haemostasis control and postoperative patient comfort than other surgical troughing procedures. Laser-mediated gingival displacement seems to be safe particularly in the case of thick gingival biotype.

Conclusions As regards laser-related issues in prosthodontics such as pre-setting protocols of laser devices, the best laser system in gingival retraction, their use around implants and effectiveness compared to other troughing systems, further in vitro, in vivo, and randomized controlled trial studies are needed.

of approximately 0.2 mm is mandatory to allow the impression material to flow within the sulcus with proper dimensional accuracy (1). Furthermore, retraction procedures must take place in a way that does not injure the basal cell layer and connective tissue cells, in order to avoid tissue changes and shrinkage of the gingiva (1). Various gingival retraction systems have been described in the literature, which are as follows.

1. Mechanical systems, such as retraction cords or pastes.
2. Chemomechanical systems, with cords impregnated with hemostatic solutions.
3. Surgical procedures, such as gingivectomy or electrosurgery based on the use of electrotomes.
4. Laser surgery involving diode lasers, neodymium-doped yttrium-aluminum-garnet (Nd:YAG), erbium-doped yttrium-aluminum-garnet (Er:YAG), erbium, chromium-doped yttrium-scandium-gallium-garnet (Er,Cr:YSGG), and CO₂ laser systems (2-4).

Several investigations confirmed the effectiveness of laser systems in gingival retraction (1,4-6), through the removal of about 200 µm epithelium thickness from the sulcus (4), as a painless, simple, and convenient procedure (5).

The characteristics of the several types of laser systems are related to waveforms and wavelength (7).

Lasers are based on a high-powered focused beam operating by photo-ablation that causes tissue vaporization at 100-150 °C and they incise tissues without hemorrhage and by fast healing with no inflammation and pain (7-8).

A survey of 696 dentists in the USA and Canada reported that 92% of them use gingival displacement cords, while 20.2% use laser systems and 32% electrosurgery as an adjunct for gingival troughing (9).

To date, the effectiveness of laser technologies in gingival retraction is clear, but despite their use in this procedure, there are still many points to be clarified. The first is: what are the disadvantages and advantages related to

INTRODUCTION

The accuracy of the marginal fit of a fixed prosthesis mainly depends on the detection of the finish line of the tooth to be restored. This is possible by making an impression of the finish line, which, if subgingival, can be shown through the retraction of the gingiva itself. This gingival retraction must take place both apically and laterally, to allow accurate registration of all the details of the finish line through the use of impression materials or intraoral scanners. A minimum lateral displacement

the use of lasers compared to other systems for gingival retraction. Moreover, it should be investigated whether laser is better than other gingival retraction methods. Lastly: what is the best type of laser for gingival retraction and how to set them.

The purpose of the present narrative review is to shed light on the use of dental lasers for gingival retraction procedures, in particular, the pre-setting of laser devices, advantages and disadvantages of laser retraction devices, and the comparison with other gingival retraction systems.

METHODS

Search strategy

An electronic literature search was performed using the following databases: Medline (using PubMed), Scopus, Embase, Google Scholar, Dynamed, and Open Grey. Articles published up to August 31 2021, were considered. The electronic search was conducted using keywords and MeSH terms connected by the Boolean operators "AND", "OR":

- (gingiva AND displacement AND laser);
- (gingiva AND displacing AND laser);
- (gingiva AND troughing AND laser);
- (gingiva AND retraction AND laser).

Only with the Google Scholar database, the following combination was used: (gingiva) and (retraction or displacement or displacing or troughing) and (laser).

To avoid the lack of relevant papers, the authors examined the reference lists of the identified records.

In the present literature search, no time limits were considered for the year of publication of the records.

Inclusion and exclusion criteria

Studies were deemed suitable for the present review if they met the following inclusion criteria: 1) studies in which at least one laser system was used or tested for gingival retraction, 2) *in vivo* or *in vitro* studies, systematic reviews, or case reports, and 3) studies published in English language.

Exclusion criteria were: non-human animals *in vivo* studies, and studies published in languages other than English.

Data extraction

According to the inclusion criteria, 3 calibrated researchers independently selected the studies reading the titles, abstracts, and keywords. The full text of each identified article was read to decide if it was suitable for inclusion. A majority criterion (i.e., 2 out of 3) was used in the case of disagreement among the investigators.

RESULTS

Study selection

The search strategy produced 344 records, many of

which were duplicates, 49 from PubMed/Medline, 49 from Scopus, 44 from Embase, 202 from Google Scholar, and 0 from both Dynamed and Open Grey. All the duplicates were discarded, thereby all the selected databases produced 164 records. After evaluating titles, abstracts, and keywords, the reviewers deleted 121 papers that did not meet the inclusion criteria. After a full-text analysis of the remaining 43 papers, 18 more were discarded because they did not provide any useful information about laser systems for gingival retraction. The remaining 25 records were included in the present review. No systematic reviews were found.

The literature search was concluded in August 2021, and the papers included in the present review were published between 1995 and 2019.

Among the search investigators, no disagreement was reported.

The workflow of the paper screening process followed the "PRISMA 2009 Flow Diagram" (10) (Fig. 1).

Advantages and disadvantages, indications, and contraindications

Several advantages can be related to the use of dental laser systems for gingival retraction.

First of all, the reduced bleeding during laser-surgical procedures (4,7,11-13) and postoperative hemostasis (3-4,14), both determined by coagulation through tissue vaporization, should be considered. Besides, the reduced intra-operative bleeding is accompanied by minor mechanical trauma (13), which favors less postoperative swelling and scarring (13). It is worth noticing that

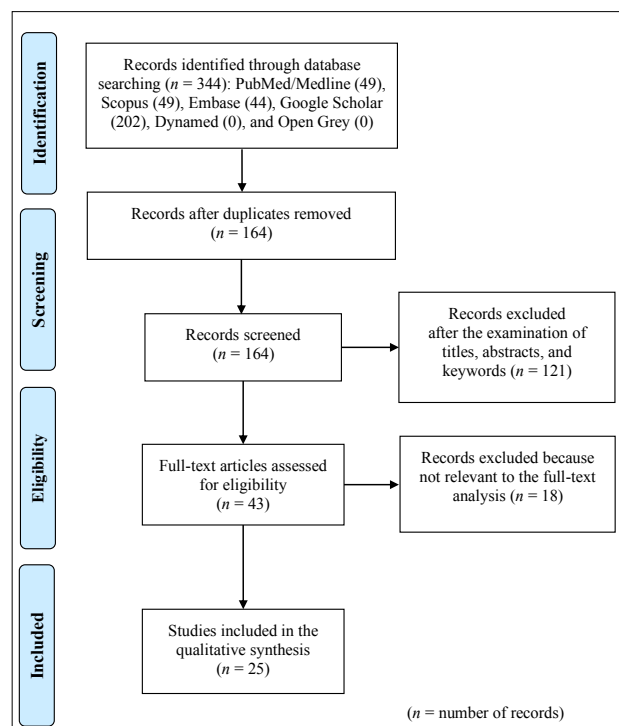


FIG. 1 PRISMA (10) search workflow.

laser-induced surgical wounds heal with secondary intention, and incision lines display disorganized fibroblast alignment. This helps to preserve gingival margin heights by reducing tissue shrinkage caused by scarring (7).

The characteristic hemostasis of laser technologies facilitates the procedure for impression making on multiple abutments. This is very important because, in the case of zirconia frameworks that are becoming more and more popular (15), greater accuracy of impressions is required than those in metal alloy, as zirconia cannot be soldered to compensate for the inherent imprecision in impressions (16). Moreover, thanks to coagulation properties, laser systems are helpful for digital scanning in order to provide a dry and clear surface for the scanning procedure (2).

Differently from electrocoagulation, lasers technology provides a reduced collateral heat generation (4) on soft and hard tissue, also with control of heat transfer to adjacent tissues (14).

Generally, the procedure of gingiva displacement seems to be relatively painless (3,13,17), improving patient comfort (4,11-12).

Finally, it should be considered that laser systems could be effectively managed not requiring local anesthesia for gingival troughing, especially in the case of gingival hypertrophied tissues (8).

Despite the many advantages related to laser-mediated gingival retraction, it should be considered that this procedure is technique sensitive (13,17), without tactile

feedback (18). Also, it is complicated to visualize the laser beam, due to the cooling water (18) and exposure of the prosthetic crown margins and tissue shrinkage could occur when overused (8).

Trainor et al. suggested to not use laser systems on thin gingiva in order to avoid recession (19). Additionally, differently from the CO₂ laser, Nd:YAG systems are not recommended on peri-implant soft tissues because the implant surfaces tend to absorb heat and transport it towards bone tissues (20–21). Indeed, unlike other lasers, the technology behind CO₂ lasers has water as the prime chromophore which bounces off metal surfaces. Close to metal implant surfaces, CO₂ lasers absorb little energy, with only minimal temperature increase (<3 °C), minor collateral damage, and without altering the structure of implant surfaces. CO₂ lasers uncover the implant margins by creating a trough by excision instead of displacing soft tissues (22). Hence, if they are adopted around deeply positioned implants, significant defects may occur (17,21). Also 2.940 nm Er:YAG lasers could be considered reasonably safe because their wavelengths are reflected on metal implant surfaces also with a minimum penetration of the soft tissues, but its hemostasis is not as efficient as that of CO₂ lasers (21).

Pre-setting of laser devices

Laser devices have preset parameters based on the type of dental procedure to be performed, but at the same time, it is possible to customize these settings (2).

Several protocols were described in the literature for

REFERENCE	LASER SYSTEM (WAVELENGTH)	POWER (W)	MODE	FREQUENCY (HZ)	FIBER TIP DIAMETER (µm)
Dawani et al. 2016 (1)	Diode Laser (810 nm)	0.8	Continuous	25.000	400
Marsch 2013 (2)	Diode laser (970 nm)	2.0	Pulsed	20	320
Krishna et al. 2013 (4)	Diode Laser (980 nm)	0.8	Continuous		
Goutham et al. 2018 (6)	Diode Laser (wavelength not specified)	0.8	Continuous	25.000	400
Gherlone et al. 2004 (23)	Diode Laser (980 nm)	2.5 to 3.5	Continuous		
Gherlone et al. 2004 (23)	Nd:YAG (1064 nm)	2.5 to 4.0		25 to 40	
Gururaj et al. 2019 (24)	Diode Laser (810 nm)	0.8	Continuous	25.000	400
Gupta et al. 2012 (25)	Diode Laser (980 nm)	1.5	Continuous		320
Stuffken and Vahidi 2016 (26)	Diode Laser (810 nm)	0.7 to 2.0	Continuous		
Melilli et al. 2018 (27)	Diode Laser (940 nm)	0.9	200 µs pulse duration	20	300
Tao et al. 2018 (28)	Diode Laser (810 nm)	2.0	Continuous	20	320
Tao et al. 2018 (28)	Nd:YAG (1064 nm)	2.0	Short pulse	15	320
Tao et al. 2018 (28)	Er:YAG (2940)	2.0	Very long pulse	15	500

TABLE 1 Laser settings used for gingival retraction as reported in the literature.

the various types of lasers, where the settings of the main parameters vary, as described in Table 1.

Some authors suggested inserting the fiber tip to a depth of 1.0 to 1.5 mm into the crevicular sulcus (4,23) with a circular movement around the tooth (23), in the same manner of a conventional scalpel (8). Although many authors set a continuous mode (1,4,6,23–26), Lee (16) suggests using the laser beam in a pulsed mode where possible with the addition of spray water and air cooling during the procedure.

Comparison among lasers and other gingival retraction systems

Several clinical studies evaluated the effectiveness of laser systems in gingival retraction and focused on the biological impact of these technologies, particularly on periodontal structures, sometimes through comparisons with other gingival retraction systems or among different types of laser systems.

The results of clinical investigations are different, sometimes discordant, as they were conducted with different research protocols.

A clinical investigation reported that a diode laser produced greater mean lateral gingival displacement (0.48 ± 0.10 mm) than magic foam cord, an expanding polyvinyl siloxane (Coltene Whaledent Inc, Altstätten, Switzerland) (0.31 ± 0.09 mm), and retraction cord impregnated with aluminum chloride (0.44 ± 0.11 mm) (6). These findings were confirmed by another study in which diode laser produced a wider lateral displacement (0.62 ± 0.09 mm) than magic foam cord (0.42 ± 0.04 mm) (1). Conversely, another clinical study reported that retraction cord produced a larger lateral displacement (0.33 mm) than diode laser (0.31 mm) and magic foam cord (0.19 mm).

The effectiveness of gingival retraction can be highlighted by noticing that laser systems determine a gingival troughing of about 230–670 μ m, a range similar to the sulcular epithelium thickness and wider than the minimum limit of 200 μ m needed for retraction (4,19). As regards the depth of the gingival sulcus, the retraction cord showed the best value (1.43 mm), followed by diode laser (1.24 mm) and, finally, by magic foam cord (0.81 mm) (24).

Diode laser also seems to be the fastest gingival retraction system (mean value = 56.20 s) compared to magic foam cord (85.75 s) and retraction cord (252.15 s). Furthermore, compared to the latter troughing system, the diode laser procedure appears to be simpler (24).

One clinical study showed that the use of pulsed Nd:YAG laser allowed faster healing and lower inflammation and hemorrhage than retraction cords impregnated with ferric sulphate or aluminum chloride (5). Furthermore, another investigation reported a better hemorrhage control of diode laser than retraction cord, although it was worse than magic foam cord (24).

As regards gingival recession, comparable but not

clinically significant differences were reported for the double-cord technique impregnated with aluminum chloride cords (mean = 0.26 mm) and diode laser (0.27 mm) 8 weeks after cementation (26).

Different authors reported a greater gingival recession with the double-cord and electro-surgery systems compared to diode and Nd:YAG lasers (23). Furthermore, both these laser systems were found to be less aggressive also about gingival bleeding. In effect, less bleeding occurred with lasers than with the double-cord technique. Finally, the same authors observed that the diode laser has a haemostatic capacity similar to that of electrosurgery and superior to that of Nd:YAG (23). According to the Visual Analog Scale (VAS) assessment system, the use of the diode laser (mean = 9.37) is significantly easier than the cord retraction technique (6.79). Furthermore, diode laser saved time (mean = 16.46 ± 3.2 s) more than cord (185.26 ± 46.2 s) and is considered more comfortable according to VASs (mean of diode laser = 9.4; mean of cord = 5.95) (27). A clinical study did not record bleeding on the 35 tooth that underwent laser procedure, while out of 39 abutments with the cord system, bleeding was observed in 10 during retraction and 8 after retraction. No significant difference was detected between the two retraction systems for gingival retraction immediately after each procedure (mean cord = 0.65 ± 0.33 mm; mean laser = 0.66 ± 0.43 mm) and 15 days after impression (mean cord = 0.03 ± 0.27 mm; mean laser = 0.02 ± 0.46 mm) (27).

Another comparative study measured the gingival width and recession occurred with the following gingival troughing systems: retraction cord and diode, Nd:YAG, and Er:YAG laser systems (28). Significant differences resulted between lasers and retraction cords in gingival width, with the following mean values immediately after retraction: retraction cord = 0.32 ± 0.09 mm, diode = 0.55 ± 0.15 mm, Nd:YAG = 0.60 ± 0.17 mm, Er:YAG = 0.65 ± 0.14 mm. Also, regarding gingival recession, statistical differences were found between lasers and retraction cords, with the following mean values 4 weeks after surgery: retraction cord = 0.24 ± 0.08 mm, diode = 0.13 ± 0.08 mm, Nd:YAG = 0.14 ± 0.07 mm, Er:YAG = 0.10 ± 0.06 mm. These results showed wider gingival width and less gingival recession for lasers than retraction cord. Also, the authors reported that among laser systems, Er:YAG exhibited the most uneventful and rapid wound healing when compared to diode and Nd:YAG lasers (28).

CONCLUSION

According to the current literature, the following conclusions can be drawn.

- Laser systems provide optimal postoperative hemostasis and minor mechanical trauma that favors less postoperative swelling and scarring which

preserve gingival margin heights.

- CO₂ and Er:YAG lasers could be used on peri-implant soft tissues while Nd:YAG systems are contraindicated.
- Diode laser produces a greater lateral gingival displacement than magic foam cord. Also, it seems to be the faster, more comfortable, and simpler gingival retraction system compared to magic foam cord and retraction cord.
- Nd:YAG laser allowed faster healing, better hemostasis, and lower inflammation than retraction cords impregnated with ferric sulphate or aluminum chloride.

To date, the data concerning the lateral and vertical displacement of the gingiva are still scarce and often controversial due to the different research protocols and the few available studies.

Laser technologies are efficient systems for gingival retraction and appear safe when used for thick gingival biotypes. Nevertheless, more *in vitro* or *in vivo* studies, and randomized controlled trials are mandatory to define the clinical indications around implants, the best laser system for gingival retraction and the pre-setting protocol, and their effectiveness with respect to other retraction systems.

REFERENCES

1. Dawani M, Sathe S, Godbole SR. Comparative evaluation of clinical efficacy of two new gingival retraction systems - An *in vivo* research. *Int J Sci Res* 2016;5:4-10.
2. Marsch A. Use of a diode laser for gingival troughing in conservative and prosthetic dentistry. *Int Mag Laser Dent* 2013;30-1.
3. Martin E, Parker S. The use of lasers in fixed prosthodontics. *Dent Clin North Am* 2004;48:971-98.
4. Krishna CV, Gupta N, Reddy KM, Sekhar NC, Aditya V, Reddy GV. Laser gingival retraction: a quantitative assessment. *J Clin Diagn Res* 2013;7:1787-8.
5. Gabbar AF, Aboulazm SF. Comparative study on gingival retraction using mechanochemical procedure and pulsed Nd = YAG laser irradiation. *Egypt Dent J* 1995;41:1001-6.
6. Goutham GB, Jayanti I, Jalaluddin M, Avijeeta A, Ramanna PK, Joy J. Clinical assessment of gingival sulcus width using various gingival displacement materials. *J Contemp Dent Pract* 2018;19:502-6.
7. Parker S. The use of lasers in fixed prosthodontics. *Dent Clin North Am* 2004;48:971-98.
8. Kamath R, Sarandha DL, Baid GC. Advances in gingival retraction. *Int J Clin Dent Sci* 2011;2:64-7.
9. Ahmed SN, Donovan TE. Gingival displacement: Survey results of dentists' practice procedures. *J Prosthet Dent* 2015;114:81-5.e1-2.
10. Liberati A, Altman DG, Tetzlaff J, Mulrow C, Gøtzsche PC, Ioannidis JP, Clarke M, Devereaux PJ, Kleijnen J, Moher D. The PRISMA statement for reporting systematic reviews and meta-analyses of studies that evaluate health care interventions: explanation and elaboration. *PLoS Med* 2009;6:e1000100, <https://doi.org/10.1371/journal.pmed.1000100>.
11. Coluzzi DJ, Convissar RA. Lasers in clinical dentistry. *Dent Clin North Am* 2004;48:11-2. <https://doi.org/10.1016/j.cden.2004.06.003>.
12. Donovan TE, Chee WW. Current concepts in gingival displacement. *Dent Clin North Am* 2004;48:433-44.
13. Singh DK, Gupta P, Bhatnagar A. Gingival displacements options in prosthodontics: A critical review on recent advances. *J Adv Res Dent Oral Health* 2016;1:13-21.
14. Rossmann JA, Cobb CM. Lasers in periodontal therapy. *Periodontol* 2000 1995;9:150-64.
15. Zarone F, Di Mauro MI, Ausiello P, Ruggiero G, Sorrentino R. Current status on lithium disilicate and zirconia: a narrative review. *BMC Oral Health* 2019;19:134. <https://doi.org/10.1186/s12903-019-0838-x>.
16. Lee EA. Laser-assisted gingival tissue procedures in esthetic dentistry. *Pract Proced Aesthet Dent* 2006;18:suppl 2-6.
17. Prasad KD, Hegde C, Agrawal G, Shetty M. Gingival displacement in prosthodontics: A critical review of existing methods. *J Interdiscip Dentistry* 2011;1:80-6.
18. Albaker AM. Gingival retraction-techniques and materials: a review. *Pak Oral Dent* 2010;30:545-51.
19. Trainor J, Keeling A, Wassell R. Extra-Coronal Restorations. Concepts and clinical application, 2nd ed. In: Wassell R, Nohl F, Steele J, Walls A. (eds). Cham: Springer; 2019. P 363-374.
20. Scott A. Use of an erbium laser in lieu of retraction cord: a modern technique. *Gen Dent* 2005;53:116-9.
21. Martin E. Lasers in dental implantology. *Dent Clin North Am* 2004;48:999-1015.
22. Bennani V, Schwass D, Chandler N. Gingival retraction techniques for implants versus teeth: current status. *J Am Dent Assoc* 2008;139:1354-63.
23. Gherlone EF, Maiorana C, Grassi RF, Ciancaglini R, Cattoni, F. The use of 980-nm diode and 1064-nm Nd:YAG lasers for gingival retraction in fixed prosthesis. *J Oral Laser Appl* 2004;4:183-90.
24. Gururaj R, Jayesh SR, Nayar S. Comparative evaluation of four factors in gingival retraction using three different gingival retraction techniques: *In vivo* study. *Indian J Public Health Res Dev* 2019;10:1190-5.
25. Gupta A, Jain N, Makhija PG. Clinical applications of 980 nm diode laser for soft tissue procedures in prosthetic restorative dentistry. *J Lasers Med Sci* 2012;3:185-8.
26. Stuffken M, Vahidi F. Preimpression troughing with the diode laser: A preliminary study. *J Prosthet Dent* 2016;115:441-6.
27. Melilli D, Mauceri R, Albanese A, Matranga D, Pizzo G. Gingival displacement using diode laser or retraction cords: A comparative clinical study. *Am J Dent* 2018;31:131-4.
28. Tao X, Yao JW, Wang HL, Huang C. Comparison of gingival troughing by laser and retraction cord. *Int J Periodontics Restorative Dent* 2018;38:527-32.