

RESEARCH ARTICLE

Early vascular modifications after endoscopic endonasal pituitary surgery: The role of OCT-angiography

Gilda Cennamo^{1*}, Domenico Solari², Daniela Montorio³, Maria Rosaria Scala², Antonietta Melenzane³, Federica Fossataro³, Teresa Somma², Fausto Tranfa³, Luigi Maria Cavallo²

1 Public Health Department, University of Naples "Federico II", Naples, Italy, **2** Division of Neurosurgery, Department of Neurosciences, Reproductive Sciences and Dentistry, University of Naples "Federico II", Naples, Italy, **3** Eye Clinic, Department of Neurosciences, Reproductive Sciences and Dentistry, University of Naples "Federico II", Naples, Italy

* xgilda@hotmail.com



Abstract

Purpose

The aim of the present study is to analyze the changes in retinal vessel density (VD), using Optical Coherence Tomography Angiography (OCT-A), in patients that received endoscopic endonasal approach for the removal of an intra-suprasellar pituitary adenoma compressing optic chiasm.

Methods

We evaluated the VD in Superficial Capillary Plexus (SCP), Deep Capillary Plexus (DCP), Radial Peripapillary Capillary (RPC) and the Foveal Avascular Zone (FAZ) area in a series of fourteen patients (7 males, 7 females, mean age 56 ± 13 years), as compared to healthy controls. We also detected the structural Spectral Domain (SD)-OCT parameters: Ganglion Cell Complex (GCC), Retinal Nerve Fiber Layer (RNFL), visual field parameters (Mean Deviation, Pattern Standard Deviation) and Best Corrected Visual Acuity (BCVA). These measurements were performed prior than surgery and 48 hours after.

Results

The patients showed a significant decrease in VD of the macular and papillary regions, a significant increase in FAZ area, a significant impairment in SD-OCT, VF parameters and BCVA respect to 14 eyes of 14 healthy controls ($p < 0.05$), at pre-op evaluation. In patients group the VD in SCP, DCP and RPC increased after surgery respect to baseline but the difference turned to be out statistically significant only in RPC ($p = 0.003$). Also the BCVA ($p = 0.040$) and the Mean Deviation at visual field ($p = 0.015$) significantly improved after surgery. While there was a reduction in structural OCT parameters but it was statistically significant only in GCC ($p = 0.039$). A positive correlation was found between the preoperative VD of

OPEN ACCESS

Citation: Cennamo G, Solari D, Montorio D, Scala MR, Melenzane A, Fossataro F, et al. (2020) Early vascular modifications after endoscopic endonasal pituitary surgery: The role of OCT-angiography. PLoS ONE 15(10): e0241295. <https://doi.org/10.1371/journal.pone.0241295>

Editor: Sanjoy Bhattacharya, Bascom Palmer Eye Institute, UNITED STATES

Received: June 16, 2020

Accepted: October 12, 2020

Published: October 29, 2020

Copyright: © 2020 Cennamo et al. This is an open access article distributed under the terms of the [Creative Commons Attribution License](https://creativecommons.org/licenses/by/4.0/), which permits unrestricted use, distribution, and reproduction in any medium, provided the original author and source are credited.

Data Availability Statement: All relevant data are within the paper.

Funding: The author(s) received no specific funding for this work.

Competing interests: The authors have declared that no competing interests exist.

the RPC, Mean Deviation, BCVA and the postoperative Mean Deviation ($r = 0.426$ $p = 0.027$; $r = 0.624$ $p = 0.001$; $r = 0.515$ $p = 0.006$).

Conclusion

OCT-A allows to detect the early changes occurring within 48 hours after surgery showing that the improvement in retinal vessel density could occur before the recovery of the structural OCT parameters and can be a positive predictive factor for the functional recovery.

Introduction

Visual impairment due to optic chiasm or optic nerve compression is most commonly detected in patients harboring intra-suprasellar lesions, e.g. pituitary adenomas, Rathke cleft cysts, craniopharyngiomas, accounting for up to 10–15% of all intracranial tumors [1]. Transnasal surgery for the treatment of these conditions, allows an optical surgical resection along with remarkable vision improvements [2]. The comprehension of several anatomical and functional information, i.e. the assessment of the structural integrity of the anterior visual pathway and the evaluation of visual loss along with definition of signs are crucial [3]. Elements associated with visual outcomes following the chiasm decompression surgery have been widely investigated: visual prognosis depends on the interval of compression, nature, and size of the lesion, patients' age, visual fields, and visual acuity at the time of surgery and the presence of optic disc atrophy [4,5]. However, none of the aforementioned factors can allow the surgeon to define the specific postoperative course. On one side, visual field examination provides chiasmal status but it is not possible to quantify the impairment of lost or dysfunctional ganglion cells that can cause visual field alterations. Since the introduction of Optical Coherence Tomography (OCT), an imaging technique that utilizes near-infrared light interferometry to generate *in vivo* cross-sectional and three-dimensional volumes of retinal layers, it has been possible to reveal permanent structural anatomical changes, more precisely define the likelihood of functional recovery [6]. Recently, several optical coherence tomography angiography (OCT-A) methods have been developed especially for the reconstruction of three-dimensional noninvasive chorioretinal vascular imaging and are gaining popularity for the diagnosis of optic neuropathies [7–13].

To the best of our knowledge, only one study investigated the potential role of OCT-A in the measurement of vessel density to predict the postoperative visual recovery in chiasm compression due to pituitary tumors evaluating patients before and at 3 months after surgery [14]. The aim of our study is focused on the identification of early changes occurring in retinal vessel density (VD), using Optical Coherence Tomography Angiography (OCT-A), in patients that received Endoscopic Endonasal Approach (EEA) for the removal of an intra-suprasellar pituitary adenoma compressing the optic chiasm and to evaluate its eventual predictive factor of the functional recovery.

Materials and methods

Population and study design

In this study we enrolled 14 patients (twenty-eighty eyes), who underwent endoscopic endonasal approach (EEA) for the removal of intra-suprasellar pituitary adenoma compressing the optic chiasm, at the Division of Neurosurgery of the University of Naples "Federico II" from January to March 2019.

The inclusion criteria were: evidence of lesion compressing the chiasm at magnetic resonance imaging (MRI), the preoperative visual field (VF) impairment and absence of previous endoscopic endonasal surgery.

Exclusion criteria were: previous treatment for lesions compressing the chiasm, previous ocular surgery, congenital eye disease; high myopia (>6 diopters); diagnosis of glaucoma; any optic disc anomaly and macula disease; low-quality OCT and OCT-A images.

14 healthy subjects (8 females, 6 males, mean age 55 ± 10 years) with no optic disease were studied and served as control group for quantity analysis.

Each patients underwent pre-operative and post-operative (48 hours after) ophthalmological assessment, including: the measurement of best-corrected visual acuity (BCVA) according to the Early Treatment of Diabetic Retinopathy Study (ETDRS) [15] (the BCVA was converted into logarithm of the Minimum Angle of Resolution (log MAR) scale for statistical calculations), slit-lamp biomicroscopy, fundus examination, automatic perimetry test (Humphrey Field Analyzer using the 30–2 SITA-Standard algorithm of the Humphrey perimeter; Carl Zeiss Meditec, Dublin, CA, USA), evaluation of the structural Spectral Domain (SD)-OCT parameters (Ganglion Cell Complex and Retinal Nerve Fiber Layer) and OCT-A.

The study was approved by the Institutional Review Board of the University of Naples “Federico II” (clinical trials: NCT04425954) and all investigations adhered to the tenets of the Declaration of Helsinki. Written informed consents were obtained from the patients enrolled in the study.

OCT angiography

OCT-A images with the Optovue Angiovue System (software ReVue XR version 2017.1.0.151, Optovue Inc., Fremont, CA, USA) that is based on split-spectrum amplitude de-correlation algorithm (SSADA) which uses blood flow as intrinsic contrast [16,17].

The software (AngioAnalytic™) automatically calculated the vessel density (VD) of different retinal vascular networks in macular area over a 6 x 6 mm scan centered on the fovea and divided, according to the ETDRS classification of diabetic retinopathy, in whole image, fovea and parafovea. The retinal vascular networks analyzed were: the Superficial Capillary Plexus (SCP) and the Deep Capillary Plexus (DCP) [18].

The Angio Vue disc mode automatically segmented the Radial Peripapillary Capillary (RPC) analyzing the whole papillary region with an area scan of 4.5 x 4.5 mm. The VD was analyzed in the superficial retinal layers and extended from the ILM to the RNFL posterior boundary [19].

The vessel density (VD) was defined as the percentage area occupied by vessels in the analyzed region [20]. Angiovue software automatically calculated the Foveal Avascular Zone (FAZ) area in square millimetres over the 6 mm x 6 mm macular area in the full retinal plexus [21].

From the analysis were excluded the images with a signal strength index less than 40 and residual motion artefacts and incorrect segmentation.

Surgical technique

Surgical treatment consisted of an endoscopic endonasal “standard” approach in all the cases, according to the techniques already described in previous publications [22–27]. All the procedures were performed using a rigid 0-degree endoscope, 18 cm in length and 4 mm in diameter (Karl Storz Endoscopy, Tuttlingen, Germany), as the sole visualizing tool.

Statistical analysis

Statistical analysis was performed with the Statistical Package for Social Sciences (Version 20.0 for Windows; SPSS Inc, Chicago, Ill, USA). The unpaired Student's t-test for independent samples was used to compare SD-OCT, OCT-A, visual field parameter and BCVA between patient before the surgery and control group. Moreover these parameters were analyzed in patients at baseline and 48 hours after the surgery by the paired Student's t-test. Pearson's correlation was assessed to evaluate the correlation between preoperative SD-OCT, OCT-A, visual field (VF) parameters, BCVA and postoperative Mean Deviation (MD). A p value of < 0.05 was considered statistically significant.

Results

A total of twenty-eight eyes of fourteen patients (7 males, 7 females, mean age 56 ± 13 years) with a optic chiasm compression syndrome due to an intra and suprasellar lesion were enrolled in this study.

There were no statistically significant differences in terms of age ($p = 0.747$) and sex ($p = 0.987$) between the patients group and controls.

At SD-OCT exam, the Ganglion Cell Complex (GCC) and the Retinal Nerve Fiber Layer (RNFL) were significantly thinner in patients prior surgery respect to controls ($95.78 \pm 10.75 \mu\text{m}$ vs $102.32 \pm 5.98 \mu\text{m}$, $p = 0.021$; $95.25 \pm 8.98 \mu\text{m}$ vs $103.82 \pm 7.99 \mu\text{m}$, $p < 0.001$; respectively).

Also the VD of the SCP, DCP in all macular sectors and the VD of the RPC were significantly decreased ($p < 0.05$), while the FAZ area was significantly increased ($p < 0.001$) compared to healthy subjects.

Regarding the visual acuity and the visual field parameters, the patients showed a significant impairment in preoperative BCVA ($-0.01 \pm 0.39 \log\text{MAR}$ vs $-0.25 \pm 0.05 \log\text{MAR}$, $p = 0.002$), MD ($-5.87 \pm 7 \text{ dB}$ vs $-0.58 \pm 1.18 \text{ dB}$, $p < 0.001$) and Pattern Standard Deviation (PSD) ($5.86 \pm 4.8 \text{ dB}$ vs $2.11 \pm 0.45 \text{ dB}$, $p < 0.001$) as compared group (Table 1).

When comparing data prior and 48 hours after surgery, a statistically significant improvement in BCVA ($-0.01 \pm 0.39 \log\text{MAR}$ vs $-0.14 \pm 0.16 \log\text{MAR}$, $p = 0.040$) was observed.

The structural OCT parameters (GCC and RNFL thicknesses) were reduced after surgery respect to baseline but a statistically significant difference was found only in GCC ($95.78 \pm 10.75 \mu\text{m}$ vs $92.89 \pm 6.60 \mu\text{m}$, $p = 0.039$).

Conversely, at OCT-A examination, the VD in RPC significantly increased after surgery ($46.86 \pm 2.98\%$ vs $48.13 \pm 3.67\%$, $p = 0.003$), also the VD of the SCP and DCP in each macular sector were slightly increased after surgery, although not statistically significant (SCP whole image: $48.20 \pm 3.81\%$ vs $48.91 \pm 3.45\%$; $p = 0.348$; DCP whole image: $51.54 \pm 8\%$ vs $52.06 \pm 7\%$; $p = 0.711$). On the contrary, there were no significant alterations in FAZ area after surgery.

Finally, concerning the visual field parameters, we noticed that the MD had significantly improved ($-5.87 \pm 7 \text{ dB}$ vs $-3.19 \pm 4.7 \text{ dB}$, $p = 0.015$) while the PSD did not show any change after surgery (Table 2, Fig 1).

In patients group the preoperative VD of the RPC ($r = 0.426$, $p = 0.027$), MD ($r = 0.624$, $p = 0.001$) and BCVA ($r = 0.515$, $p = 0.006$) were significantly correlated with the postoperative MD (Table 3).

Discussion

In our study, we evaluated the preoperative and postoperative Vessel Density in Superficial Capillary Plexus (SCP), Deep Capillary Plexus (DCP), Radial Peripapillary Capillary (RPC) and SD-OCT parameters (GCC and RNFL) 48 hours after endoscopic endonasal removal of

Table 1. Differences in OCTA, SD-OCT, visual field parameters and BCVA between preoperative patients and controls.

	Patients	Controls	p value
Superficial Capillary Plexus (%)			
<i>Whole image</i>	48.20 ± 3.81	54.21 ± 3.09	<0.001
<i>Parafovea</i>	50.86 ± 6.06	53.96 ± 3.62	0.024
<i>Fovea</i>	18.44 ± 8.58	27.60 ± 4.81	<0.001
Deep Capillary Plexus (%)			
<i>Whole image</i>	51.54 ± 8	56.21 ± 4.78	0.011
<i>Parafovea</i>	56.01 ± 5.95	59.14 ± 3.43	0.019
<i>Fovea</i>	36.24 ± 10.04	44.96 ± 6.22	<0.001
Foveal Avascular Zone (mm²)	0.306 ± 0.12	0.188 ± 0.06	<0.001
Radial Peripapillary Capillary (%) <i>Whole image</i>	46.86 ± 2.98	53.21 ± 3.44	<0.001
Ganglion Cell Complex (μm)			
<i>Average</i>	95.78 ± 10.75	102.32 ± 5.98	0.021
Retinal Nerve Fiber Layer (μm)			
<i>Average</i>	95.25 ± 8.98	103.82 ± 7.99	<0.001
Mean Deviation (dB)	-5.87 ± 7	-0.58 ± 1.18	<0.001
Pattern Standar Deviation (dB)	5.86 ± 4.8	2.11 ± 0.45	<0.001
BCVA (logMAR)	-0.01 ± 0.39	-0.25 ± 0.05	0.002

Data expressed as mean ± SD; dB: decibel; BCVA: Best Corrected Visual Acuity; logMAR: logarithm of the minimum angle of resolution.

The unpaired Student's t-test, p<0.05.

<https://doi.org/10.1371/journal.pone.0241295.t001>

an intra-suprasellar pituitary adenoma compressing the optic apparatus. The depth-resolved visualization of all the retinal vascular layers has been possible by the Optic Coherence

Table 2. Differences in OCTA, SD-OCT, visual field parameters and BCVA before and after surgery via endoscopic endonasal approach.

	Before	After	p value
Superficial Capillary Plexus (%)			
<i>Whole image</i>	48.20 ± 3.81	48.91 ± 3.45	0.348
<i>Parafovea</i>	50.86 ± 6.06	51.38 ± 5.20	0.642
<i>Fovea</i>	18.44 ± 8.58	19.23 ± 8.92	0.526
Deep Capillary Plexus (%)			
<i>Whole image</i>	51.54 ± 8	52.06 ± 7	0.711
<i>Parafovea</i>	56.01 ± 5.95	56.18 ± 5.77	0.887
<i>Fovea</i>	36.24 ± 10.04	37.42 ± 10.27	0.393
Foveal Avascular Zone (mm²)	0.306 ± 0.12	0.306 ± 0.13	0.994
Radial Peripapillary Capillary (%) <i>Whole image</i>	46.86 ± 2.98	48.13 ± 3.67	0.003
Ganglion Cell Complex (μm)			
<i>Average</i>	95.78 ± 10.75	92.89 ± 6.60	0.039
Retinal Nerve Fiber Layer (μm)			
<i>Average</i>	95.25 ± 8.98	94.85 ± 10.46	0.561
Mean Deviation (dB)	-5.87 ± 7	-3.19 ± 4.7	0.015
Pattern Standar Deviation (dB)	5.86 ± 4.8	5.13 ± 4.75	0.319
BCVA (logMAR)	-0.01 ± 0.39	-0.14 ± 0.16	0.040

Data expressed as mean ± SD; dB: decibel; BCVA: Best Corrected Visual Acuity; logMAR: logarithm of the minimum angle of resolution.

The paired Student's t-test, p<0.05.

<https://doi.org/10.1371/journal.pone.0241295.t002>

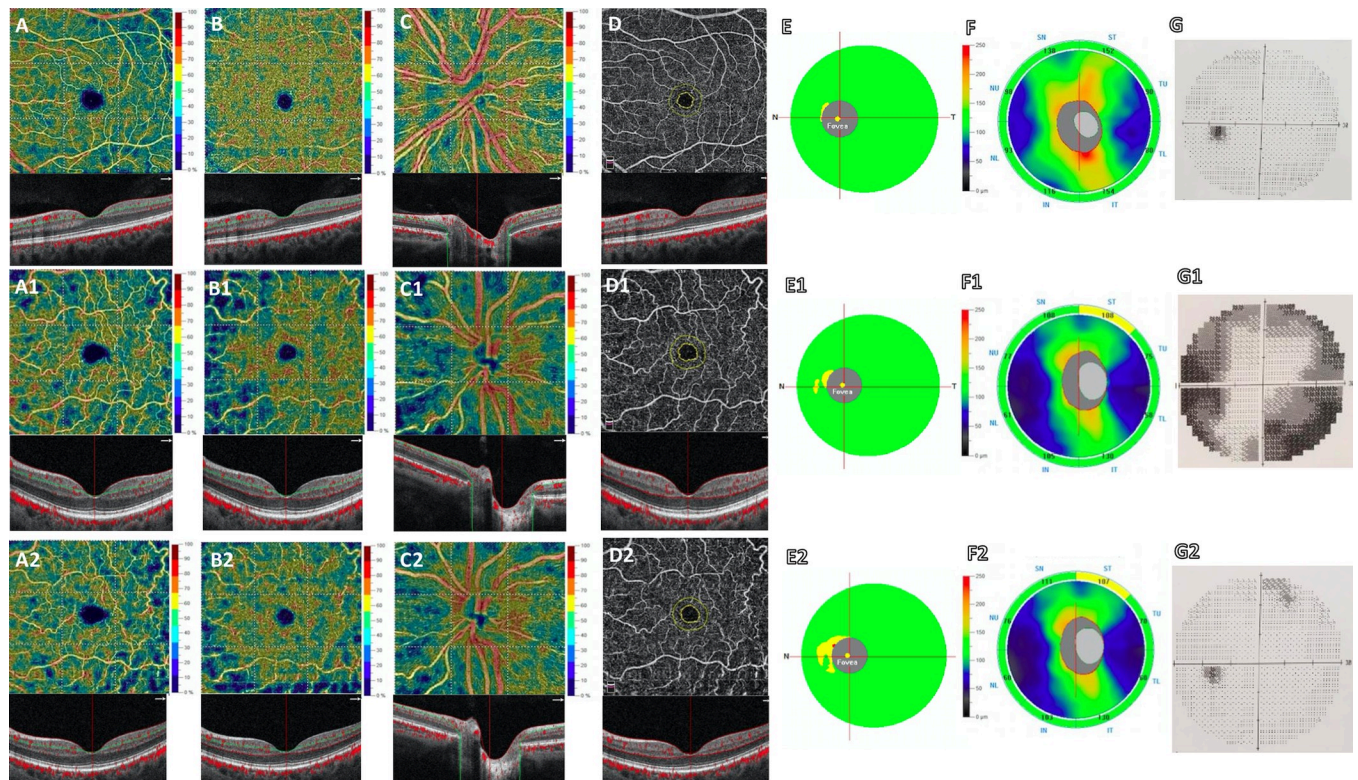


Fig 1. Left eye of an healthy subject (45 years-old female) shows at Optical Coherence Tomography Angiography (OCTA) normal vessel density of the superficial capillary plexus (SCP) (A), deep capillary plexus (DCP) (B), radial peripapillary capillary (RPC) (C) and foveal avascular zone (FAZ) area (D). Left eye of a patient (50 years-old female) with pituitary adenoma before surgery reveals a reduction of vessel density in SCP (A1), DCP (B1), RPC (C1) and an increase of FAZ area (D1) respect to healthy subject. No significant change in vessel density of the SCP (A2), DCP (B2), in FAZ area (D2) and an increased vessel density of the RPC (C2) are found in the same patient 48 hours after endoscopic endonasal surgery respect to baseline. Structural Spectral Domain OCT (SD-OCT) shows normal thickness of the Ganglion Cell Complex (GCC) (E) and Retinal Nerve Fiber Layer (RNFL) (F) in healthy control. The patient shows a focal reduction in GCC and RNFL (E1, F1) at baseline, a decrease in GCC (E2) and absence of changes in RNFL (F2) 48 hours after surgery. Respect to control (G), a significant impairment of visual field examination and a significant improvement are found at baseline (G1) and after surgery (G2), respectively.

<https://doi.org/10.1371/journal.pone.0241295.g001>

Tomography Angiography (OCT-A), which is an innovative, non-invasive, and rapid imaging modality without the necessary cooperation of the patient [28,29]. OCT-A devices reflect the anatomical modifications using different algorithms, all of which based on the hypothesis that erythrocytes are the only moving particles within the blood vessels; hence, they can be detected as natural motion contrast. Since its recent introduction, OCT-A has gained popularity and has been applied to a broad spectrum of retinal disorders and other optic nerve diseases [28,30–37].

And yet few studies evaluated the role of OCT-A for definition of chiasm compression [38].

In our study, we explored the predictive role of OCT-A in visual recovery by investigating the early vessel density modifications that may occur 48 hours after endoscopic endonasal pituitary surgery.

The deformation of the optic chiasm caused by the growth of the pituitary adenomas is responsible for the occurrence of visual disturbances and, furthermore, for their entity. Considering the above, also in accordance with optic chiasm fibers disposition, the most common Visual Field defect is bitemporal hemianopsia, implying that the nasal retinal fibers are damaged [39,40]. Moreover, their major vulnerability may be attributed to their partial decussation before forming the optic tracts [41]: a significant positive relationship between the extent of bitemporal VF loss and the degree of central chiasm elevation has been demonstrated [42].

Table 3. Correlations between preoperative SD-OCT, OCTA, visual field parameters, BCVA and postoperative MD.

	Postoperative MD	
	r	p
Superficial Capillary Plexus		
<i>Whole image</i>	0.016	0.938
<i>Parafovea</i>	-0.120	0.552
<i>Fovea</i>	0.432	0.124
Deep Capillary Plexus		
<i>Whole image</i>	-0.256	0.198
<i>Parafovea</i>	-0.214	0.285
<i>Fovea</i>	0.313	0.111
Foveal Avascular Zone	0.484	0.210
Radial Peripapillary Capillary		
<i>Whole image</i>	0.426	0.027
Ganglion Cell Complex average	0.430	0.125
Retinal Nerve Fiber Layer average	0.598	0.201
Mean Deviation	0.624	0.001
Pattern Standard Deviation	0.658	0.241
BCVA	0.515	0.006

Pearson's correlation $p < 0.05$.

<https://doi.org/10.1371/journal.pone.0241295.t003>

Prieto et al. analyzed the correlation between optic chiasm distortions as quantified at MRI and their impact on the visual outcomes: the rate of visual loss was minor in patients with normal and/or compressed downward chiasms (less than 20%) and it was major in cases where chiasms were stretched from below [43]. These conditions were directly the final postoperative visual outcomes.

When the optic chiasm is directly compressed or its blood supply system is altered by the lesion, axonal injury and dysfunction or ganglion cell apoptosis may occur [44–46]. The role of OCT in the detection of anatomical changes during chiasmal compression has been widely investigated. It translates to a diminished thickness of both retinal nerve fiber layer (RNFL) and ganglion cell complex (GCC) [47], as stated in our previous publication, where patients with better preoperative values of p-RNFL and GCC presented a higher percentage of visual recovery [48]. Garcia et al. enrolled 34 patients with evidence of chiasmal compression and assessed the nasal RNFL thickness was an optimal prognostic factor for peripheral visual field recovery [4]. It is also well known there is a consistent correlation between the degree of visual function recovery and the degree of initial damage to retinal ganglion cell axons [44,45].

Different hypotheses have been postulated to relate the visual outcomes and timing of decompression through surgery. At first, the compression causes a physiological conduction block resulting in an impairment of anterograde and retrograde axoplasmic flow, creating a mainly reversible condition where an initial nerve suffering is established; if this condition persists, irreversible axonal damage will progress, as well as a visual dysfunction, leading to demyelination and advanced loss of ganglion cells. It may be associated with decreased retinal needs and may lead to capillary loss and that could be shown using optical coherence tomography angiography (OCT-A) [49].

Moon et al. studied the changes that occur after optic chiasmal decompression in terms of OCT parameters and visual field assessment and noticed that visual field recovery precedes the demonstrable retinal regeneration, albeit the established correlation between the anatomical

and functional modifications [50]. It was thought the surgical timing may also play a role in terms of visual improvement.

Hence, we took into consideration the time elapsed between visual disturbances onset and surgical timing to assess any correlation with the visual recovery with regard to postoperative BVCA, VD, and Angio-OCT RPC value.

Accordingly, we first divided the patients into 3 groups; the first group received the surgical treatment within 30 days, the second one in a period between 45–60 days and, the third group in a period longer than 90 days. We initially compared their visual outcomes in order to identify a correlation and then, we calculated the presence of any difference among the groups between the preoperative and postoperative BVCA, VD and Angio-OCT RPC value assuming that those who received the surgical treatment before could score better visual improvements. Nonetheless, both correlations turned out to be not statistically significant. However, it cannot be underestimated that this can be related to the limited number of cases.

In agreement with previous studies, our preoperative values of VD of the SCP, DCP in all macular sectors, and the VD of the RPC were significantly decreased, along with RNFL and GCC, compared to the healthy subjects [14,49].

Up to date, only one study evaluated the potential role of OCT-A in the measurement of vessel density to predict the postoperative visual recovery in chiasm compression due to pituitary tumors. Lee et al. evaluated both OCT and OCT-A parameters of patients before and at a 3 months follow-up period after surgery. They did not find any statistical correlation between preoperative RNFL and GCC thickness and postoperative VF recovery, because of the great number presence of patients with mild VF but fewer structural anatomical changes, whereas they demonstrate a strong association between the average VD and the postoperative VF outcomes [14].

In the present study, we presumed that the early modification in VD at the OCT-A examination may precede the OCT parameters normalization and, consequentially, provide new instruments to predict the visual outcome of our patients. We assumed that during chiasmal compression there is initially a mechanical lower retinal perfusion along with reduced metabolic demand due to the optic injury, made by the lesion and we alleged that the early examination of the eventual normalization of VD could provide a prognostic factor on visual outcomes compared to the current ones such as RNFL or GCC.

Our findings demonstrate that VD of the SCP, DCP in each macular sector and RPC was increased after surgery even if the difference turned out to be statistically significant only in RPC ($46.86 \pm 2.98\%$ vs $48.13 \pm 3.67\%$, $p = 0.003$), notwithstanding the structural OCT parameters (GCC and RNFL thicknesses) were found ameliorated after surgery respect to baseline. Moreover, in patients group the postoperative MD was significantly correlated with VD of the RPC ($r = 0.426$, $p = 0.027$), MD ($r = 0.624$, $p = 0.001$) and BCVA which has shown better scores for all the patients ($r = 0.515$, $p = 0.006$) (Table 3).

According to our results, it might be said that the normalization of this OCT-A parameter after the chiasm decompression is strictly related to the peculiar RPC vessels anatomical location [51–54]. Michaelson has originally described them as a unique plexus of capillary bed with a limited distribution in the posterior pole and with a parallel orientation to the retinal nerve fiber layer axons [55]. Being the most superficial layer of capillaries lying in the inner part of the RNFL they might return to their original status thanks to the mechanical decompression effect achieved with the surgery [56–58]. Moreover, according to Yu et al., there is an established correlation between RPC distribution and RNFL thickness and their function is most likely to nourish its inner portion, as it is also postulated in other several publications regarding the physiopathology relative to ophthalmologic disease [51,52,59–61]. In agreement with previous observations, the RPC are the most prominent in the arcuate RNFL regions, and

the positive correlation between RNFL thickness and RPC volume indicates a necessary supportive role of the RPCs in the RNFL [58].

Therefore, our data suggest that an early regularization of the RPC parameter alone may be considered as a sign of an optimal decompression achieved; this software can represent a non-invasive, rapid, and valid examination providing an accurate perspective of the functional and anatomical optic apparatus. At the same time, it can give information to both the neurosurgeon and the ophthalmologist in regards to the restitutio in integrum of the blood flow in the RNFL nourished by the RPC vessels, and provide a good prediction of visual recovery.

Conclusions

Endoscopic endonasal surgery represents a sound and effective strategy for pituitary tumors removal. This technique allows a significant visual improvement in the majority of cases presenting with chiasm compression. OCT-A is a non-invasive innovative tool that allows an easy and fast vascular and anatomical retinal examination; consequentially, thus being a valid tool to estimate functional recovery. Although several factors should be taken into consideration, we retain that the early postoperative detection of the RPC parameter can be claimed as a reliable predicting factor of visual recovery in those patients presenting chiasm compression at onset. More extensive series and further efforts are required to define better the diagnostic and prognostic role of OCT-A along with its correlation with functional assays.

Author Contributions

Conceptualization: Gilda Cennamo, Domenico Solari.

Data curation: Federica Fossataro.

Formal analysis: Daniela Montorio.

Investigation: Antonietta Melenzane, Federica Fossataro, Teresa Somma.

Methodology: Daniela Montorio.

Project administration: Gilda Cennamo, Domenico Solari.

Supervision: Fausto Tranfa, Luigi Maria Cavallo.

Validation: Fausto Tranfa, Luigi Maria Cavallo.

Writing – original draft: Gilda Cennamo, Domenico Solari, Daniela Montorio, Maria Rosaria Scala.

Writing – review & editing: Domenico Solari, Daniela Montorio.

References

1. Lake MG, Krook LS, Cruz SV. Pituitary adenomas: an overview. *Am Fam Physician*. 2013; 88: 319–327. PMID: [24010395](https://pubmed.ncbi.nlm.nih.gov/24010395/)
2. Yu SY, Du Q, Yao SY, Zhang KN, Wang J, Zhu Z, et al. Outcomes of endoscopic and microscopic transphenoidal surgery on non-functioning pituitary adenomas: a systematic review and meta-analysis. *J Cell Mol Med*. 2018; 22: 2023–2027. <https://doi.org/10.1111/jcmm.13445> PMID: [29314715](https://pubmed.ncbi.nlm.nih.gov/29314715/)
3. Savino PJ. Evaluation of the retinal nerve fiber layer: descriptive or predictive? *J Neuroophthalmol*. 2009; 29: 245–249. <https://doi.org/10.1097/WNO.0b013e3181b1b3d7> PMID: [19726949](https://pubmed.ncbi.nlm.nih.gov/19726949/)
4. Lee S, Kim SJ, Yu YS, Kim Yh, Paek SH, Kim DG, et al. Prognostic factors for visual recovery after transsphenoidal pituitary adenectomy. *Br J Neurosurg*. 2013; 27: 425–429. <https://doi.org/10.3109/02688697.2013.767316> PMID: [23421587](https://pubmed.ncbi.nlm.nih.gov/23421587/)

5. Al-Louzi O, Prasad S, Mallery RM. Utility of optical coherence tomography in the evaluation of sellar and parasellar mass lesions. *Curr Opin Endocrinol Diabetes Obes*. 2018; 25: 274–284. <https://doi.org/10.1097/MED.0000000000000415> PMID: 29771751
6. Danesh-Meyer HV, Wong A, Papchenko T, Matheos K, Stylli A, Nichols A, Frampton C, Daniell M, Savino PJ, Kaye AH. Optical coherence tomography predicts visual outcome for pituitary tumors. *J Clin Neurosci*. 2015; 22: 1098–1104. <https://doi.org/10.1016/j.jocn.2015.02.001> PMID: 25891894
7. Huang Y, Zhang Q, Thorell MR, An L, Durbin MK, Laron M, et al. Swept-source OCT angiography of the retinal vasculature using intensity differentiation-based optical microangiography algorithms. *Ophthalmic Surg Lasers Imaging Retina*. 2014; 45: 382–389. <https://doi.org/10.3928/23258160-20140909-08> PMID: 25230403
8. Schwartz DM, Fingler J, Kim DY, Zawadzki RJ, Morse LS, Park SS, et al. Phase-variance optical coherence tomography: a technique for noninvasive angiography. *Ophthalmology*. 2014; 121: 180–187. <https://doi.org/10.1016/j.ophtha.2013.09.002> PMID: 24156929
9. Jia Y, Bailey ST, Hwang TS, McClintic SM, Gao SS, Pennesi ME, et al. Quantitative optical coherence tomography angiography of vascular abnormalities in the living human eye. *Proc Natl Acad Sci U S A*. 2015; 112: E2395–2402. <https://doi.org/10.1073/pnas.1500185112> PMID: 25897021
10. Miura M, Hong YJ, Yasuno Y, Muramatsu D, Iwasaki T, Goto H. Three-dimensional vascular imaging of proliferative diabetic retinopathy by Doppler optical coherence tomography. *Am J Ophthalmol*. 2015; 159: 528–538.e523. <https://doi.org/10.1016/j.ajo.2014.12.002> PMID: 25498353
11. Ishibazawa A, Nagaoka T, Takahashi A, Omae T, Tani T, et al. Optical Coherence Tomography Angiography in Diabetic Retinopathy: A Prospective Pilot Study. *Am J Ophthalmol*. 2015; 160: 35–44.e31. <https://doi.org/10.1016/j.ajo.2015.04.021> PMID: 25896459
12. de Carlo TE, Salz DA, Waheed NK, Baurnal CR, Duker JS, Witkin AJ. Visualization of the Retinal Vasculature Using Wide-Field Montage Optical Coherence Tomography Angiography. *Ophthalmic Surg Lasers Imaging Retina*. 2015; 46: 611–616. <https://doi.org/10.3928/23258160-20150610-03> PMID: 26172062
13. Tan PE, Balaratnasingam C, Xu J, Mammo Z, Han SX, Mackenzie P, et al. Quantitative Comparison of Retinal Capillary Images Derived By Speckle Variance Optical Coherence Tomography With Histology. *Invest Ophthalmol Vis Sci*. 2015; 56: 3989–3996. <https://doi.org/10.1167/iovs.14-15879> PMID: 26098464
14. Lee GI, Park KA, Oh SY, Kong DS. Parafoveal and Peripapillary Perfusion Predict Visual Field Recovery in Chiasmal Compression due to Pituitary Tumors. *J Clin Med*. 2020; 9. <https://doi.org/10.3390/jcm9030697> PMID: 32143464
15. Kniestedt C, Stamper RL. Visual acuity and its measurement. *Ophthalmol Clin North Am*. 2003; 16: 155–170. [https://doi.org/10.1016/s0896-1549\(03\)00013-0](https://doi.org/10.1016/s0896-1549(03)00013-0) PMID: 12809155
16. Jia Y, Tan O, Tokayer J, Potsaid B, Wang Y, Liu JJ, et al. Split-spectrum amplitude-decorrelation angiography with optical coherence tomography. *Opt Express*. 2012; 20: 4710–4725. <https://doi.org/10.1364/OE.20.004710> PMID: 22418228
17. Scoles D, Gray DC, Hunter JJ, Wolfe R, Gee BP, Geng Y, et al. In-vivo imaging of retinal nerve fiber layer vasculature: imaging histology comparison. *BMC Ophthalmol*. 2009; 9: 9. <https://doi.org/10.1186/1471-2415-9-9> PMID: 19698151
18. Cennamo G, Montorio D, Mirra F, Comune C, D'Alessandro A, Tranfa F. Study of vessel density in adult-onset foveomacular vitelliform dystrophy with Optical Coherence Tomography Angiography. *Photodiagnosis Photodyn Ther*. 2020: 101702. <https://doi.org/10.1016/j.pdpdt.2020.101702> PMID: 32126304
19. Rao HL, Pradhan ZS, Weinreb RN, Reddy HB, Riyazuddin M, Dasari S, et al. Regional Comparisons of Optical Coherence Tomography Angiography Vessel Density in Primary Open-Angle Glaucoma. *Am J Ophthalmol*. 2016; 171: 75–83. <https://doi.org/10.1016/j.ajo.2016.08.030> PMID: 27590118
20. Huang D, Jia Y, Gao SS, Lumbroso B, Rispoli M. Optical Coherence Tomography Angiography Using the Optovue Device. *Dev Ophthalmol*. 2016; 56: 6–12. <https://doi.org/10.1159/000442770> PMID: 27022989
21. Moein HR, Novais EA, Rebhun CB, Cole Ed, Louzada RN, Witkin AJ, et al. Optical coherence tomography angiography to detect macular capillary ischemia in patients with inner retinal changes after resolved diabetic macular edema. *Retina*. 2018; 38: 2277–2284. <https://doi.org/10.1097/IAE.0000000000001902> PMID: 29068912
22. Cavallo LM, Somma T, Solari D, Iannuzzo G, Frio F, Baiano C, et al. Endoscopic Endonasal Transsphenoidal Surgery: History and Evolution. *World Neurosurg*. 2019; 127: 686–694. <https://doi.org/10.1016/j.wneu.2019.03.048> PMID: 31266131

23. Cavallo LM, Solari D, Somma T, Cappabianca P. The 3F (Fat, Flap, and Flash) Technique For Skull Base Reconstruction After Endoscopic Endonasal Suprasellar Approach. *World Neurosurg.* 2019; 126: 439–446. <https://doi.org/10.1016/j.wneu.2019.03.125> PMID: 30904811
24. Cappabianca P, Cavallo LM, Solari D, Stagno V, Esposito F, de Angelis M. Endoscopic endonasal surgery for pituitary adenomas. *World Neurosurg.* 2014; 82: S3–11. <https://doi.org/10.1016/j.wneu.2014.07.019> PMID: 25496632
25. Cappabianca P, Cavallo LM, Solari D, Esposito F. Endoscopic endonasal transsphenoidal approach to pituitary adenomas. *J Neurosurg.* 2015; 122: 473–474. <https://doi.org/10.3171/2014.8.JNS141716> PMID: 25495741
26. Solari D, Cavallo LM, Cappabianca P. Surgical approach to pituitary tumors. *Handb Clin Neurol.* 2014; 124: 291–301. <https://doi.org/10.1016/B978-0-444-59602-4.00019-8> PMID: 25248594
27. de Notaris M, Solari D, Cavallo LM, Iodice D'Enza A, Enseñat J, Berenguer J, et al. The "suprasellar notch," or the tuberculum sellae as seen from below: definition, features, and clinical implications from an endoscopic endonasal perspective. *J Neurosurg.* 2012; 116: 622–629. <https://doi.org/10.3171/2011.11.JNS111162> PMID: 22196097
28. Rabiolo A, Gelormini F, Sacconi R, Cicinelli MV, Triolo G, Bettin P, et al. Comparison of methods to quantify macular and peripapillary vessel density in optical coherence tomography angiography. *PLoS One.* 2018; 13: e0205773. <https://doi.org/10.1371/journal.pone.0205773> PMID: 30335815
29. Spaide RF, Klancnik JM, Cooney MJ. Retinal vascular layers imaged by fluorescein angiography and optical coherence tomography angiography. *JAMA Ophthalmol.* 2015; 133: 45–50. <https://doi.org/10.1001/jamaophthalmol.2014.3616> PMID: 25317632
30. Durbin MK, An L, Shemonski ND, Soares M, Santos T, Lopes M, et al. Quantification of Retinal Microvascular Density in Optical Coherence Tomographic Angiography Images in Diabetic Retinopathy. *JAMA Ophthalmol.* 2017; 135: 370–376. <https://doi.org/10.1001/jamaophthalmol.2017.0080> PMID: 28301651
31. Samara WA, Shahlaea A, Adam MK, Khan MA, Chiang A, Maguire JI, et al. Quantification of Diabetic Macular Ischemia Using Optical Coherence Tomography Angiography and Its Relationship with Visual Acuity. *Ophthalmology.* 2017; 124: 235–244. <https://doi.org/10.1016/j.ophtha.2016.10.008> PMID: 27887743
32. Samara WA, Shahlaea A, Sridhar J, Khan MA, Ho AC, Hsu J. Quantitative Optical Coherence Tomography Angiography Features and Visual Function in Eyes With Branch Retinal Vein Occlusion. *Am J Ophthalmol.* 2016; 166: 76–83. <https://doi.org/10.1016/j.ajo.2016.03.033> PMID: 27038893
33. Cicinelli MV, Rabiolo A, Sacconi R, Lamanna F, Querques L, Bandello F, et al. Retinal vascular alterations in reticular pseudodrusen with and without outer retinal atrophy assessed by optical coherence tomography angiography. *Br J Ophthalmol.* 2018; 102(9): 1192–1198. <https://doi.org/10.1136/bjophthalmol-2017-311317> PMID: 29363531
34. Battaglia Parodi M, Cicinelli MV, Rabiolo A, Pierro L, Bolognesi G, Bandello F. Vascular abnormalities in patients with Stargardt disease assessed with optical coherence tomography angiography. *Br J Ophthalmol.* 2017; 101: 780–785. <https://doi.org/10.1136/bjophthalmol-2016-308869> PMID: 27628426
35. Battaglia Parodi M, Cicinelli MV, Rabiolo A, Pierro L, Gagliardi M, et al. Vessel density analysis in patients with retinitis pigmentosa by means of optical coherence tomography angiography. *Br J Ophthalmol.* 2017; 101: 428–432. <https://doi.org/10.1136/bjophthalmol-2016-308925> PMID: 27343210
36. Battaglia Parodi M, Rabiolo A, Cicinelli MV, Iacono P, Romano F, Bandello F. Quantitative analysis of optical coherence tomography angiography in adult-onset foveomacular vitelliform dystrophy. *Retina.* 2018; 38: 237–244. <https://doi.org/10.1097/IAE.0000000000001539> PMID: 28145974
37. Battaglia Parodi M, Romano F, Cicinelli MV, Rabiolo A, Arrigo A, Pierro L, et al. Retinal Vascular Impairment in Best Vitelliform Macular Dystrophy Assessed by Means of Optical Coherence Tomography Angiography. *Am J Ophthalmol.* 2018; 187: 61–70. <https://doi.org/10.1016/j.ajo.2017.12.013> PMID: 29288639
38. Higashiyama T, Ichiyama Y, Muraki S, Nishida Y, Ohji M. Optical Coherence Tomography Angiography of Retinal Perfusion in Chiasmal Compression. *Ophthalmic Surg Lasers Imaging Retina.* 2016; 47: 724–729. <https://doi.org/10.3928/23258160-20160808-05> PMID: 27548449
39. Mejico LJ, Miller NR, Dong LM. Clinical features associated with lesions other than pituitary adenoma in patients with an optic chiasmal syndrome. *Am J Ophthalmol.* 2004; 137: 908–913. <https://doi.org/10.1016/j.ajo.2003.12.038> PMID: 15126157
40. Ogra S, Nichols AD, Stylli S, Kaye AH, Savino PJ, Danesh-Meyer HV. Visual acuity and pattern of visual field loss at presentation in pituitary adenoma. *J Clin Neurosci.* 2014; 21(5): 735–740. <https://doi.org/10.1016/j.jocn.2014.01.005> PMID: 24656736

41. McIlwaine GG, Carrim ZI, Lueck CJ, Chrisp TM. A mechanical theory to account for bitemporal hemianopia from chiasmal compression. *J Neuroophthalmol*. 2005; 25: 40–43. <https://doi.org/10.1097/00041327-200503000-00011> PMID: 15756133
42. Kane EJ, Ashton DE, Mews PJ, Reid K, Neely A, Lueck CJ. Correlation of MRI Findings With Patterns of Visual Field Loss in Patients With Pituitary Tumors. *J Neuroophthalmol*. 2019; 39: 333–338. <https://doi.org/10.1097/WNO.0000000000000763> PMID: 30807381
43. Prieto R, Pascual JM, Barrios L. Optic chiasm distortions caused by craniopharyngiomas: clinical and magnetic resonance imaging correlation and influence on visual outcome. *World Neurosurg*. 2015; 83: 500–529. <https://doi.org/10.1016/j.wneu.2014.10.002> PMID: 25308925
44. Danesh-Meyer HV, Carroll SC, Foroozan R, Savino PJ, Fan J, Jiang Y, et al. Relationship between retinal nerve fiber layer and visual field sensitivity as measured by optical coherence tomography in chiasmal compression. *Invest Ophthalmol Vis Sci*. 2006; 47: 4827–4835. <https://doi.org/10.1167/iovs.06-0327> PMID: 17065494
45. Danesh-Meyer HV, Papchenko T, Savino PJ, Law A, Evans J, Gamble GD. In vivo retinal nerve fiber layer thickness measured by optical coherence tomography predicts visual recovery after surgery for parachiasmal tumors. *Invest Ophthalmol Vis Sci*. 2008; 49: 1879–1885. <https://doi.org/10.1167/iovs.07-1127> PMID: 18263812
46. Moon CH, Hwang SC, Ohn YH, Park TK. The time course of visual field recovery and changes of retinal ganglion cells after optic chiasmal decompression. *Invest Ophthalmol Vis Sci*. 2011; 52: 7966–7973. <https://doi.org/10.1167/iovs.11-7450> PMID: 21896856
47. Ohkubo S, Higashide T, Takeda H, Murotani E, Hayashi Y, Sugiyama K. Relationship between macular ganglion cell complex parameters and visual field parameters after tumor resection in chiasmal compression. *Jpn J Ophthalmol*. 2012; 56: 68–75. <https://doi.org/10.1007/s10384-011-0093-4> PMID: 21975828
48. Solari D, Cennamo G, Amoroso F, Frio F, Donna P, Iodice D'enza A, Melenzane A, et al. Predicting the early visual outcomes in sellar-suprasellar lesions compressing the chiasm: the role of SD-OCT series of 20 patients operated via endoscopic endonasal approach. *J Neurosurg Sci*. 2019. <https://doi.org/10.23736/S0390-5616.19.04687-3> PMID: 31339115
49. Dallorto L, Lavia C, Jeannerot AL, Shor N, Jublanc C, Boch AL, et al. Retinal microvasculature in pituitary adenoma patients: is optical coherence tomography angiography useful? *Acta Ophthalmol*. 2019. <https://doi.org/10.1111/aos.14322> PMID: 31808290
50. Gnanalingham KK, Bhattacharjee S, Pennington R, Ng J, Mendoza N. The time course of visual field recovery following transphenoidal surgery for pituitary adenomas: predictive factors for a good outcome. *J Neurol Neurosurg Psychiatry*. 2005; 76: 415–419. <https://doi.org/10.1136/jnnp.2004.035576> PMID: 15716538
51. Mansoori T, Sivaswamy J, Gamalapati JS, Balakrishna N. Topography and correlation of radial peripapillary capillary density network with retinal nerve fibre layer thickness. *Int Ophthalmol*. 2018; 38: 967–974. <https://doi.org/10.1007/s10792-017-0544-0> PMID: 28447287
52. Yu PK, Cringle SJ, Yu DY. Correlation between the radial peripapillary capillaries and the retinal nerve fibre layer in the normal human retina. *Exp Eye Res*. 2014; 129: 83–92. <https://doi.org/10.1016/j.exer.2014.10.020> PMID: 25447563
53. Yu PK, Balaratnasingam C, Xu J, Morgan WH, Mammo Z, Han S, et al. Label-Free Density Measurements of Radial Peripapillary Capillaries in the Human Retina. *PLoS One*. 2015; 10: e0135151. <https://doi.org/10.1371/journal.pone.0135151> PMID: 26252395
54. Mase T, Ishibazawa A, Nagaoka T, Yokota H, Yoshida A. Radial Peripapillary Capillary Network Visualized Using Wide-Field Montage Optical Coherence Tomography Angiography. *Invest Ophthalmol Vis Sci*. 2016; 57: OCT504–510. <https://doi.org/10.1167/iovs.15-18877> PMID: 27454659
55. M I. *Retinal Circulation in Man and Animals*.: Springfield, IL: Charles C Thomas; 1954.
56. Henkind P. Radial peripapillary capillaries of the retina. I. Anatomy: human and comparative. *Br J Ophthalmol*. 1967; 51: 115–123. <https://doi.org/10.1136/bjo.51.2.115> PMID: 4959937
57. Henkind P, Bellhorn RW, Poll D. Radial peripapillary capillaries. 3. Their development in the cat. *Br J Ophthalmol*. 1973; 57: 595–599. <https://doi.org/10.1136/bjo.57.8.595> PMID: 4743924
58. Mansoori T, Sivaswamy J, Gamalapati JS, Agraharam SG, Balakrishna N. Measurement of Radial Peripapillary Capillary Density in the Normal Human Retina Using Optical Coherence Tomography Angiography. *J Glaucoma*. 2017; 26: 241–246. <https://doi.org/10.1097/JG.0000000000000594> PMID: 27906811
59. Zhang L, Xu L, Zhang JS, Zhang YQ, Yang H, Jonas JB. Cotton-wool spot and optical coherence tomography of a retinal nerve fiber layer defect. *Arch Ophthalmol*. 2012; 130: 913. <https://doi.org/10.1001/archophthalmol.2011.1567> PMID: 22776929

60. Kornzweig AL, Eliasoph I, Feldstein M. Selective atrophy of the radial peripapillary capillaries in chronic glaucoma. *Arch Ophthalmol*. 1968; 80: 696–702. <https://doi.org/10.1001/archopht.1968.00980050698002> PMID: [4177355](https://pubmed.ncbi.nlm.nih.gov/4177355/)
61. Zabel P, Kaluzny JJ, Wilkosc-Debczynska M, Gebaska-Toloczek M, Suwala K, Zabel K, et al. Comparison of Retinal Microvasculature in Patients With Alzheimer's Disease and Primary Open-Angle Glaucoma by Optical Coherence Tomography Angiography. *Invest Ophthalmol Vis Sci*. 2019; 60: 3447–3455. <https://doi.org/10.1167/iovs.19-27028> PMID: [31408108](https://pubmed.ncbi.nlm.nih.gov/31408108/)