


# Portal venous gas after a failed endoscopic retrograde cholangiopancreatography attempt in a patient with a large hepatocellular carcinoma: A case report

Gianluca Cassese<sup>1</sup>  | Francesco Maione<sup>1</sup> | Mariantonietta Alagia<sup>1</sup> | Luisa Ambrosio<sup>1</sup> | Emanuele Caruso<sup>1</sup> | Alessia Chini<sup>1</sup> | Claudio Cimmino<sup>1</sup> | Riccardo Aurelio Nasto<sup>1</sup> | Francesca Pegoraro<sup>1</sup> | Mariano Cesare Giglio<sup>1</sup> | Giovanni Domenico De Palma<sup>1,2</sup>

<sup>1</sup>Department of Clinical Medicine and Surgery, University of Naples "Federico II", Napoli, Italy

<sup>2</sup>Center of Excellence for Technical Innovation in Surgery of Naples, "CEITC Unina", Napoli, Italy

## Correspondence

Gianluca Cassese, Department of Clinical Medicine and Surgery, University of Naples "Federico II", Via S. Pansini, 5, Napoli, Italy.

Email: gianluca.cassese91@gmail.com

## Abstract

The cause of hepatic portal vein gas (HPVG) is variable. Good knowledge of the possible causes, combined with the clinical assessment of the patient and a good quality imaging, is required to correctly identify the underlying cause of HPVG and to best predict the prognosis.

## KEYWORDS

endoscopy, ERCP, hepatocellular carcinoma, portal vein gas

## 1 | INTRODUCTION

Portal vein gas is a rare radiologic finding, with an unclear pathogenesis. Different management strategies have been proposed, without unanimous consent. A patient with massive hepatocellular carcinoma (HCC) that compressed the biliary ducts, with poor performance status, underwent endoscopic biliary drainage attempt. The patient developed portal pneumatosis that lead to death.

Portal vein gas or hepatic portal vein gas (HPVG) is a rare radiologic finding, with only <200 cases reported in the literature by 2001.<sup>1</sup> It was first described in 1955 by Wolfe and Evans in pediatric patients with necrotizing enterocolitis.<sup>2</sup> First reports showed a high mortality rate, with very rare case of patients that survived to such an event, suggesting a risk of imminent death in HPVG patients.<sup>3</sup> More recent imaging modalities such as Doppler imaging and computed tomography (CT) showed higher sensitivity,<sup>4</sup> allowing to detect HPVG

as an incidental finding in many benign diseases.<sup>5</sup> Different causes and conditions have been described to be associated HPVG in adults<sup>6-10</sup> (Table 1), with intestinal ischemia that seem to be the most common (75%) and the worst one in term of prognosis.<sup>11</sup> The underlying clinical events associated with HPVG seem to play the key role for patients' survival and prognosis that could be mainly related to the pathology itself and not to the presence of HPVG.<sup>12</sup>

The pathogenesis of HPVG is not well known. Different factors have been proposed: translocation of gas produced by gas-forming bacteria in bowel lumen or in an abscess which then somehow circulate into the liver, as well as the presence of mucosal lesions that allow a passage of gas-forming bacteria into the blood vessels, or a mechanical effect of a gaseous distension of the viscera that somehow overcomes an already weak wall due to underlying pathologies.<sup>5</sup>

A management algorithm has been proposed by Nelson et al,<sup>13</sup> with the so-called "ABC strategy". Urgent laparotomy

This is an open access article under the terms of the Creative Commons Attribution-NonCommercial-NoDerivs License, which permits use and distribution in any medium, provided the original work is properly cited, the use is non-commercial and no modifications or adaptations are made.

© 2021 The Authors. *Clinical Case Reports* published by John Wiley & Sons Ltd.

**TABLE 1** Pathologic conditions associated with Portal Vein Gas

Intestinal ischemia
Biliary infections
Gastric ulcer
Gastric dilatation
Duodenal perforation
Transgastric ultrasound-guided biopsy
Inflammatory bowel disease
Intra-abdominal abscess
Retroperitoneal abscess

(“Aggressive management”) is recommended for patients with signs of bowel necrosis or ischemia at CT scan, with a mortality approximated at 75%. Careful monitoring should be carried out in patients with a more nuanced clinical condition, leaving a threshold for surgical correction under appropriate conditions (“Be careful”). The risk for mortality in these cases is estimated between 20% and 30%. Finally, patients who present HPVG in nonurgent conditions or post-operatively should be treated conservatively (“Conservative management”), by acting a close observation.<sup>14</sup>

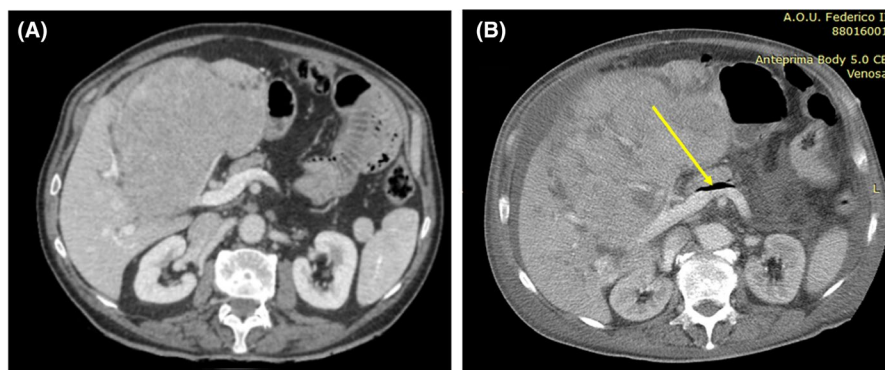
Portal venous gas after endoscopic retrograde cholangiopancreatography (ERCP) is a rare complication, described in one of 6-8 per 1000 procedures.<sup>15,16</sup> It can occur because of a vascular laceration during precut sphincterotomy or because of a porto-biliary fistula, maybe associated with tumor infiltration or inflammatory-related conditions.<sup>17,18</sup>

To our knowledge, we report the first case of portal vein gas after a simple ERCP failed attempt, without large sphincterotomy or cannulation. Literature reports showed a low morbidity and mortality after ERCP, compared to other causes. The case reported below has had a very rapid course toward the death of the patient.

## 2 | PRESENTATION OF CASE

A 70-year-old male patient was referred to the gastrointestinal surgery department by his general practitioner with an

history of progressive jaundice with itching, inappetence, weight loss, and asthenia. He was known to have a previous HCV infection eradicated for about six years, venous varices of the lower limbs. He had no current therapy. The clinical examination showed significant jaundice, palpable abdominal mass in right hypochondria, no abdominal tenderness, and some scratch injuries. Performance status of the patient was ECOG 3. A contrast-enhanced CT scan of the abdomen showed a central liver mass of about 131 millimeters, with arterial wash-in and portal wash-out features, typical for HCC. The neoplastic lesion constricted the biliary confluence, with a dilation of the intrahepatic biliary tract. Furthermore, there were no distant metastases, but some local and distant para-centimetric lymph nodes were reported. The case was discussed in a multidisciplinary oncology meeting, with an indication to perform systemic therapy after drainage of the biliary tract, to palliate jaundice. The patient was hospitalized to undergo to endoscopic biliary drainage. Preoperative blood tests showed bilirubinemia up to 279  $\mu\text{mol/L}$ , CRP at 30 mg/L, normal blood cell count, normal INR, and albuminemia at 29 g/L. The endoscopic procedure was carried out under general anesthesia, but without success. The endoscopist found a marked ab extrinsic compression of the gastric cavity with associated distortion of the piloro-duodenal axis. The orifice of the papilla of Vater was dislocated. A small precut of only 5 mm was carried out, but the numerous attempts to advance the guide-wire were unsuccessful. It was then decided to proceed with a percutaneous biliary drainage CT-guided. However, the patient's clinical conditions showed a rapid worsening, with a deterioration of the respiratory function, an increase in inflammation blood tests and a mild fever the night after the procedure. An urgent contrast-enhanced thoraco-abdominal CT scan was carried out. It showed no signs of pulmonary embolism, but a slight bilateral pleural effusion. On the other hand, it revealed portal, splenic, and gastro-epiploic vessels pneumatosis (Figure 1). There was no associated intestinal ischemia or intestinal pneumatosis. A support therapy was set up with a careful and close monitoring of the patient.



**FIGURE 1** Preoperative (A) and postoperative (B) abdominal contrast-enhanced CT scan. Yellow arrow showing presence of gas in portal vein

After an active debate among surgeons and anesthesiologists, it was decided to not proceed with surgical therapy because of the clinical conditions of the patients together with the absence of intestinal pneumatosis and intestinal ischemia. Subsequent blood tests showed leukocytosis at  $18 \times 10^3$ , increased blood creatinine level at 220  $\mu\text{mol/L}$ , increased PCR at 130 mg/L, reduced albuminemia at 25 g/L, increased AST levels at 500 U/L, and increased LDH and blood lactic acid levels. It was then set an antibiotic therapy and a support of a subintensive type. Despite a further intensive care, the patient developed a multi-organ failure that led to death in a few days.

### 3 | DISCUSSION

Clinical case here reported seems to fall into one of the scenarios leading to HPVG: bowel distention/obstruction, ischemia, and idiopathic.<sup>19</sup> In particular, we can speculate about the mechanical pathogenesis related to gas insufflation during the endoscopic procedure. Mechanical disruption of mucosal integrity may result in dissection of gas into the intestinal wall and eventually the portal system. The loss of mucosal integrity has been described also to be related to gastrointestinal neoplasms.<sup>20</sup> The translocation of the intestinal wall by gas-forming bacteria may also have concurred, resulting in the production of gas within the portal system itself.

Several therapeutic algorithms have been proposed over the years, leaving open the discussion on whether or not to perform urgent surgery. Various studies highlighted the importance of the clinical status of the patient, rather than the CT finding alone, including physical examination findings, vital signs, and laboratory values.<sup>19,21</sup> Very interesting was the paper by Koami et al that in a retrospective court of 33 patients with HPVG, using a criteria of lower blood pressure (systolic BP <108 mm Hg), high lactate dehydrogenase circulating levels (LDH >387 U/L), and the presence of pneumatosis intestinalis led to 100% sensitivity and 78.9% specificity for necrotic bowel.<sup>22</sup> A very detailed algorithm was suggested by Wayne et al by analyzing a retrospective series of 88 patients. The algorithm incorporates many clinical findings, including abdominal examination, lactate (>3 mg/dL), and radiologic findings of pneumatosis intestinalis, significant past medical history suggestive of vascular risk.<sup>23</sup> In a larger retrospective study, Hani et al<sup>24</sup> pooled data from four tertiary centers and evaluated 209 patient who had HPVG focusing on factors associated with the need for operative intervention. They found that older age, peritoneal signs, and elevated BUN are most likely associated with intestinal ischemia and need for urgent

surgery. A very recent case report by Dibra et al<sup>25</sup> also tried to suggest a set of interesting decision-making criteria in patients with portal vein gas, although with associated intestinal pneumatosis. The authors focused on the presence of clinical signs (age >60 years, hemodynamic instability, peritonitis, adynamic ileus) and laboratory/radiologic signs (elevated White Blood Cells, lactate  $\geq 2$  mmol/L, elevated INR, hepatic portal venous gas, small bowel location), according with the indications for intestinal pneumatosis of the American Association for the Surgery of Trauma.<sup>26</sup> The presence of so many papers on the same subject testifies the absence of a single therapeutic conduct universally accepted.

The case we reported is a perfect example of a patient in which it is difficult to choose the right conduct. CT scan showed no intestinal pneumatosis and signs of intestinal ischemia, but at the same time there was an increase in inflammatory indices at blood tests and a worsening of renal function. This case is a perfect example of the importance of underlying clinical conditions in determining the prognosis. The complicated postoperative course, along with the clinical conditions and the finding of HPVG at imaging without pneumatosis intestinalis, lead to an active debate among surgeons, anesthesiologists, and gastroenterologists regarding patient's management, as well as the high risk of surgery.

Nonetheless, the clinical findings and outcomes of this case illustrate the inability to predict the outcomes based only on the presence of HPVG on CT imaging, suggesting that an aggressive approach may be appropriate when the prognosis appears adverse. The underlying advanced cancer disease, along with poor performance status, inexorably leads the patient to death.

Based on the presented case, we think that the patient's performance status and underlying pathology should be considered as important additional criteria in the decision-making process of the patient with HPVG.

### 4 | CONCLUSIONS

The cause of HPVG without pneumatosis intestinalis is variable. Good knowledge of the possible causes combined with a good clinical assessment and an abdominal computed tomographic scan is required to correctly identify the underlying cause of HPVG and to decide whether urgent surgery must be performed.

Our patient presented a case of fatal HPVG, after an ERCP attempt without cannulation, fistulas, or perforations. We are convinced that each individual patient must be carefully discussed for risks and benefits of all possible procedures.

The outcome is strongly linked to the patient's underlying condition.

## ACKNOWLEDGMENTS

Nothing to declare.

## CONFLICT OF INTEREST

None declared.

## AUTHOR CONTRIBUTION

Giglio MC and De Palma GD: were responsible for study conception and design. Cassese G and Alagia M: made the drafting of manuscript. Nasto RA, Pegoraro F, Ambrosio L, and Cimmino C: participated to the acquisition of data. Maione F and Chini A: helped with the critical revision of the manuscript.

## ETHICAL STATEMENT

Written informed consent was obtained from the patient for the use of data for anonymous research and publication purposes.

## DATA AVAILABILITY STATEMENT

The data that support the findings of this study are available on request from the authors. The data are not publicly available due to privacy and ethical restrictions.

## ORCID

Gianluca Cassese  <https://orcid.org/0000-0001-9185-2054>

## REFERENCES

- Kinoshita H, Shinozaki M, Tanimura H, et al. Clinical features and management of hepatic portal venous gas: Four case reports and cumulative review of the literature. *Arch Surg*. 2001;136(12):1410. <https://doi.org/10.1001/archsurg.136.12.1410>
- Wolfe JN, Evans WA. Gas in the portal veins of the liver in infants; a roentgenographic demonstration with postmortem anatomical correlation. *Am J Roentgenol Radium Ther Nucl Med*. 1955;74(3):486–488.
- Liebman PR, Patten MT, Manny J, Benfield JR, Hechtman HB. Hepatic-portal venous gas in adults: etiology, pathophysiology and clinical significance. *Ann Surg*. 1978;187(3):281–287. <https://doi.org/10.1097/0000658-197803000-00012>
- Ben PH, Huang JS, Yang TL, Liang HL. Hepatic portal venous gas in ultrasonogram-benign or noxious. *Ultrasound Med Biol*. 2007;33(8):1179–1183. <https://doi.org/10.1016/j.ultrasmedbio.2007.01.014>
- Abboud B, El Hachem J, Yazbeck T, Doumit C. Hepatic portal venous gas: Physiopathology, etiology, prognosis and treatment. *World J Gastroenterol*. 2009;15(29):3585. <https://doi.org/10.3748/wjg.15.3585>
- Pfaffenbach B, Wegener M, Böhmeke T. Hepatic portal venous gas after transgastric EUS-guided fine-needle aspiration of an accessory spleen. *Gastrointest Endosc*. 1996;43(2):515–518. [https://doi.org/10.1016/S0016-5107\(96\)81566-5](https://doi.org/10.1016/S0016-5107(96)81566-5)
- Speer CS, Carlson DH. Portal venous air with survival in ulcerative colitis: report of a case. *Dis Colon Rectum*. 1972;15(6):453–458. <https://doi.org/10.1007/BF02642654>
- Lee C-S, Kuo Y-C, Peng S-M, et al. Sonographic detection of hepatic portal venous gas associated with suppurative cholangitis. *J Clin Ultrasound*. 1993;21(5):331–334. <https://doi.org/10.1002/jcu.1870210507>
- Radin DR, Rosen RS, Halls JM. Acute gastric dilatation: a rare cause of portal venous gas. *AJR Am J Roentgenol*. 1987;148:279–280.
- Chang SG, Lee SC, Hong DH, Chai SE. Portal and superior mesenteric venous gas with retroperitoneal abscess—CT diagnosis (case report). *J Korean Med Sci*. 1992;7(1):62. <https://doi.org/10.3346/jkms.1992.7.1.62>
- Peloponissios N. Hepatic portal gas in adults. *Arch Surg*. 2003;138(12):1367. <https://doi.org/10.1001/archsurg.138.12.1367>
- Monneuse O, Pilleul F, Barth X, et al. Portal venous gas detected on computed tomography in emergency situations: Surgery is still necessary. *World J Surg*. 2007;31(5):1066–1072. <https://doi.org/10.1007/s00268-006-0589-0>
- Nelson AL, Millington TM, Sahani D, et al. Hepatic portal venous gas: the ABCs of management. *Arch Surg*. 2009;144(6):575. <https://doi.org/10.1001/archsurg.2009.88>
- Griffiths DM, Gough MH. Gas in the hepatic portal veins. *Br J Surg*. 1986;73(3):172–176. <https://doi.org/10.1002/bjs.1800730305>
- Espinel J, Pinedo ME, Calleja JL. Portal vein filling: an unusual complication of needle-knife sphincterotomy. *Endoscopy*. 2007;39(S 1):E245. <https://doi.org/10.1055/s-2007-966156>
- Kurella R, Maple J. Portal vein cannulation: an unusual complication of ERCP. *Am J Gastroenterol*. 2010;105:S541. <https://doi.org/10.14309/0000434-201010001-01456>
- Kalaitzakis E, Stern N, Sturgess R. Portal vein cannulation: an uncommon complication of endoscopic retrograde cholangiopancreatography. *World J Gastroenterol*. 2011;17(46):5131. <https://doi.org/10.3748/wjg.v17.i46.5131>
- Kawakami H, Kuwatani M, Kudo T, Ehira N, Yamato H, Asaka M. Portobiliary fistula: Unusual complication of wire-guided cannulation during endoscopic retrograde cholangiopancreatography. *Endoscopy*. 2011;43(S 02):E98–E99. <https://doi.org/10.1055/s-0030-1256150>
- Wayne E, Ough M, Wu A, et al. Management algorithm for pneumatosis intestinalis and portal venous gas: treatment and outcome of 88 consecutive cases. *J Gastrointest Surg*. 2010;14(3):437–448. <https://doi.org/10.1007/s11605-009-1143-9>
- Schatz TP, Nassif MO, Farma JM. Extensive portal venous gas: Unlikely etiology and outcome. *Int J Surg Case Rep*. 2015;8:134–136. <https://doi.org/10.1016/j.ijscr.2014.10.058>
- Villa M, Ranade A, Jaimes-Vanegas N, et al. “STOP, LOOK, and LISTEN.” Hepatic portal venous gas: time for clinical assessment!. *Int J Angiol*. 2013;22(2):123–126. <https://doi.org/10.1055/s-0032-1333066>
- Koami H, Isa T, Ishimine T, et al. Risk factors for bowel necrosis in patients with hepatic portal venous gas. *Surg Today*. 2015;45(2):156–161. <https://doi.org/10.1007/s00595-014-0941-1>
- Wayne E, Ough M, Wu A, et al. Management algorithm for pneumatosis intestinalis and portal venous gas treatment and outcome of 88 consecutive cases. *J Gastrointest Surg*. 2009;14(3):437–448.
- Hani MB, Kamangar F, Goldberg S, et al. Pneumatosis and portal venous gas: do CT findings reassure? *J Surg Res*. 2013;185(2):581–586. <https://doi.org/10.1016/j.jss.2013.06.006>

25. Dibra R, Picciariello A, Trigiante G, et al. Pneumatosis intestinalis and hepatic portal venous gas: watch and wait or emergency surgery? A case report and literature review. *Am J Case Rep.* 2020;21: e923831. <https://doi.org/10.12659/AJCR.923831>
26. Ferrada P, Calcut R, Bauza G, et al. Pneumatosis intestinalis predictive evaluation study: a multicenter epidemiologic study of the American association for the surgery of trauma. *J Trauma Acute Care Surg.* 2017;82(3):451-460. <https://doi.org/10.1097/TA.0000000000001360>

**How to cite this article:** Cassese G, Maione F, Alagia M, et al. Portal venous gas after a failed endoscopic retrograde cholangiopancreatography attempt in a patient with a large hepatocellular carcinoma: A case report. *Clin Case Rep.* 2021;00:1–5. <https://doi.org/10.1002/ccr3.3766>