

CASE REPORT

Use of injectable collagen in partial-thickness tears of the supraspinatus tendon: a case report

Bruno Corrado^{1,*}, Ilenia Bonini¹, Vincenzo Alessio Chirico¹, Nicola Rosano² and Pietro Gisonni²

¹Department of Public Health, University Federico II of Naples, 80131 Naples, Italy, ²Department of Advanced Biomedical Sciences, University Federico II of Naples, 80131 Naples, Italy

*Correspondence address: Department of Public Health, University Federico II of Naples, Italy, Via S. Pansini n.5, 80131 Naples, Italy. Tel: +390817462796; Fax: +390817462881; E-mail: bruno.corrado@unina.it

Abstract

Management of partial-thickness rotator cuff tears is actually controversial. We treated a patient with a partial-thickness tear of the supraspinatus tendon by a series of four type I porcine collagen ultrasound-guided injections, at weekly intervals. At the same time the patient underwent physical therapy, consisting of motor re-education and proprioceptive exercises. The patient was assessed before the treatment and up to 18 months after the last injection by the Constant–Murley score, the Disability of Arm, Shoulder and Hand questionnaire and ultrasonography. Shoulder pain and functional limitation progressively improved and they almost completely disappeared at the last follow-up. Ultrasonography showed a gradual healing of the partial-thickness tear and a regeneration of the tendon structure. This is the first study on ultrasound-guided injections of type I porcine collagen for the treatment of partial-thickness rotator cuff tears. Future research should confirm the excellent result achieved in this case report.

INTRODUCTION

Partial-thickness rotator cuff tear (PTRCT) is one of the most common shoulder injuries [1]. The supraspinatus (SSP) tendon is the most affected in PTRCTs [1]. The treatment of PTRCTs remains disputed; non-operative treatment is the first approach [2]. Many injectable therapies have been proposed in the last years with controversial effectiveness [3]. According to literature, this is the first study on ultrasound (US)-guided injections of type I porcine collagen for the treatment of PTRCTs.

CASE REPORT

In March 2018, a 55-year-old right-handed housewife came to the Physical Medicine and Rehabilitation Practice complaining of pain and functional limitation in the left shoulder, lasting 2 months. She didn't report neither systemic or genetic disorders, nor previous traumas or surgical interventions and nor allergies or intolerances. She suffered from hypothyroidism

and she was in treatment with sodium levothyroxine. She didn't smoke. She was habitually practising free-body gymnastics twice a week. She had already treated the shoulder pain with rest, non-steroidal anti-inflammatory drugs and physical therapy, without improvements.

Based on physical examination we suspected left SSP tendon involvement. We excluded glenohumeral osteoarthritis by X-rays. Shoulder ultrasonography, performed by a radiologist with >20 years of experience in skeletal muscle US, revealed a partial-thickness tear of the articular surface of the SSP tendon (Grade II according to Ellman classification). We decided to treat the patient with a series of four US-guided intratendinous injections of 2-ml porcine type I collagen at weekly intervals in combination with physical therapy. After a full and clear description of the study, the patient was invited to sign the informed consent.

Injections were performed by a single doctor with >10 years of experience using an anterior approach. The patient was seated on a chair with the arm in internal rotation in order to expose as much of the SSP tendon as possible. This position was

†, <https://orcid.org/0000-0003-0990-3428>

Received: July 28, 2020; Revised: September 8, 2020; Accepted: September 21, 2020

Published by Oxford University Press and JSCR Publishing Ltd. All rights reserved. © The Author(s) 2020.

This is an Open Access article distributed under the terms of the Creative Commons Attribution Non-Commercial License (<http://creativecommons.org/licenses/by-nc/4.0/>), which permits non-commercial re-use, distribution, and reproduction in any medium, provided the original work is properly cited.

For commercial re-use, please contact journals.permissions@oup.com

Table 1: CM score and DASH questionnaire values

	T0	T1	T2	T3	T4
CM score	47	52	77	84	97
DASH score	57	48	36	34	4

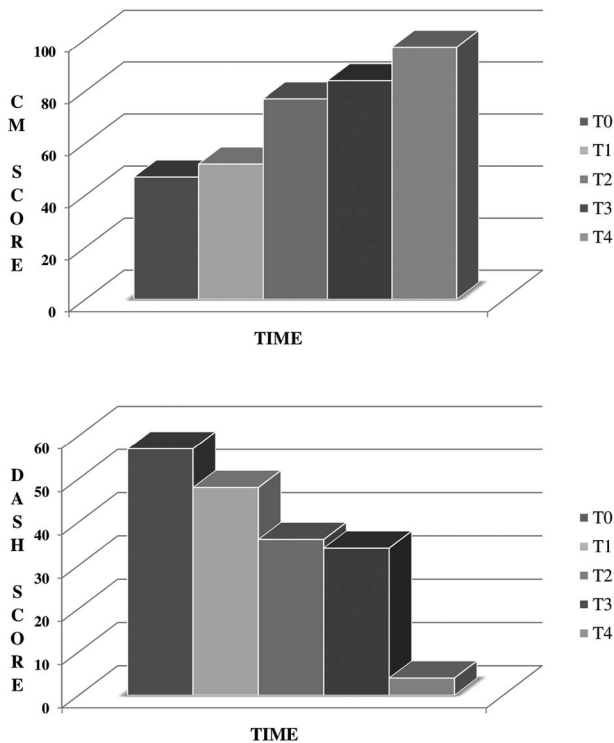


Figure 1: Outcome measures of the CM score and the DASH questionnaire over the time.

best achieved by placing the patient's arm behind her back. A 22-gauge needle was directed towards the tear of the SSP tendon as guided by US until the tip of the needle was seen in the correct position and then the collagen was injected slowly.

Physiotherapy was performed starting from the first injection and during 4 weeks, three times a week, 30 minutes per session and consisted of motor re-education and proprioceptive exercises, with the aim to recover range of motion and strength of the shoulder.

The patient was evaluated at the time of enrolment (T0), right before the third injection (T1), and 1 month (T2), 3 months (T3) and 18 months (T4) after the last injection by means of the Constant-Murley (CM) score and the Disability of the Arm, Shoulder and Hand (DASH) questionnaire. Clinical data are reported in Table 1 and their trends illustrated in Figure 1.

US assessment was performed at T0, T3 and T4 by the same expert radiologist. As shown in Fig. 2, longitudinal US of the SSP tendon at T0 showed a well-defined hypoechoic area, indicating partial-thickness tear of the articular surface of the tendon, without retraction (Grade II according to Ellman classification). Three months following the last injection, the partial-thickness tear became smaller and less defined (Grade I according to Ellman classification). Eventually, the T4 US assessment no longer showed tear within the tendon, which in addition appeared quite regular and isoechoic.

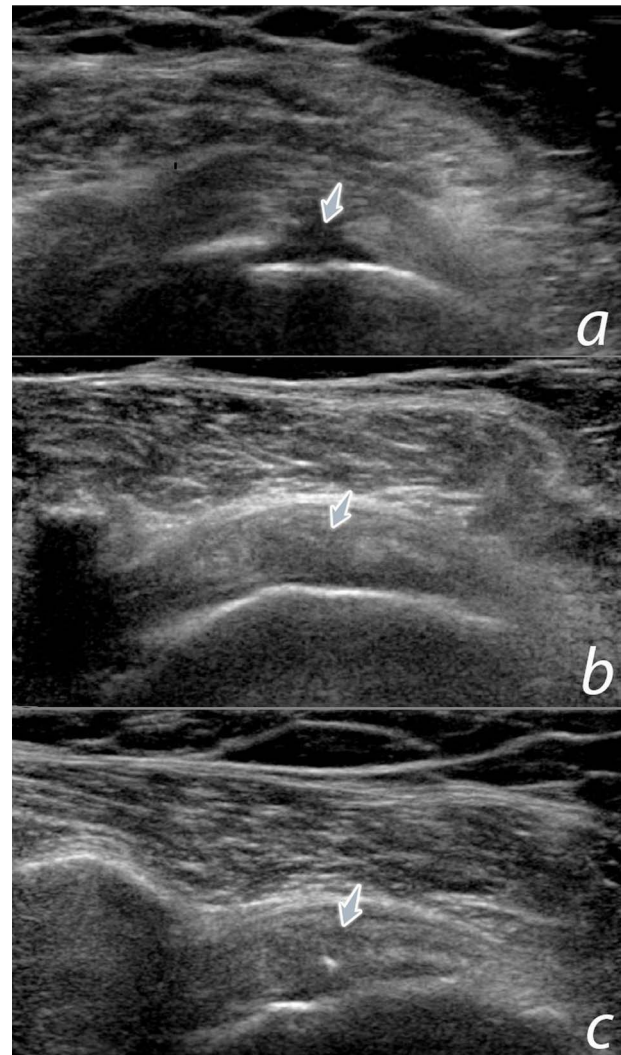


Figure 2: US assessment of the SSP tendon across multiple follow-up intervals. (a) Longitudinal US of the SSP tendon at T0 showed a well-defined partial-thickness tear of the articular surface of the tendon, without retraction (arrow). (b) Three months following the last injection, the partial-thickness tear became smaller and less defined (arrow). (c) At 18-month follow-up, the tendon looked quite regular and isoechoic, without any sign of tear (arrow).

The patient was totally compliant, following all the appointments given. No adverse events have been described after collagen injections.

DISCUSSION

According to literature, the diagnostic sensitivity and specificity of shoulder US on rotator cuff tear detection has a range of 46–95% and 50–95%, respectively [4]. The variability is highly correlated with the level of experience of the operator and the patterns of the rotator cuff tears [4].

Non-operative treatment is the first approach to PTRCTs, and surgical option has to be considered when the conservative treatment has not effect within the first 6–12 weeks [2]. Physical therapy is the first-line treatment [5]. Rest from exacerbating activity, especially repetitive overhead activity and heavy lifting, can improve the pain component. Cortisone injections may be helpful in alleviating pain in conjunction with physical therapy but offer only short-term effects [3].

Different injectable therapies have been proposed in the past years for the treatment of PTRCTs (e.g. hyaluronic acid, platelet-rich plasma, prolotherapy), but they have achieved controversial effectiveness according to literature [3].

We have decided to treat the PTRCT of our patient with type I collagen injections on the base of (i) the positive effect proved by injectable collagen on the tendon structure of cultured tenocytes [6]; (ii) the good results achieved by collagen patches implanted arthroscopically in the treatment of large and massive RC tears [7] and (iii) the promising outcomes of collagen injections in the treatment of epicondylitis and SSP tendinopathy without tears [8, 9]. Studies of degenerative tendons have found a small but significant decrease in the total collagen content and an increased proportion of collagen type III relative to collagen type I. The increase in the collagen type III to collagen type I ratio was consistent with smaller, less organized and weaker tendons.

This case report has one main limitation: the patient was not previously treated with other injective therapies; so, we cannot state that the positive effect on the PTRCT is certainly due to type I porcine collagen only. It is well known indeed that tendon needling is able to disrupt the chronic degenerative process of tendinopathies favouring localized bleeding and fibroblastic proliferation [10]. However, no data exist on the benefits of tendon needling as a stand-alone treatment for tendon tears.

In conclusion, the tear healing, the improvement in the tendon structure, the clinical and functional positive outcomes and the absence of side effects allow us to propose collagen injections as a valid option for the treatment of PTRCTs. A regenerative effect of collagen injections on tendon structure may be assumed to account the results achieved. More studies are needed to confirm these findings.

CONFLICT OF INTEREST STATEMENT

None declared.

ETHICAL APPROVAL

No approval was required.

CONSENT

An informed patient consent has been completed and it is held by the treating institution.

GUARANTOR

Bruno Corrado.

REFERENCES

1. Matthewson G, Beach CJ, Nelson AA, et al. Partial Thickness Rotator Cuff Tears: Current Concepts. *Adv Orthop* 2015;2015:458786. doi: [10.1155/2015/458786](https://doi.org/10.1155/2015/458786).
2. Ryösa A, Laimi K, Äärimala V, Lehtimäki K, Kukkonen J, Saltychev M. Surgery or conservative treatment for rotator cuff tear: a meta-analysis. *Disabil Rehabil*. 2017;39:1357–63. doi: [10.1080/09638288.2016.1198431](https://doi.org/10.1080/09638288.2016.1198431).
3. Lin MT, Chiang CF, Wu CH, Huang YT, Tu YK, Wang TG. Comparative effectiveness of injection therapies in rotator cuff tendinopathy: a systematic review, pairwise and network meta-analysis of randomized controlled trials. *Arch Phys Med Rehabil* 2019;100:336–49.e15. doi: [10.1016/j.apmr.2018.06.028](https://doi.org/10.1016/j.apmr.2018.06.028).
4. Chang RF, Lee CC, Lo CM. Quantitative diagnosis of rotator cuff tears based on sonographic pattern recognition. *PLoS One*. 2019;14:e0212741. doi: [10.1371/journal.pone.0212741](https://doi.org/10.1371/journal.pone.0212741).
5. Edwards P, Ebert J, Joss B, Bhabra G, Ackland T, Wang A. Exercise rehabilitation in the non-operative management of rotator cuff tears: a review of the literature. *Int J Sports Phys Ther*. 2016;11:279–301.
6. Randelli F, Menon A, Giai Via A, Mazzoleni MG, Sciancalepore F, Brioschi M, et al. Effect of a collagen-based compound on morpho-functional properties of cultured human tenocytes. *Cells*. 2018;7:246. doi: [10.3390/cells7120246](https://doi.org/10.3390/cells7120246).
7. Thon SG, O'Malley L 2nd, O'Brien MJ, Savoie FH 3rd. Evaluation of healing rates and safety with a bioinductive collagen patch for large and massive rotator cuff tears: 2-year safety and clinical outcomes. *Am J Sports Med*. 2019;47:1901–1908. doi: [10.1177/0363546519850795](https://doi.org/10.1177/0363546519850795)
8. Corrado B, Mazzuocollo G, Liguori L, Chirico VA, Costanzo M, Bonini I, et al. Treatment of lateral epicondylitis with collagen injections: a pilot study. *MLTJ* 2019;9:584–9. doi: [10.32098/mltj.04.2019.14](https://doi.org/10.32098/mltj.04.2019.14).
9. Corrado B, Bonini I, Chirico VA, Filippini E, Liguori L, Magliulo G, et al. Ultrasound-guided collagen injections in the treatment of supraspinatus tendinopathy: a case series pilot study. *J Biol Regul Homeost Agents*. 2020;34:33–9.
10. Krey D, Borchers J, McCamey K. Tendon needling for treatment of tendinopathy: a systematic review. *Phys Sportsmed*. 2015;43:80–6. doi: [10.1080/00913847.2015.1004296](https://doi.org/10.1080/00913847.2015.1004296).