



Beyond equality, women require extra care in cardiovascular imaging

Laura Evangelista¹ · Samia Massalha² · Alberto Cuocolo³

Published online: 13 August 2022

© The Author(s), under exclusive licence to Springer-Verlag GmbH Germany, part of Springer Nature 2022

“Is it mandatory to discriminate between women and men for cardiovascular imaging?”

This question is becoming frequent in everyday clinical practice, mainly in cardiology but also in other fields such as oncology and neurology. Metabolic syndrome and obesity in addition to other conventional cardiovascular risk factors are common in women and are related to an increasing prevalence of coronary artery disease (CAD), heart failure (HF), and other cardiac complications. Furthermore, pathophysiological mechanisms (i.e., hormones, inflammation, brain–heart axis, and sympathetic hypertonia; [1–3]) are different between women and men and therefore there is a need for a correct definition of the female biological profile. Non-invasive and invasive imaging procedures are essential for determining the pathophysiology of cardiovascular disease in women, although their use should be modulated based on the clinical conditions. Hence, the paper by Mikail et al. entitled “Imaging of Heart Disease in Women: Review and Case Presentation” recently published in the *European Journal of Nuclear Medicine and Molecular Imaging* [4] summarizes the specific features of cardiac imaging in four of the most common presentations of heart diseases in the female population including CAD, HF, pregnancy complications, and heart disease in oncology.

Indeed, heart diseases in all its spectrum have been under-detected and underdiagnosed and, therefore, women were undertreated and showing a worse prognosis. The choice of the best imaging approach or the correct diagnostic flowchart in women and in some clinical conditions should consider

different challenges relative to the imaging itself, such as the principle of radioprotection and technical features, as already emerged in the paper by Mikail et al. [4] and summarized in Table 1.

However, the second question that arises from the paper by Mikail et al. [4] is as follows: “If we have to distinguish the cardiovascular imaging approach between women and men, in which clinical scenarios is it essential?”

CAD has increased in prevalence among middle-aged women [5]. The basis of CAD pathophysiology seems different between women and men, being characterized by an erosion rather than a rupture of the coronary plaque, respectively in females and males. Therefore, “female” imaging should be able to evaluate a possible erosion of the plaque, vascular spasm, or a spontaneous dissection of the coronary artery. Coronary computed tomography angiography (CCTA) can detect arterial stenosis and dissections; however, in the female patient, its diagnostic accuracy can be limited due to the smaller diameter of the vessels [6]. The definition of CAD might be erroneous in women and should be substituted by ischemic heart disease since it includes coronary arteries (whether due to atherosclerosis, spasm, or dissection), microcirculation, or an imbalance of myocardial supply and demand such as in hypertrophic cardiomyopathies. Therefore, cardiac magnetic resonance imaging (CMRI) is considered a valid imaging technique for testing microvascular dysfunction in women [7], especially since its use is not associated with ionizing radiation exposure. Furthermore, there is large evidence that the combined use of stress electrocardiography (ECG)-gated single-photon emission tomography (SPECT) myocardial perfusion imaging, either as a diagnostic or prognostic tool, in women with an intermediate-high pre-test likelihood of CAD is of great value [8, 9]. In addition, positron emission tomography (PET) myocardial quantitative measurements of coronary flow reserve have been widely used and can identify special population — mainly women with microvascular disease leading to cardiovascular morbidity. This technological advancement shed a light on the overlooked cardiovascular morbidity of women in the absence of epicardial disease.

This article is part of the Topical Collection on Cardiology

✉ Laura Evangelista
laura.evangelista@unipd.it

¹ Nuclear Medicine Unit, Department of Medicine DIMED, University of Padua, Via Giustiniani, 2 35128 Padua, Italy

² Department of Cardiology, Rambam Health Care Campus, Haifa, Israel

³ Department of Advanced Biomedical Sciences, University Federico II, Naples, Italy

Table 1 Challenges of the cardiovascular imaging modalities in women

	Radiation exposure	Technical challenges
Echocardiography	No radiation exposure	Scarce acoustic window related to breast cancer Concave-shaped chest wall
CCTA	0.5–7 mSv	High breast tissue dose New technological advancement will reduce it
CMRI	No radiation exposure	Low breast attenuation High rate of claustrophobia
SPECT	2–8 mSv	Breast tissue attenuation CT coregistration and specific position may reduce it
PET	5–7 mSv	Breast tissue attenuation CT coregistration and specific position may reduce it

CCTA, coronary computed tomography angiography; *CMRI*, cardiac magnetic resonance imaging; *SPECT*, single-photon emission tomography; *PET*, positron emission tomography

In addition, women are more prone to developing certain types of HF that can be associated with different aetiologies; therefore, a distinct imaging flowchart should be linked with the symptoms and clinical signs in addition to gender. Often, women affected by HF have some risk factors, such as age > 70 years, metabolic syndrome, and atrial fibrillation. These conditions are associated with chronic inflammation leading to fibrosis. HF conditions such as those associated with systemic inflammatory diseases leading to non-infectious myocarditis in case of connective tissue diseases, cardiac amyloidosis, and Takotsubo cardiomyopathy have been largely described in women. In the former cases, cardiac involvement might be overlooked and the condition might be underdetected unless we truly have clear and appropriate use criteria for cardiovascular imaging in women. Echocardiography and CMRI are useful modalities in the assessment of cardiac function, chamber volumes, and mass. However, nuclear imaging has a large application, either with SPECT and PET, by using different radiopharmaceutical agents able to assess myocardial innervation (i.e., ¹²³I-MIBG [10]), myocardial perfusion (i.e., [^{99m}Tc]-sestamibi or tetrofosmin or ⁸²Rb [11]), myocardial metabolism (i.e., [¹⁸F]-FDG [12]), and the inflammation pathogenesis (i.e., [^{99m}Tc]-diphosphonate [13]). Indeed, nuclear medicine has a valuable role in the assessment of cardiac function in the presence of arrhythmia due to its larger data acquisition; its accuracy is less affected by arrhythmia than an echocardiogram and does not have the limitation of an echocardiographic window. Fibrosis represents a key element of cardiomyopathy, mainly in HF pathogenesis and in CAD. Moreover, new agents radiolabelling fibroblast activation protein inhibitors (FAPI) for diagnostic and therapeutic purposes, such as [⁶⁸Ga]-FAPI/[¹⁸F]-FAPI or [¹⁷⁷Lu]-FAPI, would be useful for targeting myofibroblast activities [14] in females with cardiovascular disease.

The paper by Mikail et al. [4] gives insight about heart diseases in pregnancy, including the dilemma of the choice between the different imaging modalities, especially when

approaching this special and vulnerable population of young women. The relatively advanced age of pregnancy in the modern world in addition to pre-existing cardiac disease is associated with an increase in cardiac morbidity and mortality. Early diagnosis of cardiovascular disease during pregnancy is crucial for the early initiation of treatment. Pregnancy is a particular physiological condition and therefore a lot of challenges should be faced, firstly physiological changes (either hemodynamic or structural) and secondly the associated ionizing radiation exposure (mother and fetus should be kept safe). Therefore, during pregnancy, the imaging modality of choice should be either echocardiography or CMRI without contrast agents, while during breastfeeding all imaging can be performed, by following specific recommendations. A potential imaging algorithm to use in pregnancy was reported by Windram et al. [15] who suggested to use mainly echocardiography (either a transthoracic or transesophageal) or CMRI in case of valvular and ventricular disease, while using CT or cardiac invasive angiography in case of acute pathology of aorta or acute CAD, respectively. Although SPECT and PET should not be completely excluded, they should be postponed as much as possible with special care to the timing of breastfeeding in case the study was performed after delivery.

Women require extra care when diagnosed with certain types of malignancies, and the cardiovascular system could be affected in this special population whether directly due to cancer or because of old and novel chemotherapeutic agents that can lead to a large spectrum of cardiotoxic manifestations. The most common cancer linked to females and correlated with drug-related cardiotoxicity is breast cancer that can be treated with chemotherapy based on anthracycline, radiation therapy, and target therapy such as trastuzumab. Radiation in addition to chemotherapy can affect the coronary microvasculature, with subsequent inflammatory and thrombotic changes, resulting in capillary loss, and reduced myocardial tissue perfusion. Conversely, anthracycline and trastuzumab may concur in increasing the risk of cardiovascular disease,

either as irreversible or reversible damage. In addition, novel drugs such as the immune checkpoint inhibitors may increase the cardiovascular risk, being associated with a high rate of myocarditis. Serial echocardiographic evaluation is often needed in women affected by breast cancer, to monitor the evolution of cardiac function during and after therapy. Early detection of reduced left ventricular ejection fraction (LVEF) or even earlier detection of impaired myocardial strain and strain rate that develops prior to a reduction in LVEF is crucial in the management of these women to prevent cardiovascular death in a cancer survivor. Sometimes echocardiography is not sensitive to sub-clinical or early-stage dysfunctions; therefore, CMRI and nuclear medicine techniques can support the identification of cardiac damage. Recent papers have also investigated the role of oncological imaging with [18F]-FDG PET/CT in predicting cancer therapy-induced cardiotoxicity in breast cancer women undergoing anthracycline and trastuzumab treatment [16].

In this comprehensive review [4], and based on the available data, the question is as follows: how can we personalize the cardiovascular imaging approach in females? We suggest a potential diagnostic flowchart for each cardiovascular disease as reported in Fig. 1. The correct imaging choice depends on several factors such as availability, experience,

and clinical scenario and by a multidisciplinary approach. Nuclear medicine has an important role in distinguishing different pathophysiological patterns, rule in or out ischemic heart disease, and cardiomyopathies and provides guidance to the best therapeutic approach, especially when accompanied by other imaging modalities, such as echocardiography, CCTA, and CMRI. However, although radiation exposure may be an obstacle particularly in young females or during pregnancy, the new imaging techniques (radiopharmaceutical agents, newer post-processing algorithms such as iterative reconstruction, newer cadmium-zinc-telluride cameras; [17, 18] can lower the radiation burden.

In conclusion, women in general but especially those with ischemic heart disease are undertreated, have higher mortality rates, and have a worse cardiovascular outcome. In an era of such advancement in multi-modality cardiovascular imaging, we can recognize the unique aspects of cardiovascular diseases in women. The recognition of the different disease patterns both in terms of physiological characteristics between women and men, the setup of specific and distinct thresholds for normal values for women, and the recognition of the new definitions of diseases will help reduce the currently existing sex-related mortality gap between women and men. Therefore, updated imaging consensus or guidelines are mandatory at this stage.

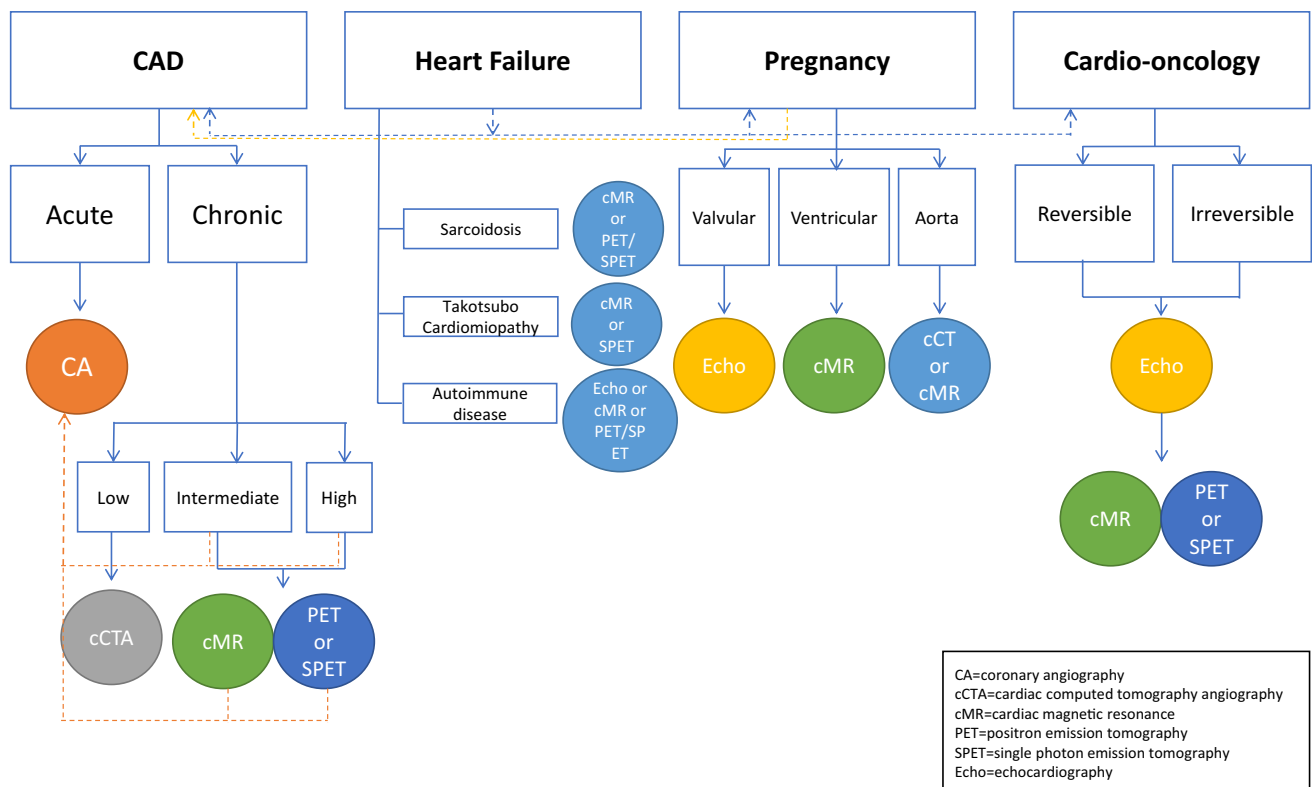


Fig. 1 Potential diagnostic flowcharts for cardiovascular imaging in women

Declarations

Ethics approval This article does not contain any studies with human participants or animals performed by any of the authors.

Informed consent Informed consent was not required for the present study.

Conflict of interest The authors declare no competing interests.

References

- Haider A, Bengs S, Luu J, Osto E, Siller-Matula JM, Muka T, Gebhard C. Sex and gender in cardiovascular medicine: presentation and outcomes of acute coronary syndrome. *Eur Heart J*. 2020;41(13):1328–36. <https://doi.org/10.1093/eurheartj/ehz898>.
- Vaccarino V, Shah AJ, Mehta PK, Pearce B, Raggi P, Bremner JD, Quyyumi AA. Brain-heart connections in stress and cardiovascular disease: implications for the cardiac patient. *Atherosclerosis*. 2021;328:74–82. <https://doi.org/10.1016/j.atherosclerosis.2021.05.020>.
- Burger IA, Lohmann C, Messerli M, Bengs S, Becker A, Maredziak M, Treyer V, Haider A, Schwyzer M, Benz DC, Kudura K, Fiechter M, Giannopoulos AA, Fuchs TA, Gräni C, Pazhenkottil AP, Gaemperli O, Buechel RR, Kaufmann PA, Gebhard C. Age- and sex-dependent changes in sympathetic activity of the left ventricular apex assessed by 18F-DOPA PET imaging. *PLoS ONE*. 2018;13(8):e0202302. <https://doi.org/10.1371/journal.pone.0202302>.
- Mikail N, Rossi A, Bengs S, Haider A, Stähli BE, Portmann A, Imperiale A, Treyer V, Meisel A, Pazhenkottil AP, Messerli M, Regitz-Zagrosek V, Kaufmann PA, Buechel RR, Gebhard C. Imaging of heart disease in women: review and case presentation. *Eur J Nucl Med Mol Imaging*. 2022.
- Benjamin EJ, Blaha MJ, Chiuve SE, Cushman M, Das SR, Deo R, de Ferranti SD, Floyd J, Fornage M, Gillespie C, Isasi CR, Jiménez MC, Jordan LC, Judd SE, Lackland D, Lichtman JH, Lisabeth L, Liu S, Longenecker CT, Mackey RH, Matsushita K, Mozaffarian D, Mussolino ME, Nasir K, Neumar RW, Palaniappan L, Pandey DK, Thiagarajan RR, Reeves MJ, Ritchey M, Rodriguez CJ, Roth GA, Rosamond WD, Sasson C, Towfighi A, Tsao CW, Turner MB, Virani SS, Voeks JH, Willey JZ, Wilkins JT, Wu JH, Alger HM, Wong SS, Muntner P, American Heart Association Statistics Committee and Stroke Statistics Subcommittee. Heart Disease and Stroke Statistics-2017 update: a report from the American Heart Association. *Circulation*. 2017;135(10):e146–603. <https://doi.org/10.1161/CIR.0000000000000485>.
- Truong QA, Rinehart S, Abbara S, Achenbach S, Berman DS, Bullock-Palmer R, Carrascosa P, Chinnaiyan KM, Dey D, Ferencik M, Fuechtner G, Hecht H, Jacobs JE, Lee SE, Leipzig J, Lin F, Meave A, Pugliese F, Sierra-Galán LM, Williams MC, Villines TC, Shaw LJ, SCCT Women's Committee. Coronary computed tomographic imaging in women: an expert consensus statement from the Society of Cardiovascular Computed Tomography. *J Cardiovasc Comput Tomogr*. 2018;12(6):451–66. <https://doi.org/10.1016/j.jcct.2018.10.019>.
- Agarwal M, Shufelt C, Mehta PK, Gill E, Berman DS, Li D, Sharif B, Li N, Bairey Merz CN, Thomson LE. Cardiac risk factors and myocardial perfusion reserve in women with microvascular coronary dysfunction. *Cardiovasc Diagn Ther*. 2013;3(3):146–52. <https://doi.org/10.3978/j.issn.2223-3652.2013.08.01>.
- Kwok Y, Kim C, Grady D, Segal M, Redberg R. Meta-analysis of exercise testing to detect coronary artery disease in women. *Am J Cardiol*. 1999;83(5):660–6. [https://doi.org/10.1016/s0002-9149\(98\)00963-1](https://doi.org/10.1016/s0002-9149(98)00963-1).
- Hachamovitch R, Berman DS, Kiat H, Cohen I, Friedman JD, Shaw LJ. Value of stress myocardial perfusion single photon emission computed tomography in patients with normal resting electrocardiograms: an evaluation of incremental prognostic value and cost-effectiveness. *Circulation*. 2002;105(7):823–9. <https://doi.org/10.1161/hc0702.103973>.
- Flotats A. Role of myocardial 123I-mIBG innervation imaging in the diagnosis of neurodegenerative diseases. *Clin Transl Imaging*. 2018;6:449–58. <https://doi.org/10.1007/s40336-018-0306-7>.
- Mieres JH, Rosman DR, Shaw LJ. The role of myocardial perfusion imaging in special populations: women, diabetics, and heart failure. *Semin Nucl Med*. 2005;35(1):52–61. <https://doi.org/10.1053/j.semnuclmed.2004.09.004>.
- Ghesani M, Depuey EG, Rozanski A. Role of F-18 FDG positron emission tomography (PET) in the assessment of myocardial viability. *Echocardiography*. 2005;22(2):165–77. <https://doi.org/10.1111/j.0742-2822.2005.04032.x>.
- Ruan D, Sun L. Diagnostic efficacy of bone scintigraphy in transthyretin cardiac amyloidosis: an updated systematic review and Bayesian bivariate meta-analysis. *Clin Transl Imaging*. 2022;10:85–98. <https://doi.org/10.1007/s40336-021-00471-8>.
- Heckmann MB, Reinhardt F, Finke D, Katus HA, Haberkorn U, Leuschner F, Lehmann LH. Relationship between cardiac fibroblast activation protein activity by positron emission tomography and cardiovascular disease. *Circ Cardiovasc Imaging*. 2020;13(9):e010628. <https://doi.org/10.1161/CIRCIMAGING.120.010628>.
- Windram J, Grewal J. Cardiovascular imaging and pregnancy. *Can J Cardiol*. 2021;37(12):2080–2. <https://doi.org/10.1016/j.cjca.2021.09.018>.
- Kim J, Cho SG, Kang SR, Yoo SW, Kwon SY, Min JJ, Bom HS, Song HC. Association between FDG uptake in the right ventricular myocardium and cancer therapy-induced cardiotoxicity. *J Nucl Cardiol*. 2020;27(6):2154–63. <https://doi.org/10.1007/s12350-019-01617-y>.
- Hyafil F, Chequer R, Sorbets E, Estellat C, Ducrocq G, Rouzet F, Alfaïate T, Regaieg H, Abtan J, Leygnac S, Milliner M, Imbert L, Burg S, Ben Azzouna R, Potier L, Laouénan C, Quentin C, Rousset R, Hartemann A, Montalescot G, Marie PY, Steg G, Le Guludec D. Head-to-head comparison of the diagnostic performances of Rubidium-PET and SPECT with CZT camera for the detection of myocardial ischemia in a population of women and overweight individuals. *J Nucl Cardiol*. 2020;27(3):755–68. <https://doi.org/10.1007/s12350-018-01557-z>.
- Mannarino T, Assante R, Ricciardi C, Zampella E, Nappi C, Gaudieri V, Mainolfi CG, Di Vaia E, Petretta M, Cesarelli M, Cuocolo A, Acampa W. Head-to-head comparison of diagnostic accuracy of stress-only myocardial perfusion imaging with conventional and cadmium-zinc telluride single-photon emission computed tomography in women with suspected coronary artery disease. *J Nucl Cardiol*. 2021;28(3):888–97. <https://doi.org/10.1007/s12350-019-01789-7>.

Publisher's note Springer Nature remains neutral with regard to jurisdictional claims in published maps and institutional affiliations.