

# Treatment of Common Femoral Artery Lesions Involving the Superficial and Profunda Femoral Artery Bifurcation: Is the Snow Too Melted to Plow With New Endovascular Devices?

Alberto Cereda<sup>1</sup>, MD; Paolo Cioffi<sup>1</sup>, MD; Riccardo Iorio<sup>1</sup>, MD; Attilio Cotroneo<sup>2</sup>, MD; Giuseppe Celano<sup>1</sup>, MD; Sante Bongo<sup>1</sup>, MD; Gaetano Chiricolo<sup>3</sup>, MD; Giuseppe Sangiorgi<sup>3</sup>, MD

From the <sup>1</sup>Department of Cardiology and <sup>2</sup>Department of Vascular Surgery, Clinica San Gaudenzio, Novara, Italy; <sup>3</sup>Department of Systemic Medicine, Institute of Cardiology, University of Tor Vergata, Rome, Italy

**Abstract:** Surgical endarterectomy for common femoral artery bifurcation obstructive atherosclerotic disease represents the "gold standard" therapy, with excellent long-term results and minimal complications. On the other hand, recent advances in endovascular therapy have led to a safer and similar effective results, with a potential reduction in hospital stays, quicker recovery to normal functional status, good short- and long-term clinical outcomes, and consequent lower morbidity and mortality.

Percutaneous directional atherectomy and intravascular lithotripsy are game-changer medical devices for the treatment of peripheral arterial disease related to complex and severely calcific atherosclerotic plaque encroaching the common femoral artery bifurcation segment. The application of these devices, technical execution, and clinical experience is reported in two exemplary cases.

VASCULAR DISEASE MANAGEMENT 2020;17(5):E87-E91.

**Key words:** angioplasty; peripheral artery disease; femoral bifurcation; directional atherectomy; intravascular lithotripsy (IVL); steno-obstructive disease

## Abbreviations

CFA → Common femoral artery  
CFE → Common femoral endarterectomy  
DA → Directional atherectomy  
IVL → Intravascular lithotripsy

MALEs → Major adverse limb events  
PAD → Peripheral arterial disease  
PFA → Profunda femoral artery  
SFA → Superficial femoral artery

## Introduction

Atherosclerotic disease of the common femoral artery bifurcation (CFAB) is usually represented by a complex lesion morphology. There is typically calcification of the common femoral artery with extension of the calcification into the bifurcation superficial and profound femoral arteries. Patients affected by CFAB disease present with severe claudication or critical limb ischemia due to the large vascular territory at risk.

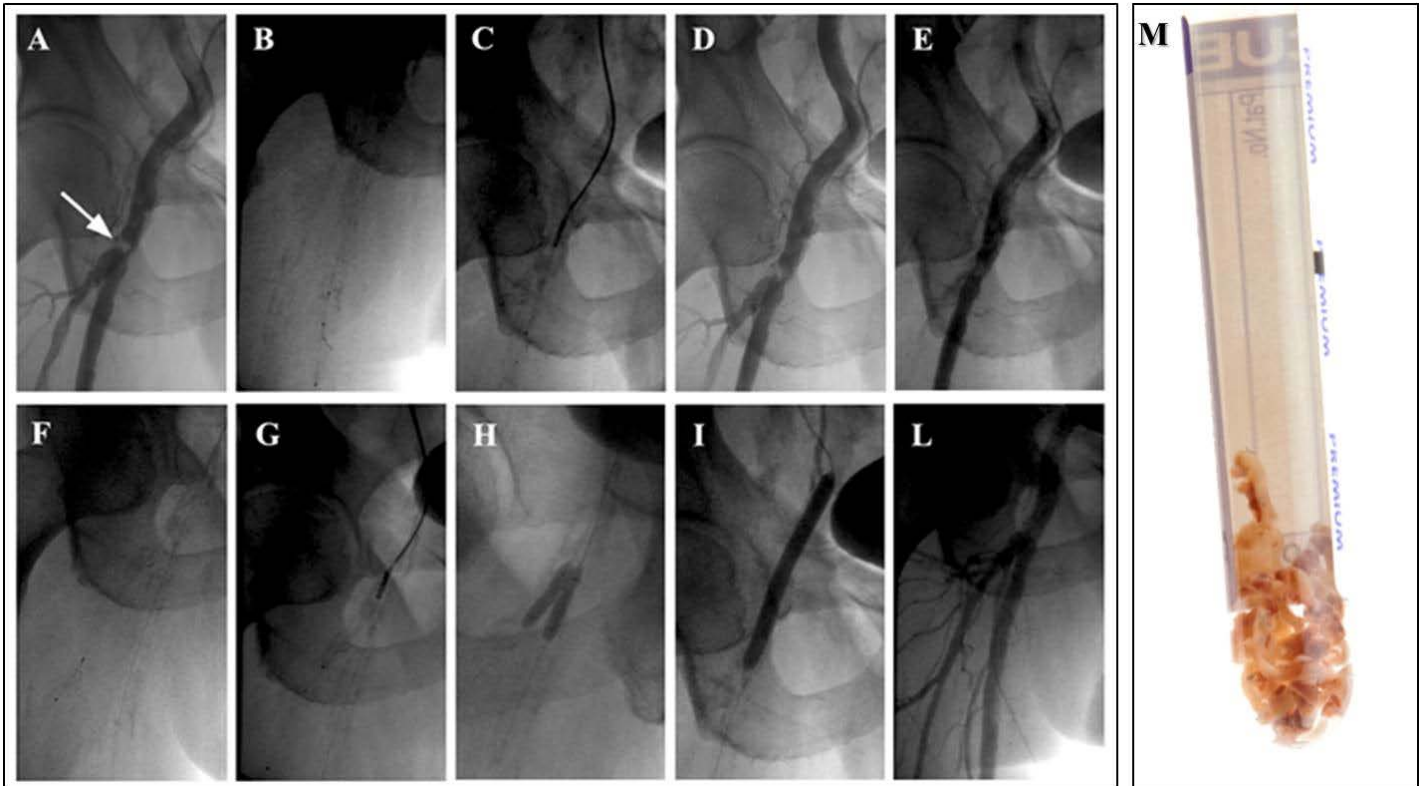
Common femoral artery endarterectomy (CFE) has been historically considered the treatment of choice for CFAB<sup>1-3</sup>, given its simple surgical execution under spinal or local anesthesia, sustained patency, and historically low complication rate.<sup>4-6</sup> However, significant morbidity has been recently associated with CFE. In the ACS-NSQIP registry<sup>8</sup> analyses that included data from 3356 patients, the risk of major or minor complications was 7.9% to 15%. Moreover, Nguyen et al<sup>7</sup> analyzed data from 1843 patients who had undergone isolated CFE between 2005 and

2010. In this study, postoperative mortality was 3.4% with a 15% risk of combined morbidity and mortality. Wound complications occurred in 8.4% of patients with 2.0% experiencing deep wound infections, 1.1% having graft failure, and 0.9% with wound dehiscence.

Given their relatively low risk and high technical success, endovascular interventions have been accepted by some authors as first-line therapy for many patients with CFAB disease<sup>9</sup>, but given the strategic location of the vessel, the endovascular management remains controversial.<sup>10</sup>

It is worth noting that simple plain balloon treatment of the CFA bifurcation segment may be complicated by a "snowplow" effect during balloon inflation with an increased risk of PFA and SFA occlusion. Moreover, stent placement in the inguinal region, where leg bending constantly occurs, can be complicated by stent fracture and stent occlusion in the long-term follow-up.

Currently, new technologies such as directional atherectomy<sup>11</sup>



**Figure 1.** (A) Baseline angiogram from right femoral artery bifurcation demonstrating common femoral artery occlusion (arrow). (B) A 6 cm SpiderFx filter (Medtronic) was placed at the level of the middle superficial femoral artery distal to the lesion. (C) An LS-M directional atherectomy catheter with 6 cm tip (SilverHawk, Medtronic) device was advanced and 7 circumferential cuts were performed. (D) Improvement of lumen patency and removal of abundant plaque material after circumferential cuts. (E) Plaque shift occurred during SFA treatment with slow flow in the PFA. (F) A second filter was advanced and placed in the mid segment of the PFA. (G) The same atherectomy catheter was utilized with 6 passages in order to perform plaque debulking at the level of the ostium of the PFA. (H) Kissing balloon inflation with two 4.0 mm x 15 mm non-compliant Sprinter coronary balloons (Medtronic) was then performed at the level of bifurcation. (I) Inflation at 12 atm of a 7 mm x 60 mm drug-eluting balloon was utilized at the level of the distal CFA involving the bifurcation region. (L) Final angiography. (M) Extracted material after plaque multiple debulking cuts at the level of the CFA, SFA, and PFA with SilverHawk directional atherectomy.

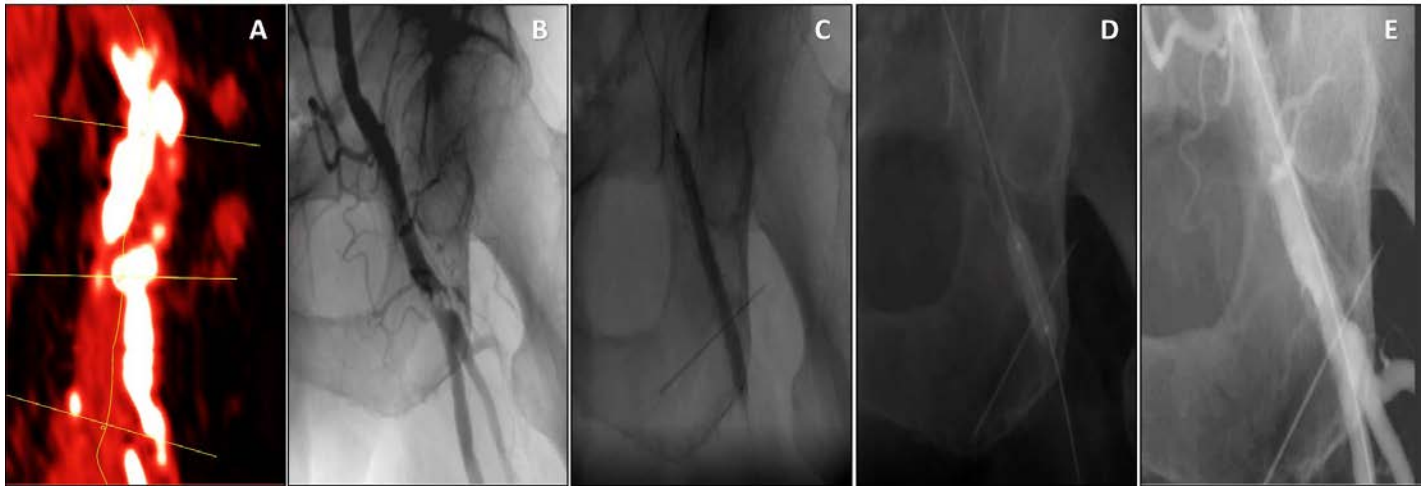
and intravascular lithotripsy<sup>12</sup> are available for heavily calcified “no-stent lesions” and large plaque burden in high-risk anatomy. Advances in such technologies resulted in a renewed interest in the potential use of endovascular therapy for the common femoral segment and bifurcation disease.

Herein, we describe two cases of chronic limb ischemia with the involvement of CFA bifurcation in which successful revascularization was achieved in the short- and long-term follow-up (up to 2 years) by percutaneous directional atherectomy (plaque debulking) and intravascular lithotripsy (plaque modulation). The technical execution and clinical experience with these devices are reported below.

### Case 1. Directional Atherectomy

A 71-year-old man with known coronary artery disease (percutaneous transluminal coronary angioplasty and coronary artery bypass graft surgery) and severe heart failure with an ejection fraction of 26% was evaluated for lifestyle-limiting right calf

claudication (ankle-brachial index [ABI] 0.4) and ultrasound evidence of a heavily calcified stenosis of the right common femoral artery. The patient was evaluated by the heart team and an endovascular management strategy was recommended. Peripheral angiography was subsequently performed with confirmation of a tight, eccentric, focal stenosis of the CFA at the level of the bifurcation (**Figure 1A**). Through an 8 French (Fr) cross-over antegrade Destination sheath (Terumo) an .014-inch BMW (Abbott Vascular) was used to cross the lesion at the level of the mid-right SFA. After placement of a 6 cm SpiderFx filter (Medtronic), a directional atherectomy peripheral device with a 6 cm tip (SilverHawk, Medtronic) was advanced and 7 circumferential cuts were performed, resulting in an improvement of lumen patency and the removal of abundant plaque material. Plaque shift (**Figure 1E**) occurred with transient slow-flow and the same directional atherectomy catheter was applied to debulk the ostial lesion. A final kissing balloon inflation with two 4.0 mm x 15 mm Sprinter non-compliant coronary balloons (Medtronic) was then performed at the level of bifurcation to



**Figure 2.** (A) Computed tomography stretched curve MPR reconstruction of the femoral bifurcation with heavy calcifications (VR red vessels preset, calcification in white). (B) Femoral angiography. (C) Application of the Shockwave Medical peripheral IVL system (6 mm x 60 mm). (D) Post dilatation with two 7 mm overlapping drug-eluting balloons. (E) Final angiographic result.

stabilize lumen geometry before final use of a 7 mm x 60 mm peripheral drug-eluting balloon (Freeway, Eurocor) (Figure 2L). The patient was discharged the day after the intervention with lifelong aspirin 100 mg/daily and clopidogrel 75 mg/daily for three months. He was followed in our outpatient clinic and was asymptomatic at 18 months follow-up with an ABI of 0.9 (Figure 2, A→M).

### Case 2. Intravascular Lithotripsy

An 86-year-old man with severe lung disease and a history of mild cognitive impairment was admitted for an IIB Leriche-Fontaine claudication. Ultrasound and computed tomography (Figure 2A) revealed a calcified near-occlusion of the left CFA with the involvement of the proximal PFA (Figure 2B). The patient was considered at high surgical risk due to the severity of his comorbidities. Over a 6 Fr cross-over antegrade sheath and a workhorse wire (V18, Boston Scientific), balloon angioplasty was performed, pre-dilating the artery with a 5 mm x 60 mm peripheral balloon (Evercross, Medtronic) at 8 atmospheres (atm) followed by a Shockwave intravascular lithotripsy peripheral balloon 7 mm x 60 mm (Shockwave Medical), with application of 180 pulses at 4 and 6 atm through the left CFA and proximal SFA (Figure 2C). After cracking the lesion and markedly improved lumen gain, angioplasty was performed with a 7 mm x 40 mm paclitaxel drug-coated balloon at 14 atm (In.Pact Admiral DCB, Medtronic) from CFA to SFA. Final angiography confirmed a good result (residual stenosis <30%) (Figure 2D). The patient was discharged two days after the procedure with lifelong aspirin 100 mg/daily and clopidogrel 75 mg/daily for three months with symptoms resolution and a persistent 15-month long-term functional status improvement and an ABI of 0.8.

### Discussion

Open-surgery endarterectomy remains the gold standard to treat atherosclerotic lesions of the femoral bifurcation, being a well-proven, low-risk surgery with known, durable success. CFAB remains a surgical domain for several reasons: this region is easily surgical accessible, surgical endarterectomy is associated with favorable long-term outcomes, and finally, CFAB may be complicated by plaque prolapse and shift into the main branches of the carina (SFA and PFA) during an endovascular approach. Moreover, the region at the level of inguinal ligament it is usually considered a “no-stent zone” because of biomechanical stresses that render the CFB particularly vulnerable to stent fracture, acute and subacute thrombosis, and neointimal hyperplasia.<sup>13,14</sup>

Data obtained from several studies reported long-term follow-up patency rates for surgical endarterectomy varying from 74% to 94%.<sup>15,16</sup> In this context, many suggest that CFE should remain the standard of care for occlusive disease of the CFA because of its safety and efficacy, representing the real standard for comparison with emerging endovascular therapies. However, it is important to note that significant morbidity has been reported following CFE.<sup>7</sup> In a recently published, large, multicenter registry<sup>8</sup>, the risk of major or minor complications ranged between 7.9% and 15%. Moreover, in another recently published study<sup>7</sup> on isolated CFE, postoperative mortality was 3.4%, with a 15% risk of combined morbidity and mortality. Wound complications occurred in 8.4% of patients, with 2.0% experiencing deep wound infections, 1.1% having graft failure, and 0.9% with wound dehiscence. Finally, 10.2% of patients required return to the operating room.<sup>7,8</sup> Both studies identified patients at high risk of periprocedural complications, including death; these are patients who may indeed benefit from a first-line endovascular management strategy. When compared to CFE, several endovascular studies (see the review by Halpin et al<sup>17</sup>) demonstrated lower incidences of both morbidity and mortality. There were no periprocedural deaths reported, which is significantly less than the 3.4% reported by Nguyen et al.<sup>7</sup> In the

largest series published to date, Soga et al<sup>18</sup> achieved 96% technical success in 111 treated limbs. However, through technical success is consistently high, the efficacies of endovascular interventions are limited by lower rates of long-term patency. In the paper by Halpin et al<sup>17</sup>, the primary patency rate with endovascular therapy was consistently lower when compared to CFE (73%–82% and 47%–50% at 1 and 5 years, respectively). Nevertheless, it has yet to be determined if newer technologies such as atherectomy devices, drug-eluting balloons, and intravascular lithotripsy, which have not been systematically evaluated in the management of CFA stenosis, can improve long-term patency. These therapies have demonstrated durable outcomes when compared to angioplasty in patients with femoropopliteal atherosclerosis, highlighting the need to evaluate their efficacy in the CFA.<sup>19,20</sup>

Herein, we have reported two cases in which directional atherectomy (DA) and intravascular-lithotripsy (IVL) followed by drug-eluting balloon application at the level of bifurcation, were respectively utilized to treat CFB disease.

Directional atherectomy<sup>21</sup> is performed with a side-cutting device. The cutter of the catheter is guided directly to the plaque for targeted atherosclerotic plaque removal. The Achilles' heel of directional atherectomy is embolic debris during plaque debulking with distal embolization, a complication avoided in our case with use of a filter device. One of the adjunctive proposed advantages of directional atherectomy is the avoidance of angioplasty and stenting in the femoral region. We opted for a final drug-coating balloon inflation after directional atherectomy to reduce the risk of restenosis in this complex anatomy.

The DEFINITIVE AR study<sup>22</sup> (Directional Atherectomy Followed by a Paclitaxel-Coated Balloon to Inhibit Restenosis and Maintain Vessel Patency - A Pilot Study of Anti-Restenosis Treatment) was an randomized, controlled trial designed to estimate the effect of directional atherectomy before DCB to facilitate the development of future endpoint-driven randomized studies. DAART (DA+drug-coated balloon) was effective and safe, and, even if the study was not powered highly enough, there was increased angiographic patency at 12 months and freedom ( $\Delta+28.1\%$ ) from target lesion revascularization at 24 months.

Intravascular lithotripsy (IVL) is a technology made up of a semi-compliant balloon catheter, a connector cable, and a generator. When activated, it releases pulsatile mechanical energy that causes microfractures in the calcium component of the atherosclerotic plaque.

The DISRUPT PAD I and II trials<sup>23,24</sup> have demonstrated that IVL is safe and effective for above-knee interventions. Procedural success was 100%, with a mean 24% residual stenosis and very few flow-limiting dissections. The DISRUPT PAD III randomized, controlled trial is currently enrolling patients. The IVL system also showed promise in coronary lesions in the DISRUPT CAD trial<sup>25</sup>, though it has not yet been compared with other plaque modification methods like rotational and orbital atherectomy. IVL technology applied through a balloon catheter is very versatile: cases of bifurcation kissing in the iliac using two IVL catheters at one time (kissing IVL technique) have already been shared on social media.<sup>26</sup>

Knowledge of different mechanisms and technical features means lesion modification can be achieved with the utilization of different devices together with a different sequence of applications and endless modular combinations, an example of which was reported in the recent case of RotaTripsy treatment (a combination of rotational atherectomy and IVL).<sup>27</sup>

## Conclusion

CFE remains the standard of care and has consistently demonstrated durable results. However, there is more morbidity and mortality associated with this procedure than previously thought. Patients at high risk of perioperative complications can be identified and may benefit from an endovascular approach. Endovascular interventions for CFA stenosis have lower rates of complications, high rates of technical success, and good short-term patency, but an increased need for repeat interventions, when compared to surgery. Herein, we have reported two cases at high risk for surgical CFE treated respectively with directional atherectomy and intravascular lithotripsy, with good clinical success both in short- and long-term follow-up. Trials comparing CFE with endovascular therapy are needed to better guide clinicians in the management of CFA stenosis. It may be that, in the near future, application of newer atherectomy devices may eliminate the worry of the "snow is too melted to plow", yielding beneficial outcomes for patients and becoming the new "gold standard" for treatment of complex CFAB lesions. ■

*Disclosure: The authors have completed and returned the ICMJE Form for Disclosure of Potential Conflicts of Interest. They report no conflicts of interest regarding the content herein.*

*Manuscript submitted January 10, 2020, final version accepted March 6, 2020.*

*Address for correspondence: Prof. Giuseppe Sangiorgi, Department of Systemic Medicine, Viale Oxford 81- Rome, Italy. Email: gsangiorgi@gmail.com*

## REFERENCES

1. Aboyans V, Ricco JB, Bartelink MEL, et al; ESC Scientific Document Group. 2017 ESC guidelines on the diagnosis and treatment of peripheral arterial diseases, in collaboration with the European Society for Vascular Surgery (ESVS). *Eur Heart J*. 2018;39(9):763–816.
2. Mukherjee D, Inahara T. Endarterectomy as the procedure of choice for atherosclerotic occlusive lesions of the common femoral artery. *Am J Surg*. 1989;157(5):498–500.
3. Desai M, Tsui J, Davis M, et al. Isolated endarterectomy of femoral bifurcation in critical limb ischemia: is restoration of inline flow essential? *Angiology*. 2011;62(2):119–125.
4. Kang JL, Patel VI, Conrad MF, Lamuraglia GM, Chung TK, Cambria RP. Common femoral artery occlusive disease: contemporary results following surgical endarterectomy. *J Vasc Surg*. 2008 Oct;48(4):872–877.
5. Mays RJ, Regensteiner JG. Therapy for peripheral artery disease: gaps in treating patients with claudication. *Circulation*. 2014;130(12):929–931.
6. Ballotta E, Gruppo M, Mazzalai F, Da Giau G. Common femoral artery endarterectomy for occlusive disease: an 8-year single-center

- prospective study. *Surgery*. 2010;147:268-274.
7. Nguyen BN, Amdur RL, Abugideiri M, Rahbar R, Neville RE, Sidawy AN. Postoperative complications after common femoral endarterectomy. *J Vasc Surg*. 2015;61(6):1489-1494. doi:10.1016/j.jvascsurg.2015.05.018
  8. Siracuse JJ, Gill HL, Jones DW, et al. Risk factors for protracted postoperative length of stay after lower extremity bypass for critical limb ischemia. *Ann Vasc Surg*. 2014;28(6):1432-1438.
  9. Rooke TW, Hirsch AT, Misra S, et al. American College of Cardiology Foundation Task Force; American Heart Association Task Force. Management of patients with peripheral artery disease (compilation of 2005 and 2011 ACCF/AHA Guideline Recommendations): a report of the American College of Cardiology Foundation/American Heart Association Task Force on Practice Guidelines. *J Am Coll Cardiol*. 2013;61(14):1555-1570.
  10. Bonvini RF, Rastan A, Sixt S, et al. Endovascular treatment of common femoral artery disease: medium-term outcomes of 360 consecutive procedures. *J Am Coll Cardiol*. 2011;58(8):792-798.
  11. Keeling WB, Shames ML, Stone PA, et al. Plaque excision with the Silverhawk catheter: early results in patients with claudication or critical limb ischemia. *J Vasc Surg*. 2007; Jan 45(1):25-31.
  12. Brodmann M, Werner M, Holden A, et al. Primary outcomes and mechanism of action of intravascular lithotripsy in calcified, femoropopliteal lesions: results of Disrupt PAD II. *Catheter Cardiovasc Interv*. 2019 Feb 1;93(2):335-342. doi: 10.1002/ccd.27943.
  13. Garcia L, Jaff MR, Metzger C, et al. Wire-interwoven nitinol stent outcome in the superficial femoral and proximal popliteal arteries: twelve-month results of the SUPERB trial. *Circ Cardiovasc Interv*. 2015 May;8(5). pii: e000937. doi: 10.1161/CIRCINTERVENTIONS.113.000937.
  14. Gouëffic Y, Schiava ND, Thaveau F, et al. Stenting or surgery for de novo common femoral artery stenosis. *J Am Coll Cardiol Interv*. 2017;10:1344-1354.
  15. Kechagias A, Ylönen K, Biancari F. Long-term outcome after isolated endarterectomy of the femoral bifurcation. *World J Surg*. 2008;32:51-54.
  16. Springhorn ME, Kinney M, Littooy FN, Saletta C, Greisler HP. Inflow atherosclerotic disease localized to the common femoral artery: treatment and outcome. *Ann Vasc Surg*. 1991 May;5(3):234-240.
  17. Halpin D, Erben Y, Jayasuriya S, Cua B, Jhamnani S, Mena-Hurtado C. Management of isolated atherosclerotic stenosis of the common femoral artery: a review of the literature. *Vasc Endovascular Surg*. 2017 May;51(4):220-227. doi: 10.1177/1538574417702773.
  18. Soga Y, Tomoi Y, Sato K, Iida O, Yokoi H. Clinical outcome after endovascular treatment for isolated common femoral and popliteal artery disease. *Cardiovasc Interv Ther*. 2013 Jul;28(3):250-257. doi: 10.1007/s12928-013-0164-1.
  19. Tepe G, Schnorr B, Albrecht T, et al. Angioplasty of femoropopliteal arteries with drug-coated balloons: 5-year follow-up of the THUNDER trial. *J Am Coll Cardiol Interv*. 2015 Jan;8(1 pt A):102-108. doi: 10.1016/j.jcin.2014.07.023
  20. Tepe G, Laird J, Schneider P, et al; IN.PACT SFA Trial Investigators. Drug-coated balloon versus standard percutaneous transluminal angioplasty for the treatment of superficial femoral and popliteal peripheral artery disease: 12-month results from the IN.PACT SFA randomized trial. *Circulation*. 2015;131(5):495-502.
  21. Marmagkiolis K, Hakeem A, Choksi N, et al. 12-month primary patency rates of contemporary endovascular device therapy for femoro-popliteal occlusive disease in 6,024 patients: beyond balloon angioplasty. *Catheter Cardiovasc Interv*. 2014;84(4): 555-556.
  22. McKinsey JF, Zeller T, Rocha-Singh KJ, Jaff MR, Garcia LA; DEFINITIVE LE Investigators. Lower extremity revascularization using directional atherectomy: 12-month prospective results of the DEFINITIVE LE study. *JACC Cardiovasc Interv*. 2014 Aug;7(8):923-933. doi: 10.1016/j.jcin.2014.05.006.
  23. Zeller T, Langhoff R, Rocha-Singh KJ, et al. Directional atherectomy followed by a paclitaxel-coated balloon to inhibit restenosis and maintain vessel patency: twelve-month results of the DEFINITIVE AR study. *Circ Cardiovasc Interv*. 2017;10(9):e004848. doi:10.1161/CIRCINTERVENTIONS.116.004848
  24. Brodmann M, Werner M, Britton T. Safety and performance of lithoplasty for treatment of calcified peripheral artery lesions. *J Am Coll Cardiol*. 2017;70:908-909.
  25. Brodmann M, Werner M, Brinton TJ, et al. Safety and performance of lithoplasty for treatment of calcified peripheral artery lesions. *J Am Coll Cardiol*. 2017 Aug 15;70(7):908-910. doi: 10.1016/j.jacc.2017.06.022
  26. Brinton TJ, Ali ZA, Hill JM, et al. Feasibility of Shockwave coronary intravascular lithotripsy for the treatment of calcified coronary stenoses. *Circulation*. 2019 Feb 5;139(6):834-836. doi: 10.1161/CIRCULATIONAHA.118.036531.
  27. Jurado-Román A, González A, Galeote G, et al. RotaTripsy: combination of rotational atherectomy and intravascular lithotripsy for the treatment of severely calcified lesions. *JACC Cardiovasc Interv*. 2019;12:e127-e129.