

Pulmonary embolism: Successful treatment of floating thrombus in SFJ after vena cava filter insertion and surgical thrombectomy

JRSM Cardiovascular Disease

Volume 9: 1–4

© The Author(s) 2020

Article reuse guidelines:

sagepub.com/journals-permissions

DOI: 10.1177/2048004020976256

journals.sagepub.com/home/cvd

Andrea Ascoli Marchetti , Bernardo Orellana Davila ,
Fabio Massimo Oddi  and Arnaldo Ippoliti

Abstract

The floating venous thrombus in the common femoral vein has a high potential risk for pulmonary embolization. Clinical treatments, using anticoagulants or fibrinolytic, open thrombectomies, or thrombectomies by endovascular devices have all been used. Our case describe an obese patient affected by floating thrombus coming from GSV and diving in common femoral vein successful treated by combined both temporary vena cava insertion and open surgical thrombectomy.

Keywords

Surgical thrombectomy, pulmonary embolism, venous thrombus, inferior vena cava, pulmonary embolism prophylaxis, pulmonary embolization, intercept thrombus, thrombus growth

Date received: 17 September 2020; Revised 3 November 2020; accepted: 4 November 2020

The surgical approach seems to be safer in experienced center. Filter insertion may be useful to avoid the thrombus dislodgment.

Introduction

A floating venous thrombus in the femoral vein has a high potential risk for pulmonary embolization (PE).¹ Clinical treatments, using anticoagulants or fibrinolytic, open thrombectomies, or thrombectomies by endovascular devices have all been used. Although the criteria for the indication of each are not always yet well defined. The most appropriate management for these pathologies is still controversial.

Case report

A 54 years old female patient with history of right leg thrombophlebitis presents to the hospital with dyspnoea, and chest discomfort. She was 156 cm tall and the weight was 95 kg. with BMI 39.04 (Obese class II) and had a history of hypertension, subclinical

hypothyroidism and a previous DVT episode, involving the left lower limb several years before at the third trimester of her pregnancy, treated with rest, enoxaparin sc, and aspirin per os. One year later she underwent on left saphenectomy.

The patient presented to her family clinician, complaining of edema and pain to the right leg, accentuated along the saphenous vein after she suffered a middle trauma at home. Her physician started analgesics, antibiotics and antithrombotic therapy per os for 7 days (Amoxicillina-acido clavulanico 875 + 125 mg and Mesoglycan). After a few minutes, the patient noticed rash and pruritus to the hands and she went to the nearest emergency department where previous

Vascular Surgery Unit, Biomedicine and Prevention Department, University of Rome, Rome, Italy

Corresponding author:

Andrea Ascoli Marchetti, Vascular Surgery Unit, Biomedicine and Prevention Department, Viale Oxford 81, 00133 Rome, Italy.
Email: ascalimarchetti@med.uniroma2.it



treatment was stopped and initiated Betametasone 4 mg/day ev in a single administration.

Twenty four hours later, the patient went on a 2 hours flight, at the moment of landing she felt weak, dizziness and endorsed an acute pain to the right thigh. At the emergency room, she is diagnosed a superficial vein thrombosis with DUS. The patient decided to go home and went to the ER of the local hospital where she was started on ambulatory treatment with ciprofloxacin and enoxaparin. The patient comes to our emergency department complaining of agitation, dyspnea and chest discomfort with minimal efforts (walking, standing up), she underwent DUS and Computed Tomography (CT). The presence of a thrombus with the free distal end in the venous lumen was highlighted and the clinical suspicion of Pulmonary Embolism (PE) was confirmed.

On physical examination, peripheral pulses were palpable. A venous DUS conducted to investigate the emboligenic source, revealed an incompressible right great saphenous vein, with no blood flow and echogenic content (thrombus) in the lumen. The thrombus extended from the mid-leg to the saphenous-femoral junction, where it “extended” into the lumen of the common femoral vein and appeared to be floating. The diagnostic conclusions of the examination were ascending thrombophlebitis of the great saphenous vein and floating thrombus of the common femoral vein, both in the right lower limb (Figure 1). An urgent intervention was planned and informed consensus was obtained. A temporary vena cava filter was inserted (Celect®, Cook Company) (Figure 2) and the patient was conducted in operating room. Under local anesthesia with mepivacaina 2% and vessel exposure, a systemic heparinization with 5000 UI was done and longitudinal phlebotomy was performed onto the confluence saphena vein. The diving floating thrombus in the femoral vein was confirmed (Figure 3). The patient made a cough at the time of clamping to tighten the central venous pressure and surgical thrombectomy and ligation of the GSV was performed without local or systemic complications. Patient was discharged in good health and anticoagulation therapy. The remove of the IVC filter was made 1 month later without complications.

Discussion

The reported PE 1-year mortality is as high as 23.8% among patients with symptomatic pulmonary thromboembolism (PTE), and 22% of deaths are reported to occur within 2 weeks from the onset². Mortality among patients with recurrent PTE is particularly high.³

Anticoagulant therapy is the gold standard for the treatment of PTE,⁴ nonetheless, reports have indicated

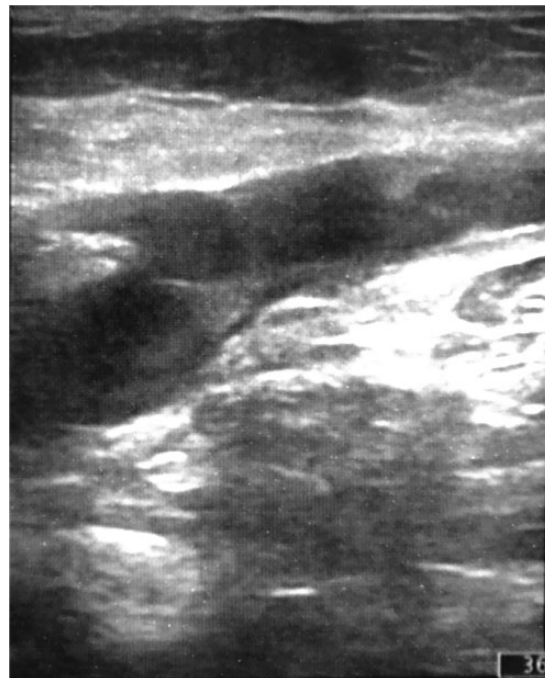

Figure 1. DUS examination of the right lower limb revealed an incompressible great saphenous vein, with no blood flow and with echogenic content (thrombus) in the lumen.

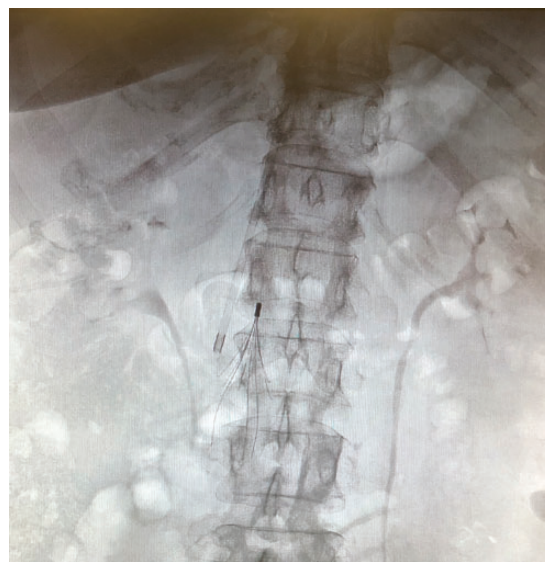

Figure 2. Inferior Vena Cava Filter before surgical thrombectomy.

that despite the use of anticoagulant therapy during the acute stage, PE recurs at a rate of 4,0% to 4,8%.⁵ Acute PET was reported to occur within 7 days in 0,5% of patients with deep vein thrombosis (DVT), even though anticoagulant therapy is given 3,5% of patients with DVT complicated by asymptomatic

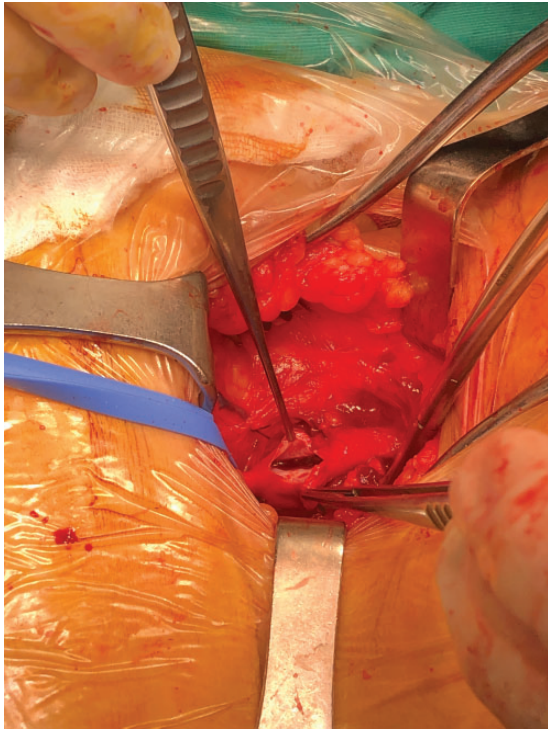


Figure 3. Intraoperative image. Floating thrombus diving into the sapheno-femoral junction.

PTE developed symptomatic PTE. Thus, anticoagulant therapy alone does not adequately prevent PTE.⁵ However, there is no unanimous consensus on the use of surgery alone in the saphenous femoral junction area, in these cases.

Because acute-phase recurrence is known to be associated with extremely high mortality,⁶ considerable effort is needed to lower the recurrence rate and new devices are proposed to treat the thrombosis. The risk of recurrence (DVT and PE) is greatest in the first two weeks and declines thereafter. The cumulative proportion of patients with early recurrence while on anticoagulant therapy can reach up to 2% at two weeks, and 6% at three months.^(7,8)

Patients with PE and a coexisting deep vein thrombosis (DVT) are at increased risk for death. As an example, one prospective study of 707 patients with PE reported increased all-cause mortality (adjusted hazard ratio [HR] 2.05, 95% CI 1.24–3.38) and PE-specific mortality (adjusted HR 4.25, 95% CI 1.61–11.25) at three months in patients with concomitant DVT compared with those without concomitant DVT.⁹

There are no specific treatment guidelines for venous thrombosis with floating thrombi, that extend into the femoral vein. Anticoagulant treatment appears to be an effective and less invasive option, and surgery is rarely associated. In cases with more extensive floating

thrombi, involving iliac veins or even the vena cava, using a temporary inferior vena cava filter could be evaluated, because of the high risk of PE,¹⁰ especially in view of surgical manipulation. In more recent experience, a note of caution against the filter use arose from guidelines with 1B evidence, but no mention of floating thrombus is reported.¹¹

Temporary filter contribute to reduce the PTE recurrence rate. It is also often considered as an adjunctive therapy in patients with recurrent embolism despite adequate anticoagulation, as well as in patients in whom an additional embolic event would be poorly tolerated (ex, those with poor cardiopulmonary reserve from massive PE underlying cardiopulmonary disease, hemodynamically unstable patients, obese patients) as in our case.¹²

It has the potential to eliminate the lysis time and reduce the risk hemorrhagic in case of use of thrombolytic agents, and potentially impact cost savings. The surgical treatment has 3 objectives: 1. Avoid the thrombus progression from the superficial to the deep vein system, 2. to treat the cause of the superficial vein insufficiency and 3. To prevent a recurrent SVT. The prevention of dislodgment of the thrombus was assure by filter insertion and definitive surgical measure associated to GSV ligation are the objectives that has been achieved.

Conclusions

The floating thrombus in the saphenous-femoral junction is a complex and challenging condition. It is important to recognize this entity because of the high risk of development of PE and recurrence. Nonetheless, being conscious that the reference standard for these cases is anticoagulant treatment, it may not be enough to prevent future PE, mostly in patients with poor cardiopulmonary reserve like an obese patient. At this point, surgical treatment is a viable option to close the thrombotic vein, avoid future PE, and save time and costs. Before performing the surgical treatment, may be important to insert an IVC filter to limit the high risk of detachment of the thrombus that could cause a PE.

Acknowledgements

None.

Availability of data and materials

The data supporting their findings can be found in the electronic archive of our hospital and are available on request.

Declaration of conflicting interests

The author(s) declared no potential conflicts of interest with respect to the research, authorship, and/or publication of this article.

Funding

The author(s) received no financial support for the research, authorship, and/or publication of this article.

Ethical approval

The ethical approval in our institution is not required for case report because the analysis undertakes used data collected for a clinical care. The patient has given written consent to the publication of the data anonymously. A copy of the consent is available in electronic medical record at the request of the publisher.

Guarantor

Arnaldo Ippoliti and Andrea Ascoli Marchetti.

Contributorship

AAM participated in the conception and design, operations, analysis and interpretation and drafted the manuscript. BOD participated in design, operations, drafted the manuscript. FMO participated in the design, operations, analysis and interpretation and drafted the manuscript. All authors participated in the conception, design interpretation and drafted the manuscript. All authors participated in critical revision and gave final approval.

ORCID iDs

Andrea Ascoli Marchetti  <https://orcid.org/0000-0001-9229-0495>

Bernardo Orellana Davila  <https://orcid.org/0000-0003-2399-8646>

Fabio Massimo Oddi  <https://orcid.org/0000-0001-8081-807X>

References

- Casian D, Gutsu E and Culiuc V. Extraluminal venous interruption for free-floating thrombus in the deep veins of lower limbs. *Chirurgia (Bucur)* 2010; 105: 361–364.
- The PIOPED Investigators. Value of the ventilation/perfusion scan in acute pulmonary embolism. Results of the prospective investigation of pulmonary embolism diagnosis PIOPED. *JAMA* 1990; 263: 2753–2759.
- Nakamura M, Fujioka H, Yamada N, et al. Clinical characteristics of acute pulmonary thromboembolism in Japan: results of a multicenter registry in the Japanese society of pulmonary embolism research. *Clin Cardiol* 2001; 24: 132–138.
- Howard L S G E, Barden S, Condliffe R, et al. British Thoracic Society Guideline for the Initial Outpatient Management of Pulmonary Embolism (PE). *Thorax* 2018; 73: ii1–ii29. DOI: 10.1136/thoraxjnl-2018-211539.
- Decousus H, Leizorovicz A, Parent F, et al. A clinical trial of vena caval filters in the prevention of pulmonary embolism in patients with proximal deep-vein thrombosis. *N Engl J Med* 1998; 338: 409–415.
- Douketis JD, Kearon C, Bates S, et al. Risk of fatal pulmonary embolism in patients with treated venous thromboembolism. *JAMA* 1998; 279: 458–462.
- Kyrle PA, Rosendaal FR and Eichinger S. Risk assessment for recurrent venous thrombosis. *Lancet* 2010; 376: 2032–2039.
- Heit JA. Predicting the risk of venous thromboembolism recurrence. *Am J Hematol* 2012; 87 Suppl 1: S63–S67.
- Jiménez D, Aujesky D, Diaz G, et al. Prognostic significance of deep vein thrombosis in patients presenting with acute symptomatic pulmonary embolism. *Am J Respir Crit Care Med* 2010; 181: 983–991.
- Kearon C, Akl EA, Ornelas J, et al. Antithrombotic therapy for VTE disease. *Chest* 2016; 149: 315–352.
- Bertanha M, Pimenta REF, Brandão GMS, et al. Trombo flutuante em veia femoral. *J Vasc Bras* 2017; 16: 314–319.
- Lip G YH, Hull R D. Overview of the treatment of lower extremity deep vein thrombosis (DVT), www.uptodate.com/contents/overview-of-the-treatment-of-lower-extremity-deep-vein-thrombosis-dvt (2019, accessed 10 November 2020).