

University of Groningen

## Postoperative skeletal stability at the one-year follow-up after splintless Le Fort I osteotomy using patient-specific osteosynthesis versus conventional osteosynthesis

van der Wel, H.; Kraeima, J.; Spijkervet, F. K.L.; Schepers, R. H.; Jansma, J.

*Published in:*  
International Journal of Oral and Maxillofacial Surgery

*DOI:*  
[10.1016/j.ijom.2022.09.005](https://doi.org/10.1016/j.ijom.2022.09.005)

**IMPORTANT NOTE: You are advised to consult the publisher's version (publisher's PDF) if you wish to cite from it. Please check the document version below.**

*Document Version*  
Version created as part of publication process; publisher's layout; not normally made publicly available

*Publication date:*  
2022

[Link to publication in University of Groningen/UMCG research database](#)

*Citation for published version (APA):*  
van der Wel, H., Kraeima, J., Spijkervet, F. K. L., Schepers, R. H., & Jansma, J. (Accepted/In press). Postoperative skeletal stability at the one-year follow-up after splintless Le Fort I osteotomy using patient-specific osteosynthesis versus conventional osteosynthesis: a randomized controlled trial. *International Journal of Oral and Maxillofacial Surgery*, 1-7. <https://doi.org/10.1016/j.ijom.2022.09.005>

### Copyright

Other than for strictly personal use, it is not permitted to download or to forward/distribute the text or part of it without the consent of the author(s) and/or copyright holder(s), unless the work is under an open content license (like Creative Commons).

The publication may also be distributed here under the terms of Article 25fa of the Dutch Copyright Act, indicated by the "Taverne" license. More information can be found on the University of Groningen website: <https://www.rug.nl/library/open-access/self-archiving-pure/taverne-amendment>.

### Take-down policy

If you believe that this document breaches copyright please contact us providing details, and we will remove access to the work immediately and investigate your claim.

Downloaded from the University of Groningen/UMCG research database (Pure): <http://www.rug.nl/research/portal>. For technical reasons the number of authors shown on this cover page is limited to 10 maximum.

## Randomised Controlled Trial Orthognathic Surgery

# Postoperative skeletal stability at the one-year follow-up after splintless Le Fort I osteotomy using patient-specific osteosynthesis versus conventional osteosynthesis: a randomized controlled trial

H. van der Wel<sup>a</sup>, J. Kraeima<sup>a</sup>,  
F.K.L. Spijkervet<sup>a</sup>, R.H. Schepers<sup>a,b</sup>,  
J. Jansma<sup>a,b</sup>

<sup>a</sup>Department of Oral and Maxillofacial Surgery, University of Groningen, University Medical Centre Groningen, Groningen, the Netherlands; <sup>b</sup>Department of Oral and Maxillofacial Surgery, Martini Hospital Groningen, Groningen, the Netherlands

H. van der Wel, J. Kraeima, F. K.L. Spijkervet, R. H. Schepers, J. Jansma:  
*Postoperative skeletal stability at the one-year follow-up after splintless Le Fort I osteotomy using patient-specific osteosynthesis versus conventional osteosynthesis: a randomized controlled trial. Int. J. Oral Maxillofac. Surg. 2021; xx: 1–7.*  
© 2022 The Authors. Published by Elsevier Inc. on behalf of International Association of Oral and Maxillofacial Surgeons. This is an open access article under the CC BY license (<http://creativecommons.org/licenses/by/4.0/>).

**Abstract.** The purpose of this study was to assess the 1-year skeletal stability of the osteotomized maxilla after Le Fort I surgery, comparing conventional osteosynthesis with patient-specific osteosynthesis. Patients were assigned to a conventional or patient-specific osteosynthesis group using prospective randomization. The primary outcome was the three-dimensional change in postoperative skeletal position of the maxilla between the 2-week and 1-year follow-up cone beam computed tomography scans. Fifty-eight patients completed the protocol for the 2-week postoperative analysis, and 27 patients completed the 1-year follow-up study protocol. Of the 27 patients completing the entire protocol, 13 were in the conventional group and 14 in the patient-specific osteosynthesis group. The three-dimensional translation analysis showed that the use of the patient-specific osteosynthesis resulted in a skeletally stable result, comparable to that of conventional miniplate fixation. For both the patient-specific osteosynthesis and conventional miniplate fixation groups, median translations of less than 1 mm and median rotations of less than 1° were observed, indicating that both methods of fixation resulted in a stable result for the 27 patients examined. For the Le Fort I osteotomy, the choice between

**Keywords:** Orthognathic surgery; Le Fort osteotomy; CAD/CAM; Follow-up study; Randomized controlled trial.

Accepted for publication 12 September 2022  
Available online xxxx

patient-specific osteosynthesis and conventional osteosynthesis did not affect the postoperative skeletal stability after 1 year of follow-up.

Preoperative virtual surgical planning (VSP) has become an important tool in orthognathic surgery. High-resolution cone beam computed tomography (CBCT) and dental scans obtained during the work-up allow improved accuracy of planning and simulation of the result. In the search for accurate translation of the VSP to the surgical result, a splintless procedure using patient-specific osteosynthesis (PSO) for Le Fort I osteotomies has recently been introduced at the authors' centre.<sup>1-3</sup> PSO has proven to be valuable in terms of improving the accuracy of maxillary placement during surgery, especially for larger (> 3.7 mm) translations.<sup>3</sup>

In addition to the initial surgical accuracy, the postoperative stability of the result should be considered when evaluating the accuracy of orthognathic surgery. For the Le Fort I osteotomy, relapse rates are considerably high, with a clinically significant (> 2 mm) amount of horizontal relapse reported to occur in 14% of patients.<sup>4</sup>

Since the introduction of Le Fort I surgery, developments aimed at improving the stability by improving the fixation method have been reported.<sup>5-8</sup> Patient-specific osteosynthesis (PSO) plates are designed to follow the anatomical contour of the maxilla without the need for intraoperative bending, ideally resulting in a passive and tension-free fitting.<sup>9</sup> In contrast, the miniplates that are conventionally used have to be bendable during surgery to achieve a proper, passive and tension-free fitting. The rigidity of the PSO plates might influence the postoperative stability, as has been indicated in two previous studies, where it was shown that PSO provided enough stability for application at the nasomaxillary buttresses only without posterior fixation,<sup>8</sup> or using only wire fixation for posterior fixation.<sup>10</sup>

Besides the publications mentioned above, there have only been a few other studies on skeletal stability after the application of PSO. One study that directly compared the stability after PSO and conventional osteosynthesis was found, which concluded that the two methods resulted in equally stable results.<sup>9</sup> Overall, the current literature seems to indicate that PSO results in a

stable fixation, comparable to that of conventional miniplate osteosynthesis, albeit with scarce evidence. Studies lack objective analysis on accuracy and the amount of relapse measured in three dimensions. As recommended by previous authors, research using a three-dimensional (3D) image fusion analysis instead of two-dimensional (2D) radiography tracings is necessary.<sup>9</sup> The aim of this study was to compare the skeletal stability of the maxilla at 1 year after Le Fort I osteotomy performed using either PSO or conventional osteosynthesis, based on 3D image fusion analysis, in a randomized controlled trial (RCT).

## Materials and methods

### Study population

The population of this multicentre RCT consisted of patients treated at the University Medical Centre Groningen and Martini Hospital Groningen between August 2015 and October 2018. The trial was approved by the local medical ethics board (Medical Ethics Review Committee, University Medical Centre Groningen; File Number METc 2015/084). The short-term results (maxillary placement accuracy at 2 weeks postoperative) have been reported previously by Kraeima et al.<sup>3</sup> The study was performed according to the CONSORT guidelines (<http://www.consort-statement.org/>).

Inclusion criteria for this study were (1) patient due to receive a Le Fort I osteotomy, with or without simultaneous mandibular osteotomy, (2) patient able to complete the routine 3D VSP work-up, and (3) patient age at least 18 years. Patient exclusion criteria were (1) patient did not agree to participate in the trial, (2) patient was unable to undergo the 3D virtual planning procedure for any reason, (3) pregnancy, and (4) patient had a known allergy to titanium.

The included patients were divided into two groups by means of block randomization: (1) a conventional osteosynthesis group of patients (control group), in whom a 3D computer-aided design and manufacturing (CAD/CAM) surgical splint and miniplate

fixation were used; and (2) a patient-specific osteosynthesis group of patients (PSO group), in whom 3D-printed drilling/osteotomy guides were used to indicate the osteotomy line and drilling location, and fixation was performed using four 3D milled titanium PSO plates, as described by Kraeima et al.<sup>11</sup>

### 3D planning and intervention

Prior to surgery, a 3D VSP was made for every patient using Maxilim v2.3 (Medicim, Mechelen, Belgium) according to the triple scan protocol described by Swennen et al.<sup>12</sup> The design of the PSO, drilling/osteotomy guides, and surgical splints was based on this 3D VSP. For the conventional group, the LevelOne Orthognathics 1.5 miniplate system by KLS Martin (KLS Martin Group, Tuttlingen, Germany) was used. For the PSO group, 3D milled medical grade titanium osteosynthesis designed and fabricated by Createch Medical (Createch Medical SL, Mendaro, Spain) was used. In both cases, the same type and length of screws were used (LevelOne 1.5 system, KLS Martin Group).

For all patients, the surgery included a conventional Le Fort I approach with an upper vestibular incision exposing the maxillary bone. The maxilla was mobilized and guided to the new position using either the surgical splint (conventional group) or the PSO (PSO group). A schematic overview of the procedure used to position the maxilla in the PSO group is provided in Fig. 1, including the 3D VSP (Fig. 1A, B), the guide placement and drilling (Fig. 1C), and the PSO placement (Fig. 1D). For bimaxillary osteotomies, the mandible was repositioned using a conventional bilateral sagittal split osteotomy (BSSO) and guidance with the final 3D surgical splint. The maxilla-first sequence was used for all bimaxillary cases.

### Analysis of postoperative skeletal stability

The patients underwent two postoperative CBCT scans as part of the routine follow-up protocol: one at the first postoperative follow-up consultation (range 9–16 days) and the other at 1 year

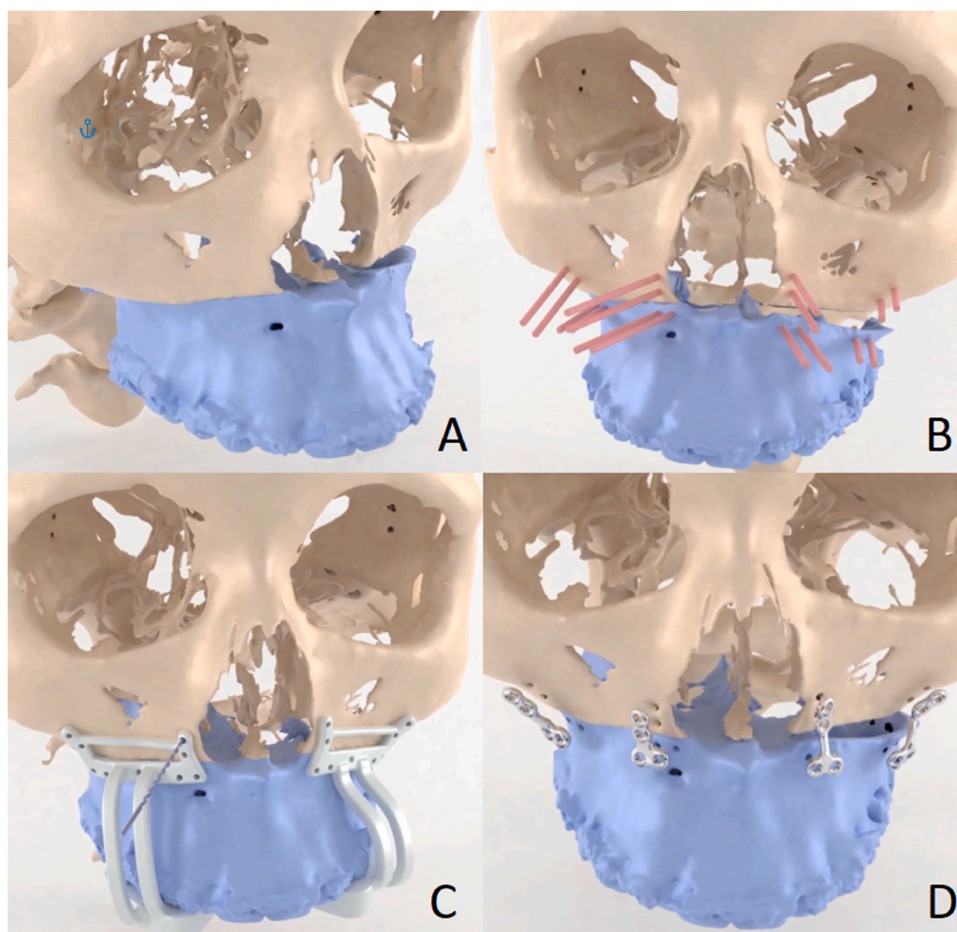


Fig. 1. Schematic overview of the 3D VSP PSO workflow. (A) 3D VSP for maxillary translation/rotation. (B) Screw position planning (screws shown in red). (C) Drilling and indication of the osteotomy line using surgical drill guides. (D) Positioning and fixation of the maxillary segment using the PSO. (3D, three-dimensional; VSP, virtual surgical planning; PSO, patient-specific osteosynthesis.).

(range 10–15 months) after surgery. 3D virtual head models were made for both scans and registered to the 3D VSP in Maxilim using voxel-based matching.<sup>13</sup> The anterior cranial base was used as the region of interest for the matching. After the bone-based matching, three landmarks on the dentition were used to quantify the movement of the maxilla: the most mesial point of the incisor edge of the right upper central incisor (UI) and the most inferior points of the mesial cusps of the crown of the right first upper molar (#16) and left first upper molar (#26).<sup>14</sup> The landmarks chosen are on the dentition, but the registration process only includes the maxilla and not the dentition. Because the points are simply moved along in a rigid manner without considering the changes in dental position, postoperative orthodontics or other changes in dental position do not influence the measurement. Fig. 2 presents an overview of the alignment of the 2-week and 1-year postoperative data.

The virtually osteotomized maxilla was translated from its preoperative position to the 2-week and 1-year postoperative positions using voxel-based matching, rigidly moving the three landmarks along. For the preoperative VSP, 2-week postoperative, and 1-year postoperative 3D head models, the coordinates of the three maxilla landmarks were exported to compare the 2-week and 1-year postoperative positions (see Fig. 3). Translations and rotations were assessed in relation to the Frankfort horizontal plane, the CBCT coronal plane, and the CBCT sagittal plane. Using the UI landmark, the translations in anterior/posterior, cranial/caudal, and left/right directions between the scans were calculated. By examining the rotation of the triangle formed by the #16, UI, and #26 landmarks, the rotation (roll, pitch, and yaw) of the osteotomized maxilla around the UI point was calculated.

### Statistical analysis

The Mann–Whitney *U*-test was performed to test for significant differences, using IBM SPSS Statistics version 23 (IBM Corp., Armonk, NY, USA). Values of  $P < 0.05$  were considered statistically significant. The inter-observer variation was determined for a randomly selected sample group ( $n=6$ ) analysed by a second observer (J.K.), for both the 2-week and 1-year postoperative measurements.

### Results

#### Inclusion

A total of 64 patients provided informed consent to participate in the RCT. Fifty-eight patients completed the protocol for the 2-week postoperative analysis, but unfortunately only 27 patients completed the 1-year

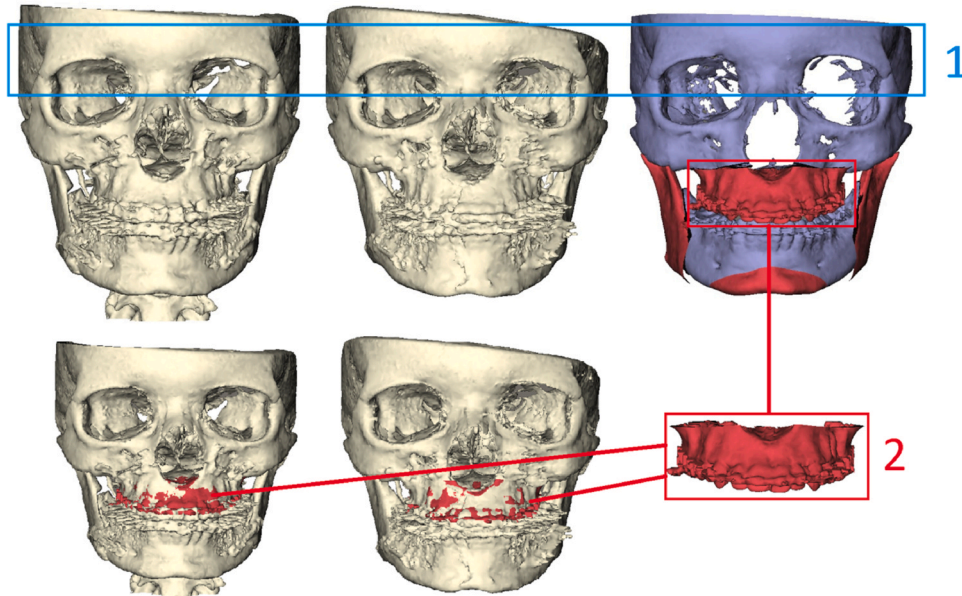


Fig. 2. Quantification of maxilla movement: (1) alignment of the 2-week and 1-year postoperative CBCT scans with the planning, based on the anterior skull region of interest; (2) alignment of the osteotomized maxilla with the 2-week and 1-year postoperative CBCT.

follow-up study protocol. Reasons for drop-out between the 2-week and 1-year protocol were as follows: no CBCT dataset available due to 'no-show' of the patient ( $n = 25$ ) or CBCT scan was performed outside the follow-up period ( $n = 6$ ).

Of the 27 patients who completed the follow-up protocol, 13 were treated with conventional osteosynthesis (control group) and 14 patients with PSO (PSO group). Except for two patients in the PSO group, all patients underwent a bimaxillary procedure, combining the Le Fort I procedure with a BSSO. The demographics and 2-week postoperative 3D results of the included patients are presented in Table 1. There was no significant difference in the 2-week postoperative 3D results between the two groups.

#### Inter-observer variability

Regarding the 2-week postoperative measurements, the intra-class correlation coefficient (ICC) for all measurements of the randomly selected six cases was 0.98, with a median error of 0.20 mm (interquartile range (IQR) 0.09–0.80 mm). Regarding the 1-year postoperative measurements, the ICC for all measurements was 0.97, with a median error of 0.23 mm (IQR 0.11–0.71 mm).

#### 1. -year skeletal stability results

The 1-year skeletal stability results are presented in Tables 2 and 3. No significant difference in relapse at 1 year was found between the control group and PSO group for translation in any

direction when the results in each group were compared to the 2-week postoperative 3D position of the maxilla. The median relapse observed was below 1 mm in both the control group and PSO group. Considering the rotational stability, a significant difference was found for the absolute rotational stability around the yaw axis, where relapse was smaller in the control group than in the PSO group ( $P < 0.01$ ).

#### Discussion

In this prospective multicentre RCT, the 1-year follow-up skeletal stability of the maxilla after Le Fort I osteotomy was compared between PSO and conventional miniplate fixation groups. The 3D translation analysis showed that the use

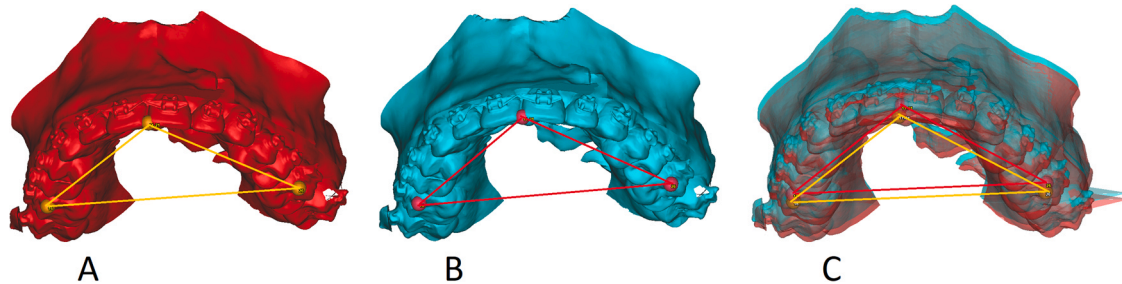


Fig. 3. Detailed view of the method used to quantify the maxilla movement. After registration of the osteotomized maxilla, the position of the triangle formed by three landmarks was exported from the 2-week position (A) and 1-year position (B), in order to calculate the translation and rotation between them (C).

Table 1. Patient characteristics. The Mann–Whitney *U*-test was performed, and it was determined that there was no significant difference in the 2-week 3D results between the two groups.

Patient characteristics				
Characteristics	Control	PSO		
Number of patients	13	14		
Sex, <i>n</i>				
Female	9	5		
Male	4	9		
Age (years), mean $\pm$ SD	26.8 $\pm$ 6.9	28.6 $\pm$ 9.7		
Number of bimaxillary	13	12		
Planned translation of UI			2-week results (mm)	
Direction	Control, <i>n</i> patients	PSO, <i>n</i> patients	Control	PSO
			Median (IQR)	Median (IQR)
Cranial	7	4	0.9 (0.2, 5.4)	2.1 (0.6, 6.5)
Caudal	6	10	2.0 (1.0, 3.0)	2.1 (1.2, 3.2)
Anterior	13	14	2.8 (1.2, 4.5)	3.8 (2.3, 4.3)
Left	6	8	1.2 (0.9, 1.6)	0.5 (0.2, 1.7)
Right	7	6	0.9 (0.9, 1.3)	0.9 (0.3, 1.8)
Planned rotation of maxilla			2-week results ( $^{\circ}$ )	
Direction	Control, <i>n</i> patients	PSO, <i>n</i> patients	Control	PSO
Pitch CW	7	7	1.8 (0.0, 3.6)	2.6 (1.7, 3.3)
Pitch CCW	6	7	1.9 (0.2, 7.3)	2.9 (0.5, 5.7)
Roll CW	3	8	1.6 (0.9, 1.6)	1.2 (0.2, 2.6)
Roll CCW	10	6	0.6 (0.2, 1.9)	0.7 (0.4, 2.0)
Yaw CW	6	7	0.9 (0.3, 1.2)	0.2 (0.2, 0.6)
Yaw CCW	7	7	0.6 (0.0, 1.3)	0.2 (0.0, 1.8)

3D, three-dimensional; CCW, counterclockwise; CW, clockwise; IQR, interquartile range (Q1, Q3); PSO, patient-specific osteosynthesis; SD, standard deviation; UI, upper central incisor.

of PSO did not result in a significant difference in 1-year skeletal stability compared to the conventional miniplate osteosynthesis approach. 3D rotation analysis showed that the rotational stability was comparable in the PSO and conventional osteosynthesis groups, with the exception of rotation around the yaw axis, where the PSO fixation seemed less stable. For both the PSO and conventional miniplate fixation groups, median relapse translations were less than 1 mm and median rotations were less than  $1^{\circ}$ , indicating that both methods of fixation gave stable results for the 27 patients examined.

Assessing the stability along the three primary axes without subdivision in direction of movement, the translations in all directions were comparably stable in the two groups. These results confirm the conclusions of Kotaniemi et al.,<sup>9</sup> who previously compared PSO fixation with conventional osteosynthesis. A 3D fusion analysis method was used in the current study, in contrast to the 2D methods used by Kotaniemi et al. and in other previous PSO relapse studies.<sup>8–10</sup> Comparison of the current results with those in the previous literature is therefore only indicative of the fact that the results are in the same range.

The rotational stability in this study was found to be comparable for pitch and roll, but significantly higher for the conventional osteosynthesis group for rotations around the yaw axis. Subgrouping the initial correction of the rotation into either clockwise or counterclockwise groups did not give a significant difference in either group. Although significant, the higher stability for rotation along the yaw axis in the conventional group, in absolute values, is only slightly more stable ( $0.0^{\circ}$  vs  $0.2^{\circ}$ ). Considering a value of relapse larger than  $1^{\circ}$  as the cut-off point for a stable result, both the PSO and

Table 2. Absolute movement between 2 weeks and 1 year, and median directional movement between 2 weeks and 1 year; the median and interquartile range (Q1, Q3) are reported.

Translation of UI (mm)	Absolute difference 1-year		Directional difference				
	Control	PSO	Control	Direction	PSO	Direction	Sig.
Cranial	0.4 (0.3, 0.8)	0.2 (0.0, 0.4)	0.3 (–0.4, 0.6)	Cranial	0.2 (0.0, 0.4)	Caudal	> 0.05
Caudal	0.2 (0.0, 0.5)	0.7 (0.2, 1.3)	0.0 (–0.2, 0.4)		0.7 (0.1, 1.3)	Cranial	> 0.05
Anterior	0.2 (0.2, 0.4)	0.5 (0.2, 0.8)	0.1 (–0.2, 0.3)	Posterior	0.1 (–0.2, 0.6)	Posterior	> 0.05
Left	0.2 (0.1, 0.4)	0.3 (0.2, 0.4)	0.0 (–0.2, 0.3)		0.1 (–0.3, 0.3)	Left	> 0.05
Right	0.2 (0.1, 0.2)	0.5 (0.2, 1.3)	0.2 (0.1, 0.2)	Left	0.4 (–0.3, 1.3)	Left	> 0.05
Rotation of maxilla ( $^{\circ}$ )	Absolute difference 1-year		Directional difference				
Direction	Control	PSO	Control	Direction	PSO	Direction	Sig.
Pitch CW	0.0 (0.0, 0.1)	0.1 (0.0, 0.3)	0.0 (0.0, 0.1)	CW	0.0 (–0.1, 0.2)	CCW	> 0.05
Pitch CCW	0.0 (0.0, 0.7)	0.1 (0.0, 1.0)	0.0 (–0.2, 0.2)		0.0 (–0.7, 0.1)		> 0.05
Roll CW	0.2 (0.1, 0.2)	0.7 (0.2, 1.5)	0.2 (0.1, 0.2)	CCW	0.3 (–0.5, 1.5)	CCW	> 0.05
Roll CCW	0.2 (0.0, 0.6)	0.2 (0.1, 0.9)	0.1 (0.0, 0.6)	CCW	0.1 (–0.2, 0.5)	CCW	> 0.05
Yaw CW	0.1 (0.0, 0.2)	0.2 (0.2, 0.8)	0.0 (–0.1, 0.1)		0.2 (–0.2, 0.8)	CW	> 0.05
Yaw CCW	0.0 (0.0, 0.1)	0.1 (0.1, 0.6)	0.0 (0.0, 0.1)		0.1 (–0.1, 0.6)	CW	> 0.05

CCW, counterclockwise; CW, clockwise; PSO, patient-specific osteosynthesis; UI, upper central incisor.

**Table 3.** Translations and rotations in the two study groups, along the cranial/caudal, anterior/posterior, left/right axis directions, and pitch, roll, and yaw dimensions; the median and interquartile range (Q1, Q3) are reported. A significant difference in absolute yaw was found between the control and PSO groups.

Translation of UI (mm)			2-week result		Absolute difference at 1 year		Sig.
Direction	Control	PSO	Control	PSO	Control	PSO	
Cranial/caudal	13	14	1.5 (0.6, 4.5)	2.1 (0.9, 3.5)	0.3 (0.2, 0.7)	0.3 (0.1, 1.3)	> 0.05
Anterior/posterior	13	14	2.8 (1.2, 4.5)	3.8 (2.3, 4.3)	0.2 (0.2, 0.4)	0.5 (0.2, 0.8)	> 0.05
Left/right	13	14	1.2 (0.9, 1.4)	0.5 (0.3, 1.7)	0.2 (0.1, 0.3)	0.3 (0.2, 0.6)	> 0.05
Rotation of maxilla (°)			2-week result		Absolute difference at 1 year		
Direction	Control	PSO	Control	PSO	Control	PSO	Sig.
Pitch	13	14	1.8 (0.2, 4.0)	2.6 (0.7, 4.7)	0.0 (0.0, 0.3)	0.1 (0.0, 0.4)	> 0.05
Roll	13	14	0.9 (0.2, 2.4)	0.7 (0.3, 2.3)	0.2 (0.0, 0.6)	0.5 (0.1, 1.1)	> 0.05
Yaw	13	14	0.6 (0.3, 1.2)	0.2 (0.2, 0.9)	0.0 (0.0, 0.1)	0.2 (0.1, 0.6)	< 0.01 *

PSO, patient-specific osteosynthesis; UI, upper central incisor. \*Significant,  $P < 0.05$ .

conventional osteosynthesis resulted in very stable results at the 1-year follow-up.

In the literature, larger advancement of the maxilla has been found to be more unstable in a number of studies.<sup>7,15–19</sup> In the current study, the PSO group had a larger median advancement of 3.8 mm in comparison to the control group advancement of only 2.8 mm; however the difference was not significant. Regardless of the larger advancement in the PSO group, the two groups had comparable postoperative stability in the anterior/posterior direction.

Of note, the statistical comparison between the directional and rotational sub-groups suffered from the skewedness in group sizes. Considering the prevalence of relapse, the skewedness in group sizes might have influenced the results of the statistical comparison. Generally, the results of this study are limited by a relatively small sample size due to the large number of patients lost during follow-up.

The accuracy of PSO is significantly favourable in a maxillary advancement of more than 3.7 mm.<sup>3</sup> The current results suggest that PSO provides a stable result for a median anterior translation of 3.8 mm. The choice between conventional osteosynthesis and PSO should possibly also be based on the patient's specific surgery plan, considering not only the immediate postoperative accuracy but also the expected stability after 1 year of follow-up.

A previous study reported in the literature on relapse when using conventional four-miniplate fixation for larger maxillary advancements, indicated that maxillary advancements of 0–6 mm, 7–9 mm, and > 10 mm resulted in increasing instability of  $0.0 \pm 0.6$  mm,  $0.7 \pm 1.5$  mm, and  $1.9 \pm 1.8$  mm

relapse, respectively.<sup>19</sup> Given the indication for the use of PSO for larger maxillary advancements, and the suggestion from the current results that PSO might result in a comparable or possibly better postoperative stability than conventional osteosynthesis for larger maxillary advancements, a separate study to compare the stability of larger (> 3.5 mm) maxillary advancements might be useful.

The 1-year follow-up data presented suggest that the choice between patient-specific and conventional osteosynthesis does not affect the postoperative skeletal stability. Although a statistically significant difference was found when considering rotation around the yaw axis, the difference was too small to be of clinical significance. Considering the clinical relevance, the postoperative stability when using PSO appears to be non-inferior to the postoperative stability when using conventional osteosynthesis.

#### Ethics approval and consent to participate

Approved by the Medical Ethics Review Committee, University Medical Centre Groningen (File Number METc 2015/084).

#### Funding

This collaboration project is co-financed by the Dutch Ministry of Economic Affairs and Climate Policy by means of the Public–Private Partnership allowance made available by Top Sector Life Sciences & Health to stimulate public–private partnerships.

#### Competing interests

None.

#### Patient consent

Written patient consent was obtained.

#### Trial registration

The trial was registered in the Netherlands Trial Registry (number NTR5324).

#### References

1. Suojanen J, Leikola J, Stoor P. The use of patient-specific implants in orthognathic surgery: a series of 32 maxillary osteotomy patients. *J Craniomaxillofac Surg* 2016;**44**:1913–6. <https://doi.org/10.1016/j.jcms.2016.09.008>
2. Heufelder M, Wilde F, Pietzka S, Mascha F, Winter K, Schramm A, Rana M. Clinical accuracy of waferless maxillary positioning using customized surgical guides and patient specific osteosynthesis in bimaxillary orthognathic surgery. *J Craniomaxillofac Surg* 2017;**45**:1578–85. <https://doi.org/10.1016/j.jcms.2017.06.027>
3. Kraeima J, Schepers RH, Spijkervet FKL, Maal TJJ, Baan F, Witjes MJH, Jansma J. Splintless surgery using patient-specific osteosynthesis in Le Fort I osteotomies: a randomized controlled multi-centre trial. *Int J Oral Maxillofac Surg* 2020;**49**:454–60. <https://doi.org/10.1016/j.ijom.2019.08.005>
4. Dowling PA, Espeland L, Sandvik L, Mobarak KA, Hogevoid HE. LeFort I maxillary advancement: 3-year stability and risk factors for relapse. *Am J Orthod Dentofacial Orthop* 2005;**128**:560–7. <https://doi.org/10.1016/j.ajodo.2004.07.051>
5. Van Sickels JE, Richardson DA. Stability of orthognathic surgery: a review of rigid fixation. *Br J Oral Maxillofac Surg* 1996;**34**:279–85. [https://doi.org/10.1016/S0266-4356\(96\)90002-9](https://doi.org/10.1016/S0266-4356(96)90002-9)
6. Egbert M, Hepworth B, Myall R, West R. Stability of Le Fort I osteotomy with maxillary advancement. A comparison of combined wire fixation and rigid fixation.

- J Oral Maxillofac Surg* 1995;**53**:243–8. [https://doi.org/10.1016/0278-2391\(95\)90217-1](https://doi.org/10.1016/0278-2391(95)90217-1)
7. Ragaey M, Van Sickels JE. Stability of large maxillary advancements using a combination of prebent and conventional plates for fixation. *Oral Surg Oral Med Oral Pathol Oral Radiol* 2017;**123**:29–36. <https://doi.org/10.1016/j.oooo.2016.08.019>
  8. Susarla SM, Ettinger R, Preston K, Kapadia H, Egbert MA. Two-point nasomaxillary fixation of the Le Fort I osteotomy: assessment of stability at one year postoperative. *Int J Oral Maxillofac Surg* 2020;**49**:466–70. <https://doi.org/10.1016/j.ijom.2019.08.006>
  9. Kotaniemi KVM, Heliövaara A, Kotaniemi M, Stoor P, Leikola J, Palotie T, Suojanen J. Comparison of postoperative skeletal stability of maxillary segments after Le Fort I osteotomy, using patient-specific implant versus mini-plate fixation. *J Craniomaxillofac Surg* 2019;**47**:1020–30. <https://doi.org/10.1016/j.jcms.2019.04.003>
  10. Carneiro Júnior JT, Voss de Oliveira D, Goodday R. Maxillary stability following Le Fort I osteotomy using prebent plates and wire fixation in patients undergoing surgery for OSAS. *J Craniomaxillofac Surg* 2018;**46**:1448–54. <https://doi.org/10.1016/j.jcms.2018.05.052>
  11. Kraeima J, Jansma J, Schepers RH. Splintless surgery: does patient-specific CAD–CAM osteosynthesis improve accuracy of Le Fort I osteotomy? *Br J Oral Maxillofac Surg* 2016;**54**:1085–9. <https://doi.org/10.1016/j.bjoms.2016.07.007>
  12. Swennen GR, Mollemans W, De Clercq C, Abeloos J, Lamoral P, Lippens F, Neyt N, Casselman J, Schutyser F. A cone-beam computed tomography triple scan procedure to obtain a three-dimensional augmented virtual skull model appropriate for orthognathic surgery planning. *J Craniofac Surg* 2009;**20**:297–307. <https://doi.org/10.1097/SCS.0b013e3181996803>
  13. Maes F, Collignon A, Vandermeulen D, Marchal G, Suetens P. Multimodality image registration by maximization of quantitative–qualitative measure of mutual information. *Pattern Recognit* 2008;**41**:285–98. <https://doi.org/10.1016/j.patcog.2007.04.002>
  14. Baan F, Liebrechts J, Xi T, Schreurs R, de Koning M, Bergé S, Maal T. A new 3D tool for assessing the accuracy of bimaxillary surgery: the OrthoGnathicanAlyser. *PLoS One* 2016;**11**:e0149625. <https://doi.org/10.1371/journal.pone.0149625>
  15. Bailey LTJ, Cevidanes LHS, Proffit WR. Stability and predictability of orthognathic surgery. *Am J Orthod Dentofacial Orthop* 2004;**126**:273–7. <https://doi.org/10.1016/j.ajodo.2004.06.003>
  16. Fahradyan A, Wolfswinkel EM, Clarke N, Park S, Tsuha M, Urata MM, Hammoudeh JA, Yamashita DR. Impact of the distance of maxillary advancement on horizontal relapse after orthognathic surgery. *Cleft Palate Craniofac J* 2018;**55**:546–53. <https://doi.org/10.1177/1055665617739731>
  17. Lee CC, Xhori O, Tannyhill RJ, Kaban LB, Peacock ZS. Variables associated with stability after Le Fort I osteotomy for skeletal Class III malocclusion. *Int J Oral Maxillofac Surg* 2021;**50**:1203–9. <https://doi.org/10.1016/j.ijom.2021.02.004>
  18. Proffit WR, Turvey TA, Phillips C. The hierarchy of stability and predictability in orthognathic surgery with rigid fixation: an update and extension. *Head Face Med* 2007;**3**:21. <https://doi.org/10.1186/1746-160X-3-21>
  19. Louis PJ, Waite PD, Austin RB. Long-term skeletal stability after rigid fixation of Le Fort I osteotomies with advancements. *Int J Oral Maxillofac Surg* 1993;**22**:82–6. [https://doi.org/10.1016/S0901-5027\(05\)80808-2](https://doi.org/10.1016/S0901-5027(05)80808-2)

Correspondence to: Department of Oral and Maxillofacial Surgery  
University Medical Center Groningen  
PO Box 30.001  
NL-9700 RB Groningen  
the Netherlands.  
E-mail: [H.van.der.wel@umcg.nl](mailto:H.van.der.wel@umcg.nl)