

## BONE TUMORS IN CHILDREN: INCIDENCE, DIAGNOSIS, SURGICAL TREATMENT AND COMPLICATIONS

MIROSLAV SMERDELJ, ROBERT KOLUNDŽIĆ, DUBRAVKO ORLIĆ and MARKO BERGOVEC

Department of Orthopedic Surgery, Clinical Hospital Center Zagreb  
and Zagreb University School of Medicine, Croatia

---

### Summary

Bone tumor treatment changed considerably during past decades. Due to improvements in basic research in the areas of tumor biology, tumor detection and imaging, surgical procedures and development of modern surgical instruments, discovery and use of new technical equipment, and especially in the use of chemotherapy and radiotherapy, significant progress has been achieved. About 100 new patients with primary bone tumor (both benign and malignant) are discovered in Croatia and treated at the Department of Orthopedic Surgery, Clinical Hospital Center Zagreb and Zagreb University School of Medicine per year, and almost a half of them (45%) are younger than 20 years. The most common benign bone tumors are osteochondroma, simple (juvenile) bone cyst, and osteoid osteoma, and the most common malignant bone tumors are osteosarcoma and Ewing's sarcoma. Bone tumors are localized mostly in the long bones (femur, tibia, humerus), and the knee joint region is the most common site of tumors.

Patient history and examination with laboratory and imaging methods remain the essence in tumor diagnosis. A conventional X-ray examination must be the first and the most important part in tumor imaging, followed by bone scan, CT, MRI, ultrasound, and histological or cytological analysis. The biopsy, as the most accurate method in tumor diagnosis must be performed as the last diagnostic procedure. Cytological analysis is useful in tumors with soft tissue.

An individual approach to patient is essential in order to choose the most suitable surgical treatment for bone tumor. Depending on the tumor type, location and other patient-related risk factors, one of the various forms of surgical therapy should be chosen. Limb salvage surgery means "en-bloc" tumor resection with the affected part of the bone through a healthy tissue and defect reconstruction, with preservation of the affected limb; this procedure is performed nowadays in about 85% of patients with malignant bone tumors. Reconstruction can be biologic (with bone auto- or homotransplant) or with foreign material (i.e. endoprosthesis or bone cement). Soft tissue reconstruction is a great challenge in this part of a treatment, and complications are not rare. Amputation still has and will have in the future an important place in treating patients with malignant bone tumor.

Decision on additional chemo- and/or radiotherapy should be made between pediatric, oncology and orthopedic surgeons, according to international guidelines.

Future devolvement in treating patients with bone tumors points into supporting and/or establishing reparative procedures. Bone and surrounding tissue regeneration is always better than defect reconstruction.

KEY WORDS: *bone tumors in children, benign, malignant, diagnosis, therapy*

### TUMORI KOSTI U DJECE: UČESTALOST, DIJAGNOZA, KIRURŠKO LIJEČENJE I KOMPLIKACIJE

#### Sažetak

Liječenje tumora kosti posljednjih se desetljeća znatno promijenilo. Zahvaljujući napretku temeljne znanosti u području biologije tumora, boljoj mogućnosti otkrivanja i snimanja tumora, kirurškim metodama i suvremenim kirurškim instrumentima, otkriću i primjeni nove tehničke opreme, a posebice kemoterapiji i radioterapiji postignuto je mnogo. U Hrvatskoj se godišnje otkrije oko 100 novih bolesnika s primarnim tumorom kosti (dobročudnih i zloćudnih) i toliko ih se liječi u Klinici za ortopediju Kliničkog bolničkog centra Zagreb i Medicinskog fakulteta Sevučilišta u Zagrebu, a gotovo

polovica tih bolesnika (45%) mlađa je od 20 godina. Najčešći dobroćudni tumori kosti su osteohondrom, jednostavna (juvenilna) koštana cista i osteoidni osteom, dok su najčešći zloćudni tumori kostiju osteosarkom i Ewingov sarkom. Tumori kostiju uglavnom se nalaze u dugim kostima (femur, tibija, humerus), a najčešće sjelo tumora je područje koljennoga zgloba.

Povijest bolesti i pregled upotpunjen laboratorijskim i radiološkim nalazima i dalje su temelj za postavljanje dijagnoze tumora. Konvencionalni rtg pregled mora biti prvi i najvažniji dio snimanja tumora, nakon čega slijede scintigrafija, CT, MRI, ultrazvuk te histološka ili citološka analiza. Biopsija je najtočnija metoda u dijagnozi tumora i zadnji dijagnostički postupak koji se mora obaviti. Citološka analiza je korisna kad je riječ o tumorima mekog tkiva.

Individualni pristup bolesniku nužan je za izbor najprikladnijeg oblika kirurškog liječenja tumora kosti. Izbor kirurške terapije ovisi o vrsti tumora, sjelu i ostalim čimbenicima rizika svakog pojedinog bolesnika. Kirurgija spašavanja ekstremiteta znači resekciju tumora 'en bloc' sa zahvaćenim dijelom kosti kroz zdravo tkivo i rekonstrukcijom defekta, uz sačuvanje zahvaćenog ekstremiteta; taj se postupak danas primjenjuje u oko 85% bolesnika sa zloćudnim tumorima kosti. Rekonstrukcija se može izvesti biološki (auto- ili homotransplantatom) ili stranim materijalom (endoprotezom ili koštanim cementom). Rekonstrukcija mekog tkiva velik je izazov u tome dijelu liječenja i komplikacije nisu rijetka pojava. Amputacija još uvijek ima i ubuduće će imati važno mjesto u liječenju bolesnika sa zloćudnim tumorima kosti.

Odluku o naknadnoj primjeni kemo- i/ili radioterapije zajedno trebaju donijeti pedijatar, onkolog i ortopedski kirurg u skladu s međunarodnim smjernicama.

Daljnja zadaća u liječenju bolesnika s tumorima kosti jest podupirati i/ili odrediti reparativne postupke. Regeneracija kosti i okolnoga tkiva uvijek je bolja solucija od rekonstrukcije defekta.

KLJUČNE RIJEČI: *tumori kosti u djece, dobroćudni, zloćudni, dijagnoza, liječenje*

## INTRODUCTION

The past decade has seen a considerable change in the treatment of primary and secondary tumors of the locomotor system. An increase in the survival of treated patients from previous 20% to more than 75% nowadays is encouraging. Due to breakthroughs in basic research in the areas of tumor biology, tumor detection and imaging, surgical procedures, development of modern surgical instruments, discovery and use of new technical equipment and especially in the use of chemotherapy and radiotherapy, significant progress has been achieved.

Biologically speaking, the behavior of a bone tumor is similar in all age groups, but there are special features of malignant disease during the first two decades of life (1-4).

## INCIDENCE

The Department of Orthopedic Surgery Clinical Hospital Centre Zagreb and Zagreb University School of Medicine is the main medical institution in Croatia for treating patients with primary bone tumors. In the time period 1994-2004, we performed about 32,000 of all operative procedures, and 4.2% were operations on patients with tumor of the locomotor system. Age distribution showed that 45% of patients are

younger than 20 years, with the peak incidence during the maximum growth (age 11-15 years). Sex distribution is about equal.

The top five most common bone tumors are osteochondroma (present in 17.1% of all tumors in patients younger than 20 years), simple (juvenile) bone cyst (6.6%), osteoid osteoma (4.8%), osteosarcoma (4.3%), and Ewing's sarcoma (3.1%). Other, less common bone tumors in children are: enchondroma, giant cell tumor of bone, hemangioma, non-ossificant fibroma, aneurismal bone cyst, and the others.

Bone tumors are localized mostly in long bones: in the distal femur (13.6%), in the proximal femur (9.8%), in the proximal tibia (8.8%), and in the proximal humerus (7.8%). The knee joint region is the most common site of tumors, presented in about one fifth of the patients (22.4%). In about three quarters of our patients, lesions are located near a growth plate (5, 6).

## DIAGNOSIS

Patient history and clinical examination must be the beginning of the approach to a patient with possible bone tumor. Many of diagnostic procedures are well known for a long time, but some clinical and diagnostic procedures are introduced in the last few years. Searching for the right diagnosis, one should choose the best avail-

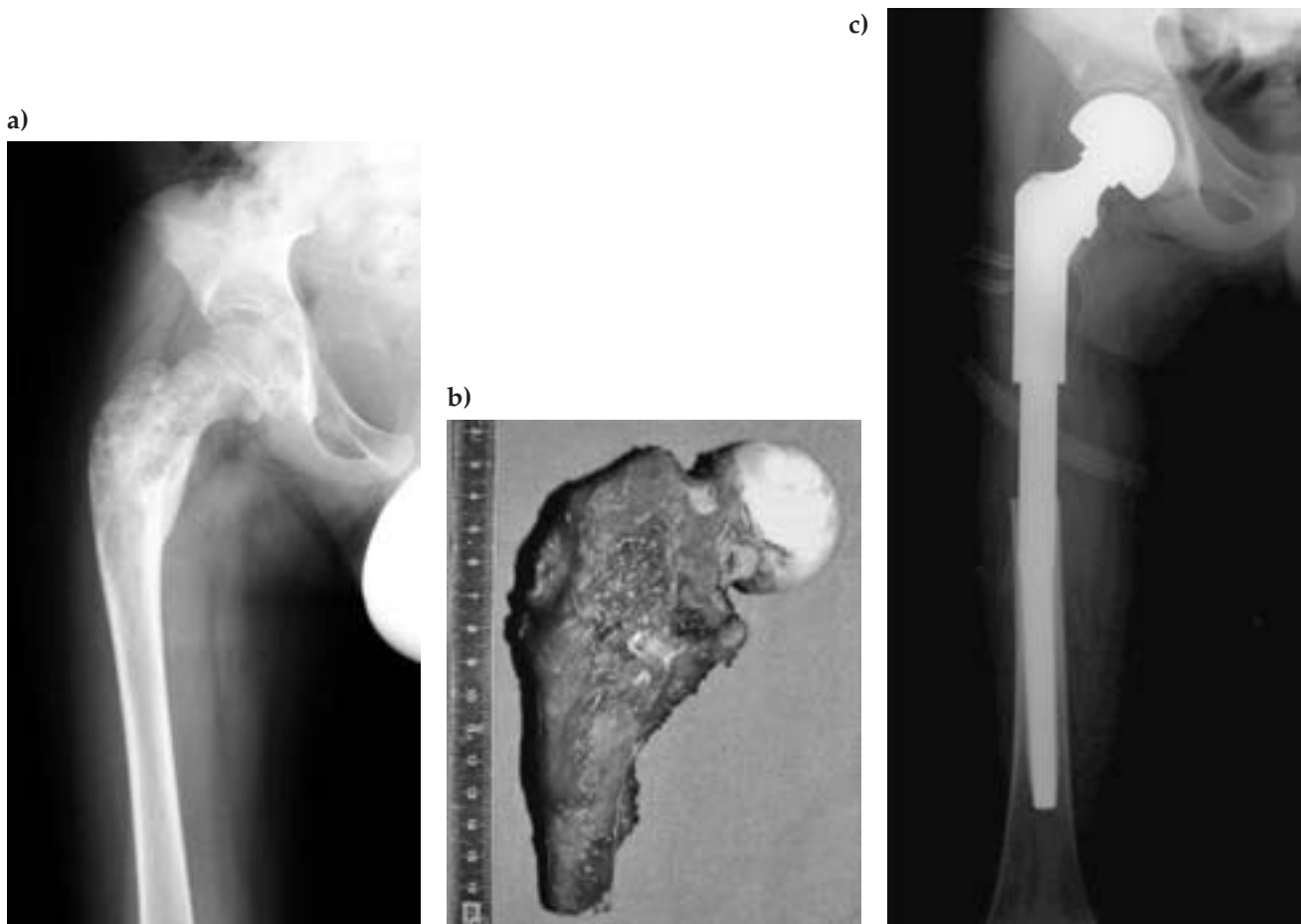


Figure 1. A 10-year-old boy with Ewing's sarcoma localized in the proximal femur (A). "En bloc" resection of 13 cm (38%) of the proximal femur (B) and implantation of partial hip endoprosthesis (C).

able diagnostic procedure individually for each patient, taking into consideration cost benefit of each of those procedures.

A conventional X-ray examination must be the first and the most important procedure in tumor imaging. The procedure is simple, available, and not very expensive, but requires greater experience for correct interpretation of pathologic changes. Bone scintigraphy with Technetium-99 methylene diphosphonate is the most frequently used nuclear test to show us the reaction of a bone due to tumor presence. Skeleton scintigrams are useful in diagnosing and staging local changes and even more so in diagnosing diffuse systemic tumor changes. CT scans are now accessible at many medical centers. Its major contribution lies in excellent 3D imaging of bone destruction and of calcification within a tumor tissue. MRI, as a non-ionizing technique, has an advan-

tage in 3D imaging of osseous and especially soft-tissue tumor structures. Analyzing a tumor in three dimensions is most helpful to an orthopedic oncologist in planning the surgical approach. An image of the intramedullary canal and tumor dissemination within bone marrow, skipped metastases and edema together with an image of neurovascular structures is particularly important to determine tumor resectability. Difficulties are still encountered in differentiating an infection or trauma from tumors (4, 7).

The biopsy of a radiographically apparent bone lesion is usually essential before treatment planning. The biopsy has potential prognostic and therapeutic consequences and therefore should be undertaken by the orthopedic surgeon who will carry out the definitive treatment. The biopsy should be performed so that biopsy scar tissue can be excised "en bloc" with the lesion

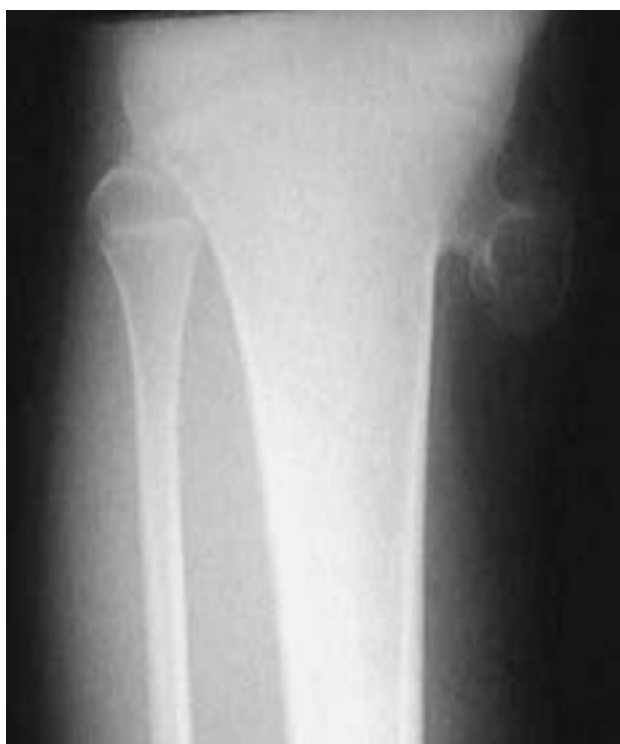

Figure 2. Osteochondroma localized in the proximal tibia. The treatment method is a simple tumor ablation.

during the subsequent operation. The principles of biopsy include complete radiologic staging before the biopsy, determining the most appropriate biopsy method (fine needle, core needle, open surgical biopsy), placing the biopsy tract appropriately. The possible complications of biopsy include hematoma, tumor-cell leakage, infection, and pathological fracture (1, 8, 9).

After tumor removal, the most reliable prognostic factors are based on observation and determination of the tumor's histological response to chemotherapy. An obviously poor response to chemotherapy inevitably requires certain changes in treatment procedures. Besides other applications, the primary role of radiotherapy is to inactivate the potential microscopic dissemination of the tumor, which is important to the effectiveness of surgical procedure (4, 10).

### SURGICAL TREATMENT AND COMPLICATIONS

Historically, bone tumors were mostly treated by amputation, although this did not increase

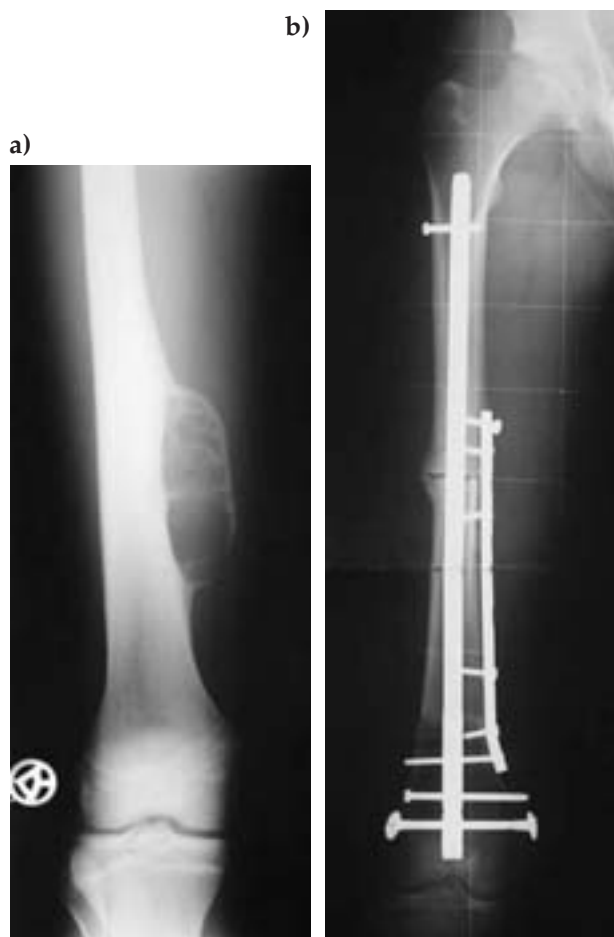

Figure 3. Radiographs of a 10-year-old boy with periosteal osteosarcoma localized in the femoral shaft (A). After "en bloc" resection reconstruction was performed with massive allograft, fixed with an unreamed femoral nail and plate and screws (B).

the survival rate. When surgery was the only method of treatment, the survival rate was less than 20% and it was seen only in patients with localized disease. With the development of modern chemotherapy and technical achievements, the outlook for malignant tumors has greatly improved and encouraged surgeons to consider limb salvage surgery in most cases. The success of limb salvage is the result of advances in the understanding of the biology and staging of tumors, improvement in the reconstructive techniques, and the development of effective adjuvant chemotherapy for the primary tumors, and is still going on (11-13).

The first part in surgical treatment is tumor excision through a healthy surrounding tissue,

and its adequacy can be judged simply by the rate of local recurrence. To cure primary bone tumors it is necessary to perform "en-bloc" resection of all macroscopic disease including the biopsy scar.

The second part in surgical treatment is reconstruction, and can be performed in the same time with "en bloc" resection (one stage) or after it (two stage operation). Nowadays, up to 85% of all malignant tumors are treated by limb salvage surgery, without compromising the oncological result. Limb salvage surgery means reconstruction of bone defect after resection with preservation of the affected limb. Limb salvage surgery has traditionally been a difficult technical problem in orthopedic oncology. These procedures require a multidisciplinary approach in which the surgeon is joined by radiologists, pathologists and oncologists, and should be performed only in highly qualified medical centers to avoid complications for inexperience due to small number of cases (1, 2, 4)

The appropriate treatment to achieve local control after resection of bone tumor is still a subject of debate, and the long-term durability of various reconstructive methods is not known.

A few patients with primary tumors of the fibula, ulna, scapula or rib can be treated by simple resection and have minimal functional impairment. Malignant lesions are most common in the lower limb and the selection of a method of reconstruction must consider the function following part of a limb resection. Currently, the three most popular options are using an endoprosthesis, allograft-prosthetic composite, and biological reconstructions. Each of those methods has its short- and long-term advantages and disadvantages, and a surgeon should consider each patient individually (14-16).

Endoprosthetic replacement offers several advantages, such as early stability, mobilization and weight bearing, a shorter operating time and hospital stay in comparison to biologic reconstructions, and it allows early introduction of post-operative adjuvant therapy. Reconstruction with an endoprosthesis after resection of a bone tumor gives good functional results in most of the cases.

There are many types and models of endoprosthesis. Classic endoprosthesis, used mostly

in degenerative joint disease, have very narrow indication area in reconstruction after tumor resection. Special tumoral endoprosthesis, modular endoprosthesis and custom made endoprosthesis are mostly used foreign material in limb salvage surgery. Mechanically, these endoprosthesis are excellent, but due to great part of bone, muscles and supporting soft tissue resection can be connected to long term failure. Special "growing endoprosthesis" could be used in younger, still growing children. These devices allow lengthening of the operated limb as the child grows.

Endoprosthesis luxation, aseptic loosening, infections, limb discrepancy due to child growth, and periprosthetic fractures are the main complications in using endoprosthesis (17, 18).

Biologic reconstruction can be performed with either bone autografts or allografts. Iliac crest, tibial tuberosity or spongy bone from other location, and autologous fibula are the main sources of autotransplant. Although autografts are biologically more acceptable than allografts, morbidity at a donor site and small amount of autogenous bone remain the main problems.

Reconstructive surgery using massive allografts is a successful alternative to prosthetic implant in young patients with a long life expectancy. Improvements in anatomic matching, infection prevention, allograft fixation, soft tissue reconstructions, and rehabilitation protocols have greatly influenced predictability and longevity of massive allografts. These demanding reconstructions require time, an experienced group of orthopedic surgeons working at an institution with access to a large volume of patients, and a reliable, modern bone bank to select the appropriate graft for each individual under safe conditions. Longer time in non-weight bearing, pseudarthrosis, hardware breakage, allograft fracture, a longer operating time and hospital stay in comparison to endoprosthesis reconstructions are the main problems in using massive bone allografts (19, 20).

Limb length discrepancy at the end of growth may be severe: this applies mainly to lower-limb reconstruction, since upper-limb asymmetry of up to 10 cm could be tolerated. For the lower limb a number of procedures have been

described, but there is no consensus which procedure is the best. Sometimes contralateral epiphyseodesis during primary surgery is enough to avoid limb-length discrepancy at the end of growth. Possible solution is also using external fixators for limb lengthening at the end of child's growth.

The refinement of techniques for limb salvage has opened a new chapter in oncological surgery of the musculoskeletal system. Still, future devolvement in treating patients with bone tumors points into supporting and/or establishing reparative procedures. Bone and surrounding tissue regeneration is always better than bone defect reconstruction.

Treatment of pediatric oncology patient must be strictly prioritized in terms of the patient's life, the limb, its function, length equalization, and cosmetic appearance. At the same time, social, socioeconomic, and cultural factors must be understood and respected to achieve the best possible outcome.

Finally: given these considerations, drafting generalized treatment recommendations is difficult. Instead, orthopedic intervention in the care of children with bone tumors must be individualized, with the broad goal being optimization of limb function (1, 21).

#### REFERENCES

1. Canadell J. Treatment of malignant bone tumors in children and adolescents. European instructional course lectures. London: The British Editorial Society of Bone and Joint Surgery, 1995;142-8.
2. Veth R, van Hoesel R, Pruszczynski M, Hoogenhout J, Schreuder B, Wobbles T. Limb salvage in musculoskeletal oncology. *Lancet Oncol* 2003; 4: 343-50.
3. Čepulić M, Orlić D, Nakić M, Fattorini I, Čepulić E, Štepan-Giljević J. Zloćudni tumori kostiju u djece. *Paediatrica Croatica* 2002;46, suppl 3; 309-12.
4. Orlić D, Smerdelj M, Kolundžić R. Tumori koštano-zglobnog sustava. In: Pećina M at al. *Ortopedija*, Zagreb: Naklada Ljevak, 2004;140-64.
5. Strnad M, Znaor A. Cancer patients survival in Croatia 1988-1998. Croatian National Cancer Registry, Croatian National Institute of Public Health. Zagreb, 2006
6. Bergovec M, Smerdelj M, Kolundzic R, Orlic D. Bone Tumor Incidence at the Department of Orthopaedic Surgery Zagreb University School of Medicine from

- 1981 to 2002. In: Program and abstracts of the 7th EFORT Congress, 4-7 June 2005, Lisboa, Portugal
7. Orlić D, Kolundžić R, Đapić T, Smerdelj M. Koštani tumori dječje dobi. *Pediatr Croat* 2003; suppl 3: 123-31.
8. Aboulafia AJ. Biopsy. *Instr Course Lect* 1999; 48: 587-90.
9. Scarborough MT. The biopsy. *Instr Course Lect* 2004; 53: 639-44.
10. Ilić I, Manojlović S, Čepulić M, Orlić D, Seiwerth S. Osteosarcoma and Ewing's sarcoma in children and adolescents: retrospective clinicopathological study. *Croat Med J* 2004; 45: 740-5.
11. Eckardt JJ, Eilber FR, Dorey FJ, Mirra JM. The UCLA experience in limb salvage surgery for malignant tumors. *Orthopedics* 1985; 8: 612-21.
12. Natarajan M, Bose JC, Rajkumar G. Proximal femoral reconstruction with custom mega prosthesis. *Int Orthop* 2003; 27: 175-9.
13. Kolundžić R, Smerdelj M, Bergovec M, Orlić D. Hitna stanja kod tumora sustava za kretanja u djece i odraslih. *Liječ Vjesn* 2005;127: 203-6.
14. Donati D, Giacomini S, Gozzi E, Mercuri M. Proximal femur reconstruction by an allograft prosthesis composite. *Clin Orthop* 2002; 394: 192-200.
15. Gibbs CP Jr, Weber K, Scarborough MT. Malignant bone tumors. *J Bone Joint Surg (Am)* 2001; 83:1728-45.
16. Manfrini M, Innocenti M, Ceruso M, Mercuri M. Original biological reconstruction of the hip in a 4-year-old girl. *Lancet* 2003; 361: 140-2.
17. Kotz R, Dominkus M, Zettl T, Ritschl P, Windhager R, Gardner H, Zielinski C, Salzer-Kuntschik M. Advances in bone tumor treatment in 30 years with respect to survival and limb salvage. A single institution experience. *Int Orthop* 2002; 26: 197-202.
18. Sanjay BK, Moreau PG. Limb salvage surgery in bone tumor with modular endoprosthesis. *Int Orthop* 1999; 23: 41-6.
19. Amillo S, Cara JA, Valenti JR. Tissue bank for the musculoskeletal system. Clinical applications. *Rev Med Univ Navarra* 1990; 34: 227-34.
20. Muscolo DL, Ayerza MA, Aponte-Tinao LA. Massive allograft use in orthopedic oncology. *Orthop Clin North Am.* 2006; 37: 65-74.
21. Weisstein JS, Goldsby RE, O'Donnell RJ. Oncologic approaches to pediatric limb preservation. *J Am Acad Orthop Surg.* 2005;13: 544-54.

*Author's address: Marko Bergovec, MD, Department of Orthopedic Surgery, Clinical Hospital Center Zagreb and Zagreb University School of Medicine, Šalata 6, 10 000 Zagreb, Croatia; tel: 01/ 481-99-11; fax: 01/ 481-88-10; e-mail: bergovec@gmail.com*