

# Effectiveness of Automatic Planning of Fronto-orbital Advancement for the Surgical Correction of Metopic Craniosynostosis

David García-Mato, PhD\*†

Antonio R. Porras, PhD‡§

Santiago Ochandiano, MD, DMD,  
PhD†¶

Gary F. Rogers, MD||

Roberto García-Leal, MD†\*\*

José I. Salmerón, MD PhD†¶

Javier Pascau, PhD\*†

Marius George Lingurar, DPhil†††

**Background:** The surgical correction of metopic craniosynostosis usually relies on the subjective judgment of surgeons to determine the configuration of the cranial bone fragments and the degree of overcorrection. This study evaluates the effectiveness of a new approach for automatic planning of fronto-orbital advancement based on statistical shape models and including overcorrection.

**Methods:** This study presents a planning software to automatically estimate osteotomies in the fronto-orbital region and calculate the optimal configuration of the bone fragments required to achieve an optimal postoperative shape. The optimal cranial shape is obtained using a statistical head shape model built from 201 healthy subjects (age  $23 \pm 20$  months; 89 girls). Automatic virtual plans were computed for nine patients (age  $10.68 \pm 1.73$  months; four girls) with different degrees of overcorrection, and compared with manual plans designed by experienced surgeons.

**Results:** Postoperative cranial shapes generated by automatic interventional plans present accurate matching with normative morphology and enable to reduce the malformations in the fronto-orbital region by  $82.01 \pm 6.07\%$ . The system took on average 19.22 seconds to provide the automatic plan, and allows for personalized levels of overcorrection. The automatic plans with an overcorrection of 7mm in minimal frontal breadth provided the closest match (no significant difference) to the manual plans.

**Conclusions:** The automatic software technology effectively achieves correct cranial morphometrics and volumetrics with respect to normative cranial shapes. The automatic approach has the potential to reduce the duration of preoperative planning, reduce inter-surgeon variability, and provide consistent surgical outcomes. (*Plast Reconstr Surg Glob Open* 2021;9:e3937; doi: [10.1097/GOX.0000000000003937](https://doi.org/10.1097/GOX.0000000000003937); Published online 11 November 2021.)

From the \*Departamento de Bioingeniería e Ingeniería Aeroespacial, Universidad Carlos III de Madrid, Madrid, Spain; †Instituto de Investigación Sanitaria Gregorio Marañón, Madrid, Spain; ‡Sheikh Zayed Institute for Pediatric Surgical Innovation, Children's National Hospital, Washington, D.C.; §Department of Biostatistics and Informatics – Colorado School of Public Health, Department of Pediatrics – School of Medicine, University of Colorado Anschutz Medical Campus, Aurora, Colo.; ¶Servicio de Cirugía Oral y Maxilofacial, Hospital General Universitario Gregorio Marañón, Madrid, Spain; and ||Division of Plastic and Reconstructive Surgery, Children's National Hospital, Washington, D.C.; \*\*Servicio de Neurocirugía, Hospital General Universitario Gregorio Marañón, Madrid, Spain; and ††School of Medicine and Health Sciences, George Washington University, Washington, D.C. Received for publication July 22, 2021; accepted September 15, 2021.

Copyright © 2021 The Authors. Published by Wolters Kluwer Health, Inc. on behalf of The American Society of Plastic Surgeons. This is an open-access article distributed under the terms of the [Creative Commons Attribution-Non Commercial-No Derivatives License 4.0 \(CCBY-NC-ND\)](https://creativecommons.org/licenses/by-nc-nd/4.0/), where it is permissible to download and share the work provided it is properly cited. The work cannot be changed in any way or used commercially without permission from the journal.

DOI: [10.1097/GOX.0000000000003937](https://doi.org/10.1097/GOX.0000000000003937)

## INTRODUCTION

Surgical correction of metopic craniosynostosis is typically performed via fronto-orbital advancement (FOA)—an open cranial vault remodeling technique.<sup>1</sup> The objective of surgical correction is to normalize the volume and shape of the calvaria. FOA involves removal, remodeling, and repositioning of the frontal bones and supraorbital bandeau. Multiple techniques have been described for this type of craniosynostosis, but most focus

**Disclosure:** The authors have no financial interest in relation to the content of this article. This work was supported by grants R42 HD081712 (Eunice Kennedy Shriver National Institute of Child Health and Human Development), K99DE027993 (National Institute of Dental and Craniofacial Research), and P118/01625 (Ministerio de Ciencia e Innovación, Instituto de Salud Carlos III and European Regional Development Fund “Una manera de hacer Europa”).

Related Digital Media are available in the full-text version of the article on [www.PRSGlobalOpen.com](http://www.PRSGlobalOpen.com).

on widening and recontouring the narrow and angulated supraorbital bandeau, increasing the convexity of the flattened frontal bones, and lateral advancement of entire fronto-orbital construct.<sup>2</sup> Widening of the supraorbital bar can be performed using interposition bone graft or merely expanding the acutely angled bandeau, and closing wedge lateral osteotomies in the bandeau have been advocated to enable the bone tissue to curve at the tenon extension for lateral continuity.<sup>3</sup> Once the supraorbital bar is remodeled and stabilized, frontal bone fragments are typically cut, bent and reshaped to match the outline of the bandeau, and to achieve the desired cranial shape. The surgical outcome following FOA is contingent on the training, experience, and subjective judgment of the surgeon and, consequently, there is wide variability among surgeons and major centers.<sup>4</sup>

Computer-assisted surgical planning has been proposed to increase the accuracy, efficiency, and reproducibility of craniostylosis surgeries.<sup>5–12</sup> Virtual surgical planning (VSP) enables surgeons to define the osteotomies, and reconfigure the fragments to achieve the desired shape and features. Several studies have demonstrated a decreased operative time, and improved cranial morphology with VSP.<sup>6,7</sup> However, most reported techniques for interventional planning are based on manual interactions to define cutting planes and reconfigure bone fragments.<sup>8–10</sup> Furthermore, most of the available methodologies for VSP do not learn from normative, reference cranial shapes, and “normal” cranial shapes are subjectively defined by craniofacial surgeons through mental constructions. Therefore, these approaches are still highly subjective and dependent on the physician’s judgment and experience.

Only a few automatic surgical planning techniques have been developed to determine the optimal cranial shape to target during FOA.<sup>11,12</sup> These algorithms are based on statistical shape models generated from databases of normative subjects. Learning from normative data, the methods determine the optimal cranial shape to target during surgical treatment, which is objective and personalized to each subject. An optimization approach is then employed to rearrange the bone fragments in the most appropriate configuration that minimizes cranial malformations with respect to the optimal normal shape. However, previous methodologies were validated using only a few surgical templates that did not include bilateral tenon extensions of the supraorbital bar, which are essential during FOA to facilitate advancement and subsequent stabilization of the remodeled fragments.

It is important to note that although significant head shape improvements have been quantified after surgical treatment,<sup>13</sup> long-term postoperative follow-up evaluations of craniostylosis patients have shown the potential of abnormal cranial development following surgery.<sup>14</sup> Therefore, achieving a statistically normal cranial shape may not be sufficient to ensure optimal long-term aesthetic and functional outcomes. In this context, many authors have reported that an overcorrection must be performed in anticipation of relapse or lack of growth, and factored into the VSP.<sup>15–19</sup> To our knowledge, there are no methods

## Takeaways

**Question:** Can we improve the objectivity of the craniostylosis interventional planning?

**Findings:** We present a novel software to assist surgeons in objectively planning craniostylosis interventions. The automated technology is based on a statistical shape model of the healthy cranium built from 201 subjects. We evaluated this technology during the surgical planning of nine patients, with metopic craniostylosis. Results show an accurate matching between the automatic plans and manual plans performed by experienced surgeons, and a significant reduction of planning duration.

**Meaning:** Automatic surgical planning can reduce planning duration, diminish inter-surgeon variability, and provide objective surgical outcomes during craniostylosis interventional planning.

for automatic surgical planning of craniostylosis that incorporate overcorrection during the virtual configuration of the fragments.<sup>20</sup>

In this study, we present and evaluate a new approach for the automatic planning of FOA to treat metopic craniostylosis. Our method follows the standard surgical approach and includes overcorrection to ensure optimal long-term outcomes for the patients. This automatic framework has been integrated into a customized software that enables surgeons to introduce manual corrections into the VSP according to their surgical needs and preferences.

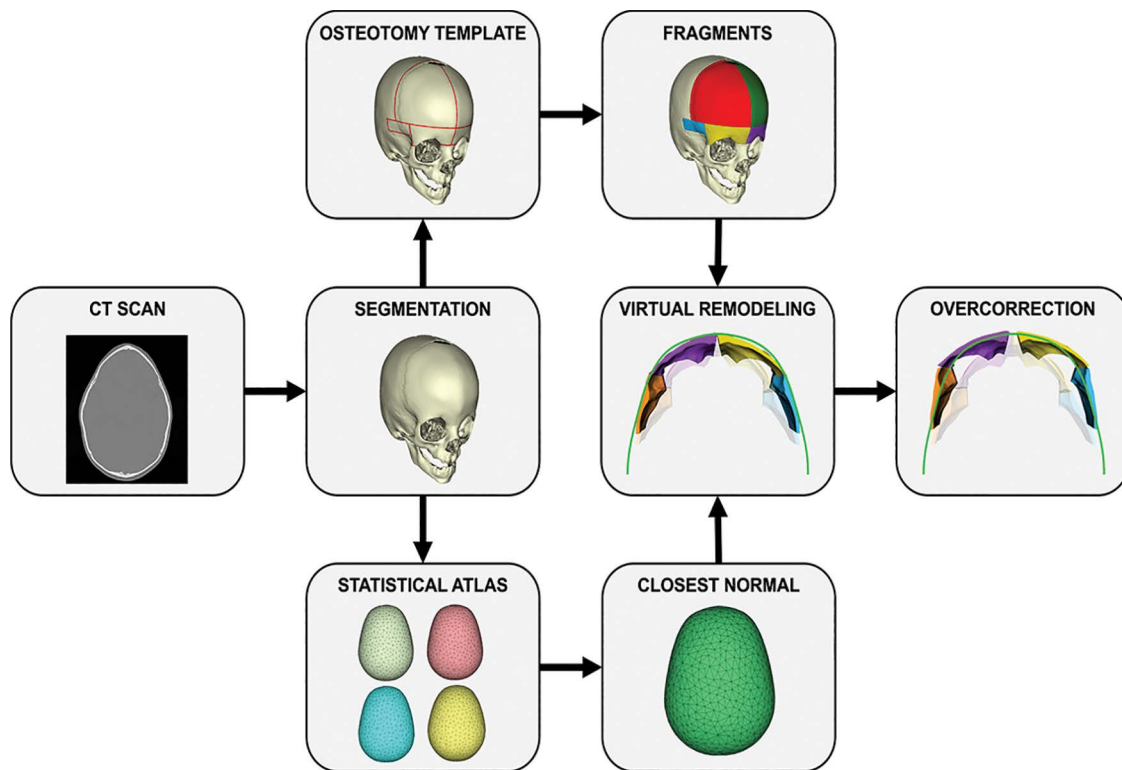
## METHODS

In this section, we first describe the database of subjects used in this study. Then, we detail the methodology for cranial shape evaluation, bone fragment estimation, and virtual remodeling. Finally, we describe the metrics used for the assessment of the performance of our planning software. A summary of the proposed workflow for automatic surgical planning is presented in [Figure 1](#).

### Data

Our automatic planning framework is evaluated on nine patients (mean age  $10.68 \pm 1.73$  months; range 8–13 months; four girls) with metopic craniostylosis. All patients were treated with an open cranial vault remodeling with FOA at Hospital General Universitario Gregorio Marañón. Available data for each patient include a preoperative CT scan, and a manual VSP performed by experienced craniofacial surgeons. The manual VSP includes virtual osteotomies, and the reconfiguration of fronto-orbital bone fragments. This manual VSP is used as a reference during surgical intervention.

In addition, we use a retrospective database including CT scans of 201 subjects without cranial conditions (mean age  $23 \pm 20$  months; range 0–72 months; 89 girls and 112 boys) to build a statistical shape atlas of the normative cranial shape.<sup>13,21</sup> The closest normative cranial shape to the patient with craniostylosis is selected as reference



**Fig. 1.** Proposed workflow for automatic surgical planning of FOA.

template to establish a common coordinate system for evaluation as described in a previous study.<sup>13</sup>

### Preoperative Cranial Shape Evaluation

Comprehensive, three-dimensional (3D) volumetric analysis of the patient cranial shape compared with normal morphology is crucial to determine the severity of the malformations, and the best approach for surgical correction. To quantify malformation, we follow the procedure described in a previous publication.<sup>21</sup> First, the cranium is extracted or segmented from the CT image. Then, we align each subject with metopic craniosynostosis with the reference template in the atlas, and compute a patient-specific, normative reference cranial shape. Then, cranial malformations are quantified at every location on the cranial vault as the local Euclidean distance between the normative reference calculated from the multi-atlas and the patient's cranial shape.

### Osteotomy Template

An osteotomy template was defined by specialized craniofacial surgeons based on their previous experience in craniosynostosis VSP. Eight cutting planes were defined in the fronto-orbital region of the reference template (normative subject) in the atlas (Fig. 2). The supraorbital axial, frontozygomatic, inferior temporal, and frontonasal planes are parallel to the Frankfurt plane. The coronal, sphenofrontal, posterior temporal, and midsagittal planes are perpendicular to the Frankfurt plane.

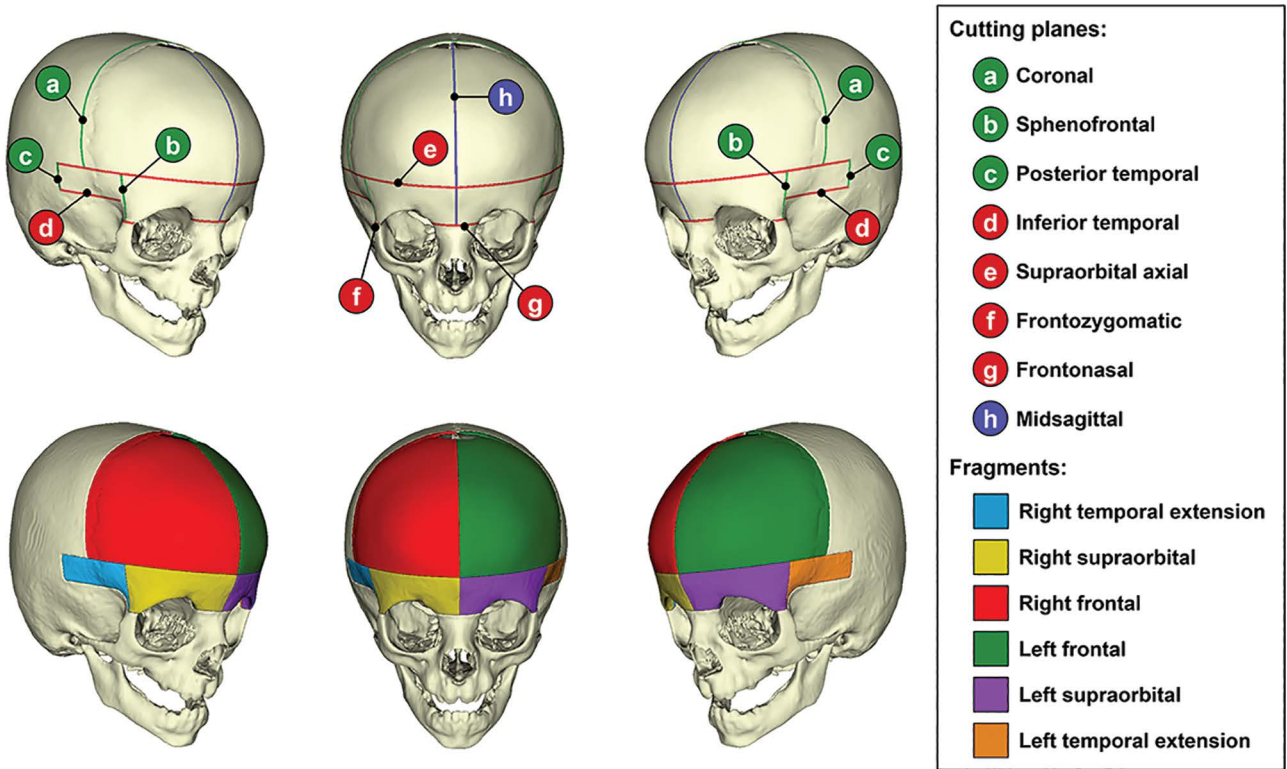
Fragments are automatically estimated for the nine subjects with craniosynostosis using the osteotomy

template. For each subject, the preoperative CT image is aligned with the reference template using the anatomy of the cranial base, and the eight cutting planes in the osteotomy template are directly projected onto the subject's coordinate space. Then, the projected cutting planes are used to simulate osteotomies in the fronto-orbital region, and generate the six bone fragments for FOA: four fragments in the supraorbital bar and two fragments in the frontal area (Fig. 2).

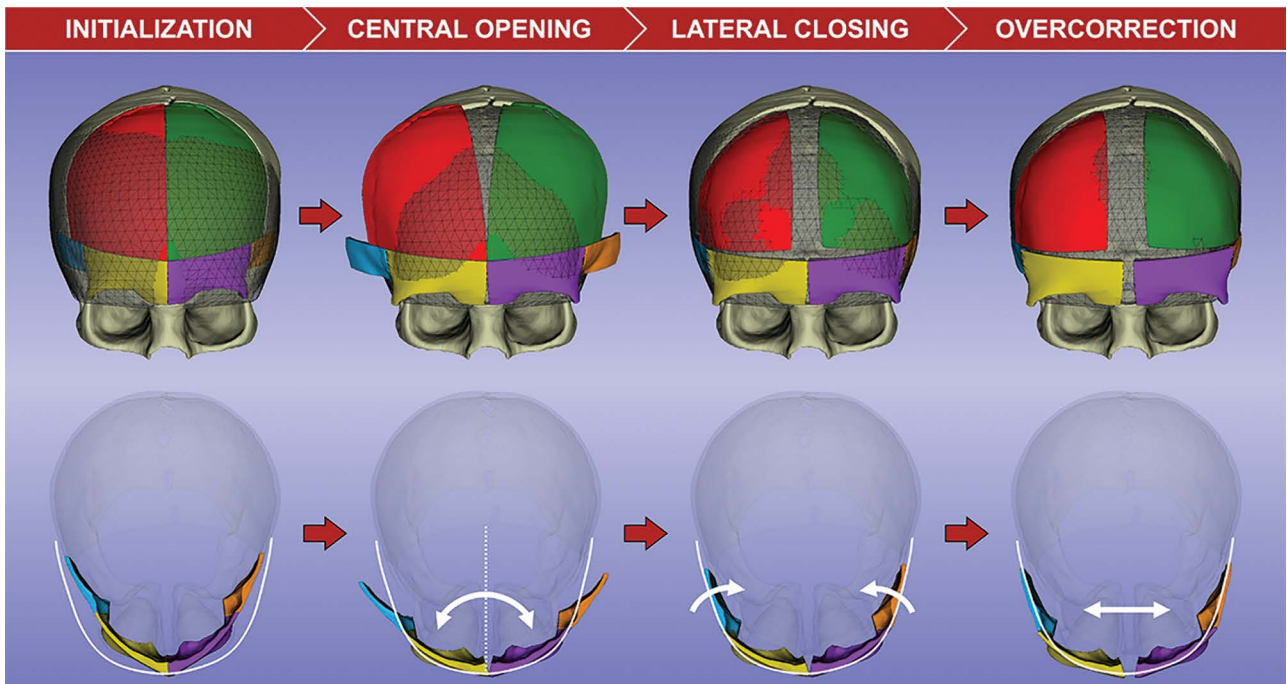
### Automatic Cranial Vault Remodeling

For virtual cranial remodeling, fragments in the fronto-orbital region are reconfigured to achieve the desired target shape (Fig. 3). The target shape is the normative reference cranial shape obtained as described in the "Preoperative Cranial Shape Evaluation" section. Our algorithm estimates the necessary transformation (ie, translation, rotation, and bending) required for each of the fragments to achieve the target cranial shape considering the constraints imposed by the clinical protocol of FOA, as explained next.

First, the two halves of the supraorbital bar and both frontal fragments are rotated parallel to the Frankfurt plane to increase the bitemporal width and the central angle. We refer to this step as the central opening. Optimal rotation is computed by minimizing the surface-to-surface distance between the left and right supraorbital fragments and the target shape. The rotation angle computed for each supraorbital fragment is applied to each ipsilateral frontal fragment. Then, bilateral temporal fragments of the bandeau are rotated parallel to the Frankfurt



**Fig. 2.** VSP of FOA: cutting planes (top) and fragments for cranial vault remodeling (bottom).



**Fig. 3.** Workflow for the simulation of FOA using a patient-specific normative reference obtained from a statistical shape model. The normative reference is displayed as a triangulated mesh in the top diagram and a white curve in the bottom diagram.

plane to ensure lateral continuity with the healthy bone tissue. In addition, the left and right frontal fragments are deformed to match the target shape by means of an affine model-to-model registration.

Finally, overcorrection is applied to further increase the interfrontal angle and the bifrontal width. The user can select two predefined levels of overcorrection: (1) *mild overcorrection*, which increases MFB by 7 mm, and (2)

severe overcorrection, which increases MFB by 15 mm as recommended by Fearon et al.<sup>14</sup> In addition, surgeons can manually input the desired degree of overcorrection into the planning software.

**Planning Software**

A software application called CranioPlan was developed to automatically plan FOA. This application was integrated as an extension of 3D Slicer,<sup>22</sup> an open-source software platform for medical image informatics, image processing, and 3D visualization. The developed application enables surgeons to import patient CT imaging studies, incorporates the tools for automatic estimation of the bone fragments in the fronto-orbital region using the osteotomy template, and reconfigures these fragments to correct the calvarial shape. (See Video [online], which shows the workflow for automatic planning of fronto-orbital advancement using CranioPlan software.) Although the software presents a fully automatic plan, it also enables the surgeon to manually modify the VSP according to their surgical needs and preferences.

CranioPlan enables the quantification of morphological metrics commonly used by craniofacial surgeons during diagnosis, surgical planning, and evaluation of surgical outcomes. These metrics include the interfrontal angle (IFA),<sup>23</sup> the transverse forehead width (TFW),<sup>24</sup> and minimal frontal breadth (MFB).<sup>14</sup> These morphological metrics are measured from a set of landmarks defined in the reference template of our statistical shape model, which are projected onto the coordinate space of each metopic subject under evaluation. Landmarks for the computation of IFA and TFW are determined as previously described by Mendoza et al,<sup>25</sup> whereas the landmarks for MFB are defined at the frontotemporal points on both sides of the reference cranium. Morphological metrics can be computed at any step during the VSP to compare the simulated surgical outcome with the preoperative and normative reference cranial shapes.

**Performance Evaluation**

The performance of our software was evaluated by automatically planning FOA in the nine patients with metopic craniosynostosis. Three treatment strategies were computed for each patient: without overcorrection (OC-0mm), mild overcorrection (OC-7mm), and severe overcorrection (OC-15mm). Optimal postoperative cranial shapes determined by our software for each

subject were compared with the manual VSP performed by experienced craniofacial surgeons, and also with the personalized normative reference shape, using the following metrics: IFA, TFW, MFB, intracranial volume (ICV) of the fronto-orbital region, and local malformations in the fronto-orbital region (ie, local Euclidean distance between the patient’s cranial shape and the personalized normative reference). The non-parametric Wilcoxon signed-rank test was used to evaluate the differences in IFA, TFW, MFB and ICV between automatic VSP, manual VSP, and normative cranial shapes. Applying Bonferroni correction for multiple comparisons, the p-value threshold for statistical significance was set at 0.0125 (0.05/4). In addition, the processing time required for automatic planning was measured for each subject.

Three experienced craniofacial surgeons evaluated the validity of automatic planning for surgical deployment according to their clinical experience and judgment. The automatic VSP for each patient was evaluated using scores on a five-point Likert scale, with possible scores for each patient ranging from one (inadequate for surgical deployment) to five (adequate for surgical deployment). Also, each surgeon indicated the most suitable treatment strategy for each patient: OC-0mm, OC-7mm, or OC-15mm.

**RESULTS**

CranioPlan software was successfully used to compute an automatic interventional plan for FOA in all patients. Evaluation of automatic VSP outcomes indicated a correct normalization of the cranial shape for all subjects (Table 1). All postoperative IFA values were within the range reported in the literature for normative patients: 136.7 ± 6.2 degrees; range 123.8–169.9 degrees.<sup>26</sup> The average processing time required to complete the automatic planning was 19.22 ± 3.25 seconds. Typical duration of manual VSP in our center ranges between 40 and 75 minutes.

Results without overcorrection (OC-0mm) demonstrated an accurate matching with the normative reference shape. There were no significant differences in IFA, TFW, and MFB metrics ( $P > 0.0125$ ). The average absolute error was 0.93 ± 0.57 degrees in IFA, 0.66 ± 0.43 mm in TFW, 2.16 ± 1.37 mm in MFB, and 1.25 ± 1.04 cm<sup>3</sup> in frontal ICV. In addition, local malformations in the fronto-orbital region were reduced from 2.73 ± 0.88 mm in the preoperative stage to 0.45 ± 0.09 mm after automatic VSP, representing an average reduction of 82.01 ± 6.07%. The

**Table 1. Mean and SD of Morphometric and Volumetric Values for Preoperative Cranial Shapes, Normative Reference Shapes, Manual Surgical Plans Performed by Experienced Craniofacial Surgeons, and Automatic Plans**

	Metric			
	IFA (degrees)	TFW (mm)	MFB (mm)	Front. ICV (cm <sup>3</sup> )
Preoperative	115.05 ± 5.26	69.12 ± 5.21	77.87 ± 4.54	161.18 ± 38.44
Normative	129.63 ± 3.89	78.51 ± 4.49	85.77 ± 3.92	190.22 ± 39.38
Manual VSP	133.48 ± 4.64	81.04 ± 4.17	88.87 ± 3.48	203.29 ± 36.46
Automatic OC-0mm	129.10 ± 3.85	78.04 ± 4.75	87.86 ± 4.74	191.47 ± 39.74
Automatic OC-7mm	132.39 ± 4.05	81.08 ± 4.46	92.40 ± 4.95	205.59 ± 42.20
Automatic OC-15mm	138.59 ± 3.18	85.87 ± 4.42	100.36 ± 5.46	235.80 ± 47.10

Automatic plans were computed with CranioPlan software with three different degrees of overcorrection: no overcorrection (OC-0mm), mild overcorrection (OC-7mm), and severe overcorrection (OC-15mm).

Downloaded from http://journals.lww.com/prsgo by BHD/M/5eP/H/K/v1/zEoun11Q/N4+K/L/HzgpsiHod4X/M10i0C/ywCX1A on 09/05/2022

average reduction was  $80.95 \pm 8.43\%$  and  $82.48 \pm 5.29\%$  in the supraorbital bar and frontal bone regions, respectively.

Automatic VSP with overcorrection showed increased IFA, TFW, MFB, and frontal ICV in all subjects (Table 2 and Fig. 4). Manual VSP performed by craniofacial surgeons showed an average overcorrection of 7.75% in the frontal ICV. Average volumetric overcorrection over the normative values was 0.66%, 8.16%, and 24.19% for OC-0mm, OC-7mm, and OC-15mm, respectively. The differences in all parameters between automatic VSP and the normative references presented lower variability than those from manual VSP, as shown by the SD values in Table 2.

Automatic mild overcorrection (OC-7mm) demonstrated a strong resemblance with manual VSP for all patients, with an average difference of 2.32 degrees in IFA, 1.28mm in TFW, 3.74mm in MFB, and  $12.81 \text{ cm}^3$  in frontal ICV. There were no significant differences in IFA, TFW, MFB, and ICV values ( $P > 0.0125$ ).

Feedback from three experienced craniofacial surgeons indicated that the automatic estimation of osteotomies was accurate and provided a suitable initialization for VSP. Surgeons considered that the orientation of the coronal cutting plane should be modified in two patients to avoid intersection with the coronal suture. In the rest of the cutting planes, no manual modifications were required. Considering that a total of eight cutting planes were defined in each of the nine patients, these results indicate that slight manual modifications were only required in two of 72 cutting planes according to surgical needs and preferences. Overall, surgeons agreed that all automatically estimated fragments were suitable for VSP (average score =  $4.78 \pm 0.42$ ). In addition, there was an agreement between surgeons that the postoperative cranial shapes generated by automatic interventional plans were adequate for surgical deployment (average score =  $4.67 \pm 0.48$ ). Surgeons indicated that interventional plans (including mild overcorrection) were the preferred treatment strategy for surgical intervention.

### DISCUSSION

Existing methods for automatic planning of FOA do not incorporate overcorrection, which is essential to ensure optimal long-term surgical outcomes.<sup>14</sup> In this work, we presented an automatic method for the interventional planning of FOA that enables surgeons to quantify and incorporate overcorrection into the VSP. The results obtained with a mild overcorrection, which increases MFB by 7mm, provided the closest match to manual VSP provided by surgeons. While the duration of manual VSP ranged between 40 and 75 minutes, automatic VSP was completed in less than 30 seconds. Feedback from

surgeons suggests that the use of CranioPlan software will improve repeatability and reduce the preoperative planning stage duration.

Our approach is based on statistical shape models of the healthy cranium used to calculate patient-specific normative reference shapes. With these, we can define the most appropriate cranial shape to target during interventional planning. This approach eliminates the subjective determination of the normal cranial shape presented by previous techniques.<sup>8,10</sup> Therefore, the combination of normative references and VSP can reduce the variability of surgical outcomes across different surgeons and institutions.

In addition, our method introduces an osteotomy template to automatically estimate the optimal bone fragments for FOA. This template includes the bilateral tenon extensions of the supraorbital bar, which are essential during FOA to facilitate advancement and subsequent stabilization of the remodeled fragments. This study indicates that the automatic estimation of osteotomies is accurate and provides a valuable and objective tool to improve repeatability and reduce the duration of the preoperative planning stage.

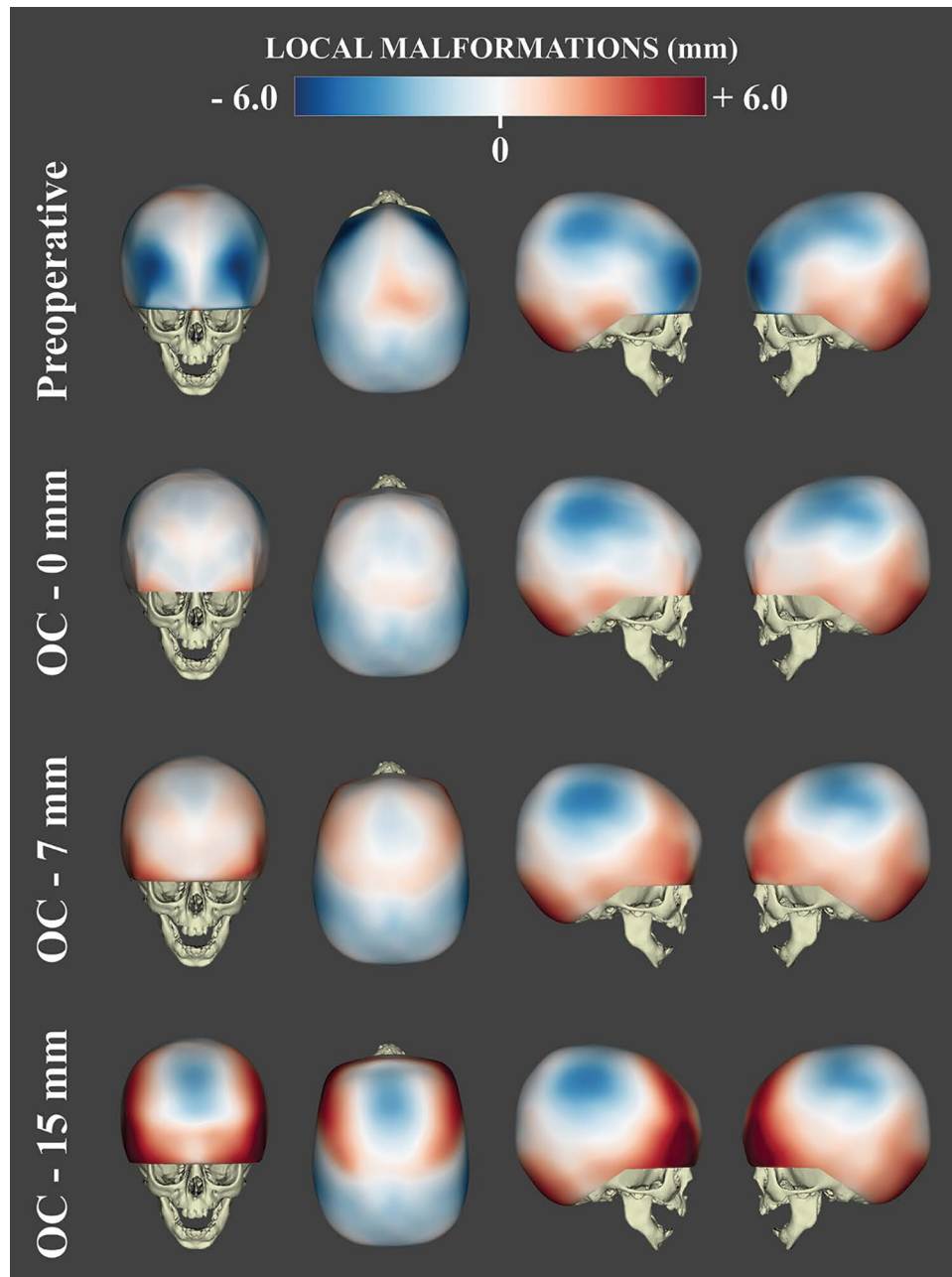
Multiple studies have highlighted the importance of performing overcorrection during craniostylosis treatment to avoid relapse or lack of growth.<sup>15-18</sup> However, there is no consensus between surgeons and institutions on the amount of overcorrection that must be performed to ensure optimal surgical outcomes. Based on the results from previous studies,<sup>14</sup> our planning software automatically estimates overcorrected postoperative cranial shapes based on morphological metrics. CranioPlan provides two predefined overcorrection degrees: mild and severe. Moreover, surgeons can manually input the desired amount of overcorrection, considering the patient clinical history and surgical preferences. This overcorrection can be quantified for later use in surgical outcome analysis. To our knowledge, this is the first tool to consider and apply overcorrection for craniostylosis VSP.

Importantly, our framework for the simulation of osteotomies and cranial remodeling is integrated into a software application (ie, CranioPlan). Although this automatic planning tool provides objective metrics and references, it is not meant to replace the surgeon's clinical judgment or technical skills. Therefore, our software enables surgeons to modify the suggested automatic plan according to their surgical needs and preferences.

The limitations of the current study are primarily related to the automatic reconfiguration of the bone fragments during simulated FOA. Our approach estimates a transformation for each fragment, which may lead to potential overlaps between fragments during the virtual remodeling. However, the defined physical constraints of FOA avoid overlaps; so

**Table 2. Percentage of Overcorrection of Manual and Automatic Virtual Surgical Plans with Respect to Normative Values**

	Percentage of Overcorrection			
	IFA (%)	TFW (%)	MFB (%)	Front. ICV (%)
Manual VSP	$2.97 \pm 2.12$	$3.27 \pm 2.39$	$3.69 \pm 3.62$	$7.75 \pm 8.93$
Automatic OC-0mm	$-0.41 \pm 0.76$	$-0.61 \pm 0.84$	$2.41 \pm 1.73$	$0.66 \pm 0.50$
Automatic OC-7mm	$2.13 \pm 0.80$	$3.29 \pm 0.64$	$7.71 \pm 1.84$	$8.16 \pm 2.19$
Automatic OC-15mm	$6.93 \pm 1.25$	$9.42 \pm 1.33$	$16.99 \pm 2.38$	$24.19 \pm 3.07$



**Fig. 4.** Local malformations of the cranium of a metopic craniosynostosis patient before planning (preoperative), after automatic planning without overcorrection (OC-0mm), after automatic planning with an overcorrection of 7 mm in MFB (OC-7mm), and after automatic planning with an overcorrection of 15 mm in MFB (OC-15mm).

we did not encounter any challenges with the data presented in this study. These constraints may not be suitable for simulating other types of open cranial vault remodeling techniques. In future work, we will integrate global registration algorithms into our framework to account for bone fragment interactions during simulation.<sup>12</sup>

Another limitation of our approach is that it does not address long-term shape maintenance, as that data were not available. However, the quantitative shape analysis software could provide the tools essential for long-term cranial shape evaluation following surgical correction.

The presented method for VSP can be combined with other technologies to further improve the surgical management of craniosynostosis. Patient-specific normative references could be used to perform quantitative evaluation of the local malformations, assisting physicians during diagnosis<sup>21</sup> or postoperative monitoring of surgical outcomes.<sup>13</sup> In addition, an accurate translation of the VSP into the operating room can be assured using novel technological advancements, such as intraoperative 3D photography,<sup>27</sup> optical tracking,<sup>28</sup> and augmented reality.<sup>29</sup>

## CONCLUSIONS

VSP of cranial vault remodeling based on statistical shape models has been demonstrated to be an accurate, automatic, and objective tool to improve the surgical management of craniosynostosis. The use of normative references of the cranium enables the definition of optimal patient-specific shapes to target during preoperative planning. Our solution allows the estimation of osteotomy locations in the fronto-orbital regions, the automatic configuration of the bone fragments to minimize cranial malformations, and the integration of overcorrection to improve long-term surgical outcomes. This technology could reduce the duration of preoperative planning, minimize inter-surgeon variability, and provide consistent and improved surgical outcomes.

Marius George Lingurar, DPhil

Sheikh Zayed Institute for Pediatric Surgical Innovation  
Children's National Health System  
111 Michigan Avenue NW  
Washington, DC 20009

E-mail: mlingura@childrensnational.org

## REFERENCES

- Cohen SR, Frank RC, Meltzer HS, et al. Craniosynostosis. *Handb Craniomaxillofacial Surg.* 2014;343–368.
- Selber J, Reid RR, Gershman B, et al. Evolution of operative techniques for the treatment of single-suture metopic synostosis. *Ann Plast Surg.* 2007;59:6–13.
- Havlik RJ, Azurin DJ, Bartlett SP, et al. Analysis and treatment of severe trigonocephaly. *Plast Reconstr Surg.* 1999;103:381–390.
- Burge J, Saber NR, Looi T, et al. Application of CAD/CAM prefabricated age-matched templates in cranio-orbital remodeling in craniosynostosis. *J Craniofac Surg.* 2011;22:1810–1813.
- Steinbacher DM. Three-dimensional analysis and surgical planning in craniomaxillofacial surgery. *J Oral Maxillofac Surg.* 2015;73(12 Suppl):S40–S56.
- LoPresti M, Daniels B, Buchanan EP, et al. Virtual surgical planning and 3D printing in repeat calvarial vault reconstruction for craniosynostosis: Technical note. *J Neurosurg Pediatr.* 2017;19:490–494.
- Mommaerts MY, Jans G, Vander Sloten J, et al. On the assets of CAD planning for craniosynostosis surgery. *J Craniofac Surg.* 2001;12:547–554.
- Rodt T, Schlesinger A, Schramm A, et al. 3D visualization and simulation of frontoorbital advancement in metopic synostosis. *Childs Nerv Syst.* 2007;23:1313–1317.
- Horvath S, Paniagua B, Andruj J, et al. Osteotomy planner: an open-source tool for osteotomy simulation. In: *Medical Imaging 2018: Image-Guided Procedures, Robotic Interventions, and Modeling.* Houston, Tex: SPIE Medical Imaging. 2018, vol. 10576:654–659.
- Seruya M, Borsuk DE, Khalifian S, et al. Computer-aided design and manufacturing in craniosynostosis surgery. *J Craniofac Surg.* 2013;24:1100–1105.
- Porras AR, Paniagua B, Ensel S, et al. Locally affine diffeomorphic surface registration and its application to surgical planning of Fronto-Orbital advancement. *IEEE Trans Med Imaging.* 2018;37:1690–1700.
- Porras AR, Zukic D, Equobahrie A, et al. Personalized optimal planning for the surgical correction of metopic craniosynostosis. *Clin Image Based Proced.* 2016;2016:60–67.
- Porras AR, Tu L, Tsering D, et al. Quantification of head shape from three-dimensional photography for pre- and post-surgical evaluation of craniosynostosis. *Plast Reconstr Surg.* 2019;144:1051e–1060e.
- Fearon JA, Dithakasem K, Chan WJ, et al. Long-term growth following trigonocephaly repairs: Are overcorrections necessary? *Plast Reconstr Surg.* 2020;145:583e–590e.
- Selber JC, Brooks C, Kurichi JE, et al. Long-term results following fronto-orbital reconstruction in nonsyndromic unicoronal synostosis. *Plast Reconstr Surg.* 2008;121:251e–260e.
- Fearon JA, Ruotolo RA, Kolar JC. Single sutural craniosynostoses: Surgical outcomes and long-term growth. *Plast Reconstr Surg.* 2009;123:635–642.
- Engel M, Castrillon-Oberndorfer G, Hoffmann J, et al. Long-term results in nonsyndromic unilateral coronal synostosis treated with fronto-orbital advancement. *J Craniomaxillofac Surg.* 2013;41:747–754.
- Taylor JA, Paliga JT, Wes AM, et al. A critical evaluation of long-term aesthetic outcomes of fronto-orbital advancement and cranial vault remodeling in nonsyndromic unicoronal craniosynostosis. *Plast Reconstr Surg.* 2015;135:220–231.
- Khechoyan DY, Saber NR, Burge J, et al. Surgical outcomes in craniosynostosis reconstruction: The use of prefabricated templates in cranial vault remodeling. *J Plast Reconstr Aesthetic Surg.* 2014;67:9–16.
- García-Mato D, Pascau J, Ochandiano S. New technologies to improve surgical outcome during open-cranial vault remodeling. *IntechOpen.* 2020:1-19.
- Mendoza CS, Safdar N, Okada K, et al. Personalized assessment of craniosynostosis via statistical shape modeling. *Med Image Anal.* 2014;18:635–646.
- Pieper S, Halle M, Kikinis R. 3D Slicer. *2004 2nd IEEE Int Symp Biomed Imaging Macro Nano.* 2004;1:632–635.
- Kellogg R, Allori AC, Rogers GF, et al. Interfrontal angle for characterization of trigonocephaly: Part 1: Development and validation of a tool for diagnosis of metopic synostosis. *J Craniofac Surg.* 2012;23:799–804.
- Ruiz-Correa S, Starr JR, Lin HJ, et al. New severity indices for quantifying single-suture metopic craniosynostosis. *Neurosurgery.* 2008;63:318–24; discussion 324.
- Mendoza CS, Safdar N, Myers E, et al. An optimal set of landmarks for metopic craniosynostosis diagnosis from shape analysis of pediatric CT scans of the head. *Med Imaging 2013 Comput Diagnosis.* 2013;8670:86702T.
- Wood BC, Mendoza CS, Oh AK, et al. What's in a name? Accurately diagnosing metopic craniosynostosis using a computational approach. *Plast Reconstr Surg.* 2015;137:205–213.
- García-Mato D, García-Sevilla M, Porras AR, et al. Three-dimensional photography for intraoperative morphometric analysis in metopic craniosynostosis surgery. *Int J Comput Assist Radiol Surg.* 2021;16:277–287.
- García-Mato D, Ochandiano S, García-Sevilla M, et al. Craniosynostosis surgery: Workflow based on virtual surgical planning, intraoperative navigation and 3D printed patient-specific guides and templates. *Sci Rep.* 2019;9:17691.
- García-Mato D, et al. Augmented reality visualization for craniosynostosis surgery. *Comput Methods Biomech Biomed Eng Imaging Vis.* 2020;9:392-399.