

Marco Esposito, Sergio Salina, Fabio Rigotti, Cristian Mazzarini, Diego Longhin, Mauro Grigoletto, Jacopo Buti, Luca Sbricoli, Federico Gualini

#### KEY WORDS

dental implant, subcrestal placement, aesthetics, bone levels

Randomised controlled trial

## MULTICENTRE WITHIN-PERSON RANDOMISED CONTROLLED TRIAL OF 0.5 MM *VERSUS* 1.5 MM SUBCRESTAL PLACEMENT OF DENTAL IMPLANTS WITH INTERNAL CONICAL CONNECTION: FIVE-YEAR POST-LOADING RESULTS



#### MARCO ESPOSITO, DDS, PHD

Freelance researcher and Associate Professor, Department of Biomaterials, The Sahlgrenska Academy at Göteborg University, Sweden

#### SERGIO SALINA, DDS

Specialist in Oral Surgery, Private practice in Milan, Italy

#### FABIO RIGOTTI, DDS

Private practice in Verona, Italy

#### CRISTIAN MAZZARINI, DDS

Private practice in Preganziol, Italy

#### DIEGO LONGHIN, DDS

Private practice in Campagna Lupia, Italy

#### MAURO GRIGOLETTO, DDS

Private practice in Noventa Padovana, Italy

#### JACOPO BUTI, DDS, PHD, MPERIO RCSED

Associate Professor, Unit of Periodontology, UCL Eastman Dental Institute, London, UK

#### LUCA SBRICOLI, DDS, PHD

Department of Neurosciences, University of Padua, Padua, Italy

#### FEDERICO GUALINI, MD, DDS, MSD

Private practices in Lovere and Bergamo, Italy

Correspondence to:

Marco Esposito

Casella Postale 34, 20862 Arcore (MB), Italy  
E-mail: espositomarco@hotmail.com

**PURPOSE.** To assess whether there are any clinical benefits to placing single dental implants either 0.5 or 1.5 mm subcrestally in healed bone crests.

**MATERIALS AND METHODS.** Sixty partially edentulous patients at six centres requiring two single implant-supported crowns had both sites randomly allocated according to a split-mouth design to either 0.5 mm or 1.5 mm subcrestal implant placement; implants in aesthetic areas were submerged for 3 months while those in non-aesthetic areas were not. Provisional acrylic crowns were fitted and replaced with definitive metal-ceramic crowns after 2 months. Patients were followed up to 5 years after loading. Outcome measures were: crown and implant failures, complications, aesthetics assessed using the pink esthetic score (PES), peri-implant marginal bone level changes, and patient preference, recorded by blinded assessors.

**RESULTS.** Two patients dropped out. There were no statistically significant differences in failure rate (out of 58 patients, four implants failed in the 0.5 mm group *versus* one in the 1.5 mm group; difference = -5.17%; 95% CI -10.87% to 0.53%;  $P = 0.250$ ) or complications (out of 58 patients eight complications occurred in eight patients from the 0.5 mm group *versus* five complications in five patients from the 1.5 mm group (difference = -5.17%; 95% CI -14.01% to 3.67%;  $P = 0.453$ ) between groups. At 5 years after loading, the mean pink aesthetic scores were  $10.89 \pm 2.30$  and  $10.79 \pm 2.41$  in the 0.5 and 1.5 mm groups, respectively, a difference that was not statistically significant ( $P = 0.943$ ). Patients from the 0.5 mm group lost on average  $0.53 \pm 1.43$  mm peri-implant marginal bone, and those in the 1.5 mm group lost  $0.31 \pm 0.98$  mm, a statistically significant difference (0.26 mm; 95% CI 0.05 to 0.47;  $P = 0.016$ ). Patients did not prefer any depth of implant placement over the other. There were no differences in outcomes between centres.

**CONCLUSIONS.** No clinically appreciable differences were noted when placing implants surrounded by at least 1 mm of bone 0.5 mm or 1.5 mm subcrestally. Clinicians are therefore free to choose which strategy they prefer.

**CONFLICT OF INTEREST STATEMENT.** Anthogyr (Sallanches, France), the manufacturer of the implants used in this investigation, partially funded this trial and donated the implants and prosthesis components; however, all data was the property of the authors, and the sponsor did not interfere with the conduct of the trial or the publication of its results in any way.

## INTRODUCTION

Among the legends circulating in implant dentistry there is the belief that aesthetics can be improved by placing implants in a subcrestal position. The origins of this myth are difficult to track down, but some authors attribute it to Buser<sup>1</sup>. However, his original statement actually referred to ITI transmucosal implants with a polished collar, whose transition portion between the rough section and the polished collar should be placed 1 mm below the bone crest in vertically augmented bone. A dedicated randomised controlled trial (RCT) tested this hypothesis in non-augmented bone<sup>2</sup>, but found no statistically significant differences in peri-implant marginal bone levels or other secondary parameters 1 year after loading. Nevertheless, the authors concluded that “from a biological point of view, the placement of the border between the rough and the smooth surfaces into a subcrestal location should not be recommended”. More recently, another RCT<sup>3</sup> evaluated the influence of the placement level of implants with a laser-microtextured collar design on the outcomes of crestal bone and soft tissue levels in immediate post-extraction implants. Patients were randomly assigned to have implants placed either at the palatal crest or 1 mm subcrestally, and were followed up to 12 months post-surgery (8 months post-loading). No statistically significant differences were observed at 8 months post-loading. The authors concluded that “the level of placement did not influence horizontal and vertical bone and soft tissue changes”.

Another RCT<sup>4</sup> evaluated platform-switched implants with a Morse taper connection, placed at either crestal level or 1 or 2 mm subcrestally. One year after loading, a statistically significant difference of 0.27 mm more bone loss was recorded at crestal implants with respect to those positioned 1 or 2 mm below, but there was no difference between those placed 1 or 2 mm below the crest. However, contrasting results were presented from another RCT<sup>5</sup> in which platform-switched implants were placed at crestal level or 1 mm below the crest. Three years after loading, significantly more bone loss (0.65 mm) was observed at implants placed 1 mm subcrestally as compared to crestally placed implants, but there was no difference in any of the remaining parameters evaluated. In another RCT<sup>6</sup>, on two different implant types, no significant differences in bone levels or other parameters were found for implants placed crestally or 1.5 to 2 mm subcrestally. However, the follow-up was only 3 months, and the implants were not even loaded, so no meaningful conclusions could be drawn. Finally, in an RCT comparing single transmucosal implants placed crestally *versus* 1.5 mm subcrestally in 80 patients 4 months after loading, no statistically significant differences were observed<sup>7</sup>.

The lack of firm evidence on this issue prompted us to investigate whether better aesthetic and/or clinical outcomes could be achieved by placing implants 1.5 mm subcrestally, or whether similar results can be obtained by placing implants 0.5 mm subcrestally. Hence, we designed a multicentre RCT to compare outcomes after placing single dental implants either 0.5 or 1.5 mm subcrestally in healed bone crests. This report presents data at 5 years after loading, and is the third in a series; previous publications have presented 1-<sup>8</sup> and 3-year<sup>9</sup> post-loading data. This article has been drafted according to the CONSORT statement (<http://www.consort-statement.org/>) and its extension checklist for reporting within-person randomised trials (<http://www.consort-statement.org/extensions/overview/withinperson>).

## MATERIALS AND METHODS

### Trial design

This was a multicentre randomised controlled trial (RCT) of split-mouth design and blind assessment. Each patient received two identical implants: the test implant was placed 1.5 mm below the crest (test implant) and the control implant 0.5 mm subcrestally (control implant).

## PATIENT SELECTION

Any patient requiring at least two single implant-supported crowns in any jaw location, being at least 18 years old and able to understand and sign an informed consent form, was eligible for inclusion. The two implant sites could be adjacent, but had to allow the placement of two implants of length at least 6.5 mm and width at least 3.4 mm wide leaving at least 1 mm of bone around the implant. For patients with more than two suitable implant sites, the operator chose those two sites with the most similar characteristics at the screening appointment. The operator coded the selected sites as implant site number 1 and implant site number 2.

Exclusion criteria were:

- General contraindications to implant surgery;
- Immunosuppression or immunocompromised;
- Irradiation to the head and/or neck area;
- Uncontrolled diabetes;
- Pregnancy or lactation;
- Untreated periodontitis;
- Poor oral hygiene and motivation;
- Substance abuse;
- Psychiatric disorders;
- Unrealistic expectations;
- Acute infection or suppuration at any of the sites intended for implant placement;
- Need for any type of bone augmentation at implant placement;
- Post-extraction sites (implants could, however, be inserted after a healing period of at least 5 months);
- Unable to commit to 5-year post-loading follow-up;
- Previous or ongoing treatment with intravenous aminobisphosphonates;
- Referral for implant placement alone, i.e., unavailable for follow-up at the treatment centre;
- Participation in other clinical studies if the present protocol could not be fully adhered to.

Patients were divided into three groups based on the number of cigarettes they declared smoking per day: i) non-smokers, ii) moderate smokers (up to 10 cigarettes per day) and iii) heavy smokers (more than 10 cigarettes per day).

Equal numbers of patients were recruited and treated by six different doctors, namely Salina, Gualini, Rigotti, Mazzarini, Longhin and Grigoletto, from private practices located in Northern Italy using similar and standardised procedures. Each clinician treated ten patients. Prior to enrolment, all patients were asked to read and sign an informed consent form to document that they understood the scope of the study (including procedures, follow-up evaluations, and any potential risks involved); all were allowed opportunities to ask questions pertaining to this study, and were apprised of treatment alternatives. The study was open to any qualifying patients, regardless of sex or race.

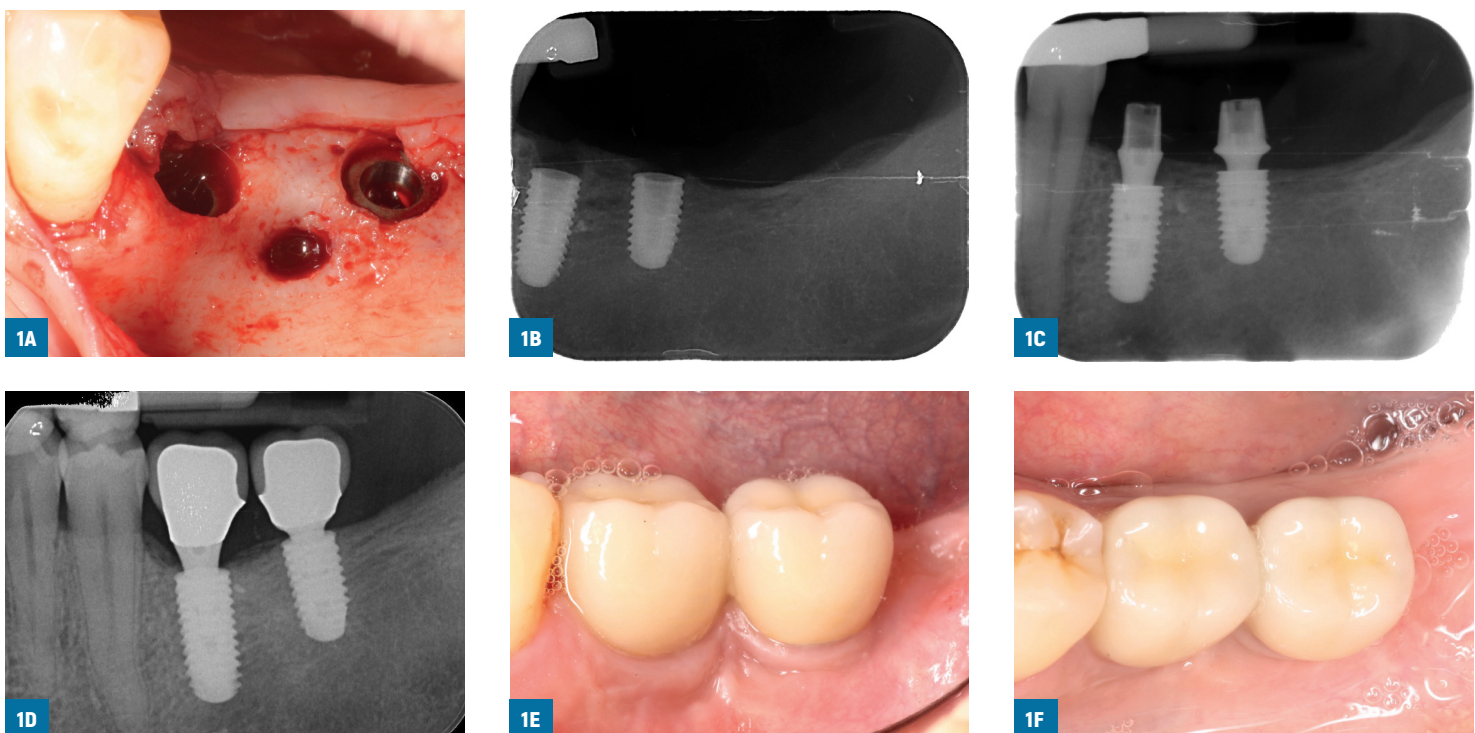
## Clinical procedures

Preoperative radiographs were taken. Investigators were free to choose the most appropriate means according to the clinical case, i.e., either periapical, panoramic and/or cone-beam computed tomography (CBCT). All patients underwent at least one oral hygiene session within the 10 days prior to the implantation procedure.

Patients received a single dose of prophylactic antibiotic 1 hour before the intervention: 2 g of amoxicillin or 500 mg of clarithromycin, if allergic to penicillin. Patients rinsed with chlorhexi-

dine mouthwash 0.2% for 1 minute prior to the intervention. Patients were treated under local anaesthesia using articaine with adrenaline 1:100,000. No intravenous sedation was used. After crestal incision and flap elevation, the sequentially numbered sealed envelope corresponding to the patient recruitment number was opened, and implant site number 1 was treated as per the instruction in the envelope. Consequently, the other intervention was performed at implant site number 2, according a split-mouth design (**FIGS. 1A-F**). The two study implants were placed in the same surgical session following similar procedures, and were restored simultaneously with similar single crowns. Bone quality was subjectively quantified at drilling as: 'hard', 'medium' or 'soft'. Implant sites were prepared using drills with increasing diameters, as suggested by the implant manufacturer, and burs at different depths according to the random allocation. Hard bone was tapped. Tapered titanium alloy (Ti6Al4V-ELI acc. to ISO5832-3) Axiom REG implants (Anthogyr, Sallanches, France) with internal Morse taper connection and platform switching were placed; their surface is sand-blasted with BCP bioceramics consisting of a mixture of hydroxyapatite (HA) and  $\beta$ -TCP (beta-tricalcium phosphate), and then subjected to mild acid treatment. Operators were free to use implants of diameters 3.4 mm (8.0, 10.0, 12.0 and 14.0 mm long), 4.0 mm, 4.6 mm or 5.4 mm (6.5, 8.0, 10.0, 12.0 and 14.0 mm long), according to clinical indications and their preferences.

In line with the random allocation, the neck of each implant was sunk either 0.5 mm or 1.5 mm subcrestally using the most apical peak of the surrounding bone as a reference point. Periapical radiographs were taken, and if the peri-implant marginal bone levels were difficult to assess, another periapical radiograph was taken. Implants in aesthetic areas were submerged, and implants in non-aesthetic areas received transmucosal healing abutments. Ibupro-



**FIGS. 1A-F:** Treatment sequence of a representative patient (treated by Dr. Salina): site 36 was randomly allocated to receive an implant with the neck placed 1.5 mm below the crest, and site 37 at 0.5 mm (A); postoperative baseline periapical radiograph clearly showing the difference in depth positioning (B); periapical radiograph at initial loading (C); periapical radiograph (D), and vestibular (E) and occlusal views (F) at 5 years after loading. Typically bone levels repositioned at the implant-abutment connection.

fen 400 mg was prescribed to be taken 2 to 4 times a day during meals, for as long as required; in the event of stomach issues or allergy to non-steroidal anti-inflammatory drugs, 1g of paracetamol was recommended instead. Patients were instructed to use 0.2% chlorhexidine mouthwash for one minute twice a day for 2 weeks, and to avoid brushing and possible trauma to the surgical sites. A soft diet was recommended for 2 weeks. After 1 week, patients were checked and sutures were removed. Implants were left to heal unloaded for 3 months; then submerged implants were exposed, and the stability of individual implants was assessed by torquing the abutment screws at 25 Ncm. Impressions were taken at implant level, provisional crowns on provisional titanium abutments were fitted, periapical radiographs were taken, and oral hygiene instructions were delivered. Exactly the same procedures were implemented at both implants. After 2 months, the following definitive standard straight titanium abutments lengths were used: 1.5, 2.5, 3.5 and 4.5 mm (OPST abutments, Anthogyr). The abutment shoulder was selected to be 0.5 to 1 mm shorter than the buccal gingival margin. The diameters of healing caps and definitive abutments used were 5 mm for implants replacing molars, and 3.4 or 4.0 mm for implants replacing other teeth, according to the clinician's assessment. The provisional restorations were replaced by definitive metal-ceramic crowns provisionally cemented on definitive standard straight titanium abutments. Implant stability was assessed, and vestibular and occlusal pictures of the study implants, including one adjacent tooth per side, were taken, together with standardised periapical radiographs of the study implants, which were to be taken using an individual stent. Oral hygiene motivation was reinforced, and patients were recalled every 6 months for check-up and hygiene for the entire duration of the study. Dental occlusion was evaluated at each visit.

### Outcome measures

This study tested the null hypothesis that there would be no differences in clinical outcomes between the two procedures against the alternative hypothesis of a difference.

Outcome measures were the following.

- Implant/crown failures: implant mobility, removal of stable implants dictated by progressive marginal bone loss or infection, or any mechanical complications rendering the implant unusable (e.g., implant fracture) were considered implant failures. If a definitive crown had to be replaced for any reason, it was counted as a crown failure. Stability of individual implants was measured at the fitting of definitive crowns, 2 months after implant placement, applying a reverse torque of 20 Ncm with a dedicated wrench. Implant stability was re-assessed at 1, 3, and 5 years after loading using the metal handles of two instruments.
- Any biological or biomechanical complications: e.g., fistula or peri-implantitis (biological complications), or abutment screw fracture or loosening (biomechanical complications).
- Peri-implant marginal bone level changes evaluated on periapical radiographs taken with the paralleling technique at implant placement, initial loading, and at 1, 3, and 5 years after loading. In the event of a non-measurable radiograph, a second radiograph was taken. Non-digital radiographs were scanned into TIFF format at 600 dpi resolution, and stored on a personal computer. Peri-implant marginal bone levels were measured using ImageJ software, version 1.48 (NIH, Bethesda, MD, USA). The software was calibrated for each single image using the known distance between the two most coronal consecutive threads and/or the nominal implant diameter. Measurements of the mesial and distal bone crest levels adjacent to each implant were made to the nearest 0.01 mm. Reference points for the linear measurements were the coronal margin of the implant collar and the most coronal point of visible bone-to-implant contact. When the bone was coronal to

the implant collar, a zero value was given. The measurements at mesial and distal sides of each implants were averaged per implant and then per group. All radiographic measurements were made by a single blinded dentist (Dr. Sbricoli).

- Aesthetic evaluation of the vestibular and occlusal clinical pictures, including one adjacent tooth per side, taken at fitting of the definitive crowns (2 months after initial loading), and at 1, 3, and 5 years after loading, was performed on a computer screen by a blinded dentist (Dr. Sbricoli). The aesthetic assessment was made using the pink esthetic score (PES)<sup>10</sup>; in brief, seven variables were evaluated: mesial papilla, distal papilla, soft tissue level, soft tissue contour, alveolar process deficiencies, soft tissue colour and texture. A 0-1-2 scoring system was used, 0 being the lowest and 2 being the highest value, with a maximum achievable score of 14 per implant.
- Patient preference. One, 3, and 5 years after loading, local blind outcome assessors provided a mirror to patients, indicated both implant-supported crowns, and asked them which crown they preferred. Possible patient answers were: i) crown at implant site number 1; ii) crown at implant site number 2; iii) I like both crowns the same; iv) I dislike both crowns. Patients could also add comments if they wanted.

At each centre there was a local blind outcome assessor who assessed implant stability and recorded patient preference. One blinded dentist (Dr. Sbricoli), not involved in the treatment of the patients, evaluated both aesthetic and marginal bone levels, without knowing group allocation. Complications were handled and reported directly by the treating clinicians, who were not blinded.

### Sample size, randomisation and allocation concealment

No sample size calculation was performed, but it was agreed to recruit 60 patients, 10 at each of the six centres participating in this trial. Six computer-generated restricted randomisation lists were created. Only one investigator (Dr. Esposito), who was not involved in the selection and treatment of the patients, knew the random sequence and had access to the randomisation list, which was stored on a password-protected laptop computer. The randomisation codes were enclosed in sequentially numbered, identical, opaque, sealed envelopes. After flap elevation, the envelope corresponding to the patient recruitment number was opened, and implant site number 1 was allocated to the group indicated in the envelope (either 0.5 or 1.5 mm), with the other site to receive the other intervention. Therefore, treatment allocation was concealed to the investigators in charge of enrolling and treating the patients.

### Statistical analysis

All data analysis was performed according to a pre-established analysis plan by a dentist (Dr. Buti) with expertise in statistics, who analysed the data without knowing the group codes. The implant sites were the statistical units of the analyses. Differences between groups in crown/implant failures and complications (dichotomous outcomes) were compared using a McNemar test. Differences between groups in continuous outcomes (mean marginal bone level changes and aesthetics, as assessed by a dentist) were compared using a paired t-test. Patients with one implant failure were excluded. Comparisons between the various follow-up endpoints and baseline measurements were made using paired t-tests to detect any changes in mean marginal bone level changes in each group. Differences between centres for continuous outcomes were analysed via ANOVA followed by Tukey's HSD post-hoc test to detect differences between groups. For categorical outcomes, the chi-squared test or Fisher's Exact test were used, depending on the count per cell (small cell sizes with values of less than 5).

Zero cells were handled by adding 0.5 to each of the cells, and then the odd's ratio was calculated over these adjusted cell counts (Haldane-Anscombe correction). All statistical comparisons were conducted at the 0.05 level of significance.

## RESULTS

Sixty-three patients were screened at the six centres, and 60 patients were consecutively enrolled in the trial. Three patients were not included because they did not want to participate in the study. All patients were treated according to the allocated interventions. Two patients dropped out. One did not want to come back after the delivery of the provisional crowns (Dr. Longhin), and the other was last seen at the 3-year follow-up, subsequently refusing to come back for 5-year follow-up, most likely because she changed dentist (Dr. Grigoletto). Periapical radiographs of both implants in one patient could not be taken at either 2 months or 1 year after loading because she was pregnant at both timepoints (Dr. Rigotti); however at bone level assessment 3 years after loading no bone loss had occurred, so it was possible to estimate with extreme precision the bone levels on the missing radiographs, and the missing data (0 value) were imputed. The data from all patients was included in the statistical analyses. The main deviations from the protocol were the following.

- The centres, at protocol stage, specifically requested that standardised periapical radiographs be taken using customised stents. This request was not considered necessary by the study coordinator, but was nevertheless incorporated into the protocol. However, after treatment of the first cases, the use of radiographic stents was discontinued due to difficulties in repositioning them over time.
- In one patient, both definitive crowns were placed 11 months after loading, because the patient had health problems and did not come back for the check-up (Dr. Salina).
- In one patient both definitive crowns were placed 9 months after the provisional crowns. The definitive crown fitting, 9 months after loading, was considered as the 1-year post-loading appointment (Dr. Rigotti).
- In one patient only, a customised monoblock abutment (OPRM100, Anthogyr) was used instead of a standard abutment at the implant placed 1.5 mm below the crest (Dr. Salina). At 4 and a half years after loading, this implant (46) was used as pilaster for a partial fixed implant-supported prosthesis (46–44) when the implant from the 0.5 mm group in position 45 failed.
- One patient was seen with a 6-month delay with respect to the 5-year follow-up because of the lockdown caused by the COVID-19 pandemic (Dr. Gualini).

Patients were recruited and received implants from June 2013 to April 2015. The follow-up of all patients remaining in the study was to 5 years after implant loading. There were 34 females and 26 males, with a mean age of 53.4 years (range 28 to 81). There were 47 non-smokers, six moderate smokers, and seven patients who smoked more than 10 cigarettes per day. Implant characteristics by study group are described in **TABLE 1**. There were no apparent significant baseline imbalances between the two groups.

- Crown and implant failures: four implants failed in the 0.5 mm group *versus* one in the 1.5 mm group, the difference in proportions of implant failures between groups was not, however, statistically significant (difference = -5.17%; 95% CI -10.87% to 0.53%; P [Exact McNemar's test] = 0.250). More specifically, two implants failed, one per group, in the same patient. Both implants were initially loaded with provisional crowns, displayed a fistula, were found to be mobile at definitive impression taking, and were consequently

**TABLE 1** INTERVENTION CHARACTERISTICS

	<b>0.5 mm N = 60</b>	<b>1.5 mm N = 60</b>
Implants in the central incisor position	0	0
Implants in the lateral incisor position	0	0
Implants in the canine position	1 (1.7%)	0
Implants in the first premolar position	7 (11.7%)	9 (15%)
Implants in the second premolar position	15 (25%)	16 (26.7%)
Implants in the first molar position	31 (51.7%)	30 (50%)
Implants in the second molar position	5 (8.3%)	5 (8.3%)
Implants in the third molar position	1 (1.7%)	0
Implants in maxillae	17 (28.3%)	15 (25%)
Implants in mandibles	43 (71.7%)	45 (75%)
Implants of diameter 3.4 mm	21 (35%)	21 (35%)
Implants of diameter 4.0 mm	35 (58.3%)	35 (58.3%)
Implants of diameter 4.6 mm	2 (3.3%)	3 (5%)
Implants of diameter 5.2 mm	2 (3.3%)	1 (1.7%)
Implants of length 6.5 mm	6 (10%)	8 (13.3%)
Implants of length 8.0 mm	24 (40%)	30 (50%)
Implants of length 10.0 mm	28 (46.7%)	22 (36.7%)
Implants of length 12.0 mm	2 (3.3%)	0
Implants of length 14.0 mm	0	0
Abutment of length 1.5 mm	33 (55%)	19 (31.7%)
Abutment of length 2.5 mm	20 (33.3%)	31 (51.7%)
Abutment of length 3.5 mm	7 (11.7%)	10 (16.7%)
Abutment of length 4.5 mm	0	0
Abutment of diameter 3.4 mm	4 (6.7%)	1 (1.7%)
Abutment of diameter 4.0 mm	31 (51.7%)	37 (61.7%)
Abutment of diameter 5.0 mm	23 (38.3%)	21 (35%)
Abutment of diameter 6.0 mm	2 (3.3%)	1 (1.7%)
Soft bone quality	8 (13.3%)	6 (13.3%)
Medium bone quality	31 (51.7%)	34 (56.7%)
Hard bone quality	21 (35%)	20 (33.3%)

removed. Both failed implants were successfully replaced, but the data pertaining to the replaced implants was not recorded, being beyond the scope of the present study. The other three implant failures in the 0.5 mm group were caused by peri-implantitis occurring at 3 years and 1 month, 4 and a half years, and 5 years after loading, respectively, all at implants that had manifested previous peri-implantitis. In addition to crown failures that occurred in relation to implant failures, one additional crown from the 1.5 mm group had to be remade as a partial fixed prosthesis because of the failure of the adjacent mesial implant from the 0.5 mm group.



— Complications: there was no statistically significant difference between the two groups in the number of patients experiencing complications (difference = -5.17%; 95% CI -14.01% to 3.67%; P [McNemar test] = 0.453); eight complications occurred in eight patients from the 0.5 mm group *versus* five complications in five patients from the 1.5 mm group. Three patients had both implants affected by the same complications. In the 0.5 mm group, one patient (ID = 13) had permanent post-operative paraesthesia at the implant in position 36. One patient (ID = 33) presented a fistula and implant mobility in position 14 at the time of definitive impression taking; it was removed and successfully replaced. Exactly the same problem arose at the other implant in the same patient. Another patient (ID = 27) displayed inflammation around the implant in position 46 at time of abutment connection, which resulted in bone loss at 1 year after loading (peri-implantitis). She was treated via light scaling using a piezoelectric device (Mectron, Carasco, Italy) with a polytetrafluoroethylene (PTFE) tip and curettes, saline irrigation, and injection of a solution of tetracycline hydrochloride (Ambramicina, 250 mg, Scharper, Milan, Italy). This treatment was repeated after 2 weeks. One patient (ID = 5) had an episode of peri-implant mucositis at the implant in position 27 (pocket depth palatally = 4.5 mm). The patient was immediately treated via light ultrasound treatment using polytetrafluoroethylene (PTFE) tips and one application of an 810 nm diode laser (1.2 watts for 1 min x 3 times) with simultaneous irrigation of 3% H<sub>2</sub>O<sub>2</sub>. The peri-implant sulcus was then filled with 0.5% chlorhexidine gel (Oralsan, IDS, Genoa, Italy), and azithromycin (Zitromax, Pfizer, Latina, Italy) 500 mg (one tablet per day for 3 days) was prescribed. The situation returned to normal in 20 days. The patient was recalled monthly for 6 months. One patient (ID = 17) was affected by peri-implantitis 1 and a half years after loading at both implants, which were adjacent to each other. Both implants were surgically debrided, and the frequency of maintenance recalls was increased. Marginal peri-implant bone at both implants stabilised for several years, but at the 5-year follow-up peri-implantitis was again evident and the long-term prognosis of both implants remains doubtful. One patient (ID = 8) showed peri-implant bone resorption 2 years after loading. There was no inflammation so no treatment was prescribed, but at 4 and a half years after loading the bone loss had increased (peri-implantitis) and the implant was removed. One patient (ID = 10) was affected by peri-implant mucositis at both implants 2 years after loading, and was treated with ultrasound debridement, laser, H<sub>2</sub>O<sub>2</sub> irrigation, and local application of doxycycline (Ligosan 140 mg, Heraeus Kulzer, Milan, Italy). The situation stabilised but the peri-implant soft tissue remained inflamed. Finally, 43 months after loading, one patient (ID = 40) had a small ceramic fracture at implant 35, which was repaired by a dental technician.

Complications reported for patients in the 1.5 mm group were: one patient (ID = 29) lost the cover screw at implant 36 one week after its placement; the soft tissues covered the implant and no treatment was necessary. In another patient, a fistula was present at a mobile implant in position 15; this and the adjacent implant were lost (ID = 33). One patient (ID = 10) was affected by peri-implant mucositis at both implants, but was successfully treated as previously described. One patient (ID = 17) was affected by peri-implantitis at both study implants 1 and a half years after loading, and was treated as previously described. Finally, 45 months after loading one patient (ID = 39) was affected by peri-implant mucositis at implant 47; this disappeared after abutment/crown replacement with a healing abutment for 3 weeks.

— Aesthetics: two months after loading, at definitive prostheses fitting, the average total PES score, as assessed by a blind assessor, was 11.22 ± 1.91 in the 0.5 mm group and 11.12 ± 1.59 in the 1.5 mm group, the difference not being statistically significantly (P [paired

t-test) = 0.626). There were also no statistically significant differences between the two groups when evaluating the individual aesthetic domains. Five years after loading, the average PES score was  $10.89 \pm 2.30$  for the 0.5 mm group and  $10.79 \pm 2.41$  for the 1.5 mm group, the difference not being statistically significantly different (P (paired t-test) = 0.943; **TABLE 2**). In this case too, assessment of the individual aesthetic domains revealed no statistically significant difference between the two groups (**TABLE 2**).

— Patient preference was assessed at definitive crown fitting (2 months after initial loading), and at 1, 3 and 5 years after initial loading, but only in those patients who did not experience any implant failure. At fitting of the definitive crowns, 57 patients expressed no particular preference (liking both crowns equally), but one patient preferred the crown at the implant positioned 1.5 mm subcrestally. At 5 years after loading, 53 patients had no preference (liking both crowns equally), and one patient preferred the crown on the implant placed 0.5 mm subcrestally.

**TABLE 2** PES SCORES AT 5 YEARS AFTER LOADING BY GROUP AND BY DIFFERENT AESTHETIC DOMAIN (SD IN PARENTHESIS)

	Mesial papilla	Distal papilla	Soft tissue level	Soft tissue contour	Alveolar process deficiencies	Soft tissue colour	Soft tissue texture	Total PES score
0.5 mm deep N = 54	1.52 (0.67)	0.98 (0.63)	1.5 (0.54)	1.67 (0.58)	1.72 (0.49)	1.65 (0.52)	1.85 (0.36)	10.89 (2.30)
1.5 mm deep N = 57	1.47 (0.71)	1.04 (0.71)	1.53 (0.57)	1.67 (0.58)	1.63 (0.49)	1.67 (0.51)	1.79 (0.41)	10.79 (2.41)
Difference [95% CI]	-0.06 [-0.34 to 0.23]	0.09 [-0.09 to 0.28]	0.04 [-0.09 to 0.17]	0.02 [-0.14 to 0.17]	-0.07 [-0.18 to 0.03]	0.02 [-0.08 to 0.12]	-0.06 [-0.15 to 0.04]	-0.02 [-0.54 to 0.50]
P-value (paired t-test)	0.700	0.322	0.569	0.811	0.159	0.709	0.261	0.943

**TABLE 3** MEAN RADIOGRAPHIC PERI-IMPLANT MARGINAL BONE LEVELS AND CHANGES BETWEEN GROUPS AND TIME PERIODS UP TO 5 YEARS AFTER LOADING

	Implant placement	Loading	2 months post loading	1 year post-loading	3 years post-loading	5 years post-loading
	N Mean (SD) [95% CI]	N Mean (SD) [95% CI]	N Mean (SD) [95% CI]	N Mean (SD) [95% CI]	N Mean (SD) [95% CI]	N Mean (SD) [95% CI]
0.5 mm deep	60 All implants = 0	59 0.07 (0.21) [0.01, 0.12]	58 0.16 (0.39) [0.06, 0.26]	58 0.21 (0.51) [0.07, 0.34]	58 0.34 (0.87) [0.12, 0.57]	55 0.53 (1.43) [0.14; 0.91]
1.5 mm deep	60 All implants = 0	59 0.04 (0.13) [0.01, 0.07]	58 0.10 (0.38) [-0.01, 0.20]	58 0.11 (0.36) [0.02, 0.21]	58 0.19 (0.54) [0.05, 0.33]	57 0.31 (0.98) [0.05; 0.57]
Difference [95% CI]	0	0.03 [-0.02, 0.07]	0.06 [-0.02, 0.15]	0.10 [-0.01, 0.20]	0.15 [0.00, 0.30]	0.26 [0.05; 0.47]
P-value	1.000	0.209	0.152	0.078	0.046*	0.016*

\*Statistically significant difference All changes from baseline statistically different (P < 0.05). When available, radiographs of failed implants were also measured.

— Peri-implant marginal bone levels (**TABLE 3**). At baseline, all bone level measures in both groups equalled 0. At 5 years post-loading, peri-implant marginal bone level/loss was  $0.53 \pm 1.43$  mm at 0.5 mm implants and  $0.31 \pm 0.98$  mm at 1.5 mm implants, the difference being statistically significant (difference = 0.26 mm; 95% CI 0.05 to 0.47; P [paired t-test] = 0.016).

A comparison of the six centres is presented in **TABLE 4**. At 5 years post-loading there were no statistically significant differences among centres.

## DISCUSSION

This trial was designed to evaluate whether it would be more advantageous to place implants 1.5 mm as opposed to 0.5 mm subcrestally. Only one statistically significant difference was noted up to 5 years after loading, namely 0.26 mm more peri-implant marginal bone loss at implants placed 0.5 mm below the crest. This difference may not be clinically significant, however, and suggests that the choice of whether to sink dental implants subcrestally or not is irrelevant, at least at the depths evaluated in the present trial; therefore, clinicians should feel free to choose to place implants at the depth (0.5 or 1.5 mm) they prefer. That being said, one purely logical consideration ought to be made: it might be sensible to place implants at a depth of 0.5 mm in order to be able to fully use 1 mm more of bone support, especially in patients with limited bone heights. Ideally, we should have also tested the placement of identical implants at crestal level or even slightly supracrestally in the same trial, in order to provide a complete overview of the relationships between implant position and aesthetic outcomes, as well other potentially clinically relevant parameters. However, it cannot be excluded that the difference in bone loss could increase over time, so longer follow-up of the same patient cohort will be necessary to test this.

Nonetheless, our current findings are in line with those of similar RCTs<sup>2-4,7</sup> testing the same hypothesis, even though implants of different design were used, such as transmucosal implants<sup>27</sup>. However, in the other RCTs, when implants were crestally placed, some statisti-

**TABLE 4** COMPARISON OF CLINICAL OUTCOMES AMONG THE SIX CENTRES AT 5 YEARS AFTER LOADING

	Salina	Gualini	Rigotti	Mazzarini	Longhin	Grigoletto	P-value
Drop-out	0/10	0/10	0/10	0/10	1/10	1/10	1.000
Crown failures	2/20	0/20	1/20	2/20	0/18	0/18	0.421
Implant failures	2/20	0/20	1/20	2/20	0/18	0/18	0.421
Complications	4/20	3/20	2/20	4/20	0/18	0/18	0.111
5-year PES score, 0.5 mm group	$10.88 \pm 1.46$	$11.5 \pm 2.92$	$12.22 \pm 0.83$	$10.33 \pm 2.12$	$10.22 \pm 3.03$	$10.11 \pm 2.26$	0.305
5-year PES score, 1.5 mm group	$10.5 \pm 1.58$	$11 \pm 3.20$	$11.7 \pm 0.95$	$10.56 \pm 1.94$	$10.89 \pm 3.59$	$10 \pm 2.60$	0.761
5-year peri-implant bone loss, 0.5 mm group	$0.66 \pm 1.75$	$0.99 \pm 2.62$	$0.28 \pm 0.66$	$0.06 \pm 0.17$	$1.01 \pm 1.19$	$0.12 \pm 0.19$	0.546
5-year peri-implant bone loss, 1.5 mm group	$0.38 \pm 0.66$	$0.68 \pm 2.08$	$0.36 \pm 0.76$	$0 \pm 0$	$0.38 \pm 0.59$	$0.01 \pm 0.03$	0.676
Patients with no preference	8/8	10/10	9/9	8/9	9/9	9/9	0.815

cally significant differences in bone loss were reported. For instance, one RCT<sup>4</sup>, evaluating platform-switched implants with a Morse taper connection placed crestally with respect to 1 and 2 mm subcrestally reported 0.27 mm more bone loss for crestal implants 1 year after loading. Surprisingly, however, another RCT<sup>5</sup> that compared platform-switched implants placed crestally or 1 mm below reported 0.65 mm more bone loss at subcrestal implants 3 years after loading. Nevertheless, there is no evidence that such small differences in bone loss affects aesthetics or any other clinical parameter. In other words, the subcrestal positioning of implants 0.5 or 1.5 mm in healed sites leads to no clinically appreciable consequences for patients.

In the present trial, no statistically significant differences between implants positioned 0.5 or 1.5 mm subcrestally nor trends were observed for aesthetics evaluated using the PES up to 5 years after loading. This could be interpreted as both procedures achieving a similar aesthetic outcome. However, it is interesting to observe that aesthetics slightly improved between month 2 and month 12 post-loading, especially at the mesial and distal papillae, suggesting that some sort of creeping attachment phenomenon occurred after fitting of the definitive crowns, meaning that the peri-implant soft tissues gradually grew around the crowns<sup>8</sup>. This improvement remained stable up to the third year after loading, but regressed to baseline values at 5 years post-loading.

While comparing clinical outcomes among different centres, there were no statistically significant differences in terms of implant failures, complications, or peri-implant marginal bone level changes, though the sample was too small to detect potential differences among operators.

Since in the present investigation both procedures were tested under real clinical conditions, and patient inclusion criteria were broad, results can be generalized with confidence to a wider population with similar characteristics.

## CONCLUSIONS

No clinically appreciable differences were noted when placing implants 0.5 mm *versus* 1.5 mm subcrestally when they were surrounded by at least 1 mm of bone, and clinicians can therefore choose the option they prefer.

## Acknowledgments

We wish to thank the following local outcome assessors for their help with this study: Dr. Roberto Ringoli, Dr. Piero Gualini, Dr. Mandy Pen Shui, Dr. Martina Furlanetto, Dr. Alberto Celon and Dr. Giulia Piccirilli.

## REFERENCES

1. Buser D, Dula K, Belser U, Hirt H-P, Berthold H. Localized ridge augmentation using guided bone regeneration. I. Surgical procedure in the maxilla. *Int J Periodontics Restorative Dentistry* 1993;13:29-45.
2. Hämmerle CHF, Brägger U, Bürgin W, Lang NP. The effect of subcrestal placement of the polished surface of ITI implants on marginal soft and hard tissues. *Clinical Oral Implants Research* 1996;7:111-9.
3. Koh RU, Oh TJ, Rudek I, Neiva GF, Misch CE, Rothman ED, Wang HL. Hard and soft tissue changes after crestal and subcrestal immediate implant placement. *J Periodontology* 2011;82:1112-20.

4. Koutouzis T, Neiva R, Nonhoff J, Lundgren T. Placement of implants with platform-switched Morse taper connections with the implant-abutment interface at different levels in relation to the alveolar crest: a short-term [1-year] randomized prospective controlled clinical trial. *Int J Oral Maxillofacial Implants* 2013;28:1553-63.
5. Kutan E, Bolukbasi N, Yildirim-Ondur E, Ozdemir T. Clinical and radiographic evaluation of marginal bone changes around platform-switching implants placed in crestal or subcrestal positions: a randomized controlled clinical trial. *Clinical Implant Dentistry Related Research* 2015;17[Suppl. 2]:e364-75.
6. Palaska I, Tsaousoglou P, Vouros I, Konstantinidis A, Menexes G. Influence of placement depth and abutment connection pattern on bone remodeling around 1-stage implants: a prospective randomized controlled clinical trial. *Clinical Oral Implants Research* 2016;27:e47-56.
7. Barausse C, Esposito M, Colombelli F, Bellini P, Buti J, Felice P. Crestal or 1.5 mm subcrestal positioning of transmucosal dental implants with cemented or screw-retained crowns in posterior jaws: 4-month data from a single-centre randomised controlled trial. *Clinical Trials Dentistry* 2020;2:19-33.
8. Gualini F, Salina S, Rigotti F, Mazzarini C, Longhin D, Grigoletto M, Trullenque-Eriksson A, Sbricoli L, Esposito M. Subcrestal placement of dental implants with an internal conical connection of 0.5 mm *versus* 1.5 mm: outcome of a multicentre randomised controlled trial 1 year after loading. *European J Oral Implantology* 2017;10:73-82.
9. Salina S, Gualini F, Rigotti F, Mazzarini C, Longhin D, Grigoletto M, Buti J, Sbricoli L, Esposito M. Subcrestal placement of dental implants with an internal conical connection of 0.5 mm *versus* 1.5 mm: three-year after loading results of a multicentre within-person randomised controlled trial. *Int J Oral Implantol* 2019;12:155-67.
10. Fürhauser R, Florescu D, Benesch T, Haas R, Mailath G, Watzek G. Evaluation of soft tissue around single-tooth implant crowns: the pink esthetic score. *Clinical Oral Implants Research* 2005;16:639-44.