

<https://helda.helsinki.fi>

Recording of Proprioceptive Muscle Reflexes in the Lower Extremity

Partanen, Juhani

IntechOpen
2021

Partanen , J , Sompa , U & Muñoz-Ruiz , M 2021 , Recording of Proprioceptive Muscle Reflexes in the Lower Extremity . in J A Vega & J Cobo (eds) , Proprioception . IntechOpen , Rijeka . <https://doi.org/10.5772/intechopen.95575>

<http://hdl.handle.net/10138/350091>

<https://doi.org/10.5772/intechopen.95575>

unspecified
publishedVersion

Downloaded from Helda, University of Helsinki institutional repository.

This is an electronic reprint of the original article.

This reprint may differ from the original in pagination and typographic detail.

Please cite the original version.

We are IntechOpen, the world's leading publisher of Open Access books Built by scientists, for scientists

6,000

Open access books available

148,000

International authors and editors

185M

Downloads

Our authors are among the

154

Countries delivered to

TOP 1%

most cited scientists

12.2%

Contributors from top 500 universities



WEB OF SCIENCE™

Selection of our books indexed in the Book Citation Index
in Web of Science™ Core Collection (BKCI)

Interested in publishing with us?
Contact book.department@intechopen.com

Numbers displayed above are based on latest data collected.
For more information visit www.intechopen.com



Recording of Proprioceptive Muscle Reflexes in the Lower Extremity

Juhani Partanen, Urho Sompa and Miguel Muñoz-Ruiz

Abstract

Electromyography (EMG) is routinely used in diagnostics of root syndromes in the lower extremity. By studying signs of axonal damage of different root levels in the corresponding myotomes of the lower extremity and back muscles with needle EMG reveals, which of the motor roots are injured in patients with suspected root compression. But by EMG study only injuries of the anterior motor roots are diagnosed. Routine electroneuromyography does not disclose specific injury of the afferent sensory posterior roots. However, the integrity of some the posterior roots is readily studied with myotatic reflexes. We have routinely measured a proprioceptive reflex, the H-reflex of the soleus muscle with stimulation of the posterior tibial nerve, and found it to be useful in the diagnostics of the S1 root syndrome. It seems to be possible to record H-reflex of the peroneus longus muscle at the L5 level. We discuss the serious problems with volume conduction, when trials to measure proprioceptive reflexes of the L4 and L5 levels are performed. It may also be useful to record the medium latency reflexes in the area of the posterior tibial nerve, which seems to have a different reflex arch (II-afferents – β -efferents) from H-reflex (Ia afferents – α efferents). These measurements are non-invasive and not time consuming, and we hope to be able to add them for the routine ENMG diagnostics, when appropriate.

Keywords: proprioception, Ia afferent, II afferent, alpha motor neuron, beta motor neuron, electromyography, H-reflex, muscle reflex, root compression

1. Introduction

Root syndrome diagnostics of the lower extremity is based on the clinical picture, anamnesis, symptoms and signs of the disease. Diagnostic investigations should be considered in a few weeks if symptoms are not resolved, or even earlier if paraparesis or bowel or bladder symptoms develop. Current imaging studies are excellent, but there is the problem with non-symptomatic degenerative changes vs. relevant findings with respect to the acute symptoms, especially in middle-aged and old patients. ENMG has another problem: after acute onset of the disease the proprioceptive tendon- and H-reflexes change in a few days. However, the development of pathological spontaneous activity, fibrillations and positive sharp waves, indicating axonal injury in electromyography (EMG) may take 2-3 weeks and even longer in distal muscles of the leg and foot [1]. Loss of motor units during

maximal voluntary contraction may be observed soon, but more distinct changes, such as increase of duration, complexity (polyphasic and jittering waveform), and amplitude of motor unit potentials after parallel reinnervation may take several weeks and even months to develop [2]. That is why ENMG studies are usually not performed until several weeks after the acute onset stage. The aim of this chapter is to describe some proprioceptive reflexes, which may be used in acute stage of the disease, when clear needle EMG findings are not yet discernible, and proprioceptive reflex measurements which may be further developed for the ENMG diagnostics of root syndromes of the lower extremity.

1.1 Routine electroneurography in root syndromes of the lower extremity

Electroneuromyography of root syndromes of the lower extremity tends to concentrate on function of motor nerve fibres. Needle EMG observes axonal damage with fibrillation potentials, and loss and sprouting alterations of motor unit potentials. Signs of axonal damage may be searched in different myotomes of the lower extremity and paraspinal muscles [2]. F-responses and amplitudes of the motor responses may give supplementary information. The sensory responses are not affected, if the root lesion is proximal to the sensory paraspinal ganglion.

1.2 Pain in root syndromes and the methods to study the posterior roots

However, pain is usually more prominent symptom in root syndromes than motor weakness. Pain may express itself in the dermatomes of different root levels but often pain symptoms are obscure. The pain pathway uses the posterior roots, which may have a separate or more prominent injury than the anterior motor roots. ENMG study involving only motor nerve fibres may not be sufficient for the proper diagnosis of a root syndrome. Methods for studying the integrity of the posterior roots are needed. Posterior root compression may cause activation of pain C-fibres, but this may not invariably change proprioceptive reflexes using sensory afferent pathways with myelinated nerve fibres. Dermatomal evoked responses have been used, but they have not got any wide popularity. The method is awkward and time-consuming and the cerebral responses are small. This method is not recommended for clinical use [3].

1.3 H-reflexes of the distal muscles

Proprioceptive reflexes, especially H-reflexes, which use the posterior root pathway are too seldom used in ENMG diagnostics [4]. The only reflex we have routinely measured in patients with root syndrome is H-reflex of the soleus muscle. Its recording is easy, non-invasive and rapid, and very useful in S1 root syndrome diagnostics. It may also be used as a part of measurements to study polyneuropathy, an entity that should also be evaluated when root syndromes are investigated. Damage of the S1 posterior root often abolishes the H reflex response or causes slight prolongation or diminution of the reflex response [4]. Compression and injury of the anterior root is observed as a marked prolongation of the latency and diminution of the response amplitude (**Figure 1**). The clinical use of the soleus H-reflex requires a comprehensive normal material, which comprises corrections for height and age and sex of the patient (**Table 1**) [5].

We have not used systemically any H-reflexes of L5 and L4 levels. The H-reflex of the anterior tibial muscle may be recorded with slight tonic voluntary contraction

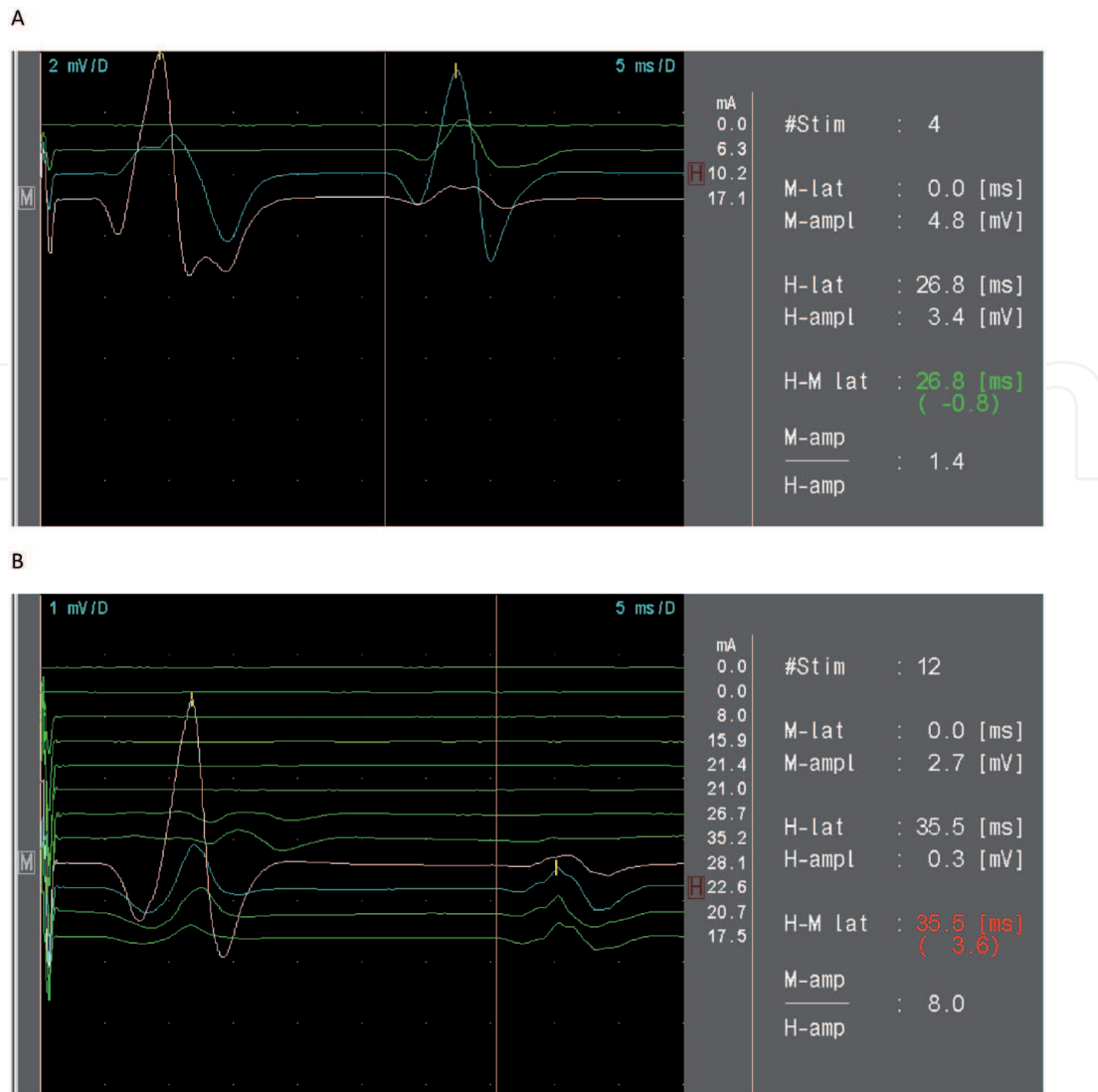


Figure 1. H-reflex in the healthy (A) and symptomatic (B) side of a patient with S1 root syndrome. Note the diminution of amplitude and large latency value of the H-reflex response in the symptomatic side, compared to the healthy one. The relatively large reflex asymmetry and good persistence also in the symptomatic side is consistent with S1 anterior root compression. The "H-M lat" describes the deviation in Z score value (normal <2) of the measured H-reflex latency from normal control values with height, age and sex corrections (Table 1). Note also the large difference in the M-amp/H-amp relationship.

Distal latency (ms)	SD	H-latency (ms)	SD		
4.13	0.50	29,18	2.18		
Calculation of the presumed normativity and the expectation percentage: (R ²) x 100 of the tibial H-reflex.					
(R ²) x 100	SD	Constant	Height coefficient (hc)	Age coefficient (ac)	sex
48	1.562	2.110	0.160		
64	1.325	-6.239	0.193	0.085	
68	1.256	-15.210	0.247	0.094	-1.45
Calculation of the expectation value: constant + hc x height (cm) + ac x age + sex (male).					

Table 1. Normal values and presumed normativity of the tibial H-reflex measured from the soleus muscle (surface electrodes near the border of the gastrocnemius muscle and the reference 2–3 cm distally).

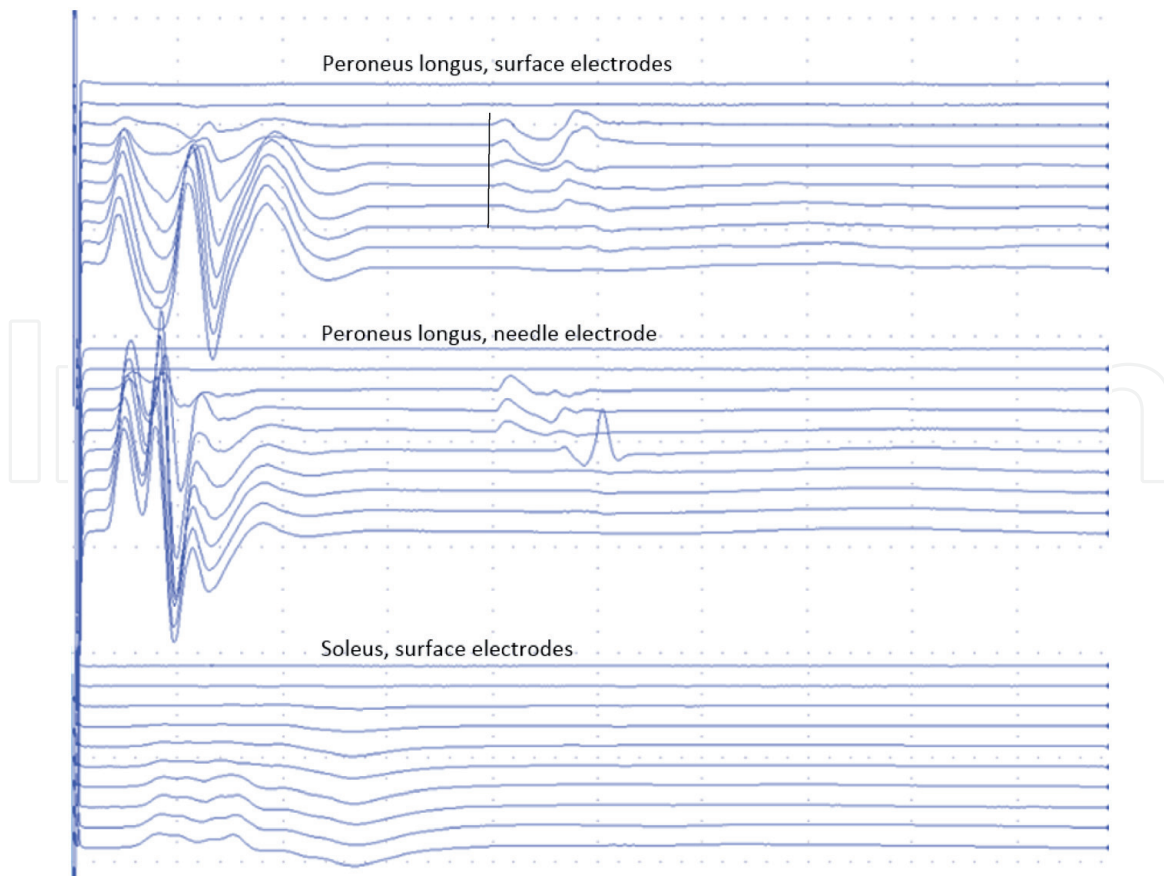


Figure 2.

H-reflex of peroneus longus, 32 years old male. Stimulation with 2 cm bipolar surface electrode to common peroneal nerve at the fibular head causing clear ankle dorsiflexion; ten concurrent stimulations with increasing stimulation current. Simultaneous recording of peroneus longus with both surface electrodes (interelectrode distance ca 3 cm), a 30 G concentric needle electrode, and soleus with surface electrodes (interelectrode distance ca 3 cm). Note the typical appearance of H-wave, latency 32 ms (vertical line), reaching its maximal amplitude before M-wave (contrary to the performance of F-responses) and appearance of H-wave solely on peroneus longus and not on soleus. 2 mV/div, 8 ms/div. A similar recording with surface electrodes on the lateral gastrocnemius muscle was also performed and no reflex response of this muscle was observed (not shown).

of the given muscle [4], but we have found it too difficult for routine use. No H-reflex for the L5-level was described for clinical use in root syndromes. We have tried to measure H-reflexes of the peroneus longus and extensor hallucis longus muscles, but these measurements were hampered by volume conduction of reflexes of the triceps surae muscle. However, H-reflex of the peroneus longus muscle can be confirmed by recording it with EMG needle electrode (**Figure 2**). The peroneus longus H-reflex may disappear in the symptomatic side of a patient with unilateral L5 root syndrome (**Figure 3**). Problems with volume conduction are discussed at the end of this chapter.

1.4 Tendon reflexes and H-reflexes of the proximal muscles

The L3-4 posterior roots can be studied with the patellar reflex (**Figure 4a and b**), and the adductor reflex [6]. The adductor tendon reflex can be evoked by ipsilateral tap to the medial epicondyle of the femur. Surprisingly, this reflex may also be elicited easily by tap to several sites of the lower extremity: for instance contralateral patellar tap, as well as ipsi- and contralateral anterior superior iliac spine tap. On the contrary, patellar tendon reflex was obtained only by ipsilateral tap to the patellar tendon. H-reflex of the adductor muscle (latency 16.4 ms, SD 1.6) is obtained by percutaneous

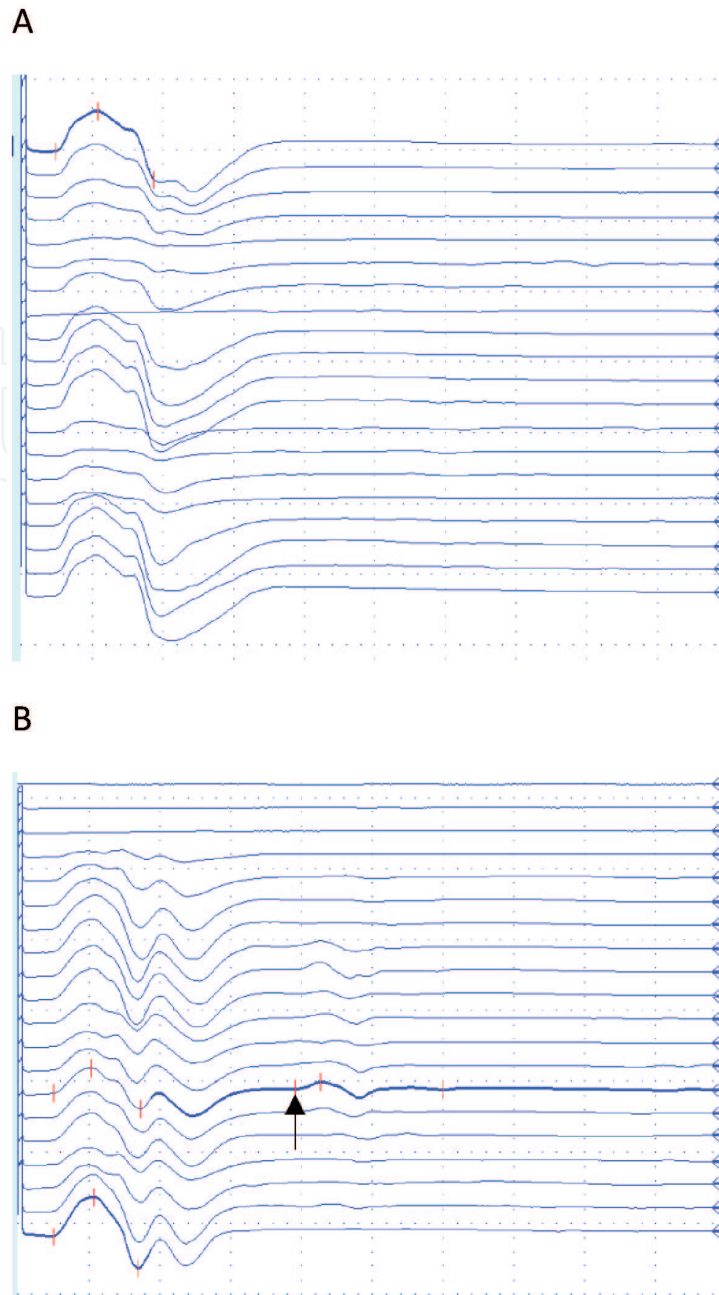
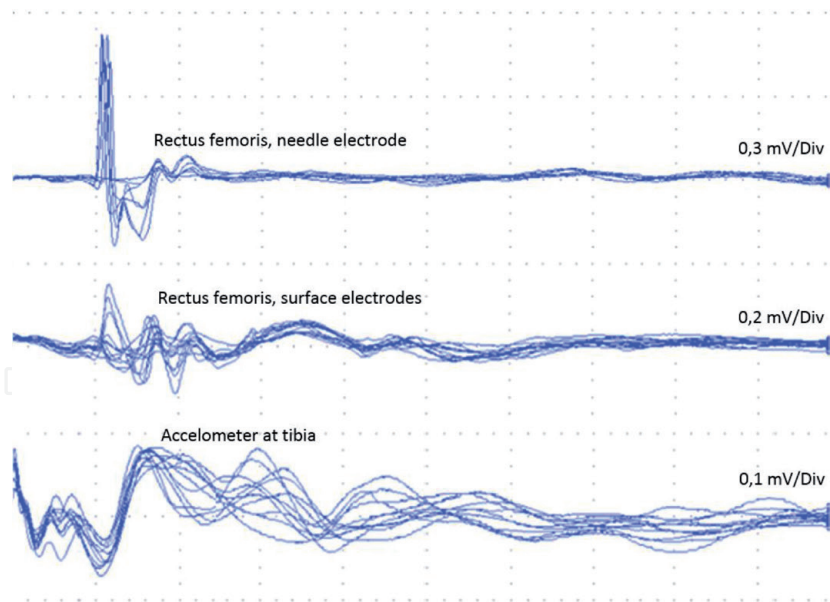
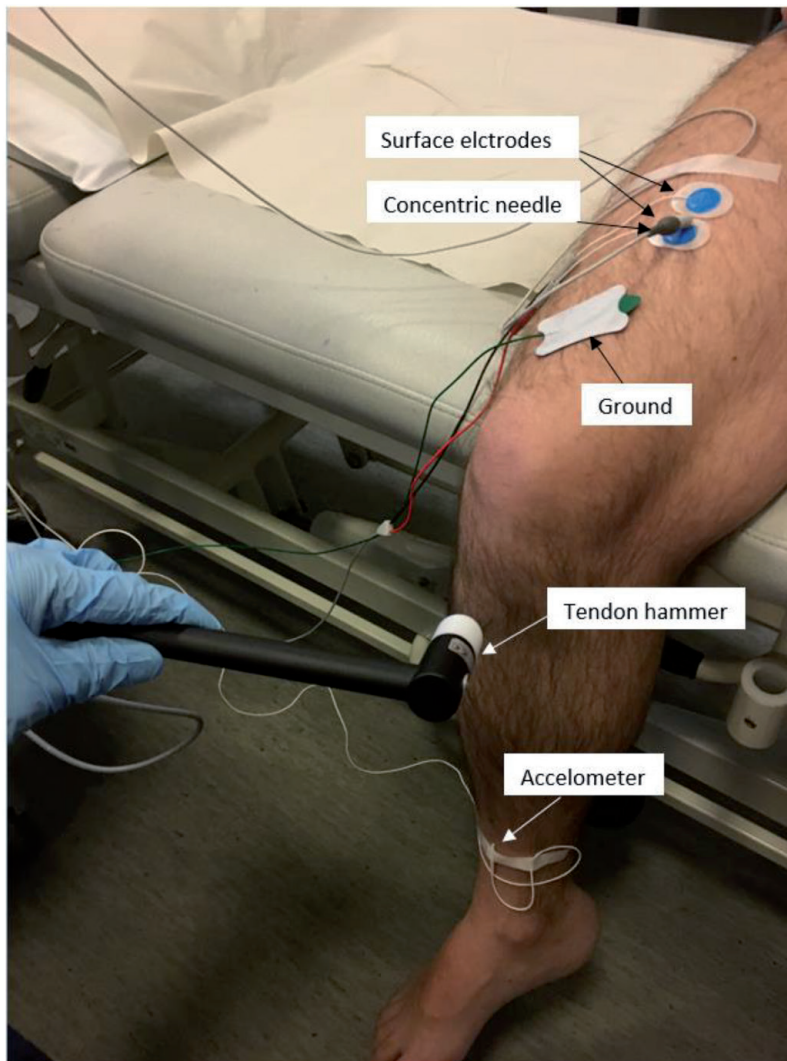


Figure 3.
A. M-response of the right peroneus longus muscle in a patient aged 80 with a right L5 root syndrome: Right L5 compression in MRI, positive needle EMG finding in the right L5 paraspinal muscle, F-response latency asymmetrically prolonged in the right extensor digitorum brevis muscle but bilaterally normal in the abductor hallucis muscles. Stimulation of the common peroneal nerve at the fibular head. Latency of the M-response 3.9 ms. The H-reflex cannot be elicited in spite of changes of the stimulation intensity 3.0-11.7 mA (submaximal and supramaximal). Calibration: 8 ms/div and 5 mV/div. No medium latency reflexes (see Figure 9). The tibialis posterior nerve was evidently not coactivated with the stimulation of the common peroneal nerve, there was only plantar dorsiflexion. B. M-response and H-reflex (arrow) of the left peroneus longus muscle of the patient. Latency of the M-response 4.0 ms and H-reflex 31.2 ms. stimulation intensity 3.1-14.4 mA. Calibration as above.

stimulation of the obturator nerve at the level of pubic tubercle. Even a medium-latency reflex, “late polysynaptic reflex response” of more than 50 ms was described in the adductor muscle [6]. However, these methods are rarely used in routine ENMG studies. The H-reflex of the quadriceps femoris muscle is readily recorded by stimulation of the femoral nerve [4], but we have not gained any experience with this method. The Achilles tendon reflex may also be recorded with surface electrodes on the triceps surae muscle. This recording was not used in routine ENMG studies. We should also remember that the tendon reflex and H-reflex have distinct differences [7].



(a)



(b)

Figure 4.

a. Electrical recording of the patellar reflex, 33 years old male. Stimulation with tendon hammer electrically connected to EMG-machine. Recording is triggered by a strike to prepatellar tendon. Recording in the rectus femoris muscle with both concentric needle electrode (30 G) and surface electrodes and an accelerometer connected to tibia. Three separate recordings of same stimulation protocol. 7-10 superimposed responses. Patellar reflex at ca 20 ms. 20 ms/div. b. Electrical recording of the patellar reflex, responses shown in a.

1.5 Medium latency reflex responses

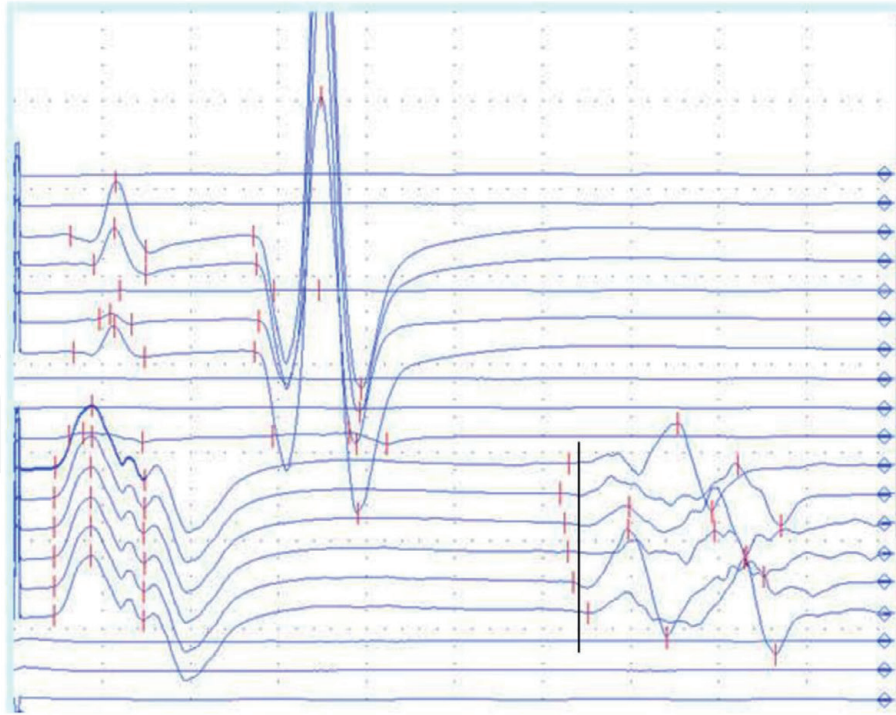
A medium latency reflex response (60-80 ms) of the soleus muscle can be recorded by supramaximal stimulus of the common peroneal nerve, which causes powerful twitch contraction of the peroneal muscles [8] (**Figure 5a**). Originally this reflex response was considered to use low-threshold muscle afferents and a transcranial loop, possibly involving the primary motor cortex and the supplementary motor area [9]. Later on it was demonstrated that the medium-latency reflex response of the soleus muscle to stretch does not involve a long reflex loop [10]. Soleus stretch resulting from unexpected perturbation during human walking elicits both short and medium latency reflex responses. It was concluded by cooling, ischaemia and tizanidine studies that the afferent receptors of the short latency component are Ia afferents and those of the medium latency component are II-afferents, respectively [11].

By stimulation of the common peroneal nerve at the fibular neck, only the medium latency reflex response can be recorded in electroneurography of the human soleus muscle [8] (**Figure 5a**). It was observed that stimulation of the common peroneal nerve results in long lasting (up to 200 ms) soleus H-reflex depression [12]. On the contrary, by stimulation of the posterior tibial nerve at the popliteal space, no medium latency reflex response can be recorded from the anterior tibial muscle [8].

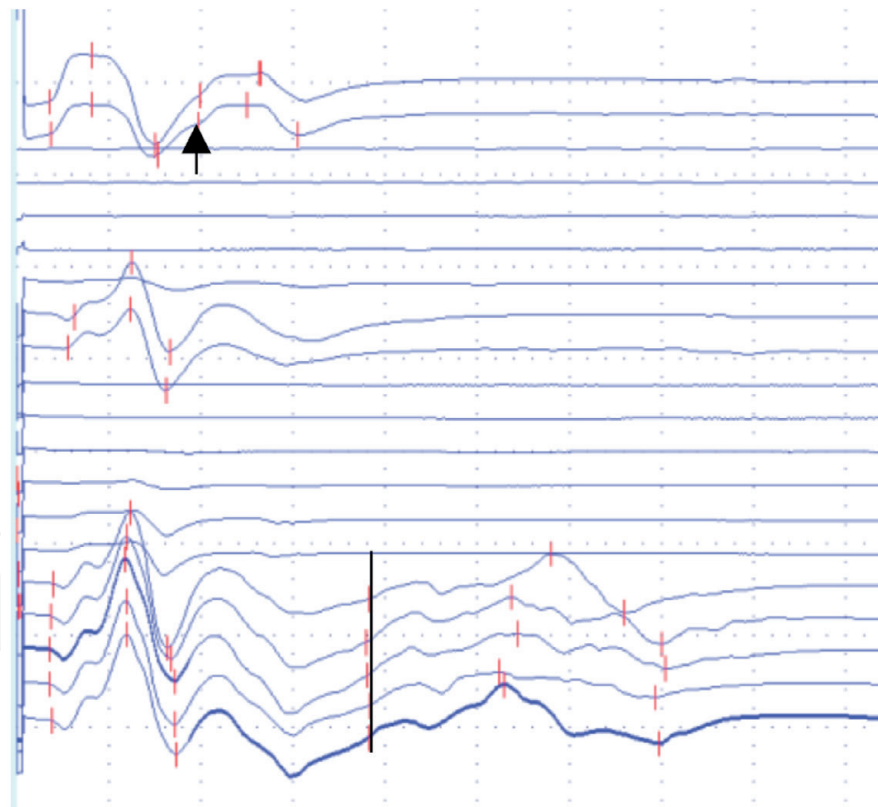
1.6 Calculations of conduction velocities and the role of β -efferents in the medium latency reflexes

The distances between the stimulation and recording sites were measured when the responses depicted in **Figure 5a** were recorded. The afferent pathway for H-reflex latency 27.0 ms was 640 mm between the stimulation site at the popliteal space, and L1 spinal level. Respectively, the distance of the efferent pathway between L1 spinal level and the estimated motor point of the soleus muscle was 750 mm. Considering that the synaptic delay in the spinal cord is about 1 ms [7] we can conjecture that the afferent conduction time from the stimulation site to the spinal cord is 11 ms and the efferent conduction time is 15 ms. The respective conduction velocities are for Ia afferents 58 m/s and for α motor efferents 50 m/s. These values match well with the recordings of Ia afferent conduction velocity 64 m/s and α motor conduction velocity 56 m/s of the median nerve [13], assuming that the respective values are slightly slower in the lower than in the upper extremity. The more distally recorded Ia afferent conduction velocity between the popliteal fossa and ankle is 56 m/s [7]. Cutaneous afferents are slower than Ia afferents, 61 m/s in the upper extremity [13] and 48 m/s in the lower extremity [7].

A similar calculation may be performed for the medium latency reflex latency 62 ms. The distance from the proximal part of the soleus muscle (site of the most proximal muscle spindles) to the L1 spinal level was 670 mm, and the distance from L1 to the motor point of the soleus muscle was 750 mm. The estimated afferent conduction time is 30 ms and the efferent conduction time 31 ms, the spinal synaptic delay time was again estimated to be 1 ms. By these values we may calculate, that the afferent conduction velocity for II-afferent pathway is 22 m/s, and for the efferent conduction velocity is 24 m/s. This afferent conduction velocity matches well with the II-afferent conduction velocity 21 m/s observed in the lower extremity [14]. But the efferent conduction velocity 24 m/s is far too slow for the α motor efferent pathway, which was calculated to be 50 m/s in the H-reflex arch (see above).



(a)



(b)

Figure 5.

a. the tibial H-reflex of the soleus muscle elicited with submaximal stimuli, minimum latency 27.0 ms. The stimulation was changed to the common peroneal nerve at the knee joint and supramaximal stimuli elicited the medium latency reflexes of soleus, minimum latency 62.0 ms (vertical line). The "M-response" was reflected from the pretibial muscles. For calculations of the afferent and efferent conduction velocities of the reflex responses see text. Calibration: 10 ms/div, 2 mV/div. A voluntary healthy subject, male, age 31 y, height 166 cm. b. H-reflex of the median nerve (2 uppermost sweeps), latency 15,5 ms (arrow), stimulation: Median nerve at the elbow, recording with surface electrodes on the forearm flexors. The stimulation was changed to the radial nerve at the spiral groove (2 middle responses). When the stimulus was turned to supramaximal value, medium latency reflex responses, latency 30.5 ms, were elicited (vertical line, 5 lowermost sweeps) from the forearm flexors. Calibration: 8 ms/div, 2 mV/div. A voluntary healthy subject, male, age 31 y, height 166 cm.

This fact justifies the hypothesis that the efferent pathway of the medium latency reflexes consists of skeletofusimotor β motor fibres, which are thinner and slower than α motor fibres. β motor efferents have been observed in man [15].

1.7 The possible influence of inhibitory pathways on the reflex responses

Ib afferent nerve fibres from Golgi tendon organs are slightly smaller than those of Ia afferents [11]. The electrically evoked excitatory postsynaptic potential may be curtailed by the inhibitory postsynaptic potential of only slightly longer latency than the excitatory postsynaptic potential [7]. There is a Ib inhibitory volley from the Golgi tendon organs, which originate from the proximal tendon insertion of the anterior tibial muscle, elicited by the strong contraction of the muscle by stimulation of the posterior tibial nerve at the popliteal space. This inhibitory volley may reach the spinal cord and prevent the occurrence of the medium latency reflex response. The lack of medium latency reflex was pointed out in this muscle [8]. Unexpected perturbation during walking elicits short- and medium-latency soleus reflex responses [11]. However, soleus stretch, caused by electric stimulation of the common peroneal nerve and powerful contraction of the pretibial muscles, elicits only a medium-latency reflex response of the soleus muscle. It may be considered that the Ia reciprocal inhibitory influence [7] plays a role in inhibition of the soleus short-latency reflex response in this situation.

1.8 Comparison with the upper extremity

The forearm flexor muscles (for example m. flexor carpi radialis and m. flexor digitorum superficialis) show H-reflexes, when the median nerve is stimulated at the elbow [4]. When the stimulation is changed to the radial nerve at the spiral groove, a medium reflex response may be recorded at the same site than the median H-reflex (**Figure 5B**). Thus, the respective reflex responses seem to be elicited in

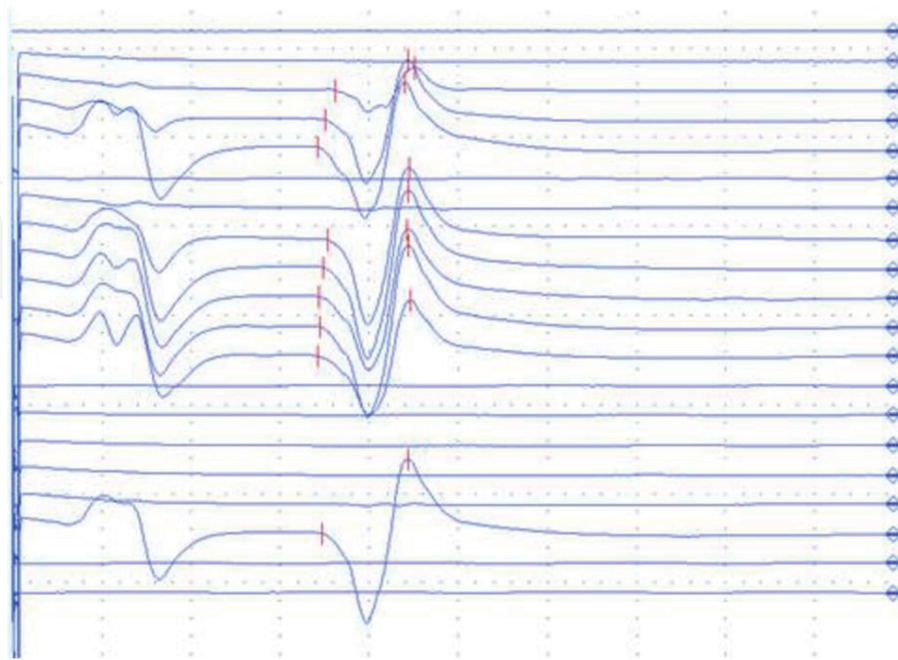
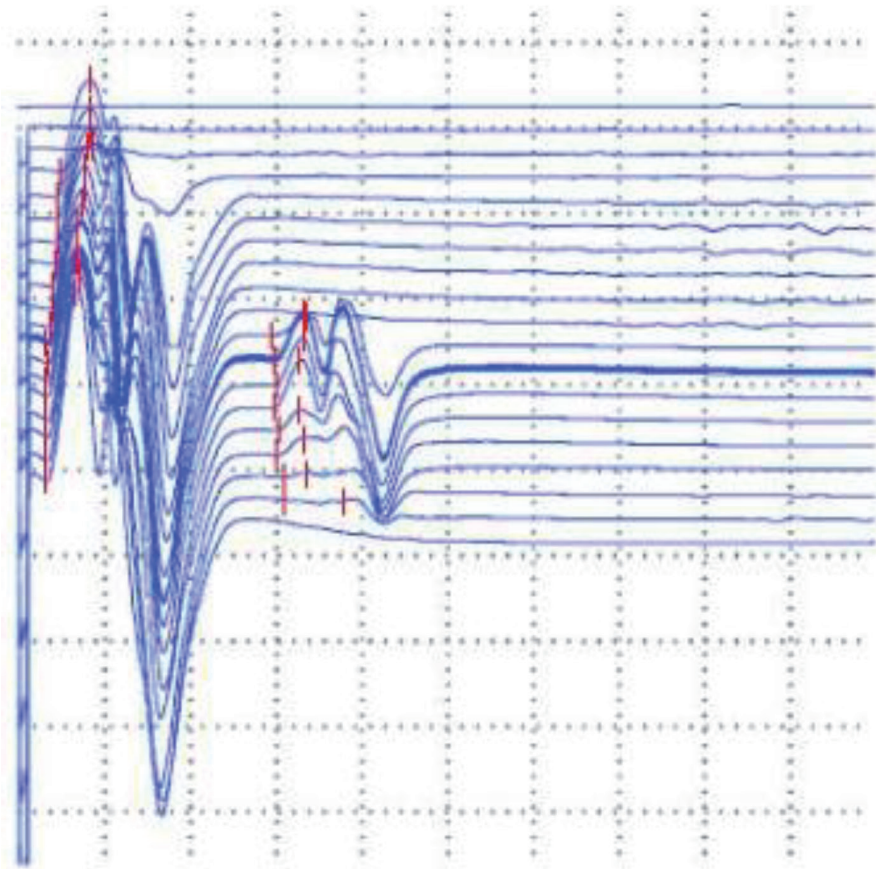


Figure 6.
*The "reflex" response of the anterior tibial muscle (latency 27.4 ms), recorded by the stimulation of the posterior tibial nerve at the popliteal fossa. Superficially it may be reminiscent to a myotatic reflex of the anterior tibial muscle, but in reality it is the H-reflex of the triceps surae muscle, volume conducted to the recording site (compare with the H-reflex recording in **Figure 4**). The "M-response" points out the direct activation of the triceps surae muscle. Calibration: 8 ms/div, 2 mV/div.*

A



B

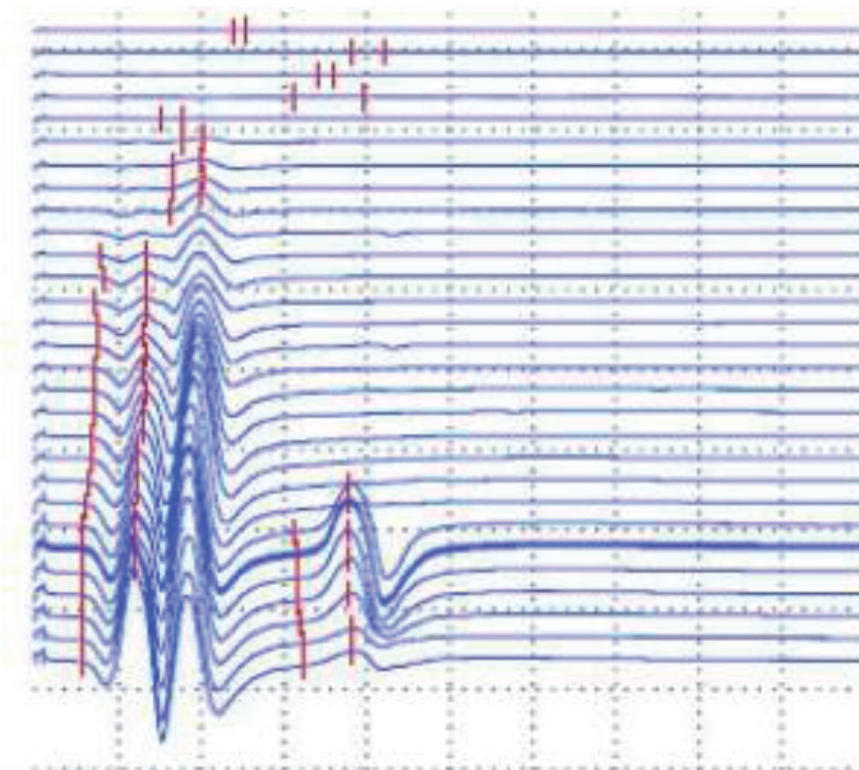


Figure 7. “H-reflexes” of the A) *peroneus longus* and B) *extensor hallucis longus* muscles by stimulation of the common peroneal nerve and recorded with surface electrodes. In reality” H-reflexes” may be H-reflexes of the *triceps surae* muscle caused by spreading of stimuli to a branch of the posterior tibial nerve. Calibration 10 ms/div, 3 mV/div.

the upper extremity than in the lower one as well. As in the lower extremities the proprioceptive reflexes are important in the process of walking and running, they might be related to grip and climbing functions in the upper extremities and thus may have served an important role in primate evolution.

1.9 Problems with volume conduction

When the common peroneal nerve is stimulated, the stimulus spreads readily to the motor branches of the posterior tibial nerve. Thus, volume conduction is a source of error especially when the reflexes of the pretibial muscles are recorded with surface electrodes. The stimulation spreading to branches of the posterior tibial nerve may elicit H-reflex of the triceps surae muscle, recorded with electrodes on the surface of the anterior tibial muscle. This reflex response may imitate the myotatic reflex of the anterior tibial muscle (**Figure 6**). A similar problem may be encountered by recording of responses of the peroneus longus and extensor hallucis longus muscles (**Figure 7**), as well as the foot muscles (**Figure 8**). However a

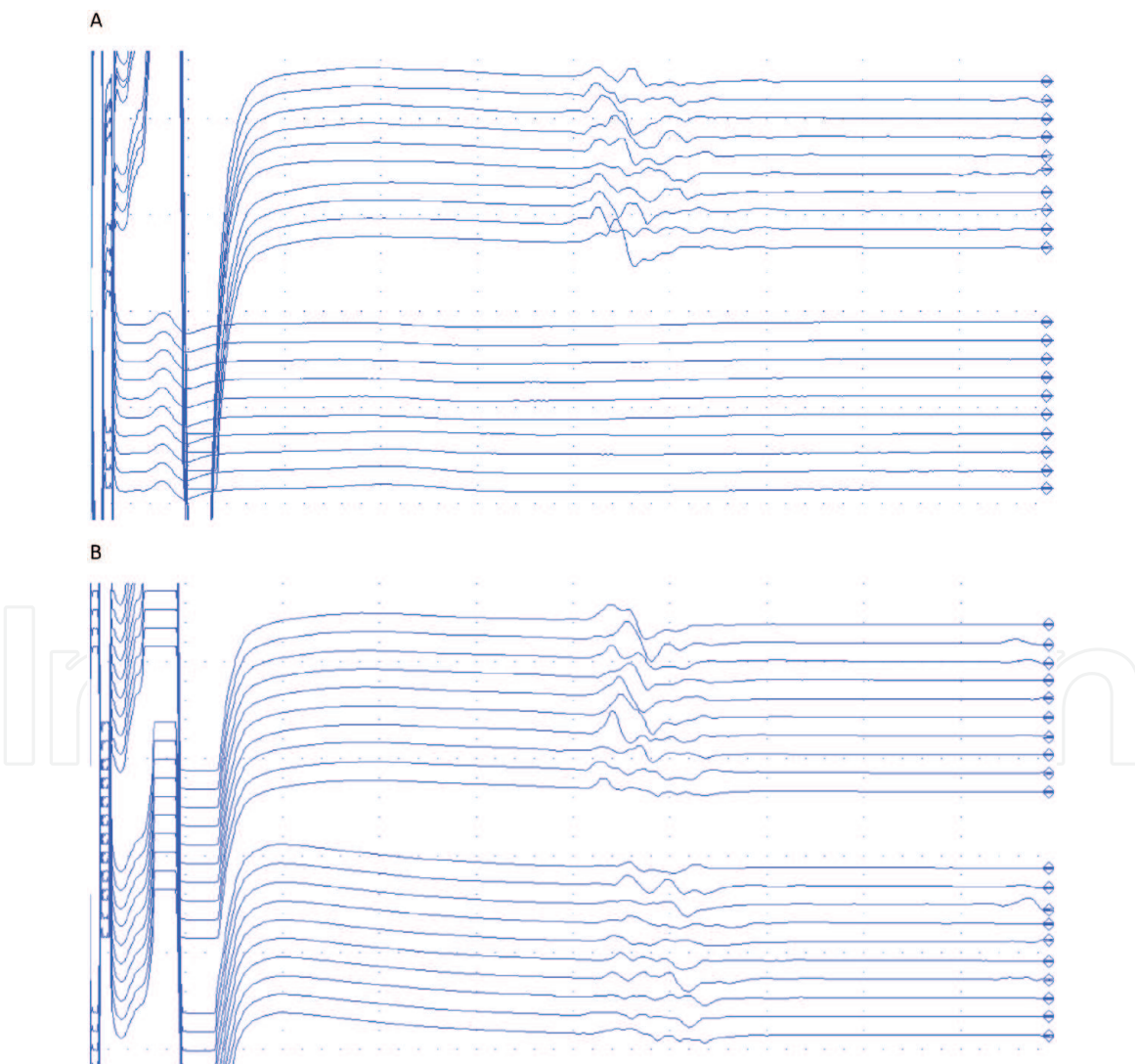


Figure 8. F-responses of the tibial nerve in the abductor hallucis brevis muscle, latency 50 ms. stimulation at the ankle, upper 10 sweeps with surface electrodes. The lower 10 sweeps are recorded from the extensor digitorum brevis muscle: A) with a concentric needle electrode, no responses, and B) with surface electrodes, active electrode on the muscle and reference placed in the distal end of 5th metatarsal bone. Observe the “medium latency reflexes” of the extensor digitorum brevis muscle, which are volume conducted F-responses of the abductor hallucis brevis muscle. Calibration: 10 ms /div, 2 mV / div.

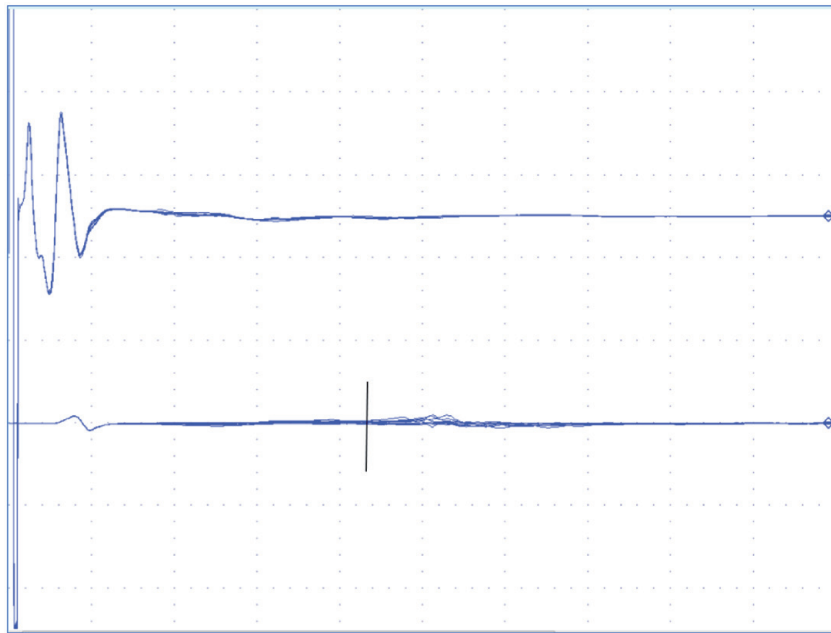


Figure 9. Stimulation of the common peroneal nerve at the fibular head. Uppermost: M-response of the anterior tibial muscle recorded with surface electrodes. Lowermost: Possible medium latency reflex responses of the abductor digiti minimi muscle, latency 85 ms (vertical line). But the volume conducted F-responses of the extensor digitorum brevis muscle might be another possibility (see **Figure 7B**). However, the F-response latency should be essentially shorter than this recorded response, with stimulation at the fibular head. Calibration 20 ms/div, 2 mV/div.

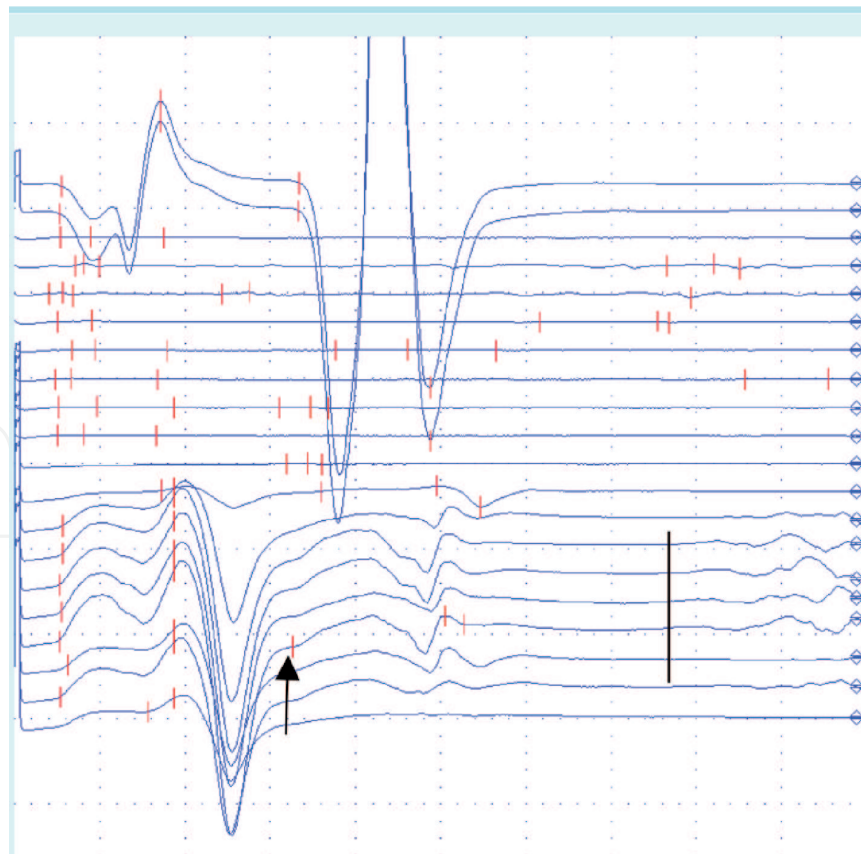


Figure 10. H-reflex of the soleus muscle, latency 29.8 ms, stimulation of n. tibialis at the popliteal space (uppermost sweeps). When the stimulation was changed to the common peroneal nerve (lowermost sweeps), "H-reflex" of the peroneus longus muscle was elicited (arrow). But we may also see a medium latency reflex response of about 64 ms (vertical line), which cannot be elicited from the peroneal muscles. This proves that a branch of the tibial nerve leading possibly to the lateral gastrocnemius muscle, with medium latency reflex response is also activated by the stimulation. Calibration 8 ms/div, 1 mV/div.

medium latency reflex response of the abductor digiti minimi muscle may really occur (**Figure 9**). The medium latency reflex response may reveal the false” H-reflex” of the peroneus longus muscle (**Figure 10**).

2. Conclusions

The H-reflex is a useful tool as a probe for clinical neurophysiologist, but the pathways and pitfalls should be considered [12]. The integrity of posterior roots of the S1 level is readily studied with the soleus H-reflex measurement, and we have used this method routinely for a long time. Unfortunately, there are difficulties with recording of H-reflex of the L5 level. Our trials with surface electrodes were often hampered by volume conducted reflex responses of the triceps surae muscle. With a simultaneous needle recording of the peroneus longus muscle we could prove that the H-reflex response of it is real, but it should be distinguished from F-responses. The medium latency reflex of the soleus muscle can be recorded with a powerful twitch contraction of the pretibial muscles elicited by supramaximal stimulation of the common peroneal nerve. We do not have any experience of its use in S1 root syndrome diagnostics. However, it is tempting to assume, that we may study the integrity of two completely different parallel proprioceptive reflex arches of the soleus muscle: the Ia-afferent – α efferent reflex arch (H-reflex), as well as the II-afferent – β efferent reflex arch (medium latency reflex), and compare the results of these measurements in investigation of the posterior root syndrome at S1 level. H-reflex of the peroneus longus muscle might be used in the diagnostics of posterior root lesion of the L5 level. We recommend the recording of this reflex with an EMG needle electrode. This recording can be performed accompanied with the needle EMG study for a possible axonal injury of the L5 motor nerve fibres of the peroneus longus muscle. L3 and L4 posterior roots might be investigated with the quadriceps femoris and adductor H-reflexes. Considering these many different methods and technical challenges related to them, a practitioner is advised to collect own normative data and always interpret the results rather conservatively in the context of full clinical picture.

Author details


Juhani Partanen^{1*}, Urho Sompa² and Miguel Muñoz-Ruiz²

¹ Department of Clinical Neurophysiology, University Central Hospital of Helsinki, Jorvi Hospital, Rörstrandinkatu 4 B 27, 00560, Helsinki, Finland

² Department of Clinical Neurophysiology, Central Finland Health Care District, Keskussairaalan tie 19, PL 123, 40620, Jyväskylä, Finland

*Address all correspondence to: junipartanen@gmail.com

IntechOpen

© 2021 The Author(s). Licensee IntechOpen. This chapter is distributed under the terms of the Creative Commons Attribution License (<http://creativecommons.org/licenses/by/3.0>), which permits unrestricted use, distribution, and reproduction in any medium, provided the original work is properly cited. 

References

- [1] Partanen J. Different types of fibrillation potentials in human needle EMG. In: Turker H editor. *Electrodiagnosis in new frontiers of clinical research*. Rijeka, Croatia: Intech 2013, <http://dx.doi.org/10.5772/55352>
- [2] Preston and Shapiro, editors. *Electromyography and neuromuscular disorders: Clinical-electrophysiologic correlations*. 2013. London: Elsevier.
- [3] American Association of Neuromuscular & Electrodiagnostic Medicine. Don't perform dermatomal somatosensory evoked potentials (SEPs) for a pinched nerve in the neck or back, as they are an unproven diagnostic procedure. 2015, February 10.
- [4] Burke D. Clinical uses of H reflexes of upper and lower limb muscles. *Clinical Neurophysiology Practice*. 2016;1:9-17.
- [5] Partanen J. F-vaste ja H-refleksi. Chapter 5.1. In: Lang H, Partanen J, Häkkinen V, Larsen A. editors. *Sähköiset hermomme*. Turku: The Society of Clinical Neurophysiology in Finland 1992, p. 143-150.
- [6] Ertekin C, Bademkiran F, Tataroglu C, Aydogdu I, Karapinar N. Adductor T and H reflexes in humans. *Muscle & Nerve* 2006;34:640-645.
- [7] Burke D, Gandevia SC, McKeon B. The afferent volleys responsible for spinal proprioceptive reflexes in man. *The Journal of Physiology* 1983;339:535-552.
- [8] Yusal H, Larsson L-E, Efendi H, Burke D, Ertekin C. Medium-latency reflex response of soleus elicited by peroneal nerve stimulation. *Experimental Brain Research* 2009;193:275-286.
- [9] Wiesendanger M, Miles TS. Ascending pathway of low-threshold muscle afferents to the cerebral cortex and its possible role in motor control. *Physiological Reviews* 1982;62:1234-1269.
- [10] Schieppati M, Nardone A, Siliotto R, Grasso M. Early and late stretch responses of human foot muscles induced by perturbation of stance. *Experimental Brain Research* 1995;105:411-422.
- [11] Grey MJ, Ladouceur M, Andersen JB, Nielsen JB, Sinkjær T. Group II muscle afferents probably contribute to the medium latency soleus stretch reflex during walking in humans. *The Journal of Physiology* 2001;534.3:925-933.
- [12] Knikou M. The H-reflex as a probe: Pathways and pitfalls. *Journal of Neuroscience Methods* 2008;17:1-12.
- [13] Metso AJ, Palmu K, Partanen JV. Compound nerve conduction velocity - A reflection of proprioceptive afferents? *Clinical Neurophysiology* 2008;119:29-32.
- [14] Nardone A, Schieppati M. Medium-latency response to muscle stretch in human lower limb: estimation of conduction velocity of group II fibres and central delay. *Neuroscience Letters* 1998;249:29-32.
- [15] Kakuda N, Miwa T, Nagaoka M. Coupling between single muscle spindle afferents and EMG in human wrist extensor muscles: physiological evidence of skeletofusimotor (beta) innervation. *Electroencephalography and Clinical Neurophysiology* 1998;109:360-363.