

<https://helda.helsinki.fi>

Simple dentate area fractures of the mandible - can we prevent postoperative infections?

Oksa, Marko

2022-10-03

Oksa , M , Haapanen , A , Marttila , E & Snäll , J 2022 , ' Simple dentate area fractures of the mandible - can we prevent postoperative infections? ' , Acta Odontologica Scandinavica , vol. 80 , no. 7 , pp. 494-500 . <https://doi.org/10.1080/00016357.2022.2036812>

<http://hdl.handle.net/10138/349939>

<https://doi.org/10.1080/00016357.2022.2036812>

cc_by_nc_nd

publishedVersion

Downloaded from Helda, University of Helsinki institutional repository.

This is an electronic reprint of the original article.

This reprint may differ from the original in pagination and typographic detail.

Please cite the original version.



Simple dentate area fractures of the mandible – can we prevent postoperative infections?

Marko Oksa, Aleksi Haapanen, Emilia Marttila & Johanna Snäll

To cite this article: Marko Oksa, Aleksi Haapanen, Emilia Marttila & Johanna Snäll (2022) Simple dentate area fractures of the mandible – can we prevent postoperative infections?, Acta Odontologica Scandinavica, 80:7, 494-500, DOI: [10.1080/00016357.2022.2036812](https://doi.org/10.1080/00016357.2022.2036812)

To link to this article: <https://doi.org/10.1080/00016357.2022.2036812>



© 2022 The Author(s). Published by Informa UK Limited, trading as Taylor & Francis Group on behalf of Acta Odontologica Scandinavica Society.



Published online: 07 Feb 2022.



Submit your article to this journal [↗](#)



Article views: 729



View related articles [↗](#)



View Crossmark data [↗](#)

Simple dentate area fractures of the mandible – can we prevent postoperative infections?

Marko Oksa^{a,b}, Aleksi Haapanen^{a,b}, Emilia Marttila^{a,b} and Johanna Snäll^{a,b}

^aDepartment of Oral and Maxillofacial Diseases, University of Helsinki, Helsinki, Finland; ^bHelsinki University Hospital, Helsinki, Finland

ABSTRACT

Objective: To evaluate the occurrence of surgical site infections and predisposing factors for these in simple mandibular fractures.

Material and Methods: A retrospective study of patients with fractures of the dentate part of the mandible included patients with intraorally treated simple fractures of the mandibular body, symphysis, and parasymphysis. The primary outcome variable was postoperative surgical site infection. Use of antibiotics, injury mechanism, fracture and surgery-related explanatory variables, patient-related variables and level of oral hygiene according to the modified Total Dental Index were evaluated.

Results: Of 254 patients with mandibular fractures, 107 were included in the final analysis. The infection group consisted of 18 patients (16.8%). Despite the high infection occurrence, significant differences were not found between antibiotic use or other studied variables and infection occurrence. Infections occurred mainly in patients without any specific explanatory factor for infection.

Conclusion: The notably high occurrence of surgical site infections despite antibiotic use after simple mandibular fracture surgery highlights the importance of perioperative tissue handling and local oral circumstances. It is also necessary to consider whether we generally accept the high risk of infection associated with the intraorally treated simple mandibular fractures.

ARTICLE HISTORY

Received 4 January 2022
Revised 19 January 2022
Accepted 22 January 2022

KEYWORDS

Antibiotics; mandible; surgical site infection; trauma

Introduction

Fractures of the mandibular body, symphysis, and parasymphysis are often treated by open reduction using the intraoral approach [1–3]. Compared with other facial fractures, mandibular fractures of the tooth-bearing region are typically open fractures, and the fracture area is in contact with the oral microbiome. Therefore, the fracture site as well as fixation material are exposed to a wide range of bacteria [4]. The aim of successful surgical treatment includes support of healing by decreasing the probability of infection [5].

Surgical site infections (SSIs) and wound dehiscence are typical complications after mandibular fracture surgery [6,7]. According to Gutta et al. [8], SSI can be considered to have the following clinical signs: the presence of pus at the site of repair, swelling, and the presence of granulation tissue with fistula. The use of antimicrobial prophylaxis among mandibular fracture patients has been justified in the prevention of SSIs. However, consensus has not been reached regarding the duration of pre- and postoperative antibiotic therapy, and notable differences exist in antibiotic-prescribing practices between surgeons [9].

Numerous previous studies involving SSIs in mandibular fracture surgery have included several types of mandibular fractures in the analysis. The studies have also included condyle fractures as well as fractures treated both intraorally

and extraorally [8,10,11]. However, the SSI risk differs between fracture types and sites; for example, angular location of the fracture increases the risk for postoperative infection [8,12]. In addition, an infected tooth in the fracture line increases the risk for SSIs [8,13]. To identify other predisposing factors for SSIs, we focussed on mandibular fractures without the forementioned causes.

Our primary objective was to evaluate the occurrence of SSI, and possible predisposing factors to it, in simple mandibular fractures treated intraorally. We wanted to clarify the need of antibiotic medication in patients with these simple and non-complicated fractures. We hypothesized that the timing and duration of antibiotic therapy do not affect SSI occurrence.

Materials and methods

Study design

Patient records of all patients with mandibular fractures treated surgically at Helsinki University Hospital between January 2018 and October 2020 were collected from the hospital's electronic medical database retrospectively.

Inclusion and exclusion criteria

Patients 18 years of age or older who had undergone surgery for a single fracture of the dentate part of the mandible *via* intraoral approach and fixation with miniplates and/or lag screws were included in the study. Included were patients with simple mandibular fractures involving full vertical height of mandible.

Patients with angle fractures and those with infection at the time of the primary surgery were excluded. Additionally, patients without available dental panoramic radiograph (DPR), those who developed endodontist-confirmed infection of a tooth in the fracture line, and those who underwent a

redo surgery due to suboptimal reduction at primary stage were excluded. A follow-up duration of at least 4 weeks was required for inclusion in the analyses.

Study variables

The primary outcome variable was postoperative SSI. It was defined as clinically confirmed postoperative infection requiring antibiotic medication with or without ancillary care and having pus formation in addition to one or more of the following infection signs: cellulitis, pain, or swelling after the initial stage of healing. Surgical wound dehiscence was not defined as infection. In this study, the presence of granulation tissue with fistula was not considered as SSI, for it can be managed without a course of antibiotics.

The primary predictor variable was duration of postoperative antibiotic medication. Additional predictor variables were total postoperative duration and total duration of antibiotic medication, use of preoperative antibiotics, use of antibiotics in anaesthesia induction, use of postoperative antibiotics, and use of postoperative chlorhexidine mouth rinse. Specific administered antibiotic medications were also reported.

Patient-related explanatory variables were age, sex, smoking, substance abuse including evident heavy alcohol use (≥ 23 doses of alcohol per week for men and ≥ 12 doses for women according to the Finnish Current Care Guidelines; one dose contains 12 g of pure alcohol [14]) and/or abuse of other drugs, immunosuppressive condition (immunosuppressive disorder and/or drug therapy), injury mechanism, and level of oral hygiene according to the modified Total Dental

Table 1. Modified total dental index.

Type of disease	Score
Caries	
No caries	0
1–3 carious lesions	1
4–7 carious lesions	2
≥ 8 carious lesions or infected roots or no teeth	3
Periodontitis	
None	0
1–3 deep vertical pockets	1
4–7 deep vertical pockets	2
≥ 8 deep vertical pockets	3
Apical periodontitis	
None	0
1 tooth	1
2 teeth	2
≥ 3 teeth	3
Furcation lesions	
Absent	0
Present	1

Modified Total Dental Index defined by Mattila et al. [15].

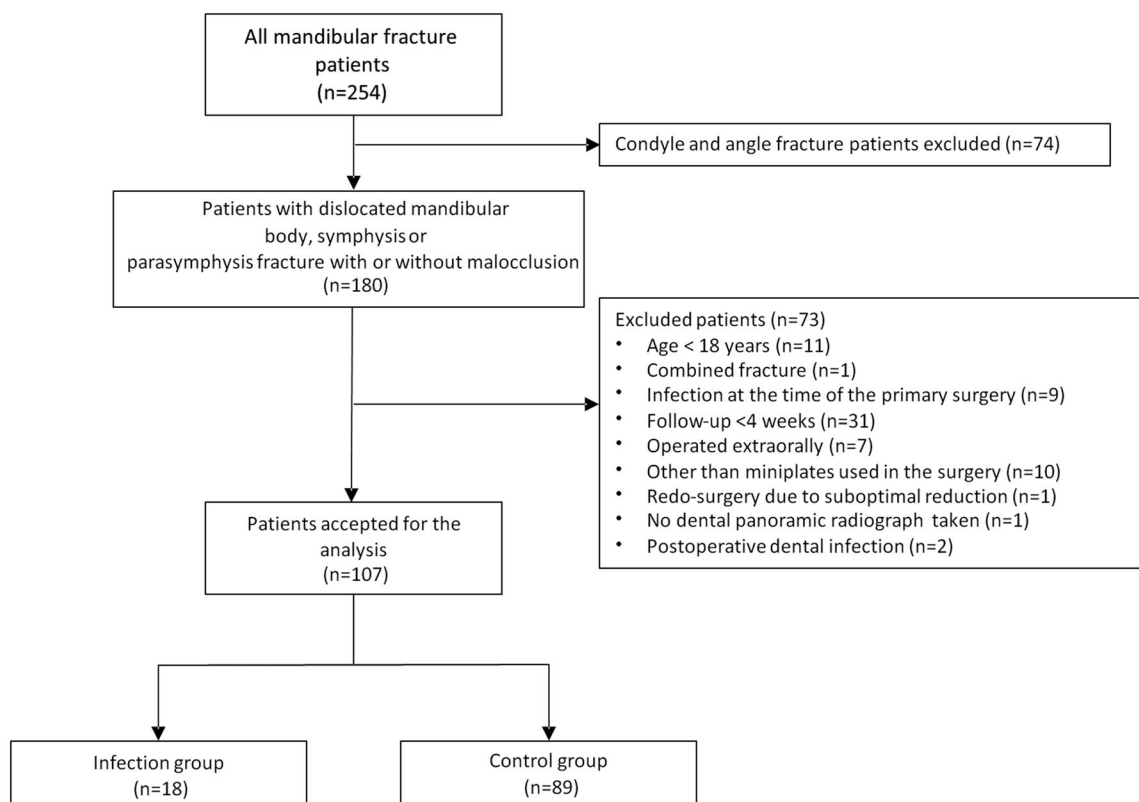


Figure 1. Flowchart of patient inclusion in the study.

Table 2. Association between explanatory variables and median duration of postoperative antibiotic course.

	Duration of postoperative antibiotics ^a		p Value
	Less than 5 days	5 days or longer	
All (n)	50	57	–
Age, years			
Range	18–74	18–89	.27
Mean	35.45	39.17	
Median	30.50	35.42	
Modified Total Dental Index (TDI)			
Range	0–5	0–8	.95
Mean	1.74	1.95	
Median	1	2	
Treatment delay from accident to surgery, days			
Range	0–8	0–6	.47
Mean	1.78	1.54	
Median	2	1	
No. of plates			
Range	0–2	0–2	.11
Mean	1.60	1.89	
Median	2	2	
No. of lag screws			
Range	0–3	0–3	.014
Mean	0.38	0.07	
Median	0	0	
No. of teeth extracted for poor dental condition (no trauma teeth)			
Range	0–4	0–12	.65
Mean	0.32	0.65	
Median	0	0	
	Less than 5 days (n)	5 days or longer (n)	
Sex			
Male	40	44	.94
Female	10	13	
Smoking			
Yes	15	22	.42
No	35	35	
Alcohol and/or drug abuse			
Yes	11	14	.82
No	39	43	
Immunosuppressive condition			
Yes	1	2	1
No	49	55	
Injury mechanism			
Assault	20	27	.96
Traffic accident	13	13	
Falling on ground	14	14	
Falling ≥ 3 m	1	1	
Struck by an object	2	2	
Fracture site			
Body	7	4	.34
Symphysis/parasymphysis	43	53	
Tooth removal (any)			
Yes	8	11	.80
No	42	46	
Tooth removal from fracture line			
Yes	1	0	.47
No	49	57	
Tooth removal during surgery for poor dental condition			
Yes	8	11	.80
No	42	46	
Comminution of the fracture			
Non-comminuted	46	55	.41
Comminuted	4	2	

^aMedian 5 days.

Index (TDI) presented in Table 1. TDI is a value between 0 and 10; the higher the value, the higher the infection load of the oral cavity [15,16].

Fracture and surgery-related explanatory variables were fracture site (symphysis/parasymphysis or body fracture) and

treatment delay from injury to surgery. The oral infection load and the total number of teeth extracted during surgery due to poor dental condition (i.e. excluding tooth removals for tooth injury) were analysed. Patients with tooth extractions were subgrouped (extraction due to poor dental condition or due to location in fracture line) and analysed separately. Number of miniplates and/or lag screws used and comminution of the fracture were also analysed as explanatory variables.

Fractures were defined as non-comminuted (i.e. no fragmentation or fragments smaller than the size of the crown of a premolar), fracture with minor comminution (i.e. one or more fragments larger than the size of the crown of a premolar and not involving the full vertical height of the mandibular arch), or fracture with major comminution (i.e. one or more small or large intermediate fragment(s) involving the full height of the mandibular arch) [17].

Radiological evaluation

Pre- and postoperative DPR images and the initial radiologists' reports were reviewed by oral and maxillofacial consultants A.H. and J.S. Fracture comminution, number of plates and/or lag screws, and variables for TDI were assessed.

Statistical analysis

Data were analysed using GraphPad Prism, version 5.00 (GraphPad Inc. San Diego, CA, USA). Two-tailed Mann-Whitney test was used for comparisons of continuous variables between the two patient groups. Fisher's exact test and Chi-squared test were used to examine associations between different categorical variables. P-values < .050 were considered statistically significant.

Ethical approval

The study protocol was approved by the internal board of the Head and Neck Centre, Helsinki University Hospital, Helsinki, Finland (HUS/356/2017).

Results

Of 254 mandibular fracture patients, 107 were included in the final analyses (Figure 1). Associations between explanatory and additional predictor variables and median duration of postoperative antibiotic course are presented in Tables 2 and 3. The number of lag screws showed a significant positive correlation with the duration of postoperative antibiotics ($p=.014$).

SSIs occurred in 18 patients (16.8%). They were more common, albeit not significantly, in patients with a shorter antibiotic course. Aside from the above-mentioned lag screws, no other statistically significant differences were found between the studied variables and SSI (Tables 4 and 5).

Table 6 summarises the details of SSIs in the 18 patients. The timing of SSIs varied between 5 and 106 days (mean

Table 3. Association between timing of antibiotic administration and median duration of postoperative antibiotic course.

	Duration of postoperative antibiotics ^a		p Value
	Less than 5 days (n)	5 days or longer (n)	
All	50	57	–
Preoperative antibiotics			
Yes	38	48	.33
No	12	9	
Penicillin G/V	29	30	
Penicillin G/V + metronidazole	0	3	
Cephalosporin	3	7	
Cephalosporin + metronidazole	2	6	
Aminopenicillin (ampicillin, amoxicillin)	0	0	
Aminopenicillin (ampicillin, amoxicillin) + clavulanic acid	2	0	
Clindamycin	0	2	
Other (combination)	2	0	
Antibiotics in anaesthesia induction			
Yes	50	56	.24
No	0	1	
Penicillin G	31	24	
Penicillin G + metronidazole	1	2	
Cefuroxime	12	16	
Cefuroxime + metronidazole	2	7	
Ampicillin	3	3	
Clindamycin	0	2	
Metronidazole	1	2	
Other (combination)	0	0	
Postoperative antibiotics			
Yes	44	57	.0088
No	6	0	
Penicillin G/V	26	30	
Penicillin G/V + metronidazole	1	3	
Cephalosporin	12	7	
Cephalosporin + metronidazole	2	5	
Aminopenicillin (ampicillin, amoxicillin)	0	0	
Aminopenicillin (ampicillin, amoxicillin) + clavulanic acid	1	0	
Clindamycin	0	2	
Other (combination)	2	10	
Postoperative chlorhexidine mouth rinse			
Yes	45	53	.73
No	5	4	

^aMedian 5 days.

31.8 days, median 19.5 days). One patient needed re-surgery for SSI and non-union 4 weeks after primary surgery. In all, fixation material was removed in 10 of 18 patients (55.6%). Primary reduction and/or fixation was assessed as slightly suboptimal in two patients: one because of a small and fragmented bone piece fixated with a screw and the other because of inadequate primary stability (only one plate was placed in the parasymphysis area).

Discussion

We evaluated the occurrence of SSI and predisposing factors to it in intraorally treated simple mandibular fractures. We hypothesized that the timing and duration of antibiotic therapy do not affect SSI occurrence. Our hypothesis was confirmed; no association was found between the duration of antibiotic medication and SSIs. However, the infection occurrence was surprisingly high (16.8%). TDI or other patient-related variables did not explain the rate. Even though, when obvious, already known risk factors for infection, such as fractures of the angular region, infections of endodontic causes, and primarily infected fractures, were excluded, SSI risk remained high in simple mandibular fractures of the dentate

area (Figure 2). Our findings indicate that local as well as surgical factors for infection risk warrant further investigations.

Mandibular fractures are known to be prone to postoperative infections. Reported infection rates vary between 7.5% and 17.7% [8,10,11,18–21]. The site of the fracture relates significantly with postoperative infections as well as the surgical approach. Particularly fractures of dentate part of the mandible are known to be prone to infections [22]. In addition, intraorally treated fractures associate with infections [18]. The overall SSI-rate in our study was 16.8%, which is in line with the previous reports of intraorally treated dentate part mandibular fractures. Due to the known infection risk, the use of antibiotic medication has been considered in several studies.

Short-term antibiotic medication has shown to be sufficient in mandibular fracture surgery [4,19,22,23]. Perepa et al. [24] observed in their prospective study that a one-day antibiotic regimen was as effective as a 5-day regimen in reducing postoperative complications after intraorally treated mandibular fractures. Our study is in line with these previous studies. Short-term antibiotic use was as effective as long-term course in infection reduction. On the other hand, according to our results, infections occur despite antibiotic treatment. Therefore, the focus should be on local factors and surgical techniques.

Table 4. Explanatory variables and postoperative surgical site infection in 107 mandibular fracture patients.

	Surgical site infection		No infection		<i>p</i> Value
	<i>n</i>	% of <i>n</i>	<i>n</i>	% of <i>n</i>	
All (n)	18		89		–
Age, years					
Range	18–61		18–89		.66
Mean	35.10		37.90		
Median	33		34		
Modified Total Dental Index (TDI)					
Range	0–5		0–8		.22
Mean	2.17		1.79		
Median	2		1		
Treatment delay from accident to surgery, days					
Range	0–8		0–6		.14
Mean	2.22		1.54		
Median	2		1		
No. of plates					
Range	0–2		0–2		.97
Mean	1.78		1.75		
Median	2		2		
No. of lag screws					
Range	0–3		0–3		.92
Mean	0.22		0.21		
Median	0		0		
No. of teeth extracted for poor dental condition (no trauma teeth)					
Range	0–3		0–12		.90
Mean	0.33		0.53		
Median	0		0		
	<i>n</i>	% of <i>n</i>	<i>n</i>	% of <i>n</i>	
Sex					
Male	16	19.0	68	81.0	.35
Female	2	8.7	21	91.3	
Smoking					
Yes	10	27.0	27	73.0	.057
No	8	11.4	62	88.6	
Alcohol and/or drug abuse					
Yes	7	28.0	18	72.0	.12
No	11	13.4	71	86.6	
Immunosuppressive condition					
Yes	0	0.0	3	100.0	1
No	18	17.3	86	82.7	
Injury mechanism					
Assault	11	23.4	36	76.6	.37
Traffic accident	2	7.7	24	92.3	
Falling on ground	5	17.9	23	82.1	
Falling ≥ 3 m	0	0)	2	100	
Struck by an object	0	0)	4	100	
Fracture site					
Body	2	18.2	9	81.8	1
Symphysis/parasymphysis	16	16.7	80	83.3	
Tooth removal (any)					
Yes	3	15.8	16	84.2	1
No	15	17.0	73	83.0	
Tooth removal from fracture line					
Yes	1	100.0	0	0.0	.17
No	17	16.0	89	84.0	
Tooth removal during surgery for poor dental condition					
Yes	3	15.8	16	84.2	1
No	15	17.0	73	83.0	
Comminution of the fracture					
Non-comminuted	17	16.8	84	83.2	1
Comminuted	1	16.7	5	83.3	
Minor comminution	1	25.0	3	75.0	
Major comminution	0	0	2	100	

Improper fixation and excessive torque during screw placement may predispose to postoperative complications [8]. Alternatively, the probability of postoperative complications may be linked to surgical experience [25]. In this study, the experience of the surgeon was not determined; however, a slightly suboptimal fixation was found in two patients. In addition to optimal fracture reduction and handling of the

bone fragment, careful soft tissue management and wound closure should be considered. For example, inappropriate use of diathermy may impair tissue healing in the oral mucosal region [26,27]. Excessive compression of the bony fragments in fracture reduction can also cause postoperative complications [28]. Interestingly, SSIs occurred over a wide time span, from five days to more than three months. This suggests several different aetiological causes.

Alcohol and drug abuse as well as smoking are associated with long-term complications after mandibular fracture surgery [19,29]. Furthermore, in a retrospective study by Hall et al., [30] alcohol and drug abusers with carious teeth had a higher postoperative complication rate after mandibular fracture surgery. Although the differences were not statistically significant, SSI occurrence was higher in smokers and alcohol and/or drug abusers than in other patients in our study. Also, TDI was higher in patients with SSI than in those without. Thus, due to high SSI occurrence in general in these single fractures and to reduce oral infection load, dental condition should also be evaluated. Affected teeth should be extracted during mandibular fracture surgery. The importance of dental expertise in the treatment of mandibular fractures should thus be noted.

Use of chlorhexidine was recommended for most patients in our study (98 of 107, 91.6%). To decrease the oral microbial load, postoperative chlorhexidine mouthwash can be recommended [31] as a short course to improve patient's oral hygiene. Postoperatively, patients should be motivated to maintain careful oral hygiene and to reduce or quit smoking; dentists and oral hygienists could therefore be part of the medical team taking care of overall oral health to enhance mandibular fracture treatment.

Fractures in the tooth-bearing area of the mandible predispose to traumatic dental injury and a pathologic process in the periodontal and periapical areas can lead to SSI [32]. Thus, the status of the teeth in the fracture line should be inspected after mandibular surgery. In the present study, none of the SSIs were related to dental infections due to our exclusion criteria. However, the high infection rate raises the suspicion that the tooth-bearing area maintains constant open contact with the fracture area even if the tooth itself is not infected.

The main limitation of this study is its retrospective design. In addition, statistically significant findings might have been obtained with a larger number of patients. Furthermore, we did not control medication adherence, and thus, we do not know whether patients were taking the antibiotics or other medications prescribed to them postoperatively.

In conclusion, considering the notable number of SSIs in these primarily non-complicated intraorally treated fractures despite antibiotic treatment, the role of perioperative tissue handling and local oral circumstances in SSIs during simple mandibular fracture surgery warrants further evaluation and should be emphasized in clinical work. To prevent postoperative infections, focus should be more on local factors instead of antibiotic medication.

Table 5. Antibiotic use in 107 mandibular fracture patients.

	Surgical site infection		No infection		<i>p</i> Value
Duration of postoperative antibiotic course, days					
Range	0–9		0–26		.087
Mean	3.44		5.04		
Median	4		5		
Total duration of antibiotic course, days					
Range	1–11		1–27		.23
Mean	5.17		6.34		
Median	5		6		
Preoperative antibiotics					
	n	% of n	n	% of n	
Yes	13	15.1	73	84.9	.34
No	5	23.8	16	76.2	
Penicillin G/V	12	20.3	47	79.7	
Penicillin G/V + metronidazole	0	0	3	100	
Cephalosporin	0	0	10	100	
Cephalosporin + metronidazole	0	0	8	100	
Aminopenicillin (ampicillin, amoxicillin)	0	0	0	0	
Aminopenicillin (ampicillin, amoxicillin) + clavulanic acid	0	0	2	100	
Clindamycin	0	0	2	100	
Other (combination)	1	50	1	50	
Antibiotics in anaesthesia induction					
Yes	18	17.0	88	83.0	1
No	0	0	1	100	
Penicillin G	13	23.6	42	76.4	
Penicillin G + metronidazole	0	0	3	100	
Cefuroxime	5	17.9	23	82.1	
Cefuroxime + metronidazole	0	0	9	100	
Ampicillin	0	0	6	100	
Clindamycin	0	0	2	100	
Metronidazole	0	0	3	100	
Other (combination)	0	0	0	0	
Postoperative antibiotics					
Yes	16	15.8	85	84.2	.27
No	2	33.3	4	66.7	
Penicillin G/V	11	19.6	45	80.4	
Penicillin G/V + metronidazole	1	25.0	3	75.0	
Cephalosporin	3	15.8	16	84.2	
Cephalosporin + metronidazole	1	14.3	6	85.7	
Aminopenicillin (ampicillin, amoxicillin)	0	0	0	0	
Aminopenicillin (ampicillin, amoxicillin) + clavulanic acid	0	0	1	100	
Clindamycin	0	0	2	100	
Other (combination)	0	0	12	100	
Postoperative chlorhexidine mouth rinse					
Yes	15	15.3	83	84.7	.17
No	3	33.3	6	66.7	

Table 6. Variables of patients with surgical site infection.

All (n)	18
Days between surgery and postoperative infection	
Range	5–106
Mean	31.83
Median	19.5
	n (%)
Refixation for infection	
Yes	1 (5.6)
No	17 (94.4)
Plate(s) removed	
Yes ^a	10 (55.6)
No	8 (44.4)
Suboptimal reduction and/or fixation	
Yes	2 (11.1)
No	16 (88.9)

^aRefixation included.

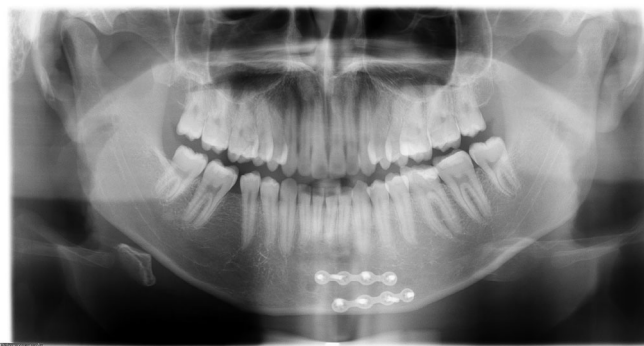

Figure 2. A healthy non-smoking 18-year-old male without history of alcohol and/or substance abuse sustained a mandibular parasymphysis fracture in a traffic accident. The fracture was operated on two days after injury. Postoperative dental panoramic tomography image shows optimal fixation with two miniplates and screws. A postoperative antibiotic regimen (Penicillin V) of four days was prescribed. Despite adequate fracture treatment, the patient had a surgical site infection nine days postoperatively without any clinically significant cause.

Disclosure statement

The authors report no conflict of interest.

Funding

The authors received no financial support for this article.

References

- [1] Ellis E, Miles BA. Fractures of the mandible: a technical perspective. *Plast Reconstr Surg.* 2007;120(7):76–89.
- [2] de Matos FP, Arnez MFM, Sverzut CE, et al. A retrospective study of mandibular fracture in a 40-month period. *Int J Oral Maxillofac Surg.* 2010;39(1):10–15.
- [3] Goodday RHB. Management of fractures of the mandibular body and symphysis. *Oral Maxillofac Surg Clin North Am.* 2013;25(4):601–616.
- [4] Shridharani SM, Berli J, Manson PN, et al. The role of postoperative antibiotics in mandible fractures: a systematic review of the literature. *Ann Plast Surg.* 2015;75(3):353–357.
- [5] Habib AM, Wong AD, Schreiner GC, et al. Postoperative prophylactic antibiotics for facial fractures: a systematic review and Meta-analysis. *Laryngoscope.* 2019;129(1):82–95.
- [6] Lamphier J, Ziccardi V, Ruvo A, et al. Complications of mandibular fractures in an urban teaching center. *J Oral Maxillofac Surg.* 2003;61(7):745–749.
- [7] Milic T, Raidoo P, Gebauer D. Antibiotic prophylaxis in oral and maxillofacial surgery: a systematic review. *Br J Oral Maxillofac Surg.* 2021;59(6):633–642.
- [8] Gutta R, Tracy K, Johnson C, et al. Outcomes of mandible fracture treatment at an academic tertiary hospital: a 5-year analysis. *J Oral Maxillofac Surg.* 2014;72(3):550–558.
- [9] Munding GS, Borsuk DE, Okhah Z, et al. Antibiotics and facial fractures: evidence-based recommendations compared with experience-based practice. *Craniofacial Trauma Reconstr.* 2015;8(1):64–78.
- [10] Lee CC, Hajibandeh JT, Tannyhill RJ, et al. Is outpatient management of mandibular fractures associated with inflammatory complications? An ACS-NSQIP study. *J Oral Maxillofac Surg.* 2021;79(12):2507–2518.
- [11] Schaefer EH, Catterson EJ. Antibiotic selection for open reduction internal fixation of mandible fractures. *J Craniofac Surg.* 2013;24(1):85–88.
- [12] Malanchuk V, Kopchak A. Risk factors for development of infection in patients with mandibular fractures located in the tooth-bearing area. *J Craniofacial Trauma Reconstr.* 2007;35(1):57–62.
- [13] Snäll J, Kormi E, Lindqvist C, et al. Pulp necrosis of teeth retained at the mandibular fracture site and the effect of dexamethasone on its occurrence. *Dent Traumatol.* 2015;31(2):136–139.
- [14] Working group appointed by the Finnish Medical Society Duodecim and the Finnish Society of Addiction Medicine: Treatment of alcohol abuse [Internet]. The Finnish Medical Society Duodecim. 2018. [cited 2021 Jun 24]. Available from: www.kaypahoito.fi/.
- [15] Mattila K, Nieminen M, Valtonen V, et al. Association between dental health and acute myocardial infarction. *BMJ.* 1989;298(6676):779–781.
- [16] Virtanen E, Nurmi T, Söder P-Ö, et al. Apical periodontitis associates with cardiovascular diseases: a cross-sectional study from Sweden. *BMC Oral Health.* 2017;17(1):1.
- [17] Cornelius C-P, Audigé L, Kunz C, et al. The comprehensive AOCMF classification system: mandible fractures-Level 3 tutorial. *Craniofacial Trauma Reconstr.* 2014;7(1_suppl):31–43.
- [18] Odom EB, Snyder-Warwick AK. Mandible fracture complications and infection: the influence of demographics and modifiable factors. *Plast Reconstr Surg.* 2016;138(2):282e–289e.
- [19] Domingo F, Dale E, Gao C, et al. A single-center retrospective review of postoperative infectious complications in the surgical management of mandibular fractures: postoperative antibiotics add no benefit. *J Trauma Acute Care Surg.* 2016;81(6):1109–1114.
- [20] Gaal A, Bailey B, Patel Y, et al. Limiting antibiotics when managing mandible fractures may not increase infection risk. *J Oral Maxillofac Surg.* 2016;74(10):2008–2018.
- [21] Czerwinski M, Parker WL, Correa JA, et al. Effect of treatment delay on mandibular fracture infection rate. *Plast Reconstr Surg.* 2008;122(3):881–885.
- [22] Andreasen JO, Jensen SS, Schwartz O, et al. A systematic review of prophylactic antibiotics in the surgical treatment of maxillofacial fractures. *J Oral Maxillofac Surg.* 2006;64(11):1664–1668.
- [23] Miles BA, Potter JK, Ellis E. The efficacy of postoperative antibiotic regimens in the open treatment of mandibular fractures: a prospective randomized trial. *J Oral Maxillofac Surg.* 2006;64(4):576–582.
- [24] Perepa A, Sinha R, Agarwal A, et al. Protocol for antibiotic administration in mandibular trauma: a prospective clinical trial. *J Maxillofac Oral Surg.* 2018;17(1):19–23.
- [25] Jerjes W, El-Maaytah M, Swinson B, et al. Experience versus complication rate in third molar surgery. *Head Face Med.* 2006;2(1):14.
- [26] Wahab PUA, Madhulaxmi M, Senthilnathan P, et al. Scalpel versus diathermy in wound healing after mucosal incisions: a split-mouth study. *J Oral Maxillofac Surg.* 2018;76(6):1160–1164.
- [27] Siddaiah-Subramanya M, Tiang KW, Nyandowe M. Complications, implications, and prevention of electrosurgical injuries: corner stone of diathermy use for junior surgical trainees. *Surg J.* 2017;03(04):e148–153.
- [28] Iizuka T, Lindqvist C, Hallikainen D, et al. Infection after rigid internal fixation of mandibular fractures: a clinical and radiologic study. *J Oral Maxillofac Surg.* 1991;49(6):585–593.
- [29] Furr AM, Schweinfurth JM, May WL. Factors associated with long-term complications after repair of mandibular fractures. *Laryngoscope.* 2006;116(3):427–430.
- [30] Hall SC, Ofodile FA. Mandibular fractures in an American inner city: the Harlem hospital center experience. *J Natl Med Assoc.* 1991;83(5):421–423.
- [31] Brookes ZLS, Bescos R, Belfield LA, et al. Current uses of chlorhexidine for management of oral disease: a narrative review. *J Dent.* 2020;103:103497.
- [32] Kamboozia AH, Punnia-Moorthy A. The fate of teeth in mandibular fracture lines. A clinical and radiographic follow-up study. *Int J Oral Maxillofac Surg.* 1993;22(2):97–101.