



CT characterisation and classification of feline temporomandibular joint trauma: a case series of 79 cats

Journal of Feline Medicine and Surgery
1–6

© The Author(s) 2022

Article reuse guidelines:

sagepub.com/journals-permissions

DOI: 10.1177/1098612X211066654

journals.sagepub.com/home/jfm

This paper was handled and processed by the European Editorial Office (ISFM) for publication in *JFMS*



Lisa A Mestrinho¹, Sónia SF Sebastião², Maciej A Zwierucho^{3*}, Aaron Lutchman⁴, Lorrie Gaschen⁵, Stephanie Goldschmidt⁶, Graham Thatcher⁷, Yu Izumisawa⁸ and Richard L Meeson⁴

Abstract

Objectives The aim of this study was to characterise and describe patterns of temporomandibular joint (TMJ) injuries occurring in cats using CT.

Methods A cross-sectional study was carried out in adherence with the STROBE guidelines. Among the medical and CT records of 79 cats, 158 TMJs were reviewed in a collaborative study between six institutions.

Results TMJ injuries were most commonly unilateral, representing 70.9% of cases. The mandibular condyle was fractured in 88 cases (55.7%) of the 158 TMJs observed. Of those, 84.0% were intra-articular condyle fractures, with the medial half of the mandibular condyle over-represented. Luxations occurred in 32.9% of cases, which was 19.0% of all evaluated TMJs. Rostradorsal luxations were most common representing 87.0% of all luxations. Temporal bone fractures were observed in 30.4% of all cases, which was 18.4% of TMJs. The majority of fractures were of an unknown cause. When the cause was determined, road traffic accident (RTA) was the most frequent, followed by animal interaction, other external forces (sharp or blunt force) and high-rise trauma. Bilateral injuries were 13.1 times more likely to occur in high-rise trauma ($P=0.01$) and temporal bone fracture was significantly associated with RTAs ($P=0.016$). No other significant associations were observed between cause of injury and the resulting TMJ injury pattern.

Conclusions and relevance Various TMJ injury patterns can occur in cats as a result of trauma. Intra-articular fractures of the medial half of the mandibular condyle occur most commonly. Although unilateral injuries are more frequent, high-rise trauma tends to present with bilateral lesions. Further studies with a larger sample size should be performed to better understand TMJ patterns of injury and how they relate to possible causes.

Keywords: Temporomandibular joint; fracture; luxation; mandible

Accepted: 26 November 2021

¹CIISA, Interdisciplinary Research Centre for Animal Health, Faculty of Veterinary Medicine, University of Lisbon, Lisbon, Portugal

²Vets4Pets, Fosse Park, Leicester, UK

³Faculty of Veterinary Medicine, University of Lisbon, Lisbon, Portugal

⁴Department Clinical Science and Services, Queen Mother Hospital for Animals, Royal Veterinary College, University of London, Hertfordshire, UK

⁵Department of Veterinary Clinical Sciences, School of Veterinary Medicine, Louisiana State University, Baton Rouge, LA, USA

⁶College of Veterinary Medicine, University of Minnesota, Paul, MN, USA

⁷School of Veterinary Medicine, University of Wisconsin-Madison, Madison, WI, USA

⁸Department of Clinical Sciences, College of Veterinary Medicine, Cornell University, Ithaca, NY, USA

*Deceased

Corresponding author:

Lisa A Mestrinho DVM, MSc, PhD, CIISA, Interdisciplinary Research Centre for Animal Health, Faculty of Veterinary Medicine, Lusófona University, Av da Universidade Técnica, Lisbon 1300-477, Portugal

Email: lmestrinho@fmv.ulisboa.pt

Introduction

Fractures involving the temporomandibular joint (TMJ) account for between 50% and 56% of all maxillofacial fractures.^{1–3} The most frequent cause depends on the studies reported, and include road traffic accident (RTA)^{2,3} and high-rise trauma.¹ Although these studies described mandibular injuries in some detail, TMJ injuries were only assessed using plain film radiography.^{1–3} Considering the reported 10% prevalence of ankylosis after TMJ trauma¹ there is a need to further understand, in more detail, which TMJ injuries might lead to ankylosis, in order to guide the preoperative decision-making. In human oral and maxillofacial surgery, CT is the preferred method of imaging complex fractures as it allows the high-quality assessment of the cortical bone.⁴

TMJ fracture patterns in cats have not been previously characterised by CT despite several publications reporting maxillofacial trauma in this species.^{2,3,5} Therefore, the aim of this study was to use CT to classify TMJ fracture configurations in cats and to understand how that relates to cause.

Materials and methods

A cross-sectional study was carried out in adherence to the STROBE checklist.⁶

CT scans and the clinical records of cats presenting with a TMJ injury were retrospectively reviewed from six international university veterinary hospitals. Cats had to have presented with suspected or witnessed trauma and have no history of prior trauma or documented skeletal abnormalities.

Records from clinical cases with a diagnosis of maxillofacial trauma were consulted retrospectively, from 2007 to 2021: 34 cases were from the University of London's Royal Veterinary College (2010–2020), 18 from the College of Veterinary Medicine, Cornell University (2007–2020), 10 cases from the Faculty of Veterinary Medicine, University of Lisbon (2020–2021), eight cases from the College of Veterinary Medicine, University of Minnesota (2008–2021), five cases from the School of Veterinary

Medicine, University of Wisconsin-Madison (2010–2020) and four cases from the Louisiana State University School of Veterinary Medicine (2007–2019).

The CT equipment used included the Aquilion 64, Aquilion 16 and Astelion 16 (Toshiba Medical Systems); Aquilion ONE Genesis Edition (Canon Medical Systems); and the GE Light Speed 16 and 8 (GE Healthcare).

Clinical variables including age and weight and cause of the injury were analysed.

CT images of 79 cases were reviewed by three authors and a consensus was reached. A total of 158 TMJs were evaluated individually. TMJ injury classification was adapted from Arzi and Lantz⁷ and from Neff et al,⁸ and classified according to the following criteria: presence of subluxation; luxation (rostradorsal vs ventrocaudal); or fracture. Fractures were classified as extra-articular or intra-articular. Intra-articular fractures were classified into type A = lateral 1/2, type B = medial 1/2, type C = comminuted, type D = simple with mandibular fossa (MF) fracture and type E = comminuted with MF fracture (Figure 1). Extra-articular fractures were classified into without override, with lateral override, with medial override or comminuted (Figure 2). Fracture of the temporal bone that makes up the mandibular fossa was also recorded (Figure 3). Finally, unilateral or bilateral occurrence was recorded.

Results were evaluated using commercial software packages for the calculation of descriptive (Microsoft Excel for Mac version 16.49) and inferential statistics (IBM SPSS Statistics for Mac version 26). Categorical variables were expressed as frequencies. χ^2 tests or Fisher's exact tests were used to assess the association between injury patterns. To determine the effects of cause on injury patterns, univariate logistic regression was used. A *P* value <0.05 was considered significant for a 95% confidence interval.

Results

CT scan slice thickness and pitch for all examinations ranged from 0.3 to 1.3mm and from 0.5 to 1 mm, respectively.

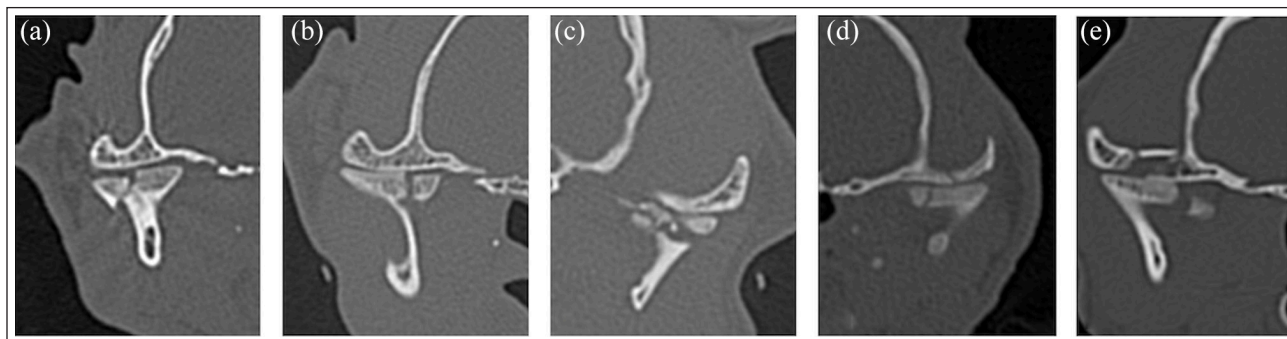


Figure 1 Intra-articular temporomandibular joint fractures in axial slice (a) of the lateral half, (b) medial half, (c) comminuted, (d) simple with mandibular fossa fracture and (e) comminuted with mandibular fossa fracture

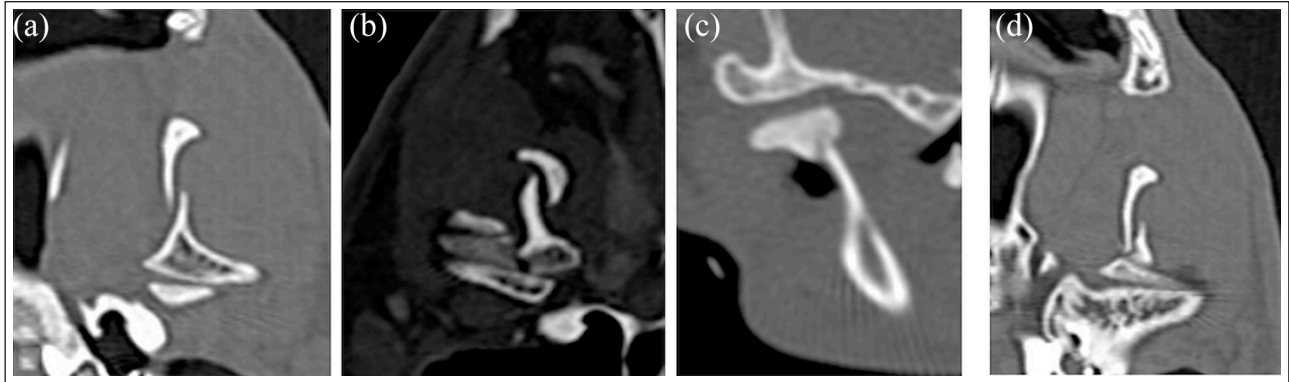


Figure 2 Extra-articular temporomandibular joint fractures (a) with lateral override in coronal slice, (b) with medial override, (c) without override and (d) comminuted

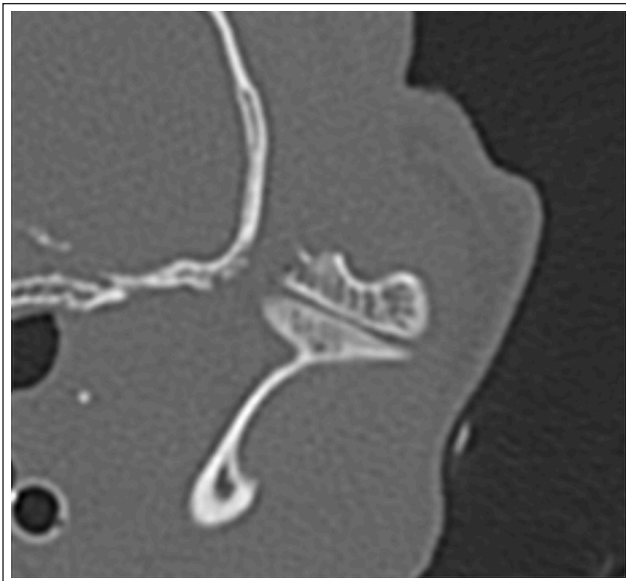


Figure 3 Axial slice of a fracture of the temporal bone at the level of the mandibular fossa

Demographics and classification of injuries

Of the 79 clinical cases included in the study, 49 were male (62%) and 30 were female (37%). One case did not have a recorded age. Mean \pm SD age and weight were 5.02 ± 3.96 years and 4.48 ± 1.39 kg, respectively.

Unilateral injuries were present in 56 cases (71%) and bilateral injuries in 23 cases (29%). TMJ luxation was observed in 26 cases (32.9%) and subluxation was observed in 17 cases (21.5%). Some type of fracture occurred in 68 cases (86.1%). Mandibular condyle fractures were found in 67 cases (84.8%) and temporal bone fracture in 24 (30.4%). Intra-articular fractures occurred in 61 cases (77.2%) and extra-articular in 26 cases (32.9%).

When assessing the 158 TMJs individually, 220 total injuries were identified, including coexisting mandibular fractures (see Table 1 in the supplementary material). Thirty were luxations (19.0%) and 17 were subluxations

(10.8%). Of the 30 luxations observed, 26 (87%) were rostradorsal and four (13.3%) caudoventral. In four cases, the luxation injuries were bilateral and were all rostradorsal on both sides. Caudoventral luxations were always unilateral.

The mandibular condyle was fractured in 88 cases (55.7%) of the 158 TMJs observed. In the 88 mandibular condyle fractures, a total of 105 injury types were observed. Of those, 76 were intra-articular and 29 were extra-articular. In 15 mandibular condyles intra- and extra-articular fractures were simultaneously observed. The relative probability of mandibular condyle fracture patterns is illustrated in Figure 4. With regard to intra-articular fracture type, medial intra-articular fractures were the most common (30/105 fractures [28.6%]). With regard to extra-articular fractures, comminuted fractures were the most common and represented 20/105 fractures (19.0%) (Figure 4). Temporal bone fractures (including or not glenoid fossa) were observed in 31/158 TMJs (19.6%). Fractures beyond the condylar neck were registered as coexisting mandibular fractures, observed in 32 cases (40.5%).

No significant associations were found between the following variables: luxation, fracture of the pars squamosa of the temporal bone, and extra-articular and intra-articular fractures. There was also no significant association with the presence of coexisting mandibular fractures. However, intra-articular fractures were significantly associated with the presence of temporal bone fracture (odds ratio [OR] 3.2, 95% confidence interval [CI] 1.35–7.54; $P = 0.008$).

Cause of injury

A considerable number of the fractures were of unknown cause ($n = 25$ [31.6%]). When cause was determined, RTA was the most frequent ($n = 26$ [32.9%]), followed by animal interaction ($n = 13$ [16.5%]), external sharp or blunt force ($n = 8$ [10.1%]) and high-rise trauma ($n = 7$ [8.9%]) (see Table 2 in the supplementary material).

No significant associations were found between the cause of injury (RTA, high-rise trauma, animal interaction

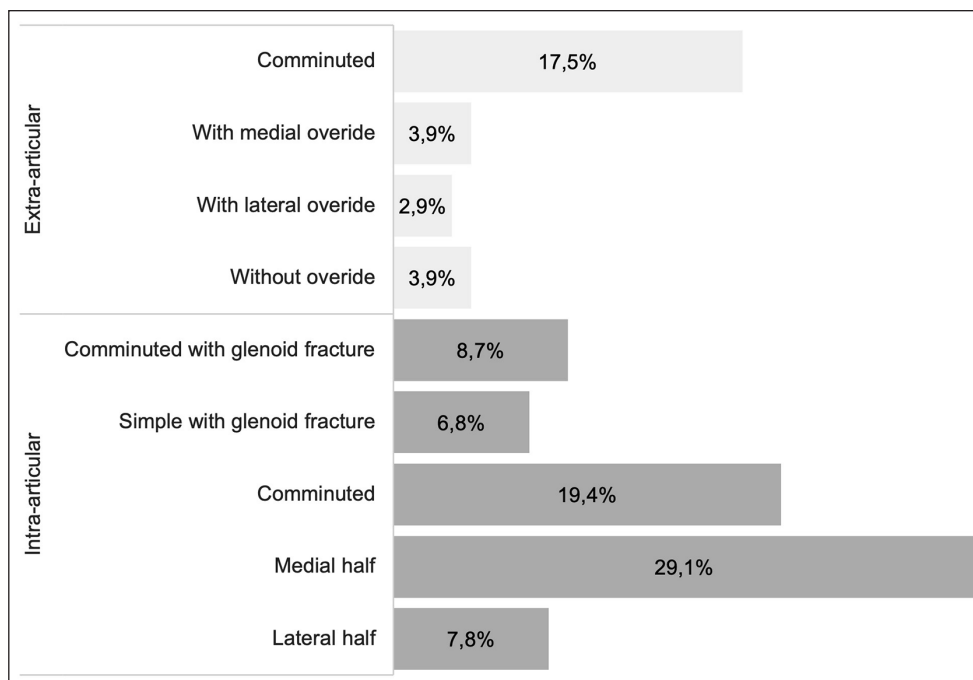


Figure 4 Relative probability of 105 mandibular condyle fracture patterns

Table 1 Odds ratio of bilateral injury according to cause

	Beta	P value	OR	95% CI
RTA	1.19	0.08	3.28	0.87–12.40
High-rise trauma	2.58	0.01	13.13	1.85–92.96
Animal interaction	0.45	0.60	1.58	0.30–8.41
External sharp or blunt force	-0.29	0.81	0.75	0.07–7.88

OR calculated using the unknown cause as reference

P values in bold are statistically significant

OR = odds ratio; CI = confidence interval; RTA = road traffic accident

or other external force) and its pattern (luxation, subluxation, the presence of temporal bone fracture, intra-articular fracture, extra-articular fracture and coexisting mandibular fractures). However, bilateral injury was significantly associated with high-rise trauma (OR 13.13, 95% CI 1.85–92.96; $P = 0.01$) (Table 1).

Distribution of the causes of TMJ injuries are illustrated in Figure 5. Mandibular condyle fractures were the most frequent TMJ injury for all causes. Mandibular condyle fractures of the medial half were the most frequently registered lesion secondary to all causes, especially high-rise trauma. Temporal bone fractures and coexisting mandibular injuries were observed in all causes except in high-rise trauma. In RTA cases, the most frequently seen lesion was temporal bone fracture. Of all temporal bone fractures where cause was established (21 in total), 69.6% were due to RTAs; this association was significant ($P = 0.016$).

Discussion

This study is the first to report and characterise TMJ injury patterns with regard to cause, using CT. Prior to this, these injuries had only been reviewed using plain film radiography.¹ CT allowed a more detailed evaluation of the different injury configurations that were missed or underestimated in previous studies. CT is considered superior to plain radiography for evaluation of the TMJ as it allows a three-dimensional assessment of lesions, overcoming the superimposition of anatomical structures.^{5,9,10} The cases were collected by six separate institutions, all of which are referral practices. The prevalence of the injuries reported here cannot reflect the true prevalence of these injuries in first opinion practices, albeit traumatic maxillofacial injuries are common in cats.¹

RTA was the most frequently reported cause of TMJ injury, followed by animal interaction, external force and high-rise trauma. While RTA was the most frequently reported cause of maxillofacial trauma in an English study,³ a study from Turkey reported high-rise trauma as the most common cause.¹ These differences are likely to be the result of regional differences in the home environment and lifestyle. For example, urban areas with multilevel buildings can increase the risk of high-rise trauma. In our case series all the high-rise trauma cases were reported from the same institution, located within an urban area, which supports this speculation (see Table 2 in the supplementary material).

Trends were observed between the cause of trauma and injury pattern. In RTA cases, most of the defined types of TMJ injuries were observed. The same was true

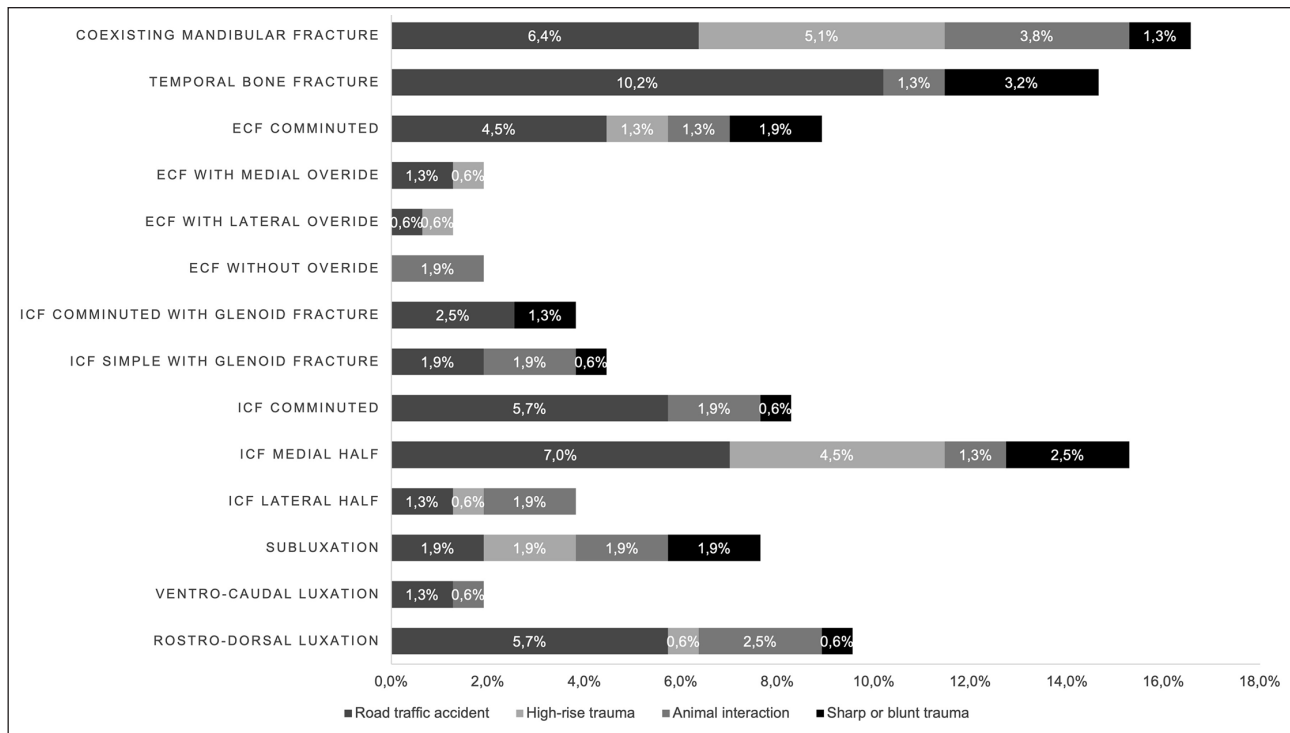


Figure 5 Distribution of injuries according to cause in 108 temporomandibular joints with 157 injuries (injuries of unknown causes were excluded from the distribution). ECF = extra-articular condylar fractures; ICF = intra-articular condylar fractures

for blunt trauma and animal interaction. The variability of TMJ injuries is likely to be the result of the direction of force, velocity and severity of the impact. Conversely, we reported less variability in TMJ injuries in high-rise trauma, which were significantly more likely to be bilateral. In these cases, intra-articular fractures (comminuted or of the medial half) and extra-articular fractures (comminuted or with lateral override) were mostly observed. This lower injury variability is most likely due to the specificity in force direction, which is always in the rostrocaudal direction. In one previous study, the author also observed fewer TMJ injuries per cat in high-rise trauma, compared with RTA.¹ Interestingly, the same author reports a significantly higher number of isolated and bilateral TMJ injuries, namely caudal luxation or condylar process fractures, in high-rise trauma.¹ In our study, ventrocaudal luxations were not observed in high-rise trauma. On the contrary, all cases of luxation were rostradorsal and in a lower proportion compared with other causes. Luxations were more frequently observed in RTAs and animal interactions.

The classification adopted was able to accommodate all TMJ injury patterns encountered in this case series. Differences between fractures of the mandibular head and condyle can be difficult to distinguish in cats because the condyle neck is very short. Therefore, TMJ injury classification was adapted from the Arbeitsgemeinschaft für Osteosynthesefragen – Craniomaxillofacial (AOCMF),⁸ considering the recommendations by Arzi and Lantz

using intra- and extra-articular fractures instead of intra- and extracapsular.⁷ Additionally, the term ‘luxation’ rather than ‘dislocation’ was used.

Intra-articular fractures occurred more frequently than extra-articular fractures. The medial half the mandibular condyle was the most frequent intra-articular fracture. Comminuted fractures were more often extra-articular. These observations suggest that the medial half of the mandibular condyle and the neck, albeit very short, are less resistant to load. The mandibular condyle has thinner cross-sectional areas at the level of the neck and, consequently, can be less resistant to direct or indirect force. As the TMJ functions as a shock absorber that dissipates transmitted forces,¹¹ it seems logical that this area might be a weak anatomical point. The observation of this fracture type as an isolated injury in 11 cases also supports this theory.

Temporal bone fractures were the least frequent TMJ injury (18.3% of 158 TMJs). The squamous portion of the temporal bone appears to have higher resistance to fracture. The force vector and direction of the trauma are also relevant in the occurrence of fracture or luxation. Temporal bone fracture was significantly associated with RTAs, being the most frequently seen injury, compared with the complete absence of this kind of injury in high-rise trauma. These observations suggest that the squamous portion of the temporal bone seems to be more resistant to a perpendicular vector, which occurs in high-rise trauma, and less resistant to more oblique vectors of

force in RTAs. The impact of the perpendicular/frontal vectors of force seen in high-rise trauma is felt simultaneously in the two temporal bones, potentiating the resistance to fracture, and the predisposition to bilateral injuries, which are also observed in these cases. In comparison, the force vectors in RTAs are more variable and more oblique in direction.

In approximately one-third of the cases evaluated in this study, TMJ luxation or subluxation was observed. Of these, the great majority were rostradorsal luxations, similar to a previous study.¹ Furthermore, all caudovertral luxations were unilateral and bilateral luxations were all rostradorsal. This fact reinforces rostral luxation as the most likely to occur and this may be explained by the joint angle and congruence, as well as the mandibular fossa, offering resistance to the caudal dislocation of the mandibular condyle.

Limitations of this study were a direct consequence of the number of cases and the intrinsic variability associated with the multi-institutional concept and retrospective data analysis. Variations of CT algorithms (slice and pitch) between institutions were also a factor and in three cases led to small anatomical gaps that could have inhibited a proper assessment. More standardised CT algorithms would have negated this limitation.

Conclusions

Unilateral TMJ injury patterns, especially intra-articular fractures of the medial half of the mandibular condyle, occur most frequently in cats following trauma. In cases of high-rise trauma these injuries tend to be bilateral.

Further studies using a larger number of cases should be performed in order to better understand TMJ patterns of injury.

Acknowledgements The authors thank Santiago Peralta and Nadine Fiani for their contribution to this study. This manuscript is dedicated to Maciej Zwierucho, an exceptional young man, who sadly passed away during this research.

Supplementary material The following files are available online:

Table 1: Distribution of injuries according to cause in 158 temporomandibular joints.

Table 2: Distribution of causes and injury extent per institution.

Conflict of interest The authors declared no potential conflicts of interest with respect to the research, authorship, and/or publication of this article.


Funding Part of this work was supported by FCT - Fundação para a Ciência e Tecnologia IP, grant UIDB/00276/2020 (LM).


Ethical approval The work described in this manuscript involved the use of non-experimental (owned or unowned) animals. Established internationally recognised high standards ('best practice') of veterinary clinical care for the individual patient were

always followed and/or this work involved the use of cadavers. Ethical approval from a committee was therefore not specifically required for publication in *JFMS*. Although not required, where ethical approval was still obtained, it is stated in the manuscript.

Informed consent Informed consent (verbal or written) was obtained from the owner or legal custodian of all animal(s) described in this work (experimental or non-experimental animals, including cadavers) for all procedure(s) undertaken (prospective or retrospective studies). No animals or people are identifiable within this publication, and therefore additional informed consent for publication was not required.

ORCID ID Lisa A Mestrinho  <https://orcid.org/0000-0002-2424-2106>

Graham Thatcher  <https://orcid.org/0000-0002-0586-3214>

Richard L Meeson  <https://orcid.org/0000-0002-8972-7067>

References

- Çetinkaya MA. **Temporomandibular joint injuries and ankylosis in the cat.** *Vet Comp Orthop Traumatol* 2012; 25: 366–374.
- Knight R and Meeson RL. **Feline head trauma: a CT analysis of skull fractures and their management in 75 cats.** *J Feline Med Surg* 2019; 21: 1120–1126.
- Tundo I, Southerden P, Perry A, et al. **Location and distribution of craniomaxillofacial fractures in 45 cats presented for the treatment of head trauma.** *J Feline Med Surg* 2019; 21: 322–328.
- Nardi C, Vignoli C, Pietragalla M, et al. **Imaging of mandibular fractures: a pictorial review.** *Insights Imaging* 2020; 11: 30. DOI: 10.1186/s13244-020-0837-0.
- Arzi B, Cissell DD, Verstraete FJ, et al. **Computed tomographic findings in dogs and cats with temporomandibular joint disorders: 58 cases (2006–2011).** *J Am Vet Med Assoc* 2013; 242: 69–75.
- von Elm E, Altman DG, Egger M, et al. **STROBE initiative. The Strengthening the Reporting of Observational Studies in Epidemiology (STROBE) statement: guidelines for reporting observational studies.** *Int J Surg* 2014; 12: 1495–1499.
- Arzi B and Lantz GC. **Fractures and luxations involving the temporomandibular joint.** In: Verstraete FJM, Lommer MJ and Arzi B (eds). *Oral and maxillofacial surgery in dogs and cats*. 2nd ed. St Louis, MO: Elsevier, 2020, pp 368–376.
- Neff A, Cornelius CP, Rasse M, et al. **The comprehensive AOCMF classification system: condylar process fractures: level 3 tutorial.** *Craniomaxillofac Trauma Reconstr* 2014; 7: S44–S58.
- Bar-Am Y, Pollard RE, Kass PH, et al. **The diagnostic yield of conventional radiographs and computed tomography in dogs and cats with maxillofacial trauma.** *Vet Surg* 2008; 37: 294–299.
- Schwarz T, Weller R, Dickie AM, et al. **Imaging of the canine and feline temporomandibular joint: a review.** *Vet Radiol Ultrasound* 2002; 43: 85–97.
- Dreizin D, Nam AJ, Tirada N, et al. **Multidetector CT of mandibular fractures, reductions, and complications: a clinically relevant primer for the radiologist.** *Radiographics* 2016; 36: 1539–1564.