



















Article

Elastodontic Therapy of Hyperdivergent Class II Patients Using AMCOP[®] Devices: A Retrospective Study

Alessio Danilo Inchingolo ^{1,†}, Sabino Ceci ^{1,†}, Assunta Patano ^{1,†}, Angelo Michele Inchingolo ^{1,†},
Valentina Montenegro ¹, Chiara Di Pede ¹, Giuseppina Malcangi ¹, Grazia Marinelli ¹, Giovanni Coloccia ¹,
Mariagrazia Garibaldi ¹, Zamira Kruti ¹, Giulia Palmieri ¹, Nicole De Leonardis ¹, Biagio Rapone ¹,
Antonio Mancini ¹, Alexandra Semjonova ¹, Ludovica Nucci ², Ioana Roxana Bordea ^{3,*}, Antonio Scarano ⁴,
Felice Lorusso ^{4,*}, Elisabetta Ferrara ⁵, Marco Farronato ⁶, Gianluca Martino Tartaglia ⁶, Daniela Di Venere ¹,
Filippo Cardarelli ^{1,‡}, Francesco Inchingolo ^{1,‡} and Gianna Dipalma ^{1,‡}

- ¹ Department of Interdisciplinary Medicine, University of Bari "Aldo Moro", 70124 Bari, Italy; ad.inchingolo@libero.it (A.D.I.); s.ceci@studenti.uniba.it (S.C.); assuntapatano@gmail.com (A.P.); angeloinchingolo@gmail.com (A.M.I.); valentinamontenegro@libero.it (V.M.); c.dipede1@studenti.uniba.it (C.D.P.); giuseppinamalcangi@libero.it (G.M.); graziamarinelli@live.it (G.M.); giovanni.coloccia@gmail.com (G.C.); mgr.garibaldi@libero.it (M.G.); zamirakruti@hotmail.it (Z.K.); giuliapalmieri13@gmail.com (G.P.); nicoledeleonardis@outlook.it (N.D.L.); biagiorapone79@gmail.com (B.R.); dr.antonio.mancini@gmail.com (A.M.); dralexandrasemjonova@libero.it (A.S.); daniela.divenere@uniba.it (D.D.V.); drfilippocardarelli@libero.it (F.C.); francesco.inchingolo@uniba.it (F.I.); giannadipalma@tiscali.it (G.D.)
- ² Multidisciplinary Department of Medical-Surgical and Dental Specialties, University of Campania Luigi Vanvitelli, Via L. De Crecchio 6, 80138 Naples, Italy; ludovica.nucci@unicampania.it
- ³ Department of Oral Rehabilitation, Faculty of Dentistry, Iuliu Hațieganu University of Medicine and Pharmacy, 400012 Cluj-Napoca, Romania
- ⁴ Department of Innovative Technologies in Medicine and Dentistry, University of Chieti-Pescara, 66100 Chieti, Italy; ascarano@unich.it
- ⁵ Complex Operative Unit of Odontostomatology, Hospital S.S. Annunziata, 66100 Chieti, Italy; igieneeprevenzione@gmail.com
- ⁶ UOC Maxillo-Facial Surgery and Dentistry, Department of Biomedical, Surgical and Dental Sciences, School of Dentistry, Fondazione IRCCS Ca Granda, Ospedale Maggiore, Policlinico, 20122 Milan, Italy; marco.farronato@unimi.it (M.F.); gianluca.tartaglia@unimi.it (G.M.T.)
- * Correspondence: roxana.bordea@ymail.com (I.R.B.); felice.lorusso@unich.it (F.L.); Tel.: +40-744-919-391 (I.R.B.); +39-328-213-2586 or +39-087-1355-4100 (F.L.)
- † These authors contributed equally to this work.
- ‡ These authors contributed equally to this work.



Citation: Inchingolo, A.D.; Ceci, S.; Patano, A.; Inchingolo, A.M.; Montenegro, V.; Di Pede, C.; Malcangi, G.; Marinelli, G.; Coloccia, G.; Garibaldi, M.; et al. Elastodontic Therapy of Hyperdivergent Class II Patients Using AMCOP[®] Devices: A Retrospective Study. *Appl. Sci.* **2022**, *12*, 3259. <https://doi.org/10.3390/app12073259>

Academic Editors: Stefano Gennai and Morena Petrini

Received: 16 February 2022

Accepted: 21 March 2022

Published: 23 March 2022

Publisher's Note: MDPI stays neutral with regard to jurisdictional claims in published maps and institutional affiliations.



Copyright: © 2022 by the authors. Licensee MDPI, Basel, Switzerland. This article is an open access article distributed under the terms and conditions of the Creative Commons Attribution (CC BY) license (<https://creativecommons.org/licenses/by/4.0/>).

Abstract: Background: The management of a hyperdivergent growth pattern is one of the most challenging in orthodontics and different treatments are advocated. The present study analyses the effectiveness of elastodontic therapy with AMCOP[®] devices in treating children with hyperdivergent class II malocclusion and the effect on the upper airway patency. Methods: The study group included 21 patients (10 males and 11 females, mean age 8.22 ± 1.17 years) with a hyperdivergent growth and a class II malocclusion treated with AMCOP[®] devices. Cephalometric analysis was performed before treatment (T0) and after treatment (T1). Results: After treatment, the cephalometric analysis revealed a correction of the class II malocclusion and a modification of the growth pattern with a divergence reduction. The improvement of the upper airway space was also observed. Conclusion: The elastodontic therapy effectively corrected hyperdivergent class II malocclusion in growing patients over a short period.

Keywords: hyperdivergent growth; class II malocclusion; upper airway space; elastodontic therapy; elastodontic appliances; AMCOP[®] devices; functional orthodontics; interceptive treatment; interceptive orthodontics; eruption guidance appliance

1. Introduction

A skeletal class II malocclusion is often characterized by a retrognathic mandible and a hyperdivergent pattern of growth, which makes it challenging to treat [1]. Schudy, in a 1964 article, was the first to suggest the term facial divergence to indicate a vertical variation with two extremes: hyperdivergence and hypodivergence [1,2]. Hyperdivergence, also denoted as skeletal open bite, refers to the excessive vertical development of the bone bases due to genetic and environmental factors. This pattern is characterized by increased lower face heights, steeper mandibular planes, and larger gonial angles [3]. Skeletal open bite has to be distinguished from dental open bite, characterized by the absence of contact between the upper and lower incisors in the vertical plane while the posterior elements occlude. It is often determined by bad habits such as atypical swallowing, prolonged sucking of the finger or thumb, and oral breathing [4].

Orthodontic treatment is necessary both for aesthetical and functional reasons. Generally, the profile of these patients is convex and presents an augmented facial lower third (from the lower lip to the menton cephalometric point). Different authors evaluated the preferences on facial profiles, concluding that a straight profile, or class I profile, is the most appreciated [5,6]. In a 2012 article, Naini et al. reported that significant chin height is considered unattractive by clinicians, patients, and laypeople with minor criticism [7]. Functionally speaking, Proffit et al., evaluating occlusal force during maximum effort, swallowing, and simulated chewing, found that this is lower in long-faced adults than in normal vertical facial ones [8]. In a second study conducted among 6- to 11-year-old children with normal and long faces, these differences were not noticed, and their occlusal forces were similar to a long-faced adult. It also emerged that children with the long-faced pattern do not develop proper muscular strength, especially in the mandibular elevator muscles, during growth. Consequently, it is essential to control the lower facial third growth tendency using interceptive orthodontics devices. Clinicians should guide these patients toward the most appreciated facial characteristics and better muscular functionality [9,10].

The early treatment aimed to control and contain maxilla vertical growth in the posterior region, prevent downward and backward mandibular rotation, and promote its development in forwarding rotation [11,12]. In this way, the need for surgery in adulthood can be reduced [13–16].

Several devices are used to control the excessive vertical size in growing patients, such as functional appliances, fixed appliances with extractions, high-pull headgears, bite blocks, or any combinations of the above [17–19]. In particular, headgear and functional appliances are two common nonsurgical therapy options for class II skeletal malocclusions. Some authors stated that the combined use of a removable functional appliance and high-pull headgear was more effective than using a single method [20,21].

There was no adequate literature about long-term stability. However, a relapse seemed to occur in those cases with atypical tongue function or an incompetent oral seal [19,22,23].

This study aims to assess the treatment of growing patients with class II malocclusion and hyperdivergent tendencies with AMCOP[®] elastodontic bio-activators, and to evaluate the upper airway patency improvement after therapy.

Elastodontic therapy with AMCOP[®] (*Armonizzatori Multifunzionali Cranio-Occluso-Posturali*/Cranio-Occlusion-Postural Multifunctional Harmonizers) represents a new approach of interceptive orthodontics that uses light and biological forces of an elastic type for orthopedic and functional action [24–27].

2. Materials and Methods

2.1. Sample Description

A retrospective analysis of 21 patients (10 males and 11 females, mean age 8.22 ± 1.17 years) was performed. For patient enrolment, the following inclusion criteria were considered: ANB angle $> 4^\circ$ (normal values n. v. $2^\circ \pm 2^\circ$ [28–31]); SNB $< 78^\circ$ (n. v. $80^\circ \pm 2^\circ$ [28,32,33]); and mandibular angle (S-N \hat{G} o-Gn) $> 32^\circ$ (n. v. 32° [30,32]). Exclusion criteria were: previous orthodontic treatment and systemic problems or craniofacial syndromes. For each patient,

informed consent was obtained. The following material was collected: extraoral photos, intraoral photos, panoramic X-rays and lateral cephalograms at the time of initial observation (T0) and the end of the treatment (T1).

2.2. AMCOP[®] Bio-Activators Description

In this study, AMCOP[®] bio-activators were adopted.

The acronym AMCOP[®] (Armonizzatori Multifunzionali Cranio-Occluso Posturali) stands for:

- HARMONIZER: harmonically reshapes the dental-cranial-facial structures;
- MULTIFUNCTIONAL: suitable for the treatment of various dysfunctional problems;
- CRANIAL-OCCLUSION-POSTURAL: acts on the relationship between the skull and jawbones, and between occlusion and posture, by acting on the first cervical vertebrae.

The AMCOP[®] devices are made of an elastic and a thermoactivable material derived from a polymer–elastomer combination. This is soft, comfortable, and adaptable to different kinds of arches. During treatment, it is possible to expand the device by immersing it in hot water at 70° for 30 sec and to make retouching or shortenings using rubber, brush, and heat-appropriate instruments. The size of the activator is chosen by measuring the transverse distance between the outermost point of the vestibular cusps of the first two upper molars. The measurement can be made on the plaster model or on a wax bite. This second option is advantageous for young children as it avoids impression-taking, which children often do not appreciate. All the AMCOP[®] devices are equipped with two high flanges, one on the vestibular side and one on the lingual side, eliminating any muscular interference on the teeth. A central area links the flanges without indentures where the teeth can move. A lingual ramp and a button help to guide the tongue on the palate. The activators are available in different colors, referred to arch shapes and skeletal classes.

In this research three specific devices were used:

AMCOP[®] Integral:

It is indicated for treating first-class malocclusions with basal skeletal disharmonies responsible for horizontal (e.g., transverse insufficiencies) or vertical (e.g., open or deep bites) deficits. It is used in all kinds of dentition (deciduous, mixed and permanent) and ideal for early and interceptive treatments. Furthermore, it is adopted for its orthopedic action, for therapy in the presence of occlusal curve alterations (anterior and/or lateral open bite) and for a proper balance of the dental arches. The occlusal plane functions as a stabilizer of the mouth balance. The flat occlusal planes are made with appropriate functional Spee and Wilson curves for correct mandibular growth. First class bio-activators (Figure 1) are subdivided into four types of arch form in relation to the kind of cranial conformation of the patient (brachycephalic, dolichocephalic, and mesocephalic).

AMCOP[®] Second Class (SC):

It is indicated for the treatment of mandibular retrognathia by repositioning it in a first-class ratio and using deciduous, mixed and permanent dentitions. It has a mandibular anterior sliding plane that promotes the advancement of the mandible (in retrusion) by positioning the incisors head-to-head, providing a lengthening of the mandibular bone base, the retro inclinations of the lower incisors and the proinclination of the upper ones (overjet). It is also used to treat TMJ dysfunction and improve lip competence and, therefore, facial aesthetics (Figure 1).

AMCOP[®] Open:

It is indicated for the anterior skeletal open-bite treatment due to atypical swallowing habits and a specific skeletal craniomandibular imbalance (Figure 1). The specific orthodontic-orthopedic action provided by the device takes place through the unblocking of specific craniofacial skeletal structures in antero-flexion movement with the restoration, in equilibrium, of the occlusal plane and resolution of the anterior open bite.

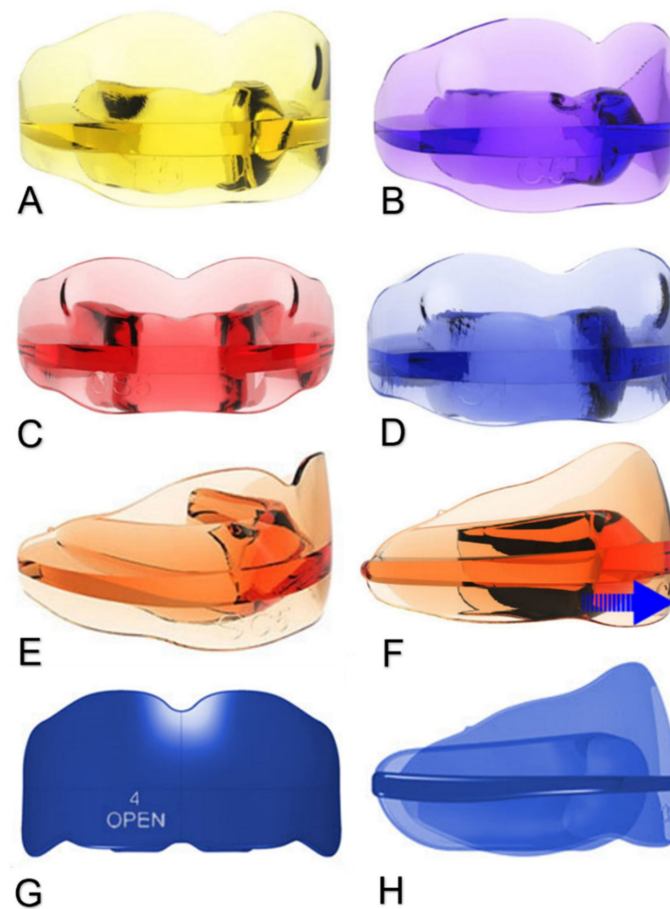


Figure 1. (A–H)—AMCOP[®] Integral, the different types of which are identified by a color and a corresponding letter: yellow F (A); purple C (B); red OS (C); blue S (D); AMCOP[®] SC with its unique orange color (E) showing the mandibular movement (F); and AMCOP[®] Open (G,H) (source: www.amcop.info, accessed on 20 March 2022).

2.3. Treatment Protocol

The patients were treated with AMCOP[®] devices for an average period of 16–18 months. All patients were asked to wear the appliance for an hour during the day and all night for 6–8 months, and then only at night for the following months. Patients wore the devices correctly for the prescribed hours to obtain desired results. The treatment protocol provided:

- In very high-angle cases ($S-N^{\wedge}-Go-Gn > 37^{\circ}$), first AMCOP[®] OPEN for 6–8 months and then the SC device;
- In slightly increased angle cases ($32^{\circ} < S-N^{\wedge}-Go-Gn \leq 37^{\circ}$), first AMCOP[®] INTEGRAL for 6–8 months and then the SC device.

The hyperdivergent vertical problem was solved in the first phase, so the AMCOP[®] Open was used for the most severe patients. In the mildest hyperdivergent patients, in which malocclusion is often linked to bad oral habits, the appliance with a flat chewing surface (INTEGRAL) was chosen. In the second phase, the class II device (AMCOP[®] SC) was used in both cases to solve the sagittal plane problem. No other appliances were used during the elastodontic therapy. No multibrackets appliances were necessary after interceptive treatment.

2.4. Data Assessment and Cephalometric Analysis

All the patients underwent complete photographic documentation and lateral radiographs before treatment (T0) and at the end of treatment (T1). The radiographs were loaded into the DeltaDent[®] cephalometric software to identify specific points and planes to

measure the dento-skeletal relationships and bone bases in the sagittal and vertical planes. The assessment of the airway patency was carried out using linear measurements at three levels: the distance between the soft palate and the posterior wall of the nasopharynx; between the lower tip of the soft palate and the posterior wall of the oropharynx; and between the lingual base along the mandibular Go–Me plane and the posterior wall of the pharynx. Example cephalometric tracings of the study are shown in Figures 2 and 3. The values obtained from the measurement of each patient were then collected within an excel worksheet and sent to statistical analysis for extrapolation. For the skeletal evaluation, dental analysis and upper airway patency (Figure 3), the cephalometric values considered are detailed in Table 1.

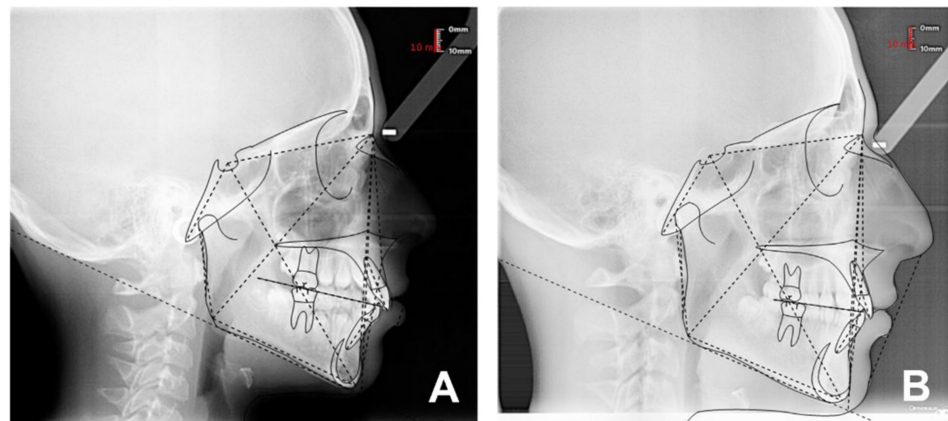


Figure 2. (A,B)—Patient F.V. cephalometric tracings, before (A) and after (B) treatment.

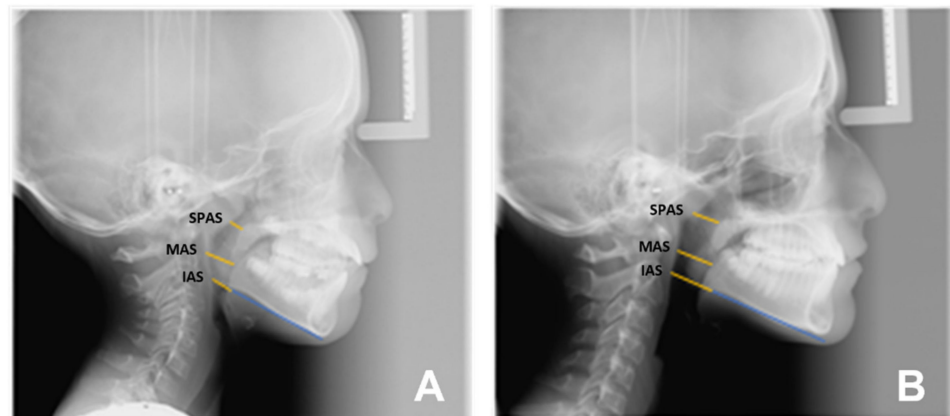


Figure 3. (A,B)—Patient V.B. airways cephalometry, before (A) and after (B) treatment. Indicated with a yellow line, SPAS superior posterior airway space (width of airway behind soft palate along a line parallel to Gonion–Menton (Go–Me) plane); MAS medium airway width measured on a line parallel to Go–Me plane passing through tip of soft palate (P); and IAS inferior airway width measured on Go–Me plane.

Table 1. All the parameters considered for this study were extracted from the cephalometric analysis.

Sagittal plane analysis:
SNA (angle comprised between Sella–Nasion and Nasion point A segments)
SNB (angle comprised between Sella–Nasion and Nasion point B segments)
ANB (angle comprised between Nasion point A and Nasion point B segments)
Vertical plane analysis:
Sna-Snp[^]Go-Gn (intermaxillary angle, angle comprised between the bispinal plane and the mandibular plane)
S-N[^]Go-Gn (mandibular angle, angle comprised between the Sella–Nasion segment and the mandibular plane)
PFH/AFH (posterior facial height and anterior facial height ratio)
Growth predictors:
N-S-Ar (saddle angle comprised between Nasion–Sella and Sella–Articular segments)
S-Ar-Go (articular angle comprised between Sella–Articular and Articular–Gonion segments)
Ar-Go-Me (gonial angle comprised between Articular–Gonion and Gonion–Menton segments)
Ar-Go-N (upper gonial angle comprised between Articular–Gonion and Gonion–Nasion segments)
N-Go-Me (lower gonial angle comprised between Nasion–Gonion and Gonion–Menton)
Dental analysis:
Is:NA (maxillary incisor distance)
Ii:NB (mandibular incisor distance)
OJV (overjet)
OVB (overbite)
IsIi : interincisal angle (angle between the major axis of the upper and lower incisors).
Upper airway space analysis:
SPAS : superior posterior airway space (distance between the soft palate and the posterior wall of the nasopharynx measured along a line parallel to Gonion–Menton (Go–Me) plane)
MAS : medium airway space (distance between the lower tip of the soft palate and the posterior wall of the oropharynx measured on a line parallel to Go–Me plane)
IAS Inferior Airway Space (distance between the lingual base along the mandibular Go–Me plane and the posterior wall of the pharynx)
Mandible measurements
Ar-Go (ramus height measured on Articular–Gonion segment)
Go-Me (corpus length measured on Gonion–Menton)

2.5. Statistical Analysis

A two-tailed paired samples *t*-test was conducted to examine whether the mean difference of variables was significantly different from zero. A Shapiro–Wilk test was conducted to determine whether a normal distribution could have produced the differences in variables. The results of the Shapiro–Wilk test were not significant based on an alpha value of 0.05, $W = 0.98$, $p = 0.186$. These results suggest that the possibility that a normal distribution produced the differences in variables cannot be ruled out, indicating that the normality assumption was met. Statistical analysis was performed at a significance level of 5% ($p < 0.05$). All data were examined using SPSS for Windows version 11 (SPSS Inc., Chicago, IL, USA).

3. Results

The results are detailed in Table 2, and photos of the two example patients of the study before and after intraoral treatment can be found in Figures 4–7. After AMCOP[®] elastodontic therapy, the following were noticed:

- Vertical skeletal outcomes: a significant increase in PFH/AFH (3.13, $p = 0.0004$), a reduction in Sna-Snp[^]Go-Gn (-2.51° , $p = 0.0146$) and S-N[^]Go-Gn (-2.87° , $p = 0.0014$);
- Sagittal skeletal outcomes: a significant mandibular advancement, SNB (2.17° , $p = 0.0015$) and a reduction in the ANB angle (-2.28° , $p = 0.0001$). On the contrary, no significant variation in the maxillary position, SNA, was noticed (-0.04° , $p = 0.9484$);

- Growth pattern outcomes: a significant reduction in the gonial angle, Ar-Go-Me (-3.13° , $p = 0.0185$), while there were no significant differences in the sellar (N-S-Ar -1.56° , $p = 0.1141$) and articular angles (S-Ar-Go 1.34° , $p = 0.4442$);
- Dental outcomes: an OVJ reduction (-2.64 mm $p = 0.0002$) without significant changes in the incisors inclination and position: Is'Ii (1.62 mm $p = 0.4836$); Is:NA (0.58 mm, $p = 0.2822$); and Ii:NB (0.92 mm, $p = 0.0524$);
- Airways outcomes: significant changes were found in the width of the upper airways, SPAS (2.21 mm, $p = 0.0099$), while the improvement in the middle and lower pharyngeal space was not significant, i.e., MAS (1.41 mm $p = 0.0786$) and IAS (1.64 mm $p = 0.1342$).

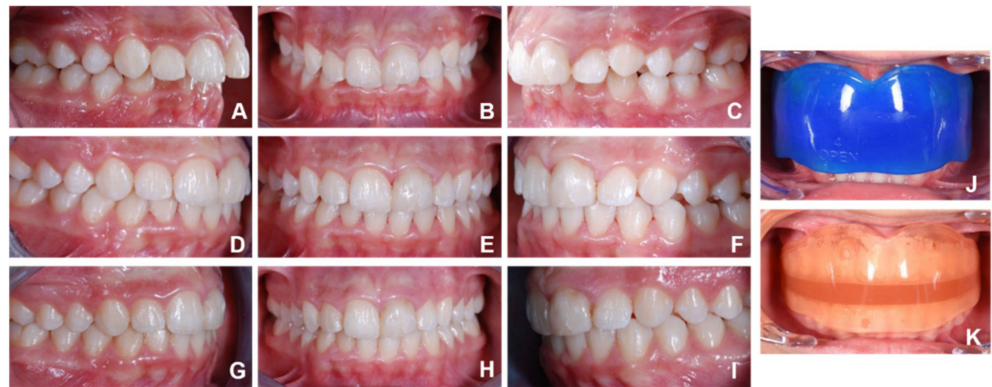

Figure 4. (A–K)—A 10-year-old male patient (V.M.) with an augmented overjet and a deep bite. A cephalometric analysis showed skeletal class II (ANB 5.9°) and severe hyperdivergency (S-N'Go-Gn 41°). The treatment plan included the use of AMCOP[®] Open in order to correct the skeletal open bite, followed by the AMCOP[®] SC device to solve the skeletal class II malocclusion. Intraoral photos of the patient: pre-treatment (A–C); the intermediate phase (D–F); post-treatment (G–I). Patient wearing AMCOP[®] Open (J) and AMCOP[®] SC (K).

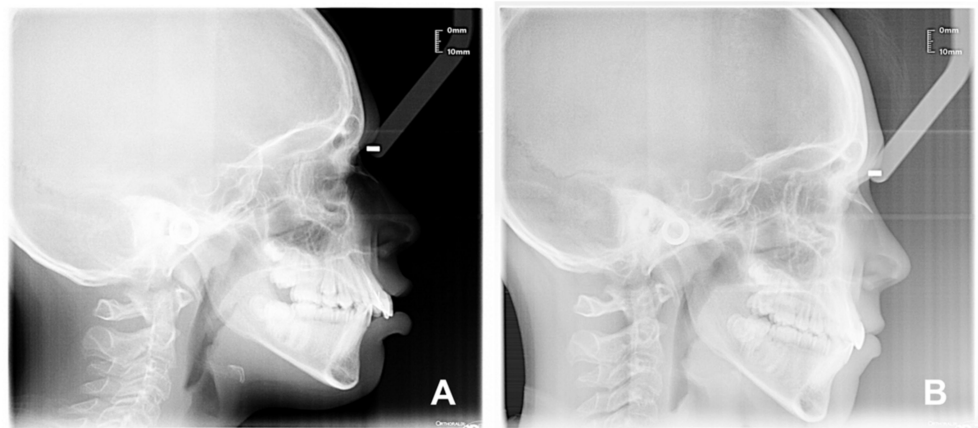


Figure 5. (A,B)—Patient (V.M.) latero-lateral teleroadiography X-ray: before treatment T0 (A); and after treatment T1 (B).

Table 2. Cephalometric measurements statistics.

	T1–T0	T-Value	p-Value
	Mean Differences		
SNA	−0.04	−0.0657	0.9484
SNB	2.17	3.7935	0.0015 *
ANB	−2.28	−4.8857	0.0001 *
Sna–Snp°Go–Gn	−2.51	−2.7185	0.0146 *
S–N°Go–Gn	−2.87	−3.8090	0.0014 *
PFH/AFH	3.09	4.4464	0.0004 *
N–S–Ar	−1.56	−1.6658	0.1141
S–Ar–Go	1.34	0.7833	0.4442
Ar–Go–Me	−3.13	−2.6041	0.0185 *
N–Go–Me	−0.71	−1.2368	0.2330
Ar–Go–N	−1.64	−1.7560	0.0971
Ar–Go	3.24	2.5629	0.0202 *
Go–Me	2.91	1.6680	0.1136
Is:NA	0.58	1.1106	0.2822
Ii:NB	0.92	2.0856	0.0524
OVJ	−2.64	−4.7315	0.0002 *
OVB	2.12	1.5256	0.1245
INTERINCISAL ANGLE	1.62	0.7162	0.4836
SPAS	2.21	2.9040	0.0099 *
MAS	1.41	1.8718	0.0786
IAS	1.64	1.5728	0.1342

* Statistically significant. *p*-Value < 0.05. SNA (Sella–Nasion–Point A angle); SNB (Sella–Nasion–Point B angle); ANB (Point A–Nasion–Point B angle); Sna–Snp°Go–Gn (intermaxillary angle, bispinal plane–mandibular plane angle); S–N°Go–Gn (mandibular angle, Sella Nasion–mandibular plane angle); PFH/AFH (posterior facial height and anterior facial height ratio); N–S–Ar (saddle angle, Nasion–Sella–Articular angle); S–Ar–Go (articular angle, Sella–Articular–Gonion angle); Ar–Go–Me (gonial angle, Articular–Gonion–Menton angle); N–Go–Me (lower gonial angle, Nasion–Gonion–Menton angle); Ar–Go–N (upper gonial angle, Articular–Gonion–Nasion angle); Ar–Go (ramus height, Articular–Gonion segment); Go–Me (corpus length, Gonion–Menton segment); Is/NA (maxillary incisor inclination); Ii/NB (mandibular incisor inclination); OVJ (overjet); OVB (overbite); SPAS Superior posterior airway space; MAS Medium airway space; IAS Inferior airway space.

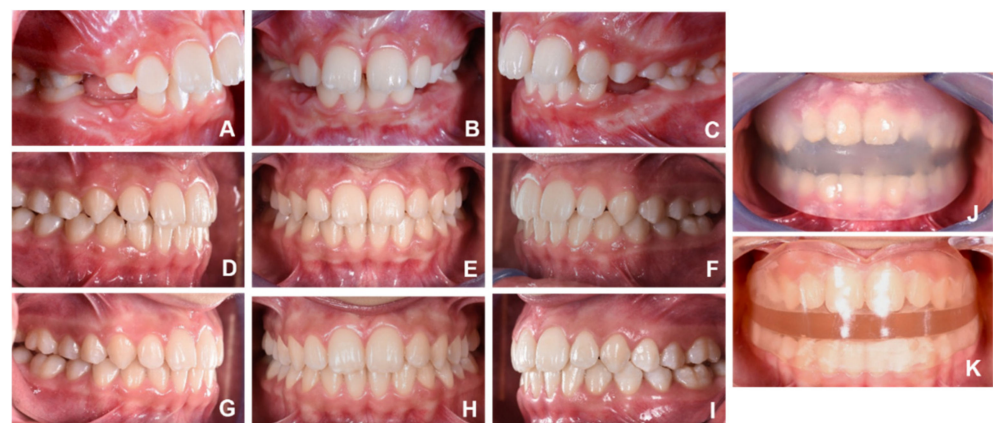

Figure 6. (A–K)—A 10-year-old female patient (D.L.) with atypical swallowing, a contraction of the upper arch, an augmented overjet, proinclination of the upper incisors and a class II malocclusion. A cephalometric analysis revealed a skeletal class II (ANB 9.3°) and mild hyperdivergency (S–N°Go–Gn 35.5°). The first phase of treatment with AMCOP® Integral for 8 months allowed to expand the upper arch, reduce the hyperdivergency, improve the dentoskeletal class and correct the overjet. Subsequently, AMCOP® SC induced the complete correction of the sagittal problem. Intraoral photos of the patient: pre-treatment (A–C); the intermediate phase (D–F); and post-treatment (G–I). Patient wearing AMCOP® Integral (J) and AMCOP® SC (K).

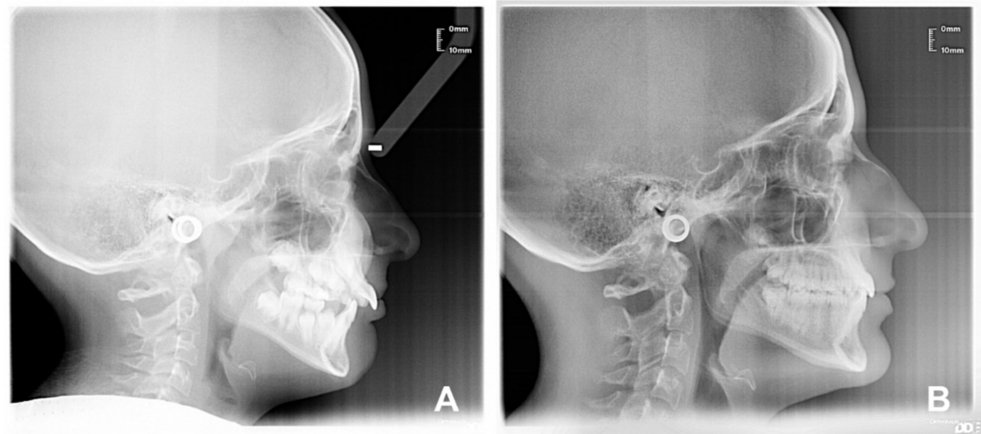


Figure 7. (A,B)—Patient (D.L.) latero-lateral teleradiography X-ray: before treatment T0 (A) and after treatment T1 (B).

4. Discussion

The present work aimed to investigate the effectiveness of AMCOP[®] elastodontic appliances for the early treatment of patients with a hyperdivergent pattern of growth and a class II malocclusion [24,34]. Numerous studies have previously evaluated the efficacy of elastodontic appliances in class II malocclusions, reporting improvements in the overjet, overbite, skeletal and dental class II [35–39]. However, no studies are reported in literature about the use of elastodontic appliances for the correction of hyperdivergent pattern of growth. Although many studies have underlined the dentoalveolar effects of elastodontic devices, significant skeletal changes were also reported [40,41]. In particular, the elastodontic treatment induces class II correction by improving the mandibular growth and position [39,42].

A study on the effects of the eruption guidance appliance in the treatment of class II division 1 malocclusions also evaluated the impact of the device on the vertical plane. The study reported that the lower anterior face height increased faster in the experimental than in the control group. This was due to the specific design of the appliance, which had more material anteriorly than posteriorly to promote the eruption of posterior teeth and the depression of incisors. However, the measurements, S-N^ˆGo-Gn and N-S-Gn, did not present statistically significant changes in the study group compared to the control group [43,44].

Recent work by Ciavarella et al. on the cephalometric effects of AMCOP[®] SC in skeletal class II division 1 cases reported that the elastodontic device does not affect the craniomandibular vertical relationship [35]. In the present study, the cephalometric analysis showed a statistically significant reduction in the ANB angle and overjet, suggesting the efficacy of AMCOP[®] devices on the correction of class II skeletal malocclusions. Furthermore, changes to the vertical plane were also obtained. Significant reductions in the SnaSnp^ˆGo-Gn, S-N^ˆGo-Gn, and Ar-Go-Me were also observed. The occlusal plane, both flat in mild hyperdivergent patients or posteriorly raised in severe hyperdivergent cases, prevents posterior dental eruption and controls vertical development. Skeletal growth is directed more anteriorly and less vertically [20,45,46]. The upward and forward mandibular rotation associated with the sagittal mandibular repositioning improves the sagittal discrepancy and, at the same time, reduces lower facial height [47,48].

Furthermore, these devices can correct functional problems of the soft tissues, such as a lingual malposition, a centripetal thrust of the lips and cheeks, and oral breathing [49,50]. They improve skeletal and dentoalveolar malocclusions and restore normal muscular activities, rebalancing the perioral, oral, and lingual musculature [27,51–56]. A study that found a link between muscle strength and occlusal barycenter confirmed the idea that inadequate musculature contributes to hyperdivergent growth. As a result, strengthening the muscle may change the occlusal barycenter. The AMCOP[®] devices perform this function

by causing constant stimulation of the masticatory muscles [57]. The devices can improve neurovegetative oropharyngeal functions, sucking and swallowing, chewing, phonation and breathing, and restoring the correct nose–mouth laryngopharyngeal function [58].

The subjects with a class II malocclusion and a hyperdivergent growth pattern have a narrower anteroposterior dimension of the upper pharyngeal airway due to mandibular retrusion and vertical maxillary excess. Other factors may also be favorable, such as the obtuse soft palate and the lower position of the hyoid bone. A narrow pharyngeal airway space could predispose to mouth breathing and obstructive sleep apnea; thus, early treatment is essential [12,59–62]. In more recent work, D. Grauer found that long-faced subjects showed a narrow airway, either anteroposteriorly or coronally [63]. Furthermore, in a comparative study between subjects with long and short faces, it was observed that the short mandibular ramus in the long face syndrome might be associated with a reduction in the cross-section of the lower pharynx [64].

In the present study, the effects on the upper airway space of AMCOP[®] elastodontic treatment were also evaluated. The results were considered at three different levels: the nasopharyngeal airway space (superior airway space—SPAS), the oropharyngeal airway space (medium airway space—MAS) and the hypopharyngeal airway space (inferior airway—IAS). This division was in agreement with other previous authors who have dealt with similar topics [46–48]. The most significant result was at the SPAS level, with an average increase of 2.2 mm. In addition, increases in MAS (1.41 mm) and IAS (1.64 mm) were found, although they were not statistically significant. The findings in the upper airway were probably attributable to a change in the tongue and hyoid bone position. In fact, the type of facial growth influences the position of the jaws, both in the vertical and sagittal planes. Therefore, by intercepting and modifying the growth pattern, improvements in upper airway patency can also be achieved [65]. Further studies on this aspect with AMCOP[®] devices need to be carried out.

The strengths of this study are linked to the originality due to the lack of works about AMCOP[®] devices and their effectiveness or ineffectiveness and the careful selection of inclusion and exclusion criteria. This study used a within-subject design comparing one group's outcomes before and after treatment without a control group that did not receive treatment. Other studies with a control group stated that the outcomes were determined by the intervention and not influenced by other variables. Another limitation of this study is the reduced sample size due to the restrictive inclusion criteria. Furthermore, this work was only an anatomic assessment. A functional assessment of the effects of AMCOP[®] devices on the stomatognathic system muscles could be helpful. Regarding airway effects, a two-dimensional lateral cephalogram does not allow for volumetric measurements so that a three-dimensional analysis could allow a complete evaluation.

5. Conclusions

The proposed protocol effectively treated hyperdivergent patients with a skeletal class II malocclusion. Significant improvements in the vertical plane were observed after therapy. The AMCOP[®] Integral with a flat mastication plane is sufficient to correct mild hyperdivergency by promoting muscle stretching and eliminating the functional disorders underlying the malocclusion. The AMCOP[®] Open is more indicated in severe hyperdivergent subjects thanks to the posteriorly raised occlusal plane with an intrusive thrust action in the posterior sectors favoring the mandibular counterclockwise rotation. This device also contributes to the functional re-education of the tongue. The use of the AMCOP[®] SC allows the correction of class II dysmorphism favoring a mandibular advancement. An enhancement of the pharyngeal air space was also observed, especially in the upper portion, allowing consequent improvement of deglutition, phonation, and respiratory function. However, the long-term stability of the results obtained is still to be evaluated, and further studies are needed.

6. Patents

Invention patents:

- Title: “dispositivo ortodontico-elastico-armonizzatore dento cranio-facciale, scope: Italian, granted under n° 102015000057082;
- Title: dispositivo ortodontico-elastico-armonizzatore dento cranio-facciale, scope: International, n° WO 2017/056010.

Author Contributions: Conceptualization, F.I., A.D.I., A.M.I., D.D.V., G.D., A.S. (Antonio Scarano), S.C., G.C., F.C., F.L. and A.P.; methodology, A.D.I., M.G., A.S. (Alexandra Semjonova), L.N., M.F., G.P., G.C., S.C. and G.M.T.; software, I.R.B., A.P., F.L., S.C., A.P., Z.K., G.D., A.M., F.I., C.D.P., V.M., B.R. and E.F.; validation, F.I., F.L., S.C., L.N., G.D., A.D.I., A.M.I. and A.S. (Antonio Scarano); formal analysis, N.D.L., A.M.I., F.L., V.M., G.P., F.C., M.G., C.D.P., D.D.V., A.D.I. and G.M. (Grazia Marinelli); investigation, G.M. (Giuseppina Malcangi), G.D., A.D.I., F.L., A.M.I., A.P., S.C., A.S. (Antonio Scarano) and F.I.; resources, A.M.I., S.C., A.P., G.D., A.D.I., F.I., I.R.B. and G.M. (Giuseppina Malcangi); data curation, G.D., M.F., V.M., F.L., M.G., B.R., E.F., A.M., G.C., G.M.T., Z.K., F.I., D.D.V. and G.M. (Grazia Marinelli); writing—original draft preparation, A.D.I., A.M.I., G.D., I.R.B., A.S. (Alexandra Semjonova), G.M.T., F.L., F.C. and F.I.; writing—review and editing, F.I., F.L., D.D.V., G.M. (Giuseppina Malcangi), A.M., A.S. (Antonio Scarano) and G.D.; visualization, F.I., A.M.I., A.D.I., F.L., A.S. (Antonio Scarano), and I.R.B.; supervision, G.D., D.D.V., F.I., A.D.I., A.S. (Antonio Scarano), and F.L.; project administration, F.I., G.D., G.M. (Giuseppina Malcangi), A.P., V.M., G.C., S.C. and G.P. All authors have read and agreed to the published version of the manuscript.

Funding: This research received no external funding.

Institutional Review Board Statement: The present clinical study was based in the University of Bari (Italy), in full accordance with ethical principles, including the World Medical Association Declaration of Helsinki and the additional requirements of Italian law. Furthermore, the University of Bari, Italy, classified the study to be exempt from ethical review as it carries only a negligible risk, and involves the use of existing data that contain only non-identifiable data about human beings. The patients signed a written informed consent form.

Informed Consent Statement: Informed consent was obtained from the subjects involved in the study. Written informed consent was obtained from the patients to publish this paper.

Data Availability Statement: All the experimental data to support the findings of this study are available by contacting the corresponding author upon request.

Conflicts of Interest: The authors declare no conflict of interest.

References

1. Buschang, P.H.; Jacob, H.; Carrillo, R. The Morphological Characteristics, Growth, and Etiology of the Hyperdivergent Phenotype. *Semin. Orthod.* **2013**, *19*, 212–226. [[CrossRef](#)]
2. Schudy, F.F. Vertical Growth versus Anteroposterior Growth as Related to Function and Treatment. *Angle Orthod.* **1964**, *34*, 75–93. [[CrossRef](#)]
3. Buschang, P.H.; Carrillo, R.; Rossouw, P.E. Orthopedic Correction of Growing Hyperdivergent, Retrognathic Patients with Miniscrew Implants. *J. Oral Maxillofac. Surg.* **2011**, *69*, 754–762. [[CrossRef](#)] [[PubMed](#)]
4. Laudadio, C.; Inchingolo, A.D.; Malcangi, G.; Limongelli, L.; Marinelli, G.; Coloccia, G.; Montenegro, V.; Patano, A.; Inchingolo, F.; Bordea, I.R.; et al. Management of Anterior Open-Bite in the Deciduous, Mixed and Permanent Dentition Stage: A Descriptive Review. *J. Biol. Regul. Homeost. Agents* **2021**, *35*, 271–281. [[CrossRef](#)]
5. Czarnecki, S.T.; Nanda, R.S.; Currier, G.F. Perceptions of a Balanced Facial Profile. *Am. J. Orthod. Dentofac. Orthop.* **1993**, *104*, 180–187. [[CrossRef](#)]
6. Maple, J.R.; Vig, K.W.L.; Beck, F.M.; Larsen, P.E.; Shanker, S. A Comparison of Providers’ and Consumers’ Perceptions of Facial-Profile Attractiveness. *Am. J. Orthod. Dentofac. Orthop.* **2005**, *128*, 690–696. [[CrossRef](#)] [[PubMed](#)]
7. Naini, F.B.; Donaldson, A.N.A.; McDonald, F.; Cobourne, M.T. Influence of Chin Height on Perceived Attractiveness in the Orthognathic Patient, Layperson, and Clinician. *Angle Orthod.* **2012**, *82*, 88–95. [[CrossRef](#)] [[PubMed](#)]
8. Proffit, W.R.; Fields, H.W.; Nixon, W.L. Occlusal Forces in Normal- and Long-Face Adults. *J. Dent. Res.* **1983**, *62*, 566–570. [[CrossRef](#)]
9. Proffit, W.R.; Fields, H.W. Occlusal Forces in Normal- and Long-Face Children. *J. Dent. Res.* **1983**, *62*, 571–574. [[CrossRef](#)]

10. Ballini, A.; Cantore, S.; Scacco, S.; Perillo, L.; Scarano, A.; Aityan, S.K.; Contaldo, M.; Cd Nguyen, K.; Santacroce, L.; Syed, J.; et al. A Comparative Study on Different Stemness Gene Expression between Dental Pulp Stem Cells vs. Dental Bud Stem Cells. *Eur. Rev. Med. Pharm. Sci.* **2019**, *23*, 1626–1633. [[CrossRef](#)]
11. Proffit, W.R.; White, R.P.; Sarver, D.M. *Contemporary Treatment of Dentofacial Deformity*; Mosby: St. Louis, MO, USA, 2003; ISBN 978-0-323-01697-1.
12. Cantore, S.; Ballini, A.; Farronato, D.; Malcangi, G.; Dipalma, G.; Assandri, F.; Garagiola, U.; Inchingolo, F.; De Vito, D.; Cirulli, N. Evaluation of an Oral Appliance in Patients with Mild to Moderate Obstructive Sleep Apnea Syndrome Intolerant to Continuous Positive Airway Pressure Use: Preliminary Results. *Int. J. Immunopathol. Pharm.* **2016**, *29*, 267–273. [[CrossRef](#)] [[PubMed](#)]
13. Sankey, W.L.; Buschang, P.H.; English, J.; Owen, A.H. Early Treatment of Vertical Skeletal Dysplasia: The Hyperdivergent Phenotype. *Am. J. Orthod. Dentofac. Orthop.* **2000**, *118*, 317–327. [[CrossRef](#)]
14. Nielsen, I.L. Vertical Malocclusions: Etiology, Development, Diagnosis and Some Aspects of Treatment. *Angle Orthod.* **1991**, *61*, 247–260. [[CrossRef](#)]
15. Solano-Hernández, B.; Antonarakis, G.S.; Scolozzi, P.; Kiliaridis, S. Combined Orthodontic and Orthognathic Surgical Treatment for the Correction of Skeletal Anterior Open-Bite Malocclusion: A Systematic Review on Vertical Stability. *J. Oral Maxillofac. Surg.* **2013**, *71*, 98–109. [[CrossRef](#)] [[PubMed](#)]
16. Patianna, A.G.; Ballini, A.; Meneghello, M.; Cantore, S.; Inchingolo, A.M.; Dipalma, G.; Inchingolo, A.D.; Inchingolo, F.; Malcangi, G.; Lucchese, A.; et al. Comparison of Conventional Orthognathic Surgery and “Surgery-First” Protocol: A New Weapon against Time. *J. Biol. Regul. Homeost. Agents* **2019**, *33*, 59–67.
17. Arat, M.; Iseri, H. Orthodontic and Orthopaedic Approach in the Treatment of Skeletal Open Bite. *Eur. J. Orthod.* **1992**, *14*, 207–215. [[CrossRef](#)] [[PubMed](#)]
18. Ng, C.; Wong, R.; Hägg, U. Orthodontic Treatment of Anterior Open Bite. *Int. J. Paediatr. Dent.* **2008**, *18*, 78–83.
19. Cozza, P.; Mucedero, M.; Baccetti, T.; Franchi, L. Early Orthodontic Treatment of Skeletal Open-Bite Malocclusion: A Systematic Review. *Angle Orthod.* **2005**, *75*, 707–713. [[CrossRef](#)]
20. Ngan, P.; Wilson, S.; Florman, M.; Wei, S.H. Treatment of Class II Open Bite in the Mixed Dentition with a Removable Functional Appliance and Headgear. *Quintessence Int.* **1992**, *23*, 323–333.
21. Chabre, C. Control of vertical dimension in the treatment of Class II malocclusion using a combined activator and extraoral traction appliance. *Orthod. Fr.* **1989**, *60 Pt 2*, 617–633.
22. Pancherz, H. The Mandibular Plane Angle in Activator Treatment. *Angle Orthod.* **1979**, *49*, 11–20. [[CrossRef](#)] [[PubMed](#)]
23. Coloccia, G.; Inchingolo, A.D.; Inchingolo, A.M.; Malcangi, G.; Montenegro, V.; Patano, A.; Marinelli, G.; Laudadio, C.; Limongelli, L.; Di Venere, D.; et al. Effectiveness of Dental and Maxillary Transverse Changes in Tooth-Borne, Bone-Borne, and Hybrid Palatal Expansion through Cone-Beam Tomography: A Systematic Review of the Literature. *Medicina* **2021**, *57*, 288. [[CrossRef](#)] [[PubMed](#)]
24. Cardarelli, D.F. Il trattamento funzionale elastodontico con apparecchi AMCOP: Funzione, estetica e postura. *Dent. Trib.* **2019**, *3*, 23–25.
25. Inchingolo, A.D.; Patano, A.; Coloccia, G.; Ceci, S.; Inchingolo, A.M.; Marinelli, G.; Malcangi, G.; Montenegro, V.; Laudadio, C.; Pede, C.D.; et al. The Efficacy of a New AMCOP[®] Elastodontic Protocol for Orthodontic Interceptive Treatment: A Case Series and Literature Overview. *Int. J. Environ. Res. Public Health* **2022**, *19*, 988. [[CrossRef](#)]
26. Marinelli, G.; Inchingolo, A.D.; Inchingolo, A.M.; Malcangi, G.; Limongelli, L.; Montenegro, V.; Coloccia, G.; Laudadio, C.; Patano, A.; Inchingolo, F.; et al. White Spot Lesions in Orthodontics: Prevention and Treatment. A Descriptive Review. *J. Biol. Regul. Homeost. Agents* **2021**, *35*, 227–240. [[CrossRef](#)]
27. Cardarelli, F.; Patano, A.; Montenegro, V.; Malcangi, G.; Coloccia, G.; Inchingolo, A.D.; Marinelli, G.; Laudadio, C.; Dipalma, G.; Di Venere, D.; et al. Elastodontic therapy un nuovo approccio alla terapia ortodontica funzionale. *Il Dent. Mod.* **2021**, *10*, 48–63.
28. Steiner, C.C. The Use of Cephalometrics as an Aid to Planning and Assessing Orthodontic Treatment: Report of a Case. *Am. J. Orthod.* **1960**, *46*, 721–735. [[CrossRef](#)]
29. Steiner, C.C. Cephalometrics in Clinical Practice. *Angle Orthod.* **1959**, *29*, 8–29. [[CrossRef](#)]
30. Fernandez, C.C.A.; Pereira, C.V.C.A.; Luiz, R.R.; Vieira, A.R.; De Castro Costa, M. Dental Anomalies in Different Growth and Skeletal Malocclusion Patterns. *Angle Orthod.* **2018**, *88*, 195–201. [[CrossRef](#)]
31. Riedel, R.A. An Analysis of Dentofacial Relationships. *Am. J. Orthod.* **1957**, *43*, 103–119. [[CrossRef](#)]
32. Steiner, C.C. Cephalometrics for You and Me. *Am. J. Orthod.* **1953**, *39*, 729–755. [[CrossRef](#)]
33. Brevi, B.; Di Blasio, A.; Di Blasio, C.; Piazza, F.; D’ascanio, L.; Sesenna, E. Which Cephalometric Analysis for Maxillo-Mandibular Surgery in Patients with Obstructive Sleep Apnoea Syndrome? *Acta Otorhinolaryngol. Ital.* **2015**, *35*, 332–337. [[CrossRef](#)] [[PubMed](#)]
34. Fichera, G.; Martina, S.; Palazzo, G.; Musumeci, R.; Leonardi, R.; Isola, G.; Lo Giudice, A. New Materials for Orthodontic Interceptive Treatment in Primary to Late Mixed Dentition. A Retrospective Study Using Elastodontic Devices. *Materials* **2021**, *14*, 1695. [[CrossRef](#)] [[PubMed](#)]
35. Ciavarella, D.; Campobasso, A.; Campa, R.; Suriano, C.; Illuzzi, G.; Cazzolla, A.P.; Tepedino, M. Cephalometric Effects of the Elastodontic Appliance in Managing Skeletal Class II Division 1 Cases. *Australas. Orthod. J.* **2021**, *37*, 251–258. [[CrossRef](#)]
36. Keski-Nisula, K.; Keski-Nisula, L.; Salo, H.; Voipio, K.; Varrela, J. Dentofacial Changes after Orthodontic Intervention with Eruption Guidance Appliance in the Early Mixed Dentition. *Angle Orthod.* **2008**, *78*, 324–331. [[CrossRef](#)]

37. Patano, A.; Cirulli, N.; Beretta, M.; Plantamura, P.; Inchingolo, A.D.; Inchingolo, A.M.; Bordea, I.R.; Malcangi, G.; Marinelli, G.; Scarano, A.; et al. Education Technology in Orthodontics and Paediatric Dentistry during the COVID-19 Pandemic: A Systematic Review. *Int. J. Environ. Res. Public Health* **2021**, *18*, 6056. [[CrossRef](#)]
38. Anastasi, G.; Putrino, A. Cephalometric Evaluation of Mandibular Changes Following Orthodontic Treatment with Preformed Appliances on Class II Patients: A Meta-Analysis. *WebmedCentral Orthod.* **2014**, *5*, WMC004491.
39. Keski-Nisula, K.; Keski-Nisula, L.; Varrela, J. Class II Treatment in Early Mixed Dentition with the Eruption Guidance Appliance: Effects and Long-Term Stability. *Eur. J. Orthod.* **2019**, *42*, 151–156. [[CrossRef](#)]
40. Migliaccio, S.; Aprile, V.; Zicari, S.; Greci, A. Eruption Guidance Appliance: A Review. *Eur. J. Paediatr. Dent.* **2014**, *15*, 163–166.
41. Myrland, R.; Dubland, M.; Keski-Nisula, K.; Kerosuo, H. One Year Treatment Effects of the Eruption Guidance Appliance in 7- to 8-Year-Old Children: A Randomized Clinical Trial. *Eur. J. Orthod.* **2015**, *37*, 128–134. [[CrossRef](#)]
42. Janson, G.R.; Pereira, A.C.; Bergersen, E.O.; Henriques, J.F.; Pinzan, A.; de Almeida, R.R. Cephalometric Evaluation of the Eruption Guidance Appliance in Class II, Division 1 Treatment. *J. Clin. Orthod.* **1997**, *31*, 299–306. [[PubMed](#)]
43. Janson, G.R.; da Silva, C.C.; Bergersen, E.O.; Henriques, J.F.; Pinzan, A. Eruption Guidance Appliance Effects in the Treatment of Class II, Division 1 Malocclusions. *Am. J. Orthod. Dentofac. Orthop.* **2000**, *117*, 119–129. [[CrossRef](#)]
44. Dimonte, M.; Inchingolo, F.; Minonne, A.; Arditi, G.; Dipalma, G. Bone SPECT in Management of Mandibular Condyle Hyperplasia. Report of a Case and Review of Literature. *Minerva Stomatol.* **2004**, *53*, 281–285.
45. Pearson, L.E. Vertical Control in Treatment of Patients Having Backward-Rotational Growth Tendencies. *Angle Orthod.* **1978**, *48*, 132–140. [[CrossRef](#)] [[PubMed](#)]
46. Inchingolo, A.D.; Patano, A.; Coloccia, G.; Ceci, S.; Inchingolo, A.M.; Marinelli, G.; Malcangi, G.; Montenegro, V.; Laudadio, C.; Palmieri, G.; et al. Genetic Pattern, Orthodontic and Surgical Management of Multiple Supplementary Impacted Teeth in a Rare, Cleidocranial Dysplasia Patient: A Case Report. *Medicina* **2021**, *57*, 1350. [[CrossRef](#)]
47. Schiavoni, R.; Grenga, V.; Macri, V. Treatment of Class II High Angle Malocclusions with the Herbst Appliance: A Cephalometric Investigation. *Am. J. Orthod. Dentofac. Orthop.* **1992**, *102*, 393–409. [[CrossRef](#)]
48. Ramirez-Yañez, G.; Paulo, F. Early Treatment of a Class II, Division 2 Malocclusion with the Trainer for Kids (T4K): A Case Report. *J. Clin. Pediatr. Dent.* **2008**, *32*, 325–329. [[CrossRef](#)]
49. Fleming, P.S. Timing Orthodontic Treatment: Early or Late? *Aust. Dent. J.* **2017**, *62*, 11–19. [[CrossRef](#)]
50. Kluemper, G.T.; Beeman, C.S.; Hicks, E.P. Early Orthodontic Treatment: What Are the Imperatives. *J. Am. Dent. Assoc.* **2000**, *131*, 613–620. [[CrossRef](#)]
51. Corsalini, M.; Di Venere, D.; Sportelli, P.; Magazzino, D.; Ripa, M.; Cantatore, F.; Cagnetta, C.; Rinaldis, C.; Montemurro, N.; Giacomo, A.; et al. Evaluation of Prosthetic Quality and Masticatory Efficiency in Patients with Total Removable Prosthesis Study of 12 Cases. *Oral Implantol.* **2018**, *11*, 230–240.
52. Stavridi, R.; Ahlgren, J. Muscle Response to the Oral-Screen Activator. An EMG Study of the Masseter, Buccinator, and Mentalis Muscles. *Eur. J. Orthod.* **1992**, *14*, 339–349. [[CrossRef](#)] [[PubMed](#)]
53. Tallgren, A.; Christiansen, R.L.; Ash, M.; Miller, R.L. Effects of a Myofunctional Appliance on Orofacial Muscle Activity and Structures. *Angle Orthod.* **1998**, *68*, 249–258. [[CrossRef](#)] [[PubMed](#)]
54. Yagci, A.; Uysal, T.; Kara, S.; Okkesim, S. The Effects of Myofunctional Appliance Treatment on the Perioral and Masticatory Muscles in Class II, Division 1 Patients. *World J. Orthod.* **2010**, *11*, 117–122. [[PubMed](#)]
55. Di Venere, D.; Pettini, F.; Nardi, G.M.; Laforgia, A.; Stefanachi, G.; Notaro, V.; Rapone, B.; Grassi, F.R.; Corsalini, M. Correlation between Parodontal Indexes and Orthodontic Retainers: Prospective Study in a Group of 16 Patients. *Oral Implant.* **2017**, *10*, 78–86. [[CrossRef](#)]
56. Di Venere, D.; Rapone, B.; Corsalini, M. Dental Trauma in the Anterior Sector: An Analysis of the Predisposing Factors in a Group of Orthodontic Patients. *Clin. Ter.* **2020**, *171*, e481–e485. [[CrossRef](#)]
57. Battista, G.; Guida, L.; Avvanzo, P.; Mastrovincenzo, M.; Chimenti, C.; Muzio, L.L.; Ciavarella, D. Instrumental evaluation of angle Class II. *Mondo Ortod.* **2011**, *36*, 175–182. [[CrossRef](#)]
58. Vanini, L.; Cardarelli, F.; D'arcangelo, C. Elastodonzia: La Bioortodonzia Con Funzione Posturale. *Teamwork Clinic.* **2021**, *3*, 60–76.
59. Mani, P.; Muthukumar, K.; Krishnan, P.; Senthil Kumar, K.P. Upper and Lower Pharyngeal Airway Space in West-Tamil Nadu Population. *J. Pharm. Bioallied Sci.* **2015**, *7*, S539–S542. [[CrossRef](#)]
60. Joseph, A.A.; Elbaum, J.; Cisneros, G.J.; Eisig, S.B. A Cephalometric Comparative Study of the Soft Tissue Airway Dimensions in Persons with Hyperdivergent and Normodivergent Facial Patterns. *J. Oral Maxillofac. Surg.* **1998**, *56*, 135–139. [[CrossRef](#)]
61. Di Venere, D.; Corsalini, M.; Nardi, G.M.; Laforgia, A.; Grassi, F.R.; Rapone, B.; Pettini, F. Obstructive Site Localization in Patients with Obstructive Sleep Apnea Syndrome: A Comparison between Otolaryngologic Data and Cephalometric Values. *Oral Implant.* **2017**, *10*, 295–310. [[CrossRef](#)]
62. Balian, A.; Malerba, A.; Strohmer, L. Obstructive Sleep Apnea Syndrome (OSAS) Treated with Orthodontic Appliances in Children: A New Feasible Approach. *Ann. Dent. Oral Disord.* **2018**, *1*, 105.
63. Grauer, D.; Cevidanes, L.S.H.; Styner, M.A.; Ackerman, J.L.; Proffit, W.R. Pharyngeal Airway Volume and Shape from Cone-Beam Computed Tomography: Relationship to Facial Morphology. *Am. J. Orthod. Dentofac. Orthop.* **2009**, *136*, 805–814. [[CrossRef](#)] [[PubMed](#)]

64. Opdebeeck, H.; Bell, W.H.; Eisenfeld, J.; Mishelevich, D. Comparative Study between the SFS and LFS Rotation as a Possible Morphogenic Mechanism. *Am. J. Orthod.* **1978**, *74*, 509–521. [[CrossRef](#)]
65. Ciavarella, D.; Lo Russo, L.; Mastrovincenzo, M.; Padalino, S.; Montaruli, G.; Giannatempo, G.; Cassano, M.; Laino, L.; Lo Muzio, L. Cephalometric Evaluation of Tongue Position and Airway Remodelling in Children Treated with Swallowing Occlusal Contact Intercept Appliance (S.O.C.I.A.). *Int. J. Pediatr. Otorhinolaryngol.* **2014**, *78*, 1857–1860. [[CrossRef](#)]