

Access this article online
Quick Response Code:

Website: www.e-tjo.org
DOI: 10.4103/tjo_57_20

# Visual functional changes after ocriplasmin injection for vitreomacular traction: A microperimetric analysis

Claudio Furino<sup>1\*</sup>, Alfredo Niro<sup>2</sup>, Luigi Sborgia<sup>1</sup>, Michele Reibaldi<sup>3</sup>,  
Francesco Boscia<sup>1</sup>, Giovanni Alessio<sup>1</sup>

## Abstract:

**PURPOSE:** The purpose is to evaluate functional changes after ocriplasmin injection to treat vitreomacular traction (VMT) by microperimetry.

**MATERIALS AND METHODS:** Prospective interventional study on patients underwent an intravitreal ocriplasmin injection. Optical coherence tomography, best-corrected visual acuity (BCVA) test, and microperimetry were performed at baseline, 1 week, 1 and 3 months. Microperimeter recorded retinal sensitivity (RS) and central retinal sensitivity (CRS) at central 12° and 4°, respectively, and fixation as bivariate contour ellipse area (BCEA) at 68%, 95%, and 99% of fixation points. Functional parameters were analyzed in patients who had (Group A) or not (Group B) VMT release.

**RESULTS:** Twenty-one patients including 18 with VMT and 3 with VMT plus macular hole (MH) were treated. Eleven patients achieved VMT resolution including all cases with MH that achieved hole closure. An impairment of BCVA, RS and CRS ( $P < 0.01$ ;  $P < 0.001$ ;  $P = 0.001$ , respectively) was reported at 1 week followed by a significant improvement (BCVA,  $P = 0.001$ ; RS, CRS,  $P = 0.02$ ) at 3 months. The early impairment of visual acuity and sensitivity significantly occurred in Group B ( $P \leq 0.01$ ) while their recovery significantly occurred in Group A ( $P < 0.01$ ). BCEA significantly increased in dimension (68%,  $P = 0.01$ ; 95%,  $P = 0.03$ ) at 1 week, subsequently returning to near baseline values over follow-up. Only in Group A, fixation stability significantly improved at 3 months.

**CONCLUSION:** Microperimetry confirms an early and reversible functional impairment after ocriplasmin injection regardless VMT resolution. If a greater decrease in function could occur in the eyes without VMT resolution, a better functional recovery could occur in the event of VMT resolution.

## Keywords:

Fixation behavior, microperimetry, ocriplasmin, retinal sensitivity, vitreomacular traction

<sup>1</sup>Department of Medical Science, Neuroscience and Sense Organs, Eye Clinic, University of Bari, Bari, Bari,

<sup>2</sup>Eye Clinic, Hospital "S. G. MOSCATI", ASL TA, Taranto,

<sup>3</sup>Eye Clinic, University of Catania, Catania Italy

## \*Address for correspondence:

Dr. Claudio Furino,  
Department of Medical Science, Neuroscience and Sense Organs, Eye Clinic, University of Bari, Piazza G. Cesare, 11, 70124 Bari, Italy.  
E-mail: claudiofurino@gmail.com

Submission: 08-06-2020  
Accepted: 19-08-2020  
Published: 04-12-2020

## Introduction

The vitreomacular interface disorders, including symptomatic vitreomacular adhesion (VMA), vitreomacular traction (VMT), and evolving or early macular hole (MH), can be associated with variable loss of visual function.<sup>[1,2]</sup> Treatment options include observation, pars plana vitrectomy, and pharmacologic vitreolysis. In selected cases, as defined by pivotal phase 3 clinical trial MIVI-TRUST<sup>[3,4]</sup> and

This is an open access journal, and articles are distributed under the terms of the Creative Commons Attribution-NonCommercial-ShareAlike 4.0 License, which allows others to remix, tweak, and build upon the work non-commercially, as long as appropriate credit is given and the new creations are licensed under the identical terms.

For reprints contact: WKHLRPMedknow\_reprints@wolterskluwer.com

OASIS study (clinicaltrials.gov/identifier: NCT01429441),<sup>[5]</sup> Ocriplasmin (Jetrea; ThromboGenics USA, Alcon/Novartis EU), a recombinant truncated form of human serine protease plasmin, was approved for the treatment. Different studies analyzing visual function recovery by assessing visual acuity, full-field electroretinogram (ERG), and multifocal ERG revealed early visual disturbances after injection.<sup>[6-12]</sup> Although the objective measurement using ERG has conventionally been considered more favorable than subjective measurement, microperimetry has been shown to be more

**How to cite this article:** Furino C, Niro A, Sborgia L, Reibaldi M, Boscia F, Alessio G. Visual functional changes after ocriplasmin injection for vitreomacular traction: A microperimetric analysis. Taiwan J Ophthalmol 2021;11:259-65.

sensitive at detecting early functional changes in response to treatment.<sup>[13,14]</sup> Recently, the OASIS MP-1 substudy analyzed the effect of ocriplasmin on microperimetric parameters. This substudy revealed better functional parameters after treatment with an early transient impairment in sensitivity in the ocriplasmin group than in the sham group. It was suggested that baseline retinal sensitivity (RS) could be a strong indicator of macular traction resolution.<sup>[15]</sup> However, in the OASIS substudy, we did not find a well-defined standardization of microperimetric test and an analysis of functional changes over follow-up related to the macular traction resolution. Hence, our aim was to evaluate the effects of ocriplasmin on functional outcomes as macular sensitivity and visual fixation related to macular traction resolution using a standardized microperimetric protocol over a 3 months' follow-up.

## Methods

A prospective interventional study was performed on patients affected by VMT or VMT associated with MH who underwent intravitreal ocriplasmin injection between April 2018 and December 2019 in Eye Clinic, Department of Ophthalmology, University of Bari, Italy. All injections were performed by the same experienced surgeon C.F. Patients were eligible for possible ocriplasmin treatment according to the NICE guidelines.<sup>[16]</sup> Exclusion criteria were history or current proliferative DR, neovascular AMD, retinal detachment, epiretinal membrane, ischemic retinopathies, retinal vein occlusions, vitreous hemorrhage, aphakia, uncontrolled glaucoma, MH >400  $\mu\text{m}$ , broad VMT/symptomatic VMA >1500  $\mu\text{m}$ , prior vitrectomy, and intravitreal injection within previous 3 months. Each patient underwent a single-intravitreal ocriplasmin injection. Assessments at baseline and follow-up included best-corrected visual acuity (BCVA) measurement using an ETDRS (logarithm of minimum angle of resolution [LogMAR]) chart, optical coherence tomography (OCT) examination and RS and fixation behavior analysis by microperimeter. The OCT examination was performed with a Topcon DRI Swept Source OCT Triton (Topcon Europe Medical BV, Netherlands) at baseline and postinjection time points. The acquisition protocol consisted of 12 radial line B-scan 9 mm in length and a 3D Macula Report in which a 6 mm  $\times$  6 mm region of the central retina was scanned. The diameter of MH was measured with a caliper as a line drawn roughly parallel to the retinal pigment epithelium, at the narrowest distance between the hole edges.<sup>[17]</sup> The success of the treatment to release VMT and close MH was determined by OCT scans which were interpreted by a blinded retina specialist. Macular sensitivity and fixation stability were evaluated by microperimeter (MP-1; Navis Software, version 1.7.6; Nidek Technologies, Padova, Italy). The MP-1 provides a 45° nonmydriatic view of the fundus with automated correction for eye movements. We performed microperimetry under

room dim light conditions. MP-1 uses a background luminance of 10  $\text{cd}/\text{m}^2$ , maximum stimulus intensity of 125  $\text{cd}/\text{m}^2$ , stimulus size of 0.11°–1.73° (Goldmann I–V), white stimulus color, 0–20 dB dynamic range. Sensitivity was measured on a grid including 45 points and centered on the fovea, using pattern Macula 12°-0 dB. At each point in the grid, sensitivity was measured for a white stimulus 0.438 in diameter (Goldmann size III) presented for 200 ms against a mesopic background (1.27  $\text{cd}/\text{m}^2$ ). The threshold at each point was determined by using a 4–2 staircase. The “follow-up” feature of the MP-1 was used to enable sensitivity measurements at the same retinal locations across all visits. The mean RS, the mean of all 45 loci in the central 12° (1° = 300  $\mu\text{m}$ ), and the mean central retinal sensitivity (CRS), the mean sensitivity of the central 13 loci (enclosed by a circle with a 4° diameter) were recorded. We also evaluated fixation behavior as bivariate contour ellipse area (BCEA, degrees<sup>2</sup>) that represents the area on which the eyes fixate for a certain proportion of time, and its calculation is based on the standard deviation of the horizontal and vertical eye fixation points at 68%, 95%, and 99%. Fixation stability was recorded during the light sensitivity examination. The standard fixation target was represented by a red cross with an arm extension of 1°, but it was increased to  $\geq 2^\circ$  if the patient was not able to see it. The examination started after a 2-min demonstration pretest to avoid a learning effect. Background luminance was 1.27  $\text{cd}/\text{m}^2$ . An auto-tracking system calculated the horizontal and vertical shifts relative to the reference during the examination recording the area of fixation. Examinations requiring longer than 15 min were excluded from the study. Routine follow-up visits were scheduled at 1 week, 1 month, and 3 months' following injection. Adverse events were also recorded. The study was conducted in accordance with the Declaration of Helsinki. Institutional review board approval was obtained (approval number: 0001/05.02.2018), and patients provided written informed consent before treatment.

## Drug administration

All injections were administered according to NICE guidelines,<sup>[16]</sup> which comprised a single intravitreal injection at a dose of 0.125 mg in 0.1 ml. Injections were performed in an operating room by one retina specialist under sterile conditions. The injection was performed with moderate injection velocity and patients lay flat for 5 min postinjection to allow gravitational dispersion of the ocriplasmin to the macula area. Patients were observed for 30 min after injection and then discharged.

## Statistical methods

The qualitative variables are presented as frequencies and percentages, while quantitative data as means  $\pm$  standard deviations. No formal sample size calculation was performed. Baseline and postoperative data including BCVA, RS, CRS, and BCEA were compared. Since

the data did pass normality test, the Student's *t*-test was applied. A  $P \leq 0.05$  was defined as statistically significant. BCVA and microperimetric parameters were also analyzed and presented in two groups of patients who had or not a VMT resolution at last follow-up. All analyses were performed using Prism version 6.0 (GraphPad Software, CA, USA).

## Results

Twenty-one eyes of 21 patients were included in the study. Demographics and baseline ocular characteristics are shown in Table 1. Functional and morphologic data at baseline and at all follow-up time points up were available for all patients. At 1 week, 6/21 (28.5%) eyes achieved VMT resolution. At month 1 and 3, 11/21 (52.4%) eyes achieved VMT resolution. All three eyes with MH achieved hole closure at last follow-up. Overall BCVA, RS, and CRS significantly decreased ( $P < 0.01$ ,  $P < 0.001$ ,  $P = 0.001$ , respectively) at 1 week after injection. Then, BCVA significantly improved at month 1 ( $P = 0.03$ ) and 3 ( $P = 0.001$ ) compared to baseline. Similarly, RS and CRS progressively returned to near baseline values at 1 month ( $P = 0.2$ ) and to better

values at 3 months ( $P = 0.02$ ) [Table 2]. Overall BCEA increased in dimensions (68%,  $P = 0.01$ ; 95%,  $P = 0.03$ ; 99%,  $P = 0.08$ ) after 1 week from injection. Then BCEA progressively returned to near baseline values after 1 month (68%,  $P = 0.24$ ; 95%,  $P = 0.10$ ; 99%,  $P = 0.05$ ) and 3 months (68%,  $P = 0.50$ ; 95%,  $P = 0.65$ ; 99%,  $P = 0.48$ ) [Figure 1 and Table 3]. In the group of patients with resolved VMT (Group A) and in the group of patients with unresolved VMT (Group B), 1-week BCVA worsened ( $P = 0.09$ ,  $P < 0.01$ , respectively) [Table 2]. Overall 12 (57.1%) patients, equally divided between the two groups, had a visual acuity impairment  $\geq 0.1$  LogMAR at 1 week. In particular, 3 (14.2%) patients (one with resolved VMT, two with unresolved VMT) had a decrease in vision of 0.2 LogMAR.

At 1 week, mean RS significantly decreased in both the groups (Group A,  $P = 0.03$ ; Group B,  $P < 0.001$ ), while CRS significantly decreased only in Group B ( $P = 0.01$ ) [Table 2]. Overall 19 (90.5%) patients, 9 with resolved and 10 with unresolved traction had a worse RS at 1 week. A total of 20 (95.2%) patients, 10 with resolved and 10 with unresolved traction had a worse CRS at 1 week.

BCVA, RS, and CRS improved in both the groups at 1 month. In particular, BCVA significantly improved in Group A ( $P = 0.001$ ) and RS significantly improved in Group B ( $P < 0.01$ ). In both groups, the improvement of visual acuity and sensitivity continued for up to 3 months but it occurred in a significant way only in Group A ( $P \leq 0.01$ ). A mild significant difference between the groups was reported only for mean RS at 3 months ( $P = 0.04$ ) [Table 2].

Both the groups reported a worse BCEA at all fixation points at 1 week, followed by a slow recovery of fixation stability over follow-up, mainly in Group A. After 3 months, fixation stability significantly improved at all fixation points in the eyes with resolved VMT but worsened in those without VMT release. A significant difference among the groups was reported for BCEA at 99.6% at 1 week ( $P = 0.03$ ) and 3 months ( $P = 0.01$ ) [Table 3].

A representative case was reported in Figure 2.

Few expected ocular adverse events associated with intraocular injections, as photopsia a myodesopsia, were reported for up to 48 h postinjection, then completely resolved. No cases of retinal detachment, retinal tears, and intraocular pressure elevation were reported.

## Discussion

Intravitreal injection of ocriplasmin induces vitreous liquefaction and separation of vitreoretinal adhesions at the macula and peripapillary retina.<sup>[18]</sup> Enzymatic activity

**Table 1: Demographic and baseline characteristics of patients (n=21)**

Variable	Statistics
Age, years	
Mean±SD	62±8
Range	44-78
Male:female	12:9
Phakic: pseudophakic	2:19
Diameter of VMT (µm), n (%)	
<1500	16 (76.2)
1500	5 (23.8)
MH size (µm), n	
<250	2/3
>250-400	1/3
IOP, mmHg	14±8
Baseline BCVA, LogMAR	
Mean±SD	0.50±0.24
Range	1-0.1
RS, dB	
Mean±SD	14.69±2.34
Range	11-19.5
CRS, dB	
Mean±SD	13.48±2.71
Range	9.2-19.5
BCEA, degree <sup>2</sup> , mean±SD	
At 68%	0.61±0.28
At 95%	1.69±0.69
At 99%	2.91±1.23

SD=Standard deviation, VMT=Vitreomacular traction, n=Number of patients, IOP=Intraocular pressure, BCVA=Best-corrected visual acuity, LogMAR=Logarithm of minimum angle of resolution, RS=Retinal sensitivity, dB=Decibel, CRS=Central retinal sensitivity, BCEA=Bivariate contour ellipse area

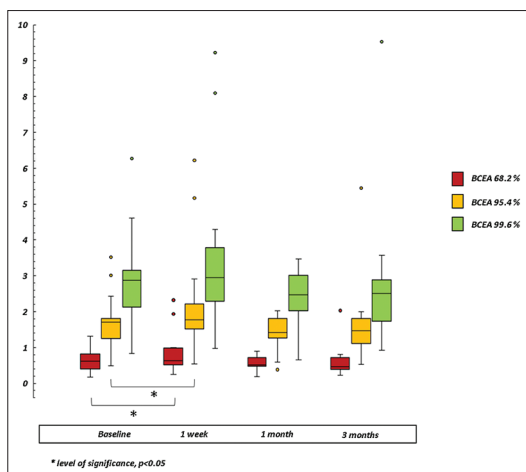
**Table 2: Functional changes in eyes with and without macular traction resolution over follow-up**

Time point	Variable	Total	Group A	Group B	P*
Baseline	BCVA (logMAR±SD)	0.50±0.24	0.52±0.21	0.47±0.27	0.52
	RS (dB±SD)	14.69±2.34	14.19±2.39	15.24±2.27	0.45
	CRS (dB±SD)	13.48±2.71	12.85±2.24	14.15±3.13	0.52
1 week	BCVA (logMAR±SD)	0.56±0.21	0.58±0.20	0.53±0.23	0.62
	P†	<0.01	0.09	<0.01	
	RS (dB±SD)	12.82±2.42	12.85±2.60	12.79±2.34	0.91
1 month	BCVA (logMAR±SD)	0.44±0.23	0.40±0.23	0.49±0.22	0.37
	P†	0.03	0.001	0.53	
	RS (dB±SD)	14.30±2.15	14.56±2.14	14.01±2.25	0.54
3 months	BCVA (logMAR±SD)	0.37±0.27	0.30±0.24	0.44±0.29	0.19
	P†	0.001	<0.001	0.19	
	RS (dB±SD)	15.85±2.19	16.63±2.25	14.9±1.85	0.04
	CRS (dB±SD)	14.9±2.39	15.45±2.62	14.3±2.08	0.35
	P†	0.02	<0.01	0.81	

\*P value (Mann-Whitney test), comparison of outcomes between Group A (eyes with resolved VMT) and Group B (eyes with unresolved VMT); †P value (Wilcoxon test), comparison of outcomes at different follow-up visits for all patients and within each Group; P<0.05 was considered statistically significant. BCVA=Best corrected visual acuity, logMAR=Logarithm of minimum angle of resolution, SD=Standard deviation, RS=Retinal sensitivity, dB=Decibel, CRS=Central retinal sensitivity

of ocriplasmin includes cleavage of fibronectin and laminin, the latter being prominent in Bruch membrane, the interphotoreceptor matrix, and the inner and outer retinal layers.<sup>[19]</sup> In this study, the VMT-release rate improved from 28.5% at 1 week to 52.4% at 1 month from injection. The latter success rate is higher than that in the MIVI-TRUST trial where eyes had a VMT-release rate of 26.5%,<sup>[3]</sup> but closer to the success rate in the OASIS trial (41.7%),<sup>[5]</sup> ORBIT study (45.8%)<sup>[20]</sup> and OVIID-I study (43.4%).<sup>[21]</sup> In addition, several smaller studies have reported a similar high release rate of between 42%<sup>[22]</sup> and 50%<sup>[23]</sup> at day 28, confirming that success rate for ocriplasmin in a real-world setting is higher than MIVI-TRUST, probably due to the better knowledge of the prognostic factors for traction release. In this study, most patients met many of these prognostic factors as age, gender, VMT diameter <1500 µm, and epiretinal membrane absence. However, 19/21 eyes had pseudophakic lens status that, despite is a negative prognostic factor for traction resolution, it might have limited the influence of age-related crystalline lens opacity on functional results. All eyes with MH obtained hole closure over 3 months. In the OVIID-I trial, the highest MH closure rate (57.1%) was reported in patients with MH ≤250 µm<sup>[21]</sup> and the small size of MH was just identified as positive prognostic factor for hole closure.<sup>[12]</sup> In this study, two cases had a MH size <250 µm while the other one had a hole size between 250 µm and 400 µm. An analysis of different studies on ocriplasmin identified

a variable incidence rate of visual acuity impairment, mostly occurred in the 1<sup>st</sup> week following treatment and resolved with a median recovery time of 2 weeks.<sup>[12]</sup> In the ORBIT study, 6.7% of patients had a decrease in vision of ≥2 ETDRS lines between day 0 and day 7 postinjection,<sup>[20]</sup> in the OASIS study 12.3% of patients complained an early loss of visual acuity,<sup>[5]</sup> while in the OVIID-1 trial 26.9% complained a visual acuity impairment ≥2 lines.<sup>[21]</sup> We reported an incidence rate of visual acuity loss (2 ETDRS lines, 0.2 LogMAR) of 14.2% at 1 week, a rate in line with those previously mentioned and closer to that reported in the OASIS study. However, 42.8% of our patients, three with resolved VMT and six with unresolved VMT, had a loss of 1 ETDRS line (0.1 LogMAR) after 1 week. Therefore, both patients with resolved and unresolved VMT experienced an early visual acuity reduction after treatment. In literature, only a case series focused on visual acuity impairment occurring in responded and in nonresponded patients but at 28 days' postinjection.<sup>[22]</sup> Over follow-up BCVA progressively improved, mainly in the eyes with VMT resolution. On the other hand, visual acuity returned to near baseline value when macular traction resolution did not occur. If early visual loss could be due to vitreous opacities when VMT resolution occurred, other factors could cause a decrease in vision in case of unresolved VMT. The functional trend of visual acuity could be explained by a transient effect of enzymatic activity of ocriplasmin on the retinal



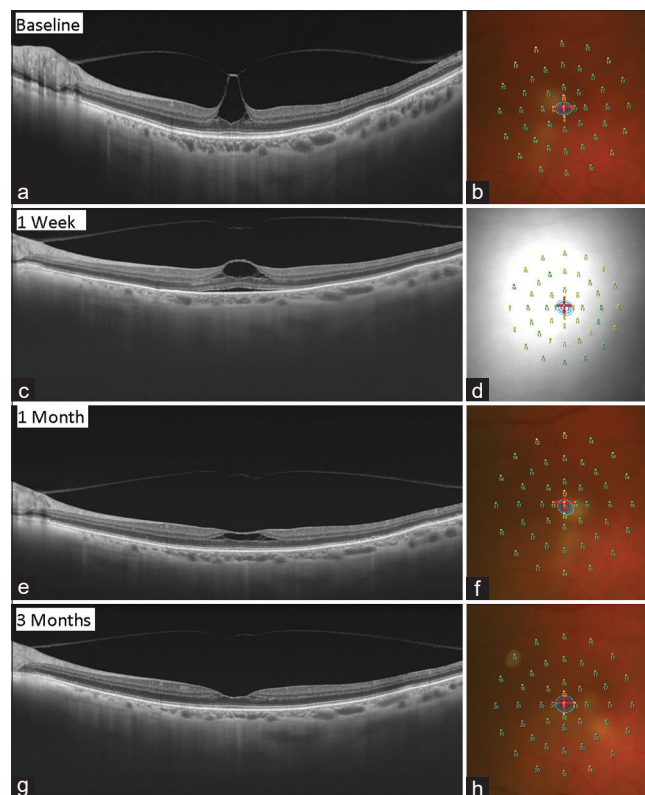
**Figure 1:** Bivariate contour ellipse area changes over follow-up. Bivariate contour ellipse area represents the area of an ellipse which encompasses a given proportion of fixation points (68%, 95%, and 99%). Each box-plot identifies each ellipse at different follow-up. In each box-plot, we draw a box from the first quartile to the third quartile. A horizontal line goes through the box at the median. The whiskers go from each quartile to the minimum or maximum. All ellipses had a similar trend over follow-up. An increase in dimension at 1 week, followed by a reduction at 1 month and a slow recovery to the baseline values after 3 months was recorded

**Table 3: Fixation stability changes over follow-up**

	BCEA	Total	Group A	Group B	P*
Baseline	68.2%	0.61±0.28	0.58±0.19	0.65±0.37	0.69
	95.4%	1.69±0.69	1.52±0.29	1.87±0.95	0.23
	99.6%	2.91±1.23	2.64±0.67	3.20±1.64	0.34
1 week	68.2%	0.79±0.51	0.65±0.23	0.86±0.52	0.50
	P†	0.01	0.02	0.05	
	95.4%	2.08±1.32	1.62±0.24	2.39±1.44	0.52
1 month	68.2%	0.56±0.17	0.52±0.13	0.67±0.29	0.15
	P†	0.24	0.03	0.66	
	95.4%	1.48±0.37	1.37±0.21	1.60±0.47	0.07
3 months	68.2%	0.56±0.39	0.44±0.20	0.70±0.50	0.19
	P†	0.51	0.003	0.71	
	95.4%	1.59±0.97	1.27±0.34	1.95±1.31	0.08
3 months	68.2%	2.66±1.72	2.07±0.61	3.47±2.27	0.01
	P†	0.65	0.03	0.85	
	99.6%	3.36±1.98	2.65±0.52	4.04±2.51	0.03
1 month	68.2%	0.56±0.17	0.52±0.13	0.67±0.29	0.15
	P†	0.24	0.03	0.66	
	95.4%	1.48±0.37	1.37±0.21	1.60±0.47	0.07
1 week	68.2%	0.79±0.51	0.65±0.23	0.86±0.52	0.50
	P†	0.01	0.02	0.05	
	95.4%	2.08±1.32	1.62±0.24	2.39±1.44	0.52
Baseline	68.2%	0.61±0.28	0.58±0.19	0.65±0.37	0.69
	95.4%	1.69±0.69	1.52±0.29	1.87±0.95	0.23
	99.6%	2.91±1.23	2.64±0.67	3.20±1.64	0.34

\*P value (Mann-Whitney test), comparison of outcomes between Group A (eyes with resolved VMT) and Group B (eyes with unresolved VMT);  
 † P (Wilcoxon test), comparison of outcomes at different follow-up visits for all patients and within each Group; P<0.05 was considered statistically significant.  
 BCEA=Bivariate contour ellipse area at 68.2%, 95.4% and 99.6% of fixation points, degrees<sup>2</sup> (mean±SD). SD=Standard deviation, VMT=Vitreo-macular traction

extracellular matrix or photoreceptor and postreceptor structures.<sup>[7,8]</sup> Various studies reported OCT alterations particularly prominent in the ellipsoid zone after ocriplasmin injection.<sup>[23,24]</sup> Chen *et al.* reported that ocriplasmin did not affect photoreceptor cells, however



**Figure 2:** Morphologic and functional changes in a case of resolved vitreomacular traction. Optical coherence tomography scans combined with microperimetric sensitivity maps and bivariate contour ellipse area. (a) Optical coherence tomography feature of vitreomacular traction with (b) corresponding central scotoma (yellow/orange numbers) at sensitivity map; (c) the traction resolution would seem to induce a foveal/parafoveal stretching of inner/outer retinal layers with; (d) related relative scotoma (yellow/orange numbers); (e) a slow release of tissues occurs over follow-up with (f) an increase of retinal sensitivity; (g) foveal pit is reconstituted; and (h) sensitivity returned to near baseline values. The three concentric ellipsoid areas at the center of the map (b) show a mild increase in dimension at 1 week (d), and a slow recovery to the baseline values over follow-up (f and h)

its effect on the retinal pigment epithelium and adjacent structures remained unclear.<sup>[25]</sup> If visual acuity, as a measurement of foveolar function, could not help alone in understanding functional changes after ocriplasmin, microperimetric analysis provides a more global assessment of retinal function within and outside the fovea after treatment. Only in the OASIS MP-1 substudy, early microperimetric changes after ocriplasmin injection were evaluated. In the treated group, the relative scotoma increased at 1 week postinjection recovering to baseline values after 6 months. Moreover, final RS was consistently higher in the ocriplasmin versus sham group after 3 months.<sup>[15]</sup> We analyzed the changes in RS within the central 4° and 12° after ocriplasmin injection, considering that the sensitivity of the parafoveal retina area is higher than that at the central 0 degrees in normal individuals<sup>[26,27]</sup> and the major age-related decrease of RS in the perifoveal area than in the center of macula.<sup>[28]</sup> Differently from the OASIS MP-1 substudy, we analyzed the change in RS in eyes with and without VMT resolution over follow-up. Our results showed that both mean RS and CRS

significantly decreased after 7 days from injection, regardless VMT resolution, followed by a progressive functional recovery at month one and three. Also in the OASIS substudy, RS reduction early occurred after induction of vitreous detachment, with subsequent recovery to near baseline by month 3.<sup>[15]</sup> In our study, baseline sensitivity parameters were higher in the eyes that not experienced VMT resolution, contrarily to the OASIS substudy. However, we observed that eyes that not experienced VMT resolution had an early higher reduction of mean RS (2.45 dB) and CRS (2.49 dB) than eyes with resolved VMT (RS, 1.34 dB; CRS, 1.38 dB). Moreover, eyes with resolved VMT had a higher increase of sensitivity (RS, 2.44 dB; CRS, 2.6 dB) than eyes without traction resolution (RS, -0.25 dB; CRS, 0.15 dB) after 3 months. A range between 90% and 95% of patients experienced an early reduction in RS, regardless macular traction resolution. However, a higher number of resolved VMT eyes had a faster and better sensitivity recovery over follow-up. The transient decrease in macular function could be most likely due to mechanical forces transmitted on posterior vitreous cortex resulting in increased foveal/parafoveal traction. Enzymatic vitreolysis may be associated with “trampoline-like” transient forces mainly on the middle and outer retinal layers, resulting in a relatively larger description of electrical signaling recorded by ERG<sup>[6]</sup> and microperimetry. We can also speculate that Müller cells playing a role in vitreoretinal adhesion<sup>[29]</sup> but also in neuroretinal architecture and metabolism,<sup>[30]</sup> could be a target of enzymatic vitreolysis. The trend of RS could suggest that mechanical stretch on neuroretinal layers, transmitted from vitreoretinal interface to outer retinal layers, is harder and more prolonged in case of unresolved physical vapor deposition probably due to a stronger adhesion of vitreous cortex, resulting in a greater functional stress on neuroretina. Another important functional parameter to consider in the treatment of macular diseases is fixation stability, probably more than fixation location in VMT condition where the locus of fixation could already be naturally relocated out of foveal site. In the OASIS MP-1 study, mean BCEA slightly decreased after 1 week with a slow increase in dimension after 1 month in treated eyes.<sup>[15]</sup> Conversely, we observed that BCEA at 68%, 95% and 99% of fixation points had an increase in dimension at 1 week, followed by a reduction at 1 month and a slow recovery to near baseline values after 3 months, regardless VMT resolution. At 3 months, the fixation significantly improved in case of VMT resolution while the eyes without VMT resolution had a less stable fixation in particular at 99.6% of fixation points. It is reasonable to assume that mechanical effects due to a transient increase in VMT after treatment would lead to a reorganization of the fixation behavior producing an enlargement of the cloud of fixation points. Conversely,

the resolution of VMT could reduce the cloud of fixation points. We know that a smaller ellipsoid area correlates to more stable fixation and better visual performance. However, fixation stability was not related to visual acuity and the compensation of fixation instability does not improve visual acuity in patients with macular disease.<sup>[31]</sup> Our study has different limitations, some shared with OASIS MP-1 substudy, including the small sample size, the study visits that were not scheduled between baseline and 1 week, not revealing if functional changes occurred before day 7 postinjection, the absence of analysis of outer retinal layers status and of microperimetric measurement variability. Factors acting on microperimetric test variability are related to patient’s compliance and clinical condition, to the examiner and instrument used. In particular, it should be mentioned the “learning factor” which can justify a certain degree of functional improvement at microperimetry during follow-up, the “eye-tracker system,” not able to ensure the same accuracy of sensitivity analysis between foveal and perifoveal site, the “point to point” overlapping error (0.5°–2°) between different tests when the “Follow-up” program of MP-1 microperimeter is used, the “4–2 strategy” algorithm used by microperimeter, which can extend the duration of the test and fatigue the patient, the “ceiling effect,” meaning the tendency to accumulate responses at the highest limit of the sensitivity threshold, and the size of each light stimulus that could involve not a single photoreceptor but more photoreceptors which converge on a single ganglion cell. We are unable to ascertain whether the functional changes reported are due to tractional stress on retinal architecture or to the toxic effect of ocriplasmin on the retinal cells or a combination of them, so our considerations remain speculative. Nonetheless, we observed new functional changes after ocriplasmin injection requiring for further insight.

## Conclusion

Ocriplasmin is confirmed as an alternative treatment for VMT with or without MH in selected cases. Early and reversible functional impairment could occur after injection, regardless VMT resolution, followed by a faster and better recovery in the event of vitreomacular release. RS and fixation behavior analysis could represent a complementary tool respect visual acuity test to investigate functional changes after ocriplasmin injection.

## Declaration of patient consent

The authors certify that they have obtained all appropriate patient consent forms. In the form, the patients have given their consent for images and other clinical information to be reported in the journal. The patients understand that their name and initials will not be published and

due efforts will be made to conceal their identity, but anonymity cannot be guaranteed.

### Financial support and sponsorship

Nil.

### Conflicts of interest

The authors declare that there are no conflicts of interests of this paper.

## References

1. Jackson TL, Donachie PH, Johnston RL; Vitreomacular Traction Study Group. Electronic medical record database study of vitrectomy and observation for vitreomacular traction. *Retina* 2016;36:1897-905.
2. Duker JS, Kaiser PK, Binder S, de Smet MD, Gaudric A, Reichel E, *et al.* The International Vitreomacular Traction Study Group classification of vitreomacular adhesion, traction, and macular hole. *Retina* 2013;120:2611-9.
3. Stalmans P, Benz MS, Gandorfer A, Kampik A, Girach A, Pakola S, *et al.* Enzymatic vitreolysis with ocriplasmin for vitreomacular traction and macular holes. *N Engl J Med* 2012;367:606-15.
4. Jackson TL, Regillo CD, Girach A, Dugel PU; MIVI-TRUST Study Group. Baseline Predictors of Vitreomacular Adhesion/Traction Resolution Following an Intravitreal Injection of Ocriplasmin. *Ophthalmic Surg Lasers Imaging Retina* 2016;47:716-23.
5. Dugel PU, Tolentino M, Feiner L, Kozma P, Leroy A. Results of the 2-year ocriplasmin for treatment for symptomatic vitreomacular adhesion including macular hole (OASIS) Randomized Trial. *Ophthalmology* 2016;123:2232-47.
6. Birch DG, Benz MS, Miller DM, Antoszyk AN, Markoff J, Kozma P, *et al.* Evaluation of full-field electroretinogram reductions after ocriplasmin treatment: Results of the OASIS trial ERG substudy. *Retina* 2018;38:364-78.
7. Freund KB, Shah SA, Shah VP. Correlation of transient vision loss with outer retinal disruption following intravitreal ocriplasmin. *Eye (Lond)* 2013;27:773-4.
8. Fahim AT, Khan NW, Johnson MW. Acute panretinal structural and functional abnormalities after intravitreal ocriplasmin injection. *JAMA Ophthalmol* 2014;132:484-6.
9. Tibbetts MD, Reichel E, Witkin AJ. Vision loss after intravitreal ocriplasmin: Correlation of spectral-domain optical coherence tomography and electroretinography. *JAMA Ophthalmol* 2014;132:487-90.
10. Reiss B, Smithen L, Mansour S. Acute vision loss after ocriplasmin use. *Retin Cases Brief Rep* 2015;9:168-9.
11. Rossi S, Testa F, Melillo P, Orrico A, Della Corte M, Simonelli F. Functional improvement assessed by multifocal electroretinogram after ocriplasmin treatment for vitreomacular traction. *BMC Ophthalmol* 2016;16:110.
12. Chatziralli I, Theodossiadis G, Xanthopoulou P, Miliogkos M, Sivaprasad S, Theodossiadis P. Ocriplasmin use for vitreomacular traction and macular hole: A meta-analysis and comprehensive review on predictive factors for vitreous release and potential complications. *Graefes Arch Clin Exp Ophthalmol* 2016;254:1247-56.
13. Jivrajka RV, Genead MA, McAnany JJ, Chow CC, Mieler WF. Microperimetric sensitivity in patients on hydroxychloroquine (Plaquenil) therapy. *Eye (Lond)* 2013;27:1044-52.
14. Querques G, Lattanzio R, Querques L, Triolo G, Cascavilla ML, Cavallero E, *et al.* Impact of intravitreal dexamethasone implant (Ozurdex) on macular morphology and function. *Retina* 2014;34:330-41.
15. Sadda SR, Dugel PU, Gonzalez VH, Meunier E, Kozma P. THE OASIS MP-1 SUBSTUDY: Characterization of the effect of ocriplasmin on microperimetry parameters. *Retina* 2019;39:319-30.
16. Ocriplasmin for Vitreomacular Traction. Information for the Public. London (UK): National Institute for Health and Care Excellence (NICE); October, 2013. (Technology appraisal guidance; no. 297). Available from: <https://www.guidelinecentral.com/summaries/ocriplasmin-for-treating-vitreomacular-traction/#section-442>. [Last accessed on 2020 Feb 20].
17. Duker JS, Kaiser PK, Binder S, de Smet MD, Gaudric A, Reichel E, *et al.* The International Vitreomacular Traction Study Group classification of vitreomacular adhesion, traction, and macular hole. *Ophthalmology* 2013;120:2611-9.
18. Gandorfer A, Rohleder M, Sethi C, Eckle D, Welge-Lüssen U, Kampik A, *et al.* Posterior vitreous detachment induced by microplasmin. *Invest Ophthalmol Vis Sci* 2004;45:641-7.
19. Libby RT, Champlaud MF, Claudepierre T, Xu Y, Gibbons EP, Koch M, *et al.* Laminin expression in adult and developing retinae: Evidence of two novel CNS laminins. *J Neurosci* 2000;20:6517-28.
20. Khanani AM, Duker JS, Heier JS, Kaiser PK, Joondeph BC, Kozma P, *et al.* Ocriplasmin Treatment Leads to Symptomatic Vitreomacular Adhesion/Vitreomacular Traction Resolution in the Real-World Setting: The Phase IV ORBIT Study. *Ophthalmol Retina* 2019;3:32-41.
21. Tadayoni R, Holz FG, Zech C, Liu X, Spera C, Stalmans P. Assessment of anatomical and functional outcomes with ocriplasmin treatment in patients with vitreomacular traction with or without macular holes: Results of OVIID-1 trial. *Retina* 2019;39:2341-52.
22. Singh RP, Li A, Bedi R, Srivastava S, Sears JE, Ehlers JP, *et al.* Anatomical and visual outcomes following ocriplasmin treatment for symptomatic vitreomacular traction syndrome. *Br J Ophthalmol* 2014;98:356-60.
23. Itoh Y, Ehlers JP. Ellipsoid zone mapping and outer retinal characterization after intravitreal ocriplasmin. *Retina* 2016;36:2290-6.
24. Quezada-Ruiz C, Pieramici DJ, Nasir M, Rabena M, Steinle N, Castellarin AA, *et al.* Outer retina reflectivity changes on SD-OCT after intravitreal ocriplasmin for vitreomacular traction and macular hole. *Retina* 2015;35:1144-50.
25. Chen W, Mo W, Sun K, Huang X, Zhang YL, Song HY. Microplasmin degrades fibronectin and laminin at vitreoretinal interface and outer retina during enzymatic vitrectomy. *Curr Eye Res* 2009;34:1057-64.
26. Fujiwara A, Shiragami C, Manabe S, Izumibata S, Murata A, Shiraga F. Normal values of retinal sensitivity determined by macular integrity assessment. *Nippon Ganka Gakkai Zasshi* 2014;118:15-21.
27. Denniss J, Astle AT. Central perimetric sensitivity estimates are directly influenced by the fixation target. *Ophthalmic Physiol Opt* 2016;36:453-8.
28. Sabates FN, Vincent RD, Koulen P, Sabates NR, Gallimore G. Normative data set identifying properties of the macula across age groups: Integration of visual function and retinal structure with microperimetry and spectral-domain optical coherence tomography. *Retina* 2011;31:1294-302.
29. Klöti R. Experimental occlusion of retinal and ciliary vessels in owl monkeys. I. Technique and clinical observations of selective embolism of the central retinal artery system. *Exp Eye Res* 1967;6:393-9.
30. Bringmann A, Pannicke T, Grosche J, Francke M, Wiedemann P, Skatchkov SN, *et al.* Müller cells in the healthy and diseased retina. *Prog Retin Eye Res* 2006;25:397-424.
31. Macedo AF, Crossland MD, Rubin GS. Investigating unstable fixation in patients with macular disease. *Invest Ophthalmol Vis Sci* 2011;52:1275-80.