

Malignant epithelial/exocrine tumors of the pancreas

Claudio Luchini¹, Federica Grillo^{2,3}, Matteo Fassan⁴, Alessandro Vanoli⁵, Paola Capelli¹, Gaetano Paolino¹, Giuseppe Ingravallo⁶, Giuseppina Renzulli⁶, Claudio Doglioni^{7,8}, Alessandro D'Amuri⁹, Paola Mattiolo¹, Sara Pecori¹, Paola Parente¹⁰, Ada M. Florena¹¹, Giuseppe Zamboni^{1,12}, Aldo Scarpa^{1,13}

¹ Department of Diagnostics and Public Health, Section of Pathology, University and Hospital Trust of Verona, Verona, Italy; ² Anatomic Pathology, San Martino IRCCS Hospital, Genova, Italy; ³ Anatomic Pathology, Department of Surgical Sciences and Integrated Diagnostics (DISC), University of Genova, Italy; ⁴ Surgical Pathology Unit, Department of Medicine (DIMED), University of Padua, Italy; ⁵ Anatomic Pathology Unit, Department of Molecular Medicine, University of Pavia, and IRCCS San Matteo Hospital, Italy; ⁶ Department of Emergency and Organ Transplantation, Section of Pathological Anatomy, University of Bari Aldo Moro, Bari, Italy; ⁷ Vita e Salute University, Milan, Italy; ⁸ Pathology Unit, Pancreas Translational and Clinical Research Center, IRCCS San Raffaele Scientific Institute, Milan, Italy; ⁹ Anatomic Pathology Unit, "A. Perrino" Hospital, Brindisi, Italy; ¹⁰ Pathology Unit, Fondazione IRCCS Ospedale Casa Sollievo della Sofferenza, San Giovanni Rotondo (FG), Italy; ¹¹ Department of Sciences for Promotion of Health and Mother and Child Care, Anatomic Pathology, University of Palermo, Italy; ¹² IRCCS Sacro Cuore Don Calabria Hospital, Negrar, Italy; ¹³ ARC-NET Research Centre, University of Verona, Verona, Italy

Received and accepted: July 7, 2020
Published online: 29 October, 2020

Correspondence

Giuseppe Zamboni
Department of Diagnostics and Public Health,
Section of Pathology, University and Hospital
Trust of Verona, 37134 Verona, Italy, and
Department of Pathology, IRCCS Sacro Cuore
Don Calabria Hospital, 37024 Negrar, Italy
Tel. 0039 045 8027618
E-mail: giuseppe.zamboni@univr.it

Conflict of interest

The Authors declare no conflict of interest.

How to cite this article: Luchini C, Grillo F, Fassan M, et al. Malignant epithelial/exocrine tumors of the pancreas. *Pathologica* 2020;112:210-226. <https://doi.org/10.32074/1591-951X-167>

© Copyright by Società Italiana di Anatomia Patologica e Citopatologia Diagnostica, Divisione Italiana della International Academy of Pathology



OPEN ACCESS

This is an open access journal distributed in accordance with the CC-BY-NC-ND (Creative Commons Attribution-NonCommercial-NoDerivatives 4.0 International) license: the work can be used by mentioning the author and the license, but only for non-commercial purposes and only in the original version. For further information: <https://creativecommons.org/licenses/by-nc-nd/4.0/deed.en>

Summary

Pancreatic malignant exocrine tumors represent the most important cause of cancer-related death for pancreatic neoplasms. The most common tumor type in this category is represented by pancreatic ductal adenocarcinoma (PDAC), an ill defined, stroma-rich, scirrhous neoplasm with glandular differentiation. Here we present the relevant characteristics of the most important PDAC variants, namely adenosquamous carcinoma, colloid carcinoma, undifferentiated carcinoma, undifferentiated carcinoma with osteoclast-like giant cells, signet ring carcinoma, medullary carcinoma and hepatoid carcinoma. The other categories of malignant exocrine tumors, characterized by fleshy, stroma-poor, circumscribed neoplasms, include acinar cell carcinoma (pure and mixed), pancreatoblastoma, and solid pseudopapillary neoplasms. The most important macroscopic, histologic, immunohistochemical and molecular hallmarks of all these tumors, highlighting their key diagnostic/pathological features are presented. Lastly, standardized indications regarding gross sampling and how to compile a formal pathology report for pancreatic malignant exocrine tumors will be provided.

Key words: pancreatic cancer, pancreatic ductal adenocarcinoma, PDAC, acinar, solid pseudopapillary

Introduction

Malignant exocrine tumors of the pancreas represent the most common pancreatic tumors, with pancreatic ductal adenocarcinoma (PDAC) in first place for both incidence and mortality rate. Due to the important clinical implications that follow a diagnosis of malignant exocrine tumor of the pancreas, pathologists should be aware of the most important diagnostic features and hallmarks of this group of tumors.

In this review, we will present this topic starting from the sampling protocols of pancreatic resection specimens, and arriving to describe the most important clinical, macroscopic, histologic, immunohistochemical

and molecular characteristics of PDAC, acinar cell carcinoma, pancreatoblastoma and solid pseudopapillary neoplasm.

The most important aim of this manuscript is providing to pathologists a serviceable and practical guideline for the correct approach to malignant exocrine tumors of the pancreas, which may be encountered during routine diagnostic activity. Finally, a schematic list of the most important points, which should be described in the final pathology report, is provided.

Gross sampling

The pancreatoduodenectomy specimen is one of the most challenging surgical samples for pathologists. It requires experience and knowledge of anatomical landmarks so that adequate information regarding resection margins, origin/size of tumor and number of lymph nodes is collected (at least 12 lymph nodes per specimen according to the recent 2017 UICC/AJCC staging handbook) ¹.

In patients with resectable PDAC of the pancreatic head, a R0 resection (i.e.: tumor-free resection margins) is a very important prognostic factor ²⁻⁵. However, R1 resection rates vary greatly between surgical series and the prognostic differences between R0 and microscopic R1 of the pancreatic neck margin/radial margins have not been confirmed by all studies ²⁻⁵. The main reason for these differences is that for many years non-standardized sampling protocols with little attention to circumferential margin status have been performed. Along this line, sampling protocols for pancreatic specimens have been under scrutiny for some years as the importance of standardization in specimen handling and sample selection have come to light ⁶.

A representative image of gross sampling is provided in Figure 1.

PANCREATODUODENECTOMY SPECIMEN HANDLING AND SAMPLING PROTOCOLS

Pancreatoduodenectomy specimens may vary with regards to which organs/parts of organs are present in the specimen such as: the distal portion of stomach in Whipple's procedure (while pylorus preserving pancreatetectomies will only have the duodenal bulb as the proximal margin), gall bladder and extrahepatic bile ducts, partial or complete venous resections (of the superior mesenteric vein or portal vein), which should be annotated by surgeons.

Once the specimen is received (ideally fresh specimens for better evaluation and biobanking), the stomach/duodenum/jejunum should be opened along the

free margin, to aid adequate fixation. A standardized sampling protocol may also include circumferential margin multicolor inking, which has proven to be a potentially important step for resection margin/surface identification ⁷. In the last decade, two main standardized sampling protocols have been proposed, both with advantages and disadvantages with regards to surface/margin recognition, complexity of cut up, distinction between tumor origin (pancreatic origin versus ampullary versus distal cholangiocarcinoma or cystic tumors) and lymph node yield.

The protocol proposed by Verbeke, axially slices the specimen perpendicularly to the long axis of the duodenum at the ampulla ⁸. Further slicing is continued cranially and caudally, in parallel to the first slice, until thin complete sections of all the pancreatic head are obtained. The main advantages of this protocol are the optimal evaluation of the circumferential margins/surfaces and an acceptable lymph node yield ⁹.

The bi-valving protocol according to Adsay involves sectioning the specimen in two halves following the plane between probes inserted in the pancreatic duct and the common bile duct ¹⁰. This method of sampling is also known as bi-valving. Prior to further sectioning, the inked pancreatic retroperitoneal margin (or superior mesenteric vessel margin) is orange peeled and fully submitted for histology with a bread-slicing sampling. The bi-valved specimen is then further sectioned (either axially, multi-valved or bread loafed). Lymph node harvesting is performed by orange-peeling of the circumferential margins/surfaces and this correlates with a high lymph node yield. Further advantages of this technique are the optimal evaluation of primary site of tumor (pancreatic, ampullary or common bile duct) and the complete evaluation of the retroperitoneal margin.

The pancreatoduodenectomy specimen requires multiple samples, including a tumor-representative sampling, the relationship of tumor with adjacent structures (e.g. common bile duct), transection margins (pancreatic, common bile duct, gastric/duodenal) and, above all in cases of extensive tumor infiltration, the circumferential resection margin(s)/surfaces. Attention must be paid in the case of resection for precursors of pancreatic cancer (e.g.: intraductal papillary mucinous neoplasm), in which an infiltration may be very focal, thus an extensive sampling is required ¹¹. Along this line, an extensive sampling is also of importance in the setting of post-neoadjuvant therapy, where a precise gross definition of tumor boundaries is not often recognizable ¹².

Among various issues frequently encountered during routine sampling activity, the most frequent regard the potential misunderstanding about specific nomen-

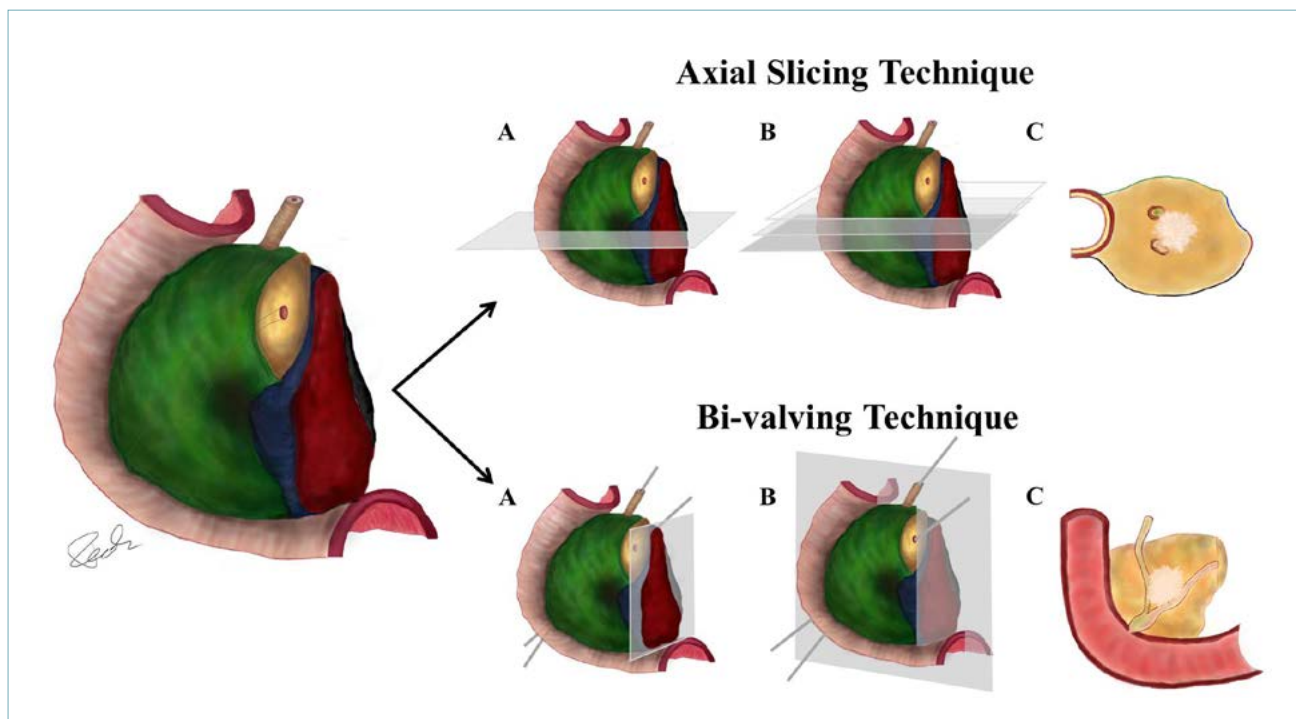


Figure 1. These images show the different sampling techniques for duodeno-pancreatic head resections. Margins are inked in different colors: green - anterior surface; blue - superior mesenteric vein groove; red - uncinata process/medial/retroperitoneal/superior mesenteric artery margin; black (minimum portion shown) - posterior surface. - *Axial Slicing Technique (upper panel)*: (A) initially, a horizontal section perpendicular to the duodenum and passing through the ampulla is performed; (B) parallel sections are then obtained; (C) complete section of duodenum with pancreatic head, main pancreatic duct, bile duct and tumor (whitish area). The circumferential margins/surfaces are shown with respective colors. - *Bi-valving Technique (lower panel)*: (A) the red uncinata process/medial/retroperitoneal/superior mesenteric artery margin is shaved and then bread-sliced and submitted entirely; (B) a horizontal section passing on a plane which passes through the probed bile duct and pancreatic duct is shown. Further sections can be parallel (or even perpendicular); (C) complete section of the bi-valved specimen showing the tumour (whitish area), which arises from the pancreas and invades the bile duct and the main pancreatic duct.

clature of circumferential margins/surfaces. Indeed, the superior mesenteric vessel margin can be also named as uncinata margin; the posterior aspect of the head of the pancreas can be intended both as a margin, behind the pancreatic transection margin, and as a surface, towards the duodenum¹³. Another possible issue includes the definition/concept of “positive” margin, since it can represent a direct invasion of neoplastic cells on the margin, but can be also defined as a distance < 1 mm between tumor cells and the margin¹⁴.

DISTAL PANCREATECTOMY SPECIMEN HANDLING AND SAMPLING PROTOCOL

Distal pancreatectomy specimens do not present significant issues in orientation and landmark identification typical in pancreatic head specimens. Indeed, the spleen and the pancreatic transection margin permit

left to right orientation, while the splenic artery and vein, which run along the posterior-superior groove of the pancreatic body and tail, permit cranial to caudal orientation. Inking with different colors is not mandatory, but can be useful for distinguishing anterior/posterior surfaces and the superior/inferior aspects. The specimen should be sliced in sections, parallel to the transection margin. This method permits the identification of the distance between the tumor and the transection margin, as well as aspects of adipose tissue infiltration and splenic vessels invasion. Lymph nodes can be retrieved from the peri-pancreatic soft tissue and from the splenic hilum; the most important site for lymph node sampling is along the course of splenic vessels.

SURGICAL RESECTIONS AFTER NEO-ADJUVANT THERAPY

Surgical resections after neoadjuvant therapy are be-

coming one of the most frequent scenario in pancreatic pathology, above all in specialized centers. These resections are often warp and diffusely whitish, with tumor area with blurred borders or even not visible. In such cases, an extensive sampling should be performed, and in cases of not identifiable tumor areas or of small tumor beds, they should be entirely included. Sometimes surgical resections include complex vessel resections (e.g.: celiac trunk, splenic-portal-mesenteric confluence), which should be correctly isolated during gross sampling and described in the final pathology report ¹⁵.

Pancreatic ductal adenocarcinoma

DEFINITION AND TERMINOLOGY

Pancreatic ductal adenocarcinoma (PDAC) is the most common type of pancreatic cancer ¹⁶. It is a malignant neoplasm composed of infiltrating glands that resembles pancreatic ducts. Synonyms include duct cell adenocarcinoma, infiltrating duct carcinoma or tubular adenocarcinoma ¹⁶.

CLINICAL AND GROSS FEATURES

About two-thirds of PDAC arise in the pancreatic head, with the rest affecting equally the body and/or the tail of the gland equally. Clinical features include back pain, dyspepsia, weight loss and new-onset diabetes; jaundice is a symptom typical of pancreatic head tumors. Rarely, acute pancreatitis and migratory thrombophlebitis may be seen in PDAC patients. Important risk factors for PDAC are tobacco smoking, obesity and alcohol consumption. The highest rates of PDAC incidence have been reported among black people in the USA. An increased risk for PDAC is also described for patients with chronic pancreatitis and diabetes mellitus, and for patients with a previously resected PDAC ^{16,17}.

From a macroscopic point of view, PDAC are usually a firm and poorly defined whitish mass with irregular borders. Usually they infiltrate surrounding structures, including peri-pancreatic adipose tissue, the duodenal wall, the distal choledocus and the ampulla of Vater. Cancers < 2 cm are quite rare (about 10% of PDAC) ^{16,18}. The most recent TNM staging system is mainly based on tumor size, with pT1 for tumors with a diameter \leq 2 cm, pT2 for tumors ranging from 2,1 to 4 cm, pT3 for tumors > 4 cm, and pT4 for tumors involving celiac axis, superior mesenteric artery, and/or common hepatic artery, regardless of size ¹⁹.

PRECURSORS OF PANCREATIC DUCTAL ADENOCARCINOMA

Precursors of PDAC include: Pancreatic Intraepithe-

lial Neoplasm (PanIN), Intraductal Papillary Mucinous Neoplasm (IPMN), Intraductal Oncocytic papillary Neoplasms (IOPN), Intraductal Tubulopapillary Neoplasm (ITPN), and Mucinous Cystic Neoplasm (MCN) ^{16,20-23}. All these lesions can progress into the invasive counterpart, which is represented by PDAC. PanIN is a microscopic, non-infiltrative epithelial neoplasm confined to the pancreatic ducts; it can show a flat or a micropapillary epithelium ^{16,20}. PanINs are classified with a two-tiered grading system: low grade and high grade dysplasia PanIN ^{15,24}. Due to their microscopic nature, PanINs are asymptomatic. Notably, high-grade PanINs represent the main precursor of PDAC ^{16,20}. From the molecular point of view, *KRAS* mutations have been described as an early event in PanIN formation and PDAC carcinogenesis, as well as *SMAD4* and *TP53* mutations represent late events in this model (high-grade PanIN) ^{16,20-23}.

IPMNs are intraductal neoplasms of the pancreas, with papillary mucinous epithelium. They are by definition > 5 mm and can involve Wirsung's duct (main duct IPMN), branch ducts (branch duct IPMN) or both (mixed IPMN) ^{16,20-23}. Main duct IPMN present a higher risk of malignant transformation and of metachronous recurrences compared to branch duct ^{25,26}. Based on the type of epithelium, IPMNs can be subdivided into intestinal, gastric and pancreatic-biliary; notably, in the current WHO classification, IOPN are considered separately from the other IPMN subtypes ^{16,20}. Similarly to PanIN, the dysplasia of IPMN is also classified as low- and high-grade. High-grade IPMN can progress to invasive PDAC, which can be indistinguishable from conventional PDAC, with the exception of colloid carcinoma, a distinct PDAC subtype producing abundant extracellular mucin, which originates from intestinal-type IPMN ²⁶⁻²⁸. From a genetic point of view, the most important alterations in IPMN include *KRAS* and *GNAS* mutations, and microsatellite instability, which is more common in the intestinal subtype ^{16,22,29}.

IOPN is a grossly exophytic, intraductal neoplasm composed by oncocytic glandular epithelium, which is more frequent in females. The most important distinctive features are the almost exclusive presence of high grade dysplasia and the lack of the most frequent somatic mutations of IPMN ¹⁶.

Macroscopically, the lesions are characterized by large, solid or papillary mass, which lack mucin. Microscopically, the lesion is constituted by complex, arborizing papillae, lined by cuboidal cells with eosinophilic granular cytoplasm, filled with mitochondria, intracytoplasmic lumen and large nuclei. Almost all IOPNs show high grade dysplasia, whereas invasive carcinoma occurs in only 30% of cases. Immunohistochemically, IOPNs show MUC6 and MUC1

positivity, with focal positivity for MUC5AC, whereas immunostaining for MUC2 and CDX2 is restricted to sparse goblet cells. IOPNs lack the common somatic mutations of IPMN, like *KRAS* and *GNAS*, whereas they can show mutations in *ERBB4* and the distinctive *PRKACA/B* gene fusions. The 5-year disease-specific survival approaches 100%.

ITPN are intraductal neoplasms of the pancreas, with a typical tubulopapillary appearance and usually with high-grade dysplasia¹⁶. From the histologic point of view, ITPN form nodules of back-to-back tubular glands, with a large, cribriform architecture; an associated invasive carcinoma is found in up to 70% of cases¹⁶. From a molecular point of view, ITPN are very peculiar, with no *KRAS* mutations; they show more frequently *KMT2* and PIK3-pathway gene mutations (*PI3KCA*, *PTEN*), and a subset of ITPN harbor *FGFR2* fusions^{16,20-23}.

MCNs are cyst-forming and mucin-producing epithelial neoplasm; they are associated with the presence of an ovarian-like sub-epithelial stroma^{16,20-23}. MCNs usually affect middle-aged women and arise in the body-tail region of the pancreas. They typically do not communicate with the Wirsung's duct. Similarly to PanIN and IPMN, the dysplasia of MCN is also classified into low- and high-grade. From a molecular point of view, *KRAS*, *TP53* and *RNF43* mutations are the most common mutations in MCN^{16,20}.

Although there is no useful immunohistochemical panel for the diagnosis of PanIN and MCN, for IPMN and ITPN there are some mucin-based stains that can be of much help in supporting diagnosis and identifying the correct histologic subtype (Tab. I)^{16,20}.

One of the most difficult challenges in pancreatic pathology regards the identification of foci of micro-infiltration originating from precursor lesions. The hallmark of an invasive component is represented by the presence of desmoplastic stroma around invasive, atypical glands. Notably, an important diagnostic pitfall is represented by the differential diagnosis between mucin extravasation in the periphery of lesions vs. true stromal invasion. The assessment of eventual

micro-invasive areas should be established by experienced pancreatic pathologists or at least discussed at a multi-headed microscope.

MICROSCOPIC DESCRIPTION WITH DIAGNOSTIC HALLMARKS

Most PDACs are composed of well to moderately differentiated duct-like and glandular structures, invading the pancreatic parenchyma¹⁶. They are characterized by an irregular growth pattern, which is typically associated with a usually marked desmoplastic stromal reaction. Indeed, PDACs exhibit an abundant stroma and consequently can be considered as hypocellular tumors. A very important feature, which can be easily used to discriminate neoplastic/infiltrative glands vs. normal ducts is represented by the fact that neoplastic glands are very commonly ruptured with areas of epithelial denudation of the gland, while normal ducts show a continuous epithelial lining. Histologically, PDAC are graded into a 3-tiered system: well, moderate and poorly differentiated PDAC, based on combined assessment of the degree of glandular differentiation, mucin production, mitotic activity and nuclear features¹⁶. Representative images of PDAC grading are provided in Figure 2, as well as a case of PDAC in the neoadjuvant setting, where no grading should be applied because it is unreliable due to iatrogenic modifications of tissues.

Well-differentiated PDACs are composed of haphazardly arranged invading and medium-size duct-like and glandular structures, with angular or irregular shapes^{16,30}. Neoplastic cells are generally columnar or cuboidal, forming a single cell layer with eosinophilic cytoplasm; the nuclei are round or oval and may be even four times larger than non-neoplastic nuclei^{16,30}. This comparison is often feasible since in many PDACs some normal ducts are trapped within the tumor mass. The nuclear membranes are well-delineated and the nucleoli, which generally are two or more, are often prominent; mitoses are not common. Lymphatic and blood vessel invasion/embolization, perineural infiltration as well as lymph node metastases represent very common findings^{16,30}. A pecu-

Table I. Immunohistochemical markers for IPMN/IOPN/ITPN classification.

Type of lesion	Subtype	MUC1	MUC2	MUC5AC	MUC6	CDX2
IPMN	G	negative	negative	positive	negative	negative
	PB	positive	negative	positive	positive	negative
	INT	negative	positive	positive	negative	positive
IOPN		positive	negative	positive	positive	negative
ITPN		positive	negative	negative	positive	negative

Abbreviations: IPMN: intraductal papillary mucinous neoplasm; IOPN: intraductal oncocytic papillary neoplasm; ITPN: intraductal tubulo-papillary neoplasm; G: gastric; PB: pancreatic-biliary; INT: intestinal.

Note: if the positivity of a marker is very intense at the immunohistochemical level and very important for diagnostic purposes, it is indicated in bold.

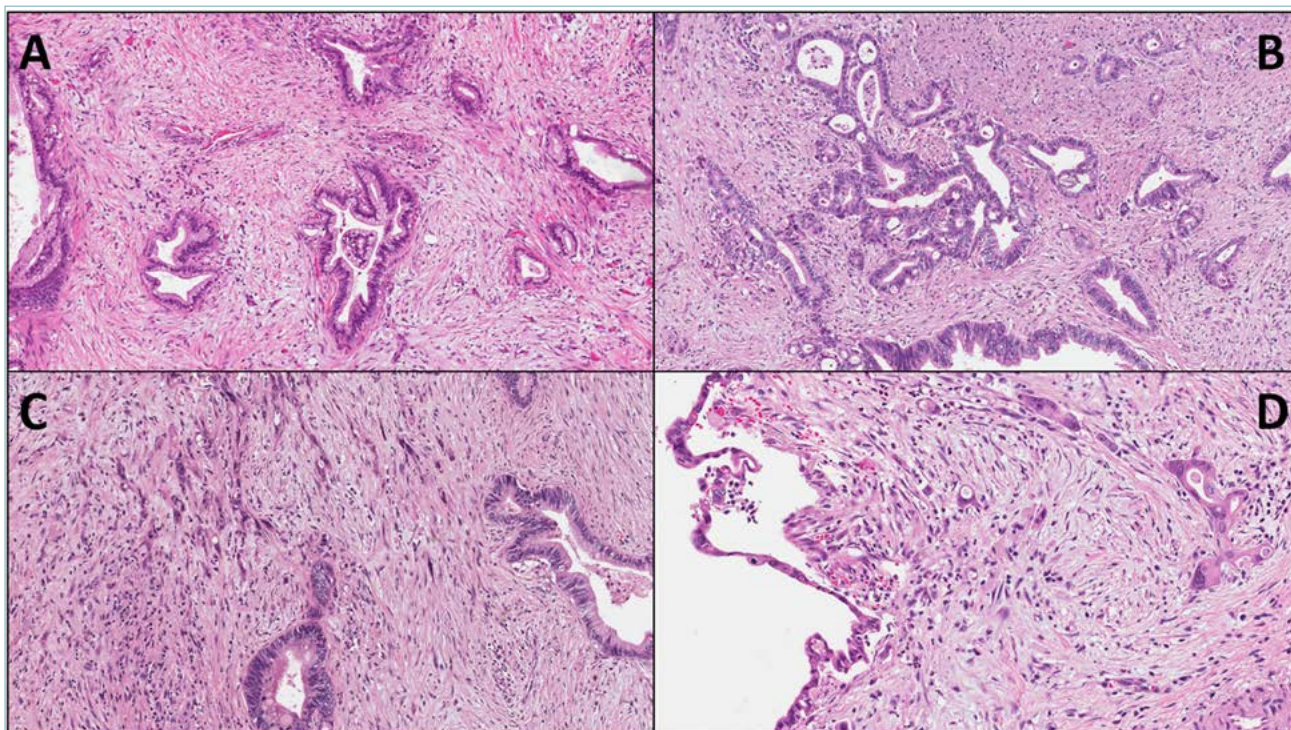


Figure 2. (A,B,C) Representative images of the grading system for pancreatic ductal adenocarcinoma: G1 (A, original magnification 20X), G2 (B, original magnification 20X) and G3 (C, original magnification 20X). D) In the setting of neo-adjuvant therapy, pancreatic ductal adenocarcinoma should not be graded, due to the unreliability of grading for the iatrogenic modifications of tissues, including therapy-induced cell atypia (original magnification 20X).

liar morphological aspect of lymph node metastasis, which is the extra-nodal extension of neoplastic cells in the peripheral adipose tissue, has recently been associated with worse prognosis in many cancer types, including PDAC³¹⁻³³.

Moderately differentiated PDACs are similar to the well-differentiated counterpart: glandular and duct-like structures, as well as the cellular and nuclear size, however, have a greater variation. Usually, tumor glands are smaller and neoplastic cells are larger, with more mitotic figures; mucin production appears to be less evident compared to well-differentiated PDAC^{16,30}.

Poorly differentiated PDACs are composed of small glands with irregular shape and of individual atypical cells; from the architectural point of view, poorly differential PDAC are densely packed tumors, sometimes with an arrangement in solid sheets and nests^{16,30}. Neoplastic cells exhibit pronounced nuclear pleomorphism, scanty or no mucin production and high mitotic activity. Areas with neoplastic cells organized in small aggregates or infiltrating as single elements are common, and represent so-called PDAC tumor budding, strictly correlated with the activation of the process of

epithelial-mesenchymal transition^{34,35}.

Some important morphologic features represent true diagnostic PDAC hallmarks. They include the irregular structural tumor pattern, the abundant desmoplastic stromal reaction and the presence of “ruptured” or “incomplete” glands^{16,30}. Furthermore, vascular and perineural invasions are both highly diagnostic of an infiltrating tumor. Another diagnostic PDAC hallmark is represented by neoplastic gland topographic location: indeed, the infiltrating malignant glands are often found in abnormal locations, such as immediately adjacent to muscular blood vessels^{30,36}. This criterion is helpful in the differential diagnosis with chronic pancreatitis and for supporting the diagnosis of PDAC in case of low-atypia (e.g.: in surgical specimens after neo-adjuvant therapies, where the degree of cellular atypia may be very mild)^{16,30}.

VARIANTS OF PANCREATIC DUCTAL ADENOCARCINOMA

The 2019 WHO classification distinguishes different PDAC variants, which are: adenosquamous carcinoma, colloid carcinoma, medullary carcinoma, poorly cohesive carcinoma/signet-ring cell carcinoma,

hepatoid carcinoma, large cell rhabdoid carcinoma, undifferentiated carcinoma and undifferentiated carcinoma with osteoclast-like giant cells¹⁶. Although some PDAC variants may show some peculiar macroscopic aspects, there are no definitive criteria to provide such a distinction by gross examination. At the same time, it has to be noted that colloid carcinoma is characterized by large pools of mucin, and undifferentiated carcinoma with osteoclast-like giant cells frequently shows foci of hemorrhage and/or necrosis. The other variants do not display peculiar gross aspects.

From a microscopic point of view, there are some specific features that characterize the different PDAC variants. Representative images of the most important variants are presented in Figure 3.

Adenosquamous carcinoma is composed of significant proportions with both ductal and squamous (at least 30%) differentiation^{16,30}. The squamous component can also be highlighted with immunohistochemistry for p63/p40³⁴. From a molecular point of view, this variant typically harbors *KRAS*, *TP53* and *UPF1* mutations^{37,38}. The prognosis is very poor³⁹.

Colloid carcinoma is characterized by the presence of large extracellular stromal mucin pools with suspended

tumor cells composing at least 80% of tumor mass¹⁶. This variant usually originates from intestinal-type IP-MN^{27,28}. Immunohistochemical markers of colloid carcinoma reflect its intestinal profile, with positivity for MUC2, CK20 and CDX2¹⁶. From a molecular point of view, colloid carcinoma are enriched of *GNAS* mutations (up to 60% of cases) and microsatellite instability^{40,41}. In pancreatic cancer, this alteration can be investigated with immunohistochemistry for the mismatch repair protein MLH1, PMS2, MSH2 and MSH6. In cases of doubtful results, MSI-based polymerase chain reaction or next generation sequencing should be performed⁴². Medullary carcinoma is a poorly differentiated carcinoma with limited gland formation, a pushing border, a syncytial growth and several tumor-infiltrating lymphocytes^{41,43}. This variant is usually associated with microsatellite instability, but a recent study highlighted that it can also arise in a hypermutated, non-microsatellite related genetic context, in association with *POLE* mutation⁴¹⁻⁴⁴.

Poorly cohesive/signet ring cell carcinoma is composed of at least 80% of individual poorly cohesive cells, often with intracellular mucin vacuoles peripherally displacing the nuclei⁴⁵.

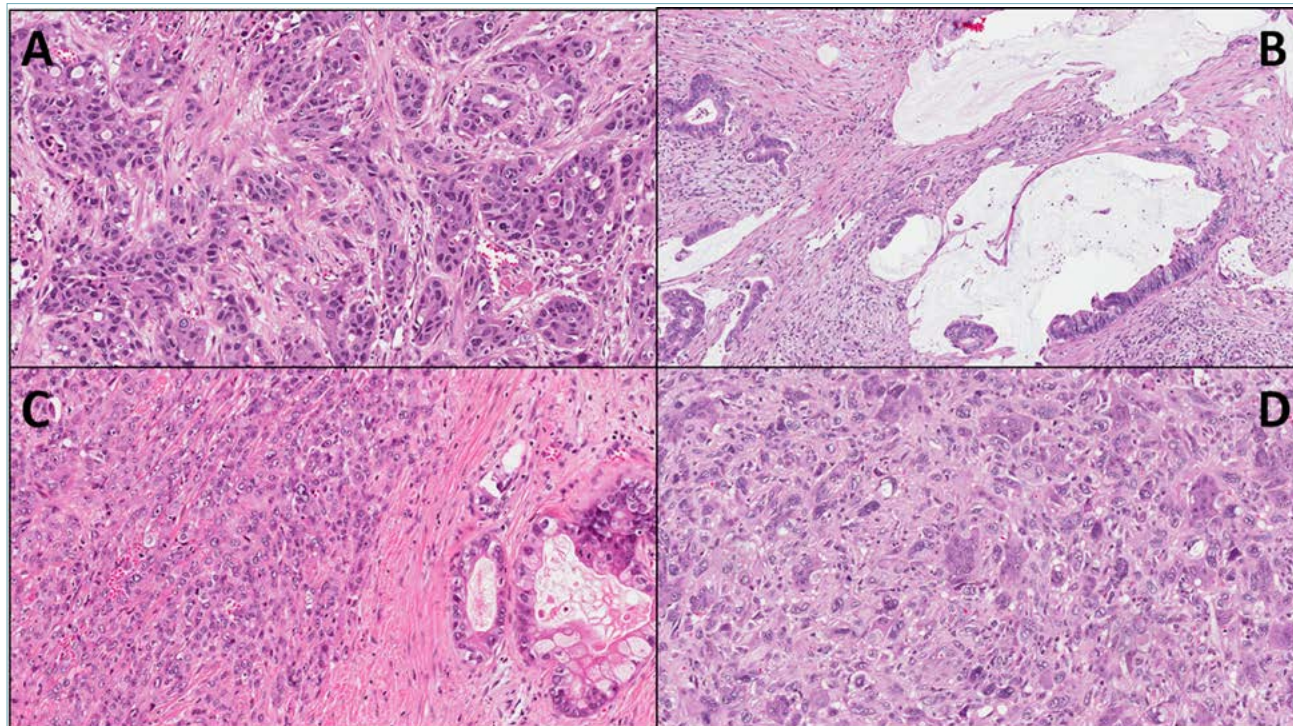


Figure 3. Representative images of the most relevant pancreatic ductal adenocarcinoma variants. (A) Adenosquamous carcinoma (original magnification 20X); (B) colloid carcinoma (original magnification 20X); (C) undifferentiated carcinoma (original magnification 20X); (D) undifferentiated carcinoma with osteoclast-like giant cells (original magnification 20X).

Hepatoid carcinoma is an extremely rare neoplasm, defined as a carcinoma in which at least 50% of cells display histological and immunohistochemical evidence of hepatocellular differentiation^{16,30}. They are composed of large, polygonal cells resembling those of hepatocellular carcinoma. Alpha-fetoprotein, Hepar1, CD10 and arginase are useful immunohistochemical markers to support such diagnosis, although the main diagnostic criterion remains morphology¹⁶. Rhabdoid carcinoma is a malignant neoplasm composed of large cells with rhabdoid features; it frequently harbors *KRAS* mutations/amplification, and in the case of *KRAS* wild-type, a typical SMARCB1 (*INI1*) immunohistochemical loss has been reported at the nuclear level^{16,45}.

Undifferentiated carcinoma is a malignant epithelial neoplasm in which the majority of tumor mass does not show any definitive direction of differentiation¹⁶. Different from conventional PDAC, undifferentiated carcinomas are hypercellular tumors. They can be stained with cytokeratin (CKAE1/3, CK8/18) and express an immunohistochemical profile associated with an activated epithelial-mesenchymal transition (expression of vimentin, *Twist1* and *Snai2*, and E-Cadherin loss)^{16,46,47}.

The undifferentiated carcinoma with osteoclast-like giant cells variant (UCOGC) is composed by three cell types: spindle and/or pleomorphic cells, the real neoplastic cells, mononuclear histiocytes and osteoclast-like giant cells^{16,46-48}. Osteoclast-like giant cells can show over 20 nuclei each and do not have a malignant behavior. This variant shows a genetic profile very similar to conventional PDAC, and seems enriched in *SERPINA3* mutations⁴⁹. Its unique immunologic microenvironment is dominated by the presence of tumor-stimulating histiocytes CD163-positive⁵⁰. In cases with the absence of an associated PDAC component, UCOGC prognosis may be very favorable with prolonged/long-term survivals⁴⁸⁻⁵⁰.

IMMUNOHISTOCHEMISTRY AND MOLECULAR PATHOLOGY

An unequivocal immunohistochemical panel that can be used to discriminate PDAC from other extrapancreatic mucin-producing adenocarcinomas does not exist. However, some markers may be of help in supporting a PDAC diagnosis. First of all, PDACs express the same keratins as the normal pancreatic duct epithelium, such as keratins 7, 8, 18 and 19^{16,30}; indeed, the highest sensibility and specificity is reached by the 8-18 cocktail. Keratin 20, a typical intestinal-epithelial marker, is not expressed by PDAC cells, with the exception of infiltrating tumors arising from intestinal-type IPMN⁵¹. Among mucins, PDAC cells are usually stained with IHC for MUC1, MUC4 and MUC5AC,

but not MUC2, which has a staining pattern very similar to Keratin 20^{52,53}.

PDACs are usually negative for pancreatic exocrine enzymes such as trypsin, chymotrypsin and lipase, and for the acinar-related marker Bcl-10, as well as for neuroendocrine markers, including chromogranin A, synaptophysin, CD56 and CD200^{16,30,49,54}. Regarding "immune-molecular" staining, the DPC4 protein is lost in up to 55% of PDACs, and the p53 protein is expressed in most cases^{16,30,49,55}. These two IHC markers may be very useful for the differential diagnosis between infiltrating vs. reactive glands.

Regarding molecular pathology, the most important alterations that are considered as the main genetic drivers of PDAC are somatic mutations affecting four key genes: the oncogene *KRAS* and the tumor suppressors *CDKN2A*, *TP53* and *SMAD4*^{56,57}. *KRAS* is the most common mutated gene in PDAC (up to 90-92% of cases); typical mutations occur in codons 12, 13 and 61⁵⁶⁻⁵⁹. Microsatellite instability is a genetic alteration that can occur in up to 2% of PDAC; however, it is more common in colloid and medullary variant than in conventional PDAC, where it probably represents a percentage < 1% of all cases⁴¹.

DIFFERENTIAL DIAGNOSIS

The most important differential diagnoses for conventional PDAC are summarized in Table II. The first to be considered is represented by chronic pancreatitis^{30,60}. From radiologic and macroscopic points of view, chronic pancreatitis may share several features with PDAC. It is important to underline that chronic pancreatitis with alcoholic or obstructive etiology usually involves the pancreas more widely than a neoplastic process, with a more rubbery and with a more gritty consistency of the parenchyma than in PDAC. From a microscopic point of view, the most important aspects to support the distinction between chronic pancreatitis and PDAC are certainly represented by the presence of vascular and neural invasion, and lymph node metastasis. Notably, the fibrosis of chronic pancreatitis may mimic the desmoplastic reaction of PDAC, and the degree of cell atypia should not be used as the most important criterion to rule out chronic pancreatitis, where the protracted inflammation may generate reactive cell alterations.

Autoimmune pancreatitis is another potential mimicker of PDAC, since it can present as a discrete, tumor-like lesion of the pancreas⁶¹⁻⁶⁷. The histological hallmarks of autoimmune pancreatitis are represented by a dense inflammation centered around pancreatic ducts, a cellular fibro-inflammatory stroma with a storiform appearance and a diffuse obliterative venulitis⁶¹⁻⁶⁷. A further potentially helpful analysis may include an immunohistochemical evaluation of plasma cells

Table II. Most relevant differential diagnoses for pancreatic ductal adenocarcinoma (PDAC), highlighting the histological aspect against PDAC diagnosis.

PDAC versus:	Useful features versus PDAC
Chronic pancreatitis	Ductal lithiasis, dense inflammatory infiltration, no clear signs of infiltrating tumor (e.g.: nodal metastasis).
Autoimmune pancreatitis	Marked inflammation with abundant plasma cells concentrated around pancreatic ducts, obliterative venulitis, cellular fibro-inflammatory stroma with a storiform appearance An increased numbers of IgG4 plasma cells.
Reactive glands	Location of glands (the presence of “naked” glands in fat is very suggestive for PDAC), absence of mitotic figures, absence of stromal desmoplastic reaction.
Precursor lesions	The presence of a possible infiltrating component, which lacks in non-infiltrating precursor lesions, should be excluded through an extensive sampling.

and of their IgG4+ sub-population, which is typically increased above all in type 1 autoimmune pancreatitis⁶⁴⁻⁶⁷.

Another important differential diagnosis that can be encountered during routine diagnostic activity is represented by reactive glands. From a microscopic point of view, the most helpful findings in distinguishing PDAC from reactive glands are represented by the location and the architecture of glands, in addition to the cytological aspects^{16,30}. The presence of “naked” glands in fat is a histological hallmark of PDAC, but attention must be paid to the fact that the adipose tissue may represent the result of adipose involution of normal pancreatic parenchyma rather than the true peri-pancreatic adipose tissue. In this case, residual neuroendocrine islets should be documented in fat tissue. Other features, that can support PDAC diagnosis are the presence of mitotic figures, necrotic luminal debris and stromal desmoplastic reaction.

The suggested immunohistochemical analysis to support a PDAC diagnosis in cases of doubtful histology include P53 and DPC4. P53 aberrant staining patterns, which are strictly correlated with *TP53* mutations, are represented by a complete loss of immunostaining or by a diffuse nuclear staining in at least 60-70% of tumor cells^{49,68}. DPC4 aberrant staining pattern, which is strictly associated with *SMAD4* mutations, is represented by loss of DPC4 nuclear expression⁶⁹.

Rarely, PDAC can exhibit a cystic appearance, thus the differential diagnoses include in such cases different types of cystic lesions. The cystic appearance may represent the macroscopic phenotype of a microscopic epiphenomenon (e.g.: PDAC intraductal colonization of a retention cyst or of a congenital cyst).

Acinar neoplasms

DEFINITION AND TERMINOLOGY

Although the acinar component constitutes the vast majority of the pancreatic parenchyma, neoplasms showing acinar cell differentiation are relatively ra-

re. They include acinar cell carcinoma, along with its mixed subtypes (mixed acinar-ductal carcinoma, mixed acinar-neuroendocrine carcinoma, mixed acinar-neuroendocrine-ductal carcinoma), and pancreatoblastoma¹⁶. In addition to these malignant neoplasms, the pancreas may undergo the so-called “acinar cystic transformation”, previously known as acinar cell cystadenoma, a non-neoplastic cystic lesion lined by acinar and ductal non-atypical cells, with no evidence of recurrence or malignant transformation.

ACINAR CELL CARCINOMA

Clinical and gross features

Acinar cell carcinomas (ACC) are rare neoplasms, accounting for only 1-2% of all pancreatic neoplasms in adults. The median age at ACC diagnosis is 60 years; however, it may also rarely affect children. Although ACC is predominantly located in the pancreatic head, jaundice is a rare symptom. Some patients may develop a lipase hypersecretion syndrome. The ACC patient prognosis is poor, with a 5-year survival rate of 25%. Grossly, ACC are large, well-circumscribed and solid mass, with a homogeneous, fleshy cut surface⁷⁰⁻⁷³. Necrotic or hemorrhagic areas may be present. In rare instances, the so-called “acinar cell cystadenocarcinomas,” gross appearance is entirely cystic.

Microscopic description with diagnostic hallmarks

Histologically, ACC is a highly cellular tumor, with scarce stroma. Tumor cells show granular eosinophilic, PAS-diastase-positive cytoplasm and relatively uniform nuclei with a characteristic single prominent eosinophilic nucleolus^{16,70-72}. Several architectural patterns (acinar, glandular, trabecular and solid), as well as the intraductal growth pattern have been described. The intraductal growth pattern is generally associated with a better prognosis. A representative image of an acinar cell carcinoma is provided in Figure 4A.

Immunohistochemistry and molecular pathology

Immunohistochemistry is of pivotal importance to con-

firm the acinar cell differentiation. Trypsin, chymotrypsin and BCL-10 (clone 331.3, recognizing the COOH-terminal portion of carboxyl ester lipase) are the most sensitive and specific immunohistochemical markers recommended for diagnosis. Pancreatic ductal markers, such as cytokeratins 7 and 19, as well as hepatocellular markers, such as HepPar-1, glypican 3, and alphafetoprotein, may be expressed by ACC^{16,70-72}.

Alterations in the Wnt/ β -catenin pathway have been frequently found, often due to APC promoter hypermethylation⁷⁴. Microsatellite instability has been detected in about 10% of cases, while an ACC subset harbors potentially targetable gene fusions involving *BRAF* or *RAF1*^{42,75}.

Differential diagnosis

The main differential diagnoses include: pancreatoblastoma, pancreatic neuroendocrine neoplasm, solid pseudopapillary neoplasm, as well as medullary and hepatoid variants of pancreatic ductal adenocarcinoma (Tab. III).

TNM stage is the most important prognostic factor for ACC; they are staged with the same TNM staging system adopted for pancreatic ductal adenocarcinoma.

MIXED ACINAR CARCINOMAS

Mixed carcinomas (mixed acinar-ductal carcinoma, mixed acinar-neuroendocrine carcinoma, mixed acinar-neuroendocrine-ductal carcinoma) are defined as carcinomas composed of two or three different components, each constituting at least 30% of tumor volume¹⁶.

Mixed acinar-neuroendocrine carcinomas account for about 20% of ACC (representative images are provided in Fig. 4B, C, D) Most acinar-neuroendocrine carcinomas do not display two morphologically distinct components, as the neuroendocrine differentiation is only recognized by immunohistochemistry. Such mixed acinar-neuroendocrine carcinomas do not fit the diagnosis of mixed neuroendocrine-non-neuroendocrine neoplasm (MiNEN), and should be regarded as a subtype of ACC. Indeed,

Table III. Histologic and immunohistochemical features helpful in the differential diagnosis of acinar and solid-pseudopapillary neoplasms

Tumor type/subtype	Prominent nucleoli	Architectural patterns	Squamoid nests	Necrosis	Stroma	Acinar cell marker expression	Neuroendocrine marker expression	Important markers for diagnosis
Acinar cell carcinoma	Yes	Acinar, glandular, trabecular, solid	No	Frequent	Fibrous, scarce	Yes	No/focal, >30% in mixed	Bcl10, trypsin
Pancreatoblastoma	Yes	Acinar, trabecular, solid	Yes	Possible	Fibrous, often hypercellular	Yes	Yes, often focal	Bcl10, trypsin; EMA-CK5-P63 (SN)
Pancreatic NET	Rare	Nesting, trabecular, glandular, solid	No	Very rare	Highly vascular, hyalinized	No	Yes, diffuse and strong	Chromogranin, Synaptophysin, Ki67
NEC/large cell	Frequent	Nesting/trabecular, occasional rosettes	No	Frequent	Desmoplastic-type	No	Yes	Synaptophysin, TP53
NEC/small cell	No	Diffuse sheets	No	Frequent	Desmoplastic-type	No	Yes	Synaptophysin, TP53, Rb
Medullary carcinoma	Yes	Solid, syncytial	No	Possible	Lymphocyte-rich	No	No	MMR proteins
Hepatoid carcinoma	Yes	Trabecular, glandular, solid	No	Possible	Scarce, occasionally lymphocyte-rich	No	Rare	Hep-par1, Arginase-1
SPN	No	Solid, pseudopapillary	No	Possible	Fibrovascular, hyalinized	No	No/focal	β -catenin (nuclear), CD10, Progesteron receptor, LEF1, Vimentin, CD200

Abbreviations: NEC: neuroendocrine carcinoma; NET: neuroendocrine tumor; SN: squamoid nests; SPN: solid pseudopapillary neoplasm; MMR: mismatch repair.

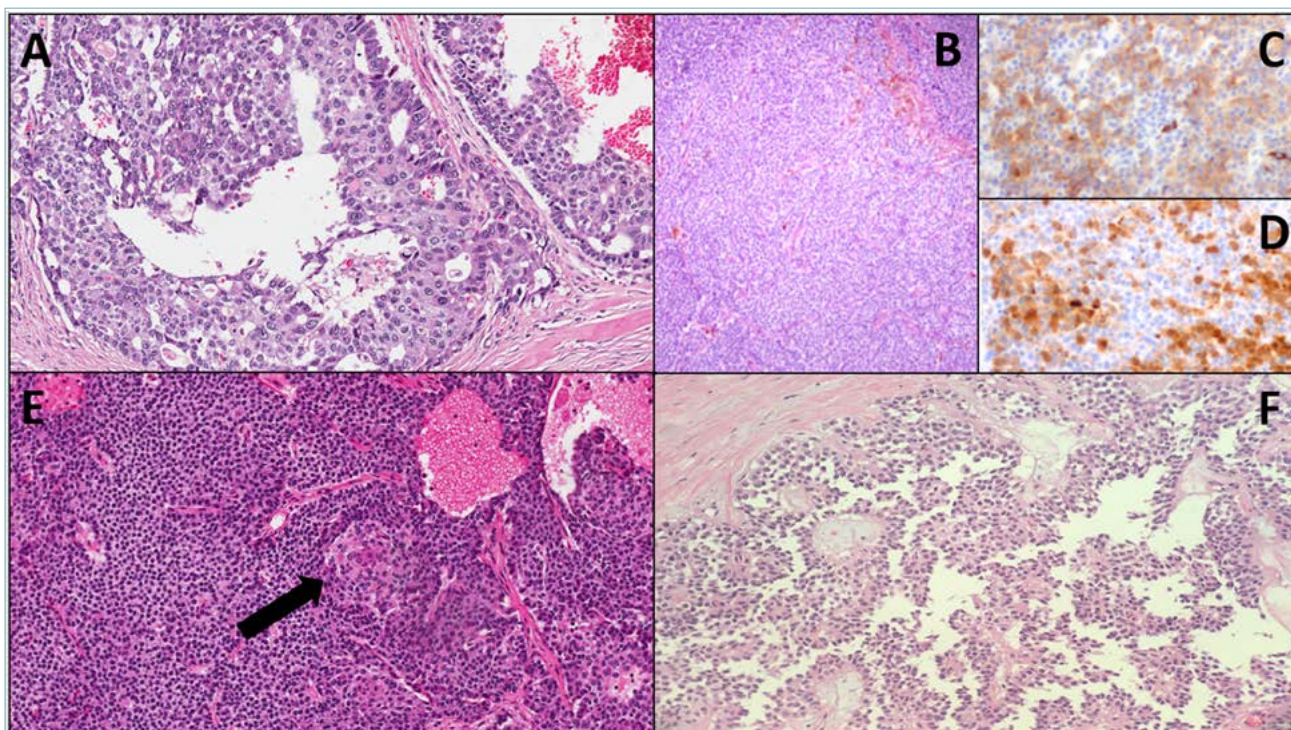


Figure 4. (A) Representative microscopic image of an acinar cell carcinoma, with aspects of intraductal growth (original magnification 20X); (B,C,D) Representative images of a mixed neuroendocrine-acinar neoplasm: B: hematoxylin-eosin staining (original magnification 10X), C: immunohistochemistry for synaptophysin (original magnification 20X), D: immunohistochemistry for trypsin (original magnification 20X); (E) representative histological image of a pancreatoblastoma, including a squamous nest, indicated with a black arrow (original magnification 20X); (F) representative microscopic image of a solid-pseudopapillary neoplasm (original magnification 10X).

their prognosis is similar to conventional ACC⁷². However, rare true pancreatic MiNENs composed of separate acinar and neuroendocrine components have been reported⁷⁶. In such cases, the neuroendocrine component should be graded and reported in the final pathology report.

Mixed acinar-ductal carcinomas have either mucin deposits or a separate component strongly resembling a ductal adenocarcinoma, in addition to an acinar component. Mixed acinar-neuroendocrine-ductal carcinomas have a mixed composite morphology, with an immunohistochemical profile supporting the three lines of differentiation. Mixed acinar-ductal or acinar-neuroendocrine-ductal carcinomas usually have a poor prognosis.

PANCREATOBLASTOMA

Pancreatoblastoma is a rare malignant neoplasm with potential multiple lines of differentiation¹⁶. Acinar cell differentiation is usually prominent. The median patient age at diagnosis is 3-4 years; however, cases in adults have been described. Pancreatoblastoma may be as-

sociated with Beckwith-Wiedemann syndrome and familial adenomatous polyposis syndrome (FAP), type 1.

Grossly, they are usually large, solid tumors, with soft yellowish lobules surrounded by fibrous bands on cut surface. Some cases may have a cystic appearance. Histologically, the neoplasm shows a lobulated architecture, with highly cellular lobules separated by fibrous hypercellular septa. Most tumor cells are morphologically similar to those of ACC and most of them express acinar cell markers. The presence of a variable number of squamoid nests, composed of epithelioid-to-splindle cells showing squamous differentiation, is the histologic hallmark of the neoplasm and is crucial to establish correct diagnosis. A representative histologic image is provided in Figure 4E. Neoplastic cells within squamous nests may show nuclear clearing and abnormal nuclear or cytoplasmic positivity for β -catenin; CD200 may be also positive in the case of nuclear β -catenin staining^{53,77,78}.

Pancreatoblastomas may also express general markers of neuroendocrine differentiation (including CD200)

and AFP. Molecular features of pancreatoblastoma are loss of 11p and alteration in Wnt/ β -catenin pathway⁷⁹. Pancreatoblastomas may have an indolent behavior, but the presence of metastasis and of a non-operable disease represent adverse prognostic factors.

Solid pseudopapillary neoplasms

DEFINITION AND TERMINOLOGY

Solid pseudopapillary neoplasm (SPN) of the pancreas is a low grade malignant epithelial tumor with uncertain cellular differentiation, first described by VK Frantz in 1959⁸⁰. It is a rare neoplasm, representing 0.9-2.7% of all pancreatic exocrine tumors⁸¹; nonetheless, it accounts for 30% of all pancreatic neoplasms in patients younger than 40 years of age⁸². SPNs were previously called “tumors” and considered to be benign or borderline lesions. They are now defined as malignant due to their demonstrated possibility to metastasize^{83,84}.

CLINICAL AND GROSS FEATURES

The vast majority of cases (90%) occur in adolescent girls and in young women (mean age 28 years). Cases involving male patients are very rare and tend to occur 5-10 years later in life with a more aggressive behavior^{85,86}. SPN is often an incidental finding in patients undergoing physical examination or imaging for other indications. Up to two-thirds of cases present with mass symptoms such as abdominal pain, discomfort, dyspepsia, nausea, vomiting or manifestations related to intratumoral hemorrhage. A small but significant percentage of patients present with acute hemoperitoneum⁸³. Tumor markers are generally normal, and there is no known association with genetic or paraneoplastic endocrine syndromes¹⁶. Metastases occur very rarely, mainly in the peritoneum and liver. The diagnosis is confirmed by imaging studies (ultrasound, MRI, CT); SPNs appear as well-demarcated neoplasms with both solid and cystic components. Calcifications are often seen, as well as fluid-debris levels^{87,88}. The long-term prognosis of SPNs after surgical resection is generally excellent.

SPNs may occur anywhere in the pancreas, although a slight preference for the body and tail region has been reported⁸⁹. Direct extension to surrounding organs, such as duodenum, spleen or the portal tract is rare but documented¹⁶. SPNs tend to be solitary and well demarcated lesions, sometimes well-encapsulated, with a mean diameter around 10 cm (range: 0.5-25 cm). On cut sections, they typically show a mixture of solid and cystic areas. Solid areas have a characteristic yellow-light brown color and soft consistency, with

macroscopically visible pseudopapillae; on the other hand, cystic areas are often filled with hemorrhagic and necrotic debris and may show calcification. Smaller lesions tend to be entirely solid, while other lesions may be completely cystic.

MICROSCOPIC DESCRIPTION WITH DIAGNOSTIC HALLMARKS

The microscopic features of SPN recapitulate its macroscopic appearance, with a mixture of solid, pseudopapillary and cystic-hemorrhagic areas. A representative histological image is provided in Figure 4F.

Solid areas are composed of loosely cohesive monomorphic polygonal cells admixed with capillary-sized blood vessels. In pseudopapillary areas, there is partial detachment of the neoplastic cells; the remaining elements are left to surround the blood vessels, therefore forming structures resembling papillae. The neoplastic cells are characterized by eosinophilic cytoplasm and uniform round-oval nuclei with granular chromatin, lacking a prominent nucleolus. Small PAS-Diastase positive hyaline globules are often found within the cytoplasm of the neoplastic cells and contain alpha-1 antitrypsin granules. Mitotic figures are absent or rare. Multinucleated atypical giant cells and nuclear pleomorphism are sometimes present, especially in older patients, and are considered to be degenerative changes rather than signs of malignancy⁹⁰. Foamy macrophages and cholesterol crystals are other common degenerative features typical of SPNs.

Foci of high-grade malignant transformation with high mitotic index may be present, and are associated with an extremely aggressive behavior¹⁶. Despite its well-demarcated macroscopic appearance, SPNs may show infiltrative borders, with tumor cells surrounded by non-neoplastic pancreas without a desmoplastic reaction. The presence of infiltrative borders and capsular invasion are associated with local recurrence⁹¹.

Although true tumor necrosis is rare, infarction is not uncommon, and can involve the lesion almost entirely. Pools of red blood cells, known as “blood lakes”, are typically present at the periphery of the lesion and should be distinguished from vascular invasion if tumor cells are present within them⁸³. The stroma around the neoplastic cells is usually scant and barely visible; when abundant, it may appear myxoid or hyaline. Calcifications are sometimes seen in the capsule. Metastatic lesions tend to have the same morphologic features of the primary tumor; however, a higher degree of pleomorphism and mitotic activity may be present.

IMMUNOHISTOCHEMISTRY AND MOLECULAR PATHOLOGY

Over 90% of SPNs show nuclear/cytoplasmic expression of β -catenin, a finding which is often accompanied by loss of membranous expression of E-cadherin. The combination of these two markers is considered useful in the diagnosis of SPNs⁹². Tumor cells are frequently positive for vimentin, CD56, neuron-specific enolase (NSE), alpha-1 antitrypsin, CD99. CD117 (c-kit) is expressed in up to 50% of cases, in absence of KIT mutations⁹³. Synaptophysin may be focally positive, while chromogranin A, trypsin, CEA and BCL-10 are consistently negative.

The key molecular feature of SPNs is the presence of somatic point mutations in exon 3 of the *CTNNB1* gene, which encodes β -catenin. Such alterations are present in almost all cases and lead to defective phosphorylation and degradation of the β -catenin protein, which accumulates in the cytoplasm and nucleus of the neoplastic cells⁸⁴. Mutated β -catenin loses its function as an adhesion molecule, an event that could probably explain the poor cohesion of neoplastic cells. Recent evidences suggested that SPNs with malignant behavior harbor more often inactivating mutations of epigenetic regulators (*KDM6A*, *TET1*, *BAP1*) associated with metastatic disease⁹⁴.

Mutations in genes typically found in infiltrating ductal adenocarcinoma, such as *KRAS*, *CDKN2A* and *SMAD4* have not been reported in SPNs; less than 5% of cases harbor *TP53* mutations^{83,95,96}.

DIFFERENTIAL DIAGNOSIS

The main differential diagnoses are reported in Table III.

In case of diffuse cystic degeneration, SPNs may be radiologically and macroscopically confused with pancreatic pseudocysts. Clinical findings are important in distinguishing these two entities, since pseudocysts arise more commonly in men with a history of chronic pancreatitis, whereas SPNs typically occur in young women with no history of chronic disease. Microscopically, pseudocysts are characterized by the absence of an epithelial lining and of the classic neoplastic SPN cells.

Another important differential diagnosis for SPNs, above all in the case of solid appearance, is represented by well-differentiated neuroendocrine neoplasms. In this context, after a careful histologic examination, immunohistochemistry may be of great importance for completing this challenging distinction. Although SPNs and neuroendocrine neoplasm may share the positive expression for some markers, such as synaptophysin and CD200⁵⁴, at the same time SPNs have a distinct IHC profile, including the positivity for β -catenin (aberrant nuclear pattern), progesterone-re-

ceptor, CD10, vimentin and are constantly negative for chromogranin A (excluding a well-differentiated neuroendocrine neoplasm) and BCL-10 (excluding an acinar cell carcinoma).

The final pathology report for pancreatic malignant/exocrine tumors

The final pathology report for malignant/exocrine tumors of the pancreas should include some important points to both support the diagnosis and to permit an adequate oncologic staging.

Accordingly to the current TNM staging system, the most important information for resectable PDAC is represented by tumor size and number of metastatic lymph nodes²¹. Furthermore, the status of all resection margins should be reported.

For tumors of pancreatic head, resection margins include: the pancreatic neck margin, the biliary margin, the retroperitoneal margin (posterior lamina) and the intestinal margins (one gastric and one intestinal in the case of Whipple procedure). Lymph nodes should be divided differentiating them into intestinal (duodenal), peri-gastric (Whipple procedure), pancreatic-duodenal (dividing them in anterior and posterior may be helpful, although it is not required by TNM staging system), peri-choloedocic and superior mesenteric artery lymph nodes (in the retroperitoneal margin). Other useful parameters to be reported are represented by vascular invasion, perineural invasion and adipose tissue infiltration. For PDAC, the grading of the tumor and the contemporary presence of dysplastic modifications of non-neoplastic ducts (e.g. PanIN, that supports the pancreatic primitiveness of the tumor) should be reported.

For tumors of the body-tail, the status of pancreatic transection margin must be reported. If tumors invade the anterior/posterior surfaces, this aspect should be mentioned in the final pathology report. Lymph nodes should be divided differentiating them into peri-pancreatic nodes (ideally identifying postero-superior nodes, which are classically located very closely to splenic vessels, and inferior nodes, although this distinction is not taken into account by TNM staging system) and the lymph nodes of splenic hilus. As for tumors affecting the pancreatic head, other useful parameters to be reported are represented by vascular invasion, perineural invasion and adipose tissue infiltration. For PDAC, in addition, grading of the tumor and the contemporary presence of dysplastic modifications of non-neoplastic ducts (e.g. PanIN, that supports the pancreatic primitiveness of the tumor) should be reported.

References

- 1 Brierley JD, Gospodarowicz MK, Wittekind C. *TNM Classification of Malignant Tumours*. Oxford: John Wiley & Sons, 2016 p. 274.
- 2 Neoptolemos JP, Stocken DD, Dunn JA, et al. Influence of resection margins on survival for patients with pancreatic cancer treated by adjuvant chemoradiation and/or chemotherapy in the ESPAC-1 randomized controlled trial. *Ann Surg* 2001;234:758-68. <https://doi.org/10.1097/00000658-200112000-00007>
- 3 Zhang B, Lee G, Qadan M et al. Revision of pancreatic neck margins based on intraoperative frozen section analysis is associated with improved survival in patients undergoing pancreatotomy for ductal adenocarcinoma. *Ann Surg* 2019 Dec 5. <https://doi.org/10.1097/SLA.0000000000003503>. Online ahead of print.
- 4 Lad NL, Squires MH, Maithel SK, et al. Is it time to stop checking frozen section neck margins during pancreaticoduodenectomy?. *Ann Surg Oncol* 2013;20:3626-33. <https://doi.org/10.1245/s10434-013-3080-9>
- 5 Verbeke CS, Leitch D, Menon KV, et al. Redefining the R1 resection in pancreatic cancer. *Br J Surg* 2006;93:1232-7. <https://doi.org/10.1002/bjs.5397>
- 6 Lüttges J, Zamboni G, Klöppel G. Recommendation for the examination of pancreaticoduodenectomy specimens removed from patients with carcinoma of the exocrine pancreas. A proposal for a standardized pathological staging of pancreaticoduodenectomy specimens including a checklist. *Dig Surg* 1999;16:291-6. <https://doi.org/10.1159/000018738>
- 7 Takahashi D, Kojima M, Sugimoto M, et al. Pathologic evaluation of surgical margins in pancreatic cancer specimens using color coding with tissue marking dyes. *Pancreas* 2018;47:830-6. <https://doi.org/10.1097/MPA.0000000000001106>
- 8 Verbeke CS, Gladhaug IP. Dissection of pancreatic resection specimens. *Surg Pathol Clin* 2016;9:523-38. <https://doi.org/10.1016/j.path.2016.05.001>
- 9 Grillo F, Ferro J, Vanoli A, et al. Comparison of pathology sampling protocols for pancreatoduodenectomy specimens. *Virchows Arch* 2020;476:735-44. <https://doi.org/10.1007/s00428-019-02687-6>
- 10 Adsay NV, Basturk O, Saka B, et al. Whipple made simple for surgical pathologists: orientation, dissection, and sampling of pancreaticoduodenectomy specimens for a more practical and accurate evaluation of pancreatic, distal common bile duct, and ampullary tumors. *Am J Surg Pathol* 2014;38:480-93. <https://doi.org/10.1097/PAS.0000000000000165>
- 11 Adsay V, Mino-Kenudson M, Furukawa T, et al. Pathologic evaluation and reporting of intraductal papillary mucinous neoplasms of the pancreas and other tumoral intraepithelial neoplasms of pancreatobiliary tract: recommendations of Verona Consensus Meeting. *Ann Surg* 2016;263:162-77. <https://doi.org/10.1097/SLA.0000000000001173>
- 12 Verbeke C, Löhr M, Karlsson JS, Del Chiaro M. Pathology reporting of pancreatic cancer following neoadjuvant therapy: challenges and uncertainties. *Cancer Treat Rev* 2015;41:17-26. <https://doi.org/10.1016/j.ctrv.2014.11.002>
- 13 Soer E, Brosens L, van de Vijver M, et al. Dilemmas for the pathologist in the oncologic assessment of pancreatoduodenectomy specimens: an overview of different grossing approaches and the relevance of the histopathological characteristics in the oncologic assessment of pancreatoduodenectomy specimens. *Virchows Arch* 2018;472:533-43. <https://doi.org/10.1007/s00428-018-2321-5>
- 14 Campbell F, Smith RA, Whelan P, et al. Classification of R1 resections for pancreatic cancer: the prognostic relevance of tumour involvement within 1 mm of a resection margin. *Histopathology* 2009;55:277-83. <https://doi.org/10.1111/j.1365-2559.2009.03376.x>
- 15 Verbeke C, H überle L, Lenggenhager D, et al. Pathology assessment of pancreatic cancer following neoadjuvant treatment: time to move on. *Pancreatology* 2018;S1424-3903(18)30077-2. <https://doi.org/10.1016/j.pan.2018.04.010>
- 16 WHO Classification of Tumours Editorial Board. *WHO Classification of Tumours*. 5th ed. Lyon: IARC press 2019.
- 17 Luchini C, Pea A, Yu J, et al. Pancreatic cancer arising in the remnant pancreas is not always a relapse of the preceding primary. *Mod Pathol* 2019;32:659-65. <https://doi.org/10.1038/s41379-018-0183-7>
- 18 He J, Ahuja N, Makary MA, et al. 2564 resected periampullary adenocarcinomas at a single institution: trends over three decades. *HPB (Oxford)* 2014;16:83-90. <https://doi.org/10.1111/hpb.12078>
- 19 Amin MB, Edge S, Greene F et al: *AJCC Cancer Staging Manual*. 8th ed. Springer International Publishing 2017.
- 20 Riva G, Pea A, Pilati C, et al. Histo-molecular oncogenesis of pancreatic cancer: From precancerous lesions to invasive ductal adenocarcinoma. *World J Gastrointest Oncol* 2018;10:317-27. <https://doi.org/10.4251/wjgo.v10.i10.317>
- 21 Zamboni G, Hirabayashi K, Castelli P, Lennon AM. Precancerous lesions of the pancreas. *Best Pract Res Clin Gastroenterol* 2013;27:299-322. <https://doi.org/10.1016/j.bpg.2013.04.001>
- 22 Meyers N, Gérard C, Lemaigre FP, Jacquemin P. Differential impact of the ERBB receptors EGFR and ERBB2 on the initiation of precursor lesions of pancreatic ductal adenocarcinoma. *Sci Rep* 2020;10:5241. Published 2020 Mar 23. <https://doi.org/10.1038/s41598-020-62106-8>.
- 23 Bazzichetto C, Conciatori F, Luchini C, et al. From Genetic alterations to tumor microenvironment: The Ariadne's String in Pancreatic Cancer. *Cells* 2020;9:309. Published 2020 Jan 28. <https://doi.org/10.3390/cells9020309>
- 24 Basturk O, Hong SM, Wood LD, et al. A revised classification system and recommendations from the Baltimore Consensus meeting for neoplastic precursor lesions in the pancreas. *Am J Surg Pathol* 2015;39:1730-41. <https://doi.org/10.1097/PAS.0000000000000533>
- 25 Sereni E, Luchini C, Salvia R, et al. Molecular and clinical patterns of local progression in the pancreatic remnant following resection of pancreatic intraductal papillary mucinous neoplasm (IPMN). *Chin Clin Oncol* 2019;8:21. <https://doi.org/10.21037/cco.2019.04.03>
- 26 Pea A, Yu J, Rezaee N, et al. Targeted DNA Sequencing Reveals Patterns of Local Progression in the Pancreatic Remnant Following Resection of Intraductal Papillary Mucinous Neoplasm (IPMN) of the Pancreas. *Ann Surg* 2017;266:133-41. <https://doi.org/10.1097/SLA.0000000000001817>
- 27 Felsenstein M, Noë M, Masica DL, et al. IPMNs with co-occurring invasive cancers: neighbours but not always relatives. *Gut* 2018;67:1652-62. <https://doi.org/10.1136/gutjnl-2017-315062>
- 28 Scarpa A, Real FX, Luchini C. Genetic unrelatedness of co-occurring pancreatic adenocarcinomas and IPMNs challenges current views of clinical management. *Gut* 2018;67:1561-3. <https://doi.org/10.1136/gutjnl-2018-316151>
- 29 Lupinacci RM, Goloudina A, Buhard O, et al. Prevalence of microsatellite instability in intraductal papillary mucinous neoplasms of the pancreas. *Gastroenterology* 2018;154:1061-5. <https://doi.org/10.1053/j.gastro.2017.11.009>
- 30 Luchini C, Capelli P, Scarpa A. Pancreatic ductal adenocarcinoma and its variants. *Surg Pathol Clin* 2016;9:547-60. <https://doi.org/10.1016/j.path.2016.05.003>

- 31 Veronese N, Nottegar A, Pea A, et al. Prognostic impact and implications of extracapsular lymph node involvement in colorectal cancer: a systematic review with meta-analysis. *Ann Oncol* 2016;27:42-8. <https://doi.org/10.1093/annonc/mdv494>
- 32 Veronese N, Fassan M, Wood LD, et al. Extranodal extension of nodal metastases is a poor prognostic indicator in gastric cancer: a systematic review and meta-analysis. *J Gastrointest Surg* 2016;20:1692-8. <https://doi.org/10.1007/s11605-016-3199-7>
- 33 Luchini C, Veronese N, Pea A, et al. Extranodal extension in N1-adenocarcinoma of the pancreas and papilla of Vater: a systematic review and meta-analysis of its prognostic significance. *Eur J Gastroenterol Hepatol* 2016;28:205-9.
- 34 Karamitopoulou E, Wartenberg M, Zlobec I, et al. Tumour budding in pancreatic cancer revisited: validation of the ITBCC scoring system. *Histopathology* 2018;73:137-46.
- 35 Lawlor RT, Veronese N, Nottegar A, et al. Prognostic role of high-grade tumor budding in pancreatic ductal adenocarcinoma: a systematic review and meta-analysis with a focus on epithelial to mesenchymal transition. *Cancers (Basel)* 2019;11:113. Published 2019 Jan 19. <https://doi.org/10.3390/cancers11010113>
- 36 Hong SM, Jung D, Kiemen A, et al. Three-dimensional visualization of cleared human pancreas cancer reveals that sustained epithelial-to-mesenchymal transition is not required for venous invasion. *Mod Pathol* 2020;33:639-47. <https://doi.org/10.1038/s41379-019-0409-3>
- 37 Basturk O, Khanani F, Sarkar F, et al. DeltaNp63 expression in pancreas and pancreatic neoplasia. *Mod Pathol* 2005;18:1193-8. <https://doi.org/10.1038/modpathol.3800401>
- 38 Liu C, Karam R, Zhou Y, et al. The UPF1 RNA surveillance gene is commonly mutated in pancreatic adenosquamous carcinoma. *Nat Med* 2014;20:596-8. <https://doi.org/10.1038/nm.3548>
- 39 Boecker J, Feyerabend B, Tiemann K, et al. Adenosquamous carcinoma of the pancreas comprise a heterogeneous group of tumors with the worst outcome: a clinicopathological analysis of 25 cases identified in 562 pancreatic carcinomas resected with curative intent. *Pancreas* 2020;49:683-91. <https://doi.org/10.1097/MPA.0000000000001548>
- 40 Amato E, Molin MD, Mafficini A, et al. Targeted next-generation sequencing of cancer genes dissects the molecular profiles of intraductal papillary neoplasms of the pancreas. *J Pathol* 2014;233:217-27. <https://doi.org/10.1002/path.4344>
- 41 Luchini C, Brosens LAA, Wood LD, et al. Comprehensive characterisation of pancreatic ductal adenocarcinoma with microsatellite instability: histology, molecular pathology and clinical implications [published online ahead of print, 2020 Apr 29]. *Gut* 2020;gutjnl-2020-320726. <https://doi.org/10.1136/gutjnl-2020-320726>
- 42 Luchini C, Bibeau F, Ligtenberg MJL, et al. ESMO recommendations on microsatellite instability testing for immunotherapy in cancer, and its relationship with PD-1/PD-L1 expression and tumour mutational burden: a systematic review-based approach. *Ann Oncol* 2019;30:1232-43. <https://doi.org/10.1093/annonc/mdz116>
- 43 Wilentz RE, Goggins M, Redston M, et al. Genetic, immunohistochemical, and clinical features of medullary carcinoma of the pancreas: A newly described and characterized entity. *Am J Pathol* 2000;156:1641-51. [https://doi.org/10.1016/S0002-9440\(10\)65035-3](https://doi.org/10.1016/S0002-9440(10)65035-3)
- 44 Kryklyva V, ter Linden E, Kroeze LI et al. Medullary pancreatic carcinoma due to somatic POLE mutation: a distinctive pancreatic carcinoma with marked long-term survival. *Pancreas* 2020;49:999-1003. <https://doi.org/10.1097/MPA.0000000000001588>
- 45 Agaimy A, Haller F, Frohnauer J, et al. Pancreatic undifferentiated rhabdoid carcinoma: KRAS alterations and SMARCB1 expression status define two subtypes. *Mod Pathol* 2015;28:248-60. <https://doi.org/10.1038/modpathol.2014.100>
- 46 Ishida K, Yamashita R, Osakabe M, et al. Expression of epithelial-mesenchymal transition proteins in pancreatic anaplastic (undifferentiated) carcinoma. *Pancreas* 2019;48:36-42. <https://doi.org/10.1097/MPA.0000000000001199>
- 47 Mattiolo P, Fiadone G, Paolino G et al. Epithelial-mesenchymal transition in undifferentiated carcinoma of the pancreas with and without osteoclast-like giant cells. *Virchows Arch* 2020 Jul 13. <https://doi.org/10.1007/s00428-020-02889-3>. Online ahead of print.
- 48 Muraki T, Reid MD, Basturk O, et al. Undifferentiated carcinoma with osteoclastic giant cells of the pancreas: clinicopathologic analysis of 38 cases highlights a more protracted clinical course than currently appreciated. *Am J Surg Pathol* 2016;40:1203-16. <https://doi.org/10.1097/PAS.0000000000000689>
- 49 Luchini C, Pea A, Lionheart G, et al. Pancreatic undifferentiated carcinoma with osteoclast-like giant cells is genetically similar to, but clinically distinct from, conventional ductal adenocarcinoma. *J Pathol* 2017;243:148-54. <https://doi.org/10.1002/path.4941>
- 50 Luchini C, Cros J, Pea A, et al. PD-1, PD-L1, and CD163 in pancreatic undifferentiated carcinoma with osteoclast-like giant cells: expression patterns and clinical implications. *Hum Pathol* 2018;81:157-65. <https://doi.org/10.1016/j.humpath.2018.07.006>
- 51 Moll R, Löwe A, Laufer J, Franke WW. Cytokeratin 20 in human carcinomas. A new histodiagnostic marker detected by monoclonal antibodies. *Am J Pathol* 1992;140:427-47.
- 52 Nagata K, Horinouchi M, Saitou M, et al. Mucin expression profile in pancreatic cancer and the precursor lesions. *J Hepatobiliary Pancreat Surg* 2007;14:243-54. <https://doi.org/10.1007/s00534-006-1169-2>
- 53 Terada T, Ohta T, Sasaki M, et al. Expression of muc apomucins in normal pancreas and pancreatic tumours. *J Pathol* 1996;180:160-5.
- 54 Lawlor RT, Daprà V, Girolami I, et al. CD200 expression is a feature of solid pseudopapillary neoplasms of the pancreas. *Virchows Arch* 2019;474:105-9. <https://doi.org/10.1007/s00428-018-2437-7>
- 55 Xu JZ, Wang WQ, Zhang WH, et al. The Loss of SMAD4/DPC4 expression associated with a strongly activated hedgehog signaling pathway predicts poor prognosis in resected pancreatic cancer. *J Cancer* 2019;10:4123-31. Published 2019 Jul 10. <https://doi.org/10.7150/jca.30883>
- 56 Waddell N, Pajic M, Patch AM, et al. Whole genomes redefine the mutational landscape of pancreatic cancer. *Nature* 2015;518(7540):495-501. <https://doi.org/10.1038/nature14169>
- 57 Bailey P, Chang DK, Nones K, et al. Genomic analyses identify molecular subtypes of pancreatic cancer. *Nature* 2016;531(7592):47-52. <https://doi.org/10.1038/nature16965>
- 58 Almoguera C, Shibata D, Forrester K, et al. Most human carcinomas of the exocrine pancreas contain mutant c-K-ras genes. *Cell* 1988;53:549-54. [https://doi.org/10.1016/0092-8674\(88\)90571-5](https://doi.org/10.1016/0092-8674(88)90571-5)
- 59 Singhi AD, George B, Greenbowe JR, et al. Real-time targeted genome profile analysis of pancreatic ductal adenocarcinomas identifies genetic alterations that might be targeted with existing drugs or used as biomarkers. *Gastroenterology* 2019;156:2242-53.e4. <https://doi.org/10.1053/j.gastro.2019.02.037>
- 60 Adsay NV, Bandyopadhyay S, Basturk O, et al. Chronic pancreatitis or pancreatic ductal adenocarcinoma?. *Semin Diagn Pathol* 2004;21:268-76. <https://doi.org/10.1053/j.semmp.2005.08.002>
- 61 Zhang L, Chari S, Smyrk TC, et al. Autoimmune pancreatitis

- (AIP) type 1 and type 2: an international consensus study on histopathologic diagnostic criteria. *Pancreas* 2011;40:1172-9. <https://doi.org/10.1097/MPA.0b013e318233bec5>
- ⁶² Zamboni G, Lüttges J, Capelli P, et al. Histopathological features of diagnostic and clinical relevance in autoimmune pancreatitis: a study on 53 resection specimens and 9 biopsy specimens. *Virchows Arch* 2004;445:552-63. <https://doi.org/10.1007/s00428-004-1140-z>
- ⁶³ De Marchi G, Paiella S, Luchini C, et al. Very high serum levels of CA 19-9 in autoimmune pancreatitis: Report of four cases and brief review of literature. *J Dig Dis* 2016;17:697-702. <https://doi.org/10.1111/1751-2980.12403>
- ⁶⁴ Detlefsen S, Zamboni G, Frulloni L, et al. Clinical features and relapse rates after surgery in type 1 autoimmune pancreatitis differ from type 2: a study of 114 surgically treated European patients. *Pancreatol* 2012;12:276-83. <https://doi.org/10.1016/j.pan.2012.03.055>
- ⁶⁵ Zhang L, Smyrk TC. Autoimmune pancreatitis and IgG4-related systemic diseases. *Int J Clin Exp Pathol* 2010;3:491-504. Published 2010 May 25.
- ⁶⁶ Zhang L, Notohara K, Levy MJ, et al. IgG4-positive plasma cell infiltration in the diagnosis of autoimmune pancreatitis. *Mod Pathol* 2007;20:23-8. <https://doi.org/10.1038/modpathol.3800689>
- ⁶⁷ Esposito I, Hruban RH, Verbeke C, et al. Guidelines on the histopathology of chronic pancreatitis. Recommendations from the working group for the international consensus guidelines for chronic pancreatitis in collaboration with the International Association of Pancreatology, the American Pancreatic Association, the Japan Pancreas Society, and the European Pancreatic Club. *Pancreatol* 2020;20:586-93. <https://doi.org/10.1016/j.pan.2020.04.009>
- ⁶⁸ Yemelyanova A, Vang R, Kshirsagar M, et al. Immunohistochemical staining patterns of p53 can serve as a surrogate marker for TP53 mutations in ovarian carcinoma: an immunohistochemical and nucleotide sequencing analysis. *Mod Pathol* 2011;24:1248-53. <https://doi.org/10.1038/modpathol.2011.85>
- ⁶⁹ Ritterhouse LL, Wu EY, Kim WG, et al. Loss of SMAD4 protein expression in gastrointestinal and extra-gastrointestinal carcinomas. *Histopathology* 2019;75:546-51. <https://doi.org/10.1111/his.13894>
- ⁷⁰ Klimstra DS, Adsay V. Acinar neoplasms of the pancreas-A summary of 25 years of research. *Semin Diagn Pathol* 2016;33:307-18. <https://doi.org/10.1053/j.semdp.2016.05.009>
- ⁷¹ Klimstra DS, Heffess CS, Oertel JE, et al. Acinar cell carcinoma of the pancreas. A clinicopathologic study of 28 cases. *Am J Surg Pathol* 1992;16:815-37. <https://doi.org/10.1097/00000478-199209000-00001>
- ⁷² La Rosa S, Adsay V, Albarello L, et al. Clinicopathologic study of 62 acinar cell carcinomas of the pancreas: insights into the morphology and immunophenotype and search for prognostic markers. *Am J Surg Pathol* 2012;36:1782-95. <https://doi.org/10.1097/PAS.0b013e318263209d>
- ⁷³ La Rosa S, Sessa F, Capella C. Acinar cell carcinoma of the pancreas: overview of clinicopathologic features and insights into the molecular pathology. *Front Med (Lausanne)* 2015;2:41. Published 2015 Jun 15. <https://doi.org/10.3389/fmed.2015.00041>
- ⁷⁴ Furlan D, Sahnane N, Bernasconi B, et al. APC alterations are frequently involved in the pathogenesis of acinar cell carcinoma of the pancreas, mainly through gene loss and promoter hypermethylation. *Virchows Arch* 2014;464:553-64. <https://doi.org/10.1007/s00428-014-1562-1>
- ⁷⁵ Chmielecki J, Hutchinson KE, Frampton GM, et al. Comprehensive genomic profiling of pancreatic acinar cell carcinomas identifies recurrent RAF fusions and frequent inactivation of DNA repair genes. [published correction appears in *Cancer Discov* 2015 Mar;5(3):332]. *Cancer Discov* 2014;4:1398-1405. <https://doi.org/10.1158/2159-8290.CD-14-0617>
- ⁷⁶ Klimstra DS, Rosai J, Heffess CS. Mixed acinar-endocrine carcinomas of the pancreas. *Am J Surg Pathol* 1994;18:765-78. <https://doi.org/10.1097/00000478-199408000-00002>
- ⁷⁷ Ohike N, Morohoshi T. Exocrine pancreatic neoplasms of non-ductal origin: acinar cell carcinoma, pancreatoblastoma, and solid-pseudopapillary neoplasm. *Surg Pathol Clin* 2011;4:579-88. <https://doi.org/10.1016/j.path.2011.03.001>
- ⁷⁸ Tanaka Y, Kato K, Notohara K, et al. Significance of aberrant (cytoplasmic/nuclear) expression of beta-catenin in pancreatoblastoma. *J Pathol* 2003;199:185-90. <https://doi.org/10.1002/path.1262>
- ⁷⁹ Wood LD, Klimstra DS. Pathology and genetics of pancreatic neoplasms with acinar differentiation. *Semin Diagn Pathol* 2014;31:491-7. <https://doi.org/10.1053/j.semdp.2014.08.003>
- ⁸⁰ Kneeland Frantz V. Atlas of tumor pathology, Section VII, Fascicles 27 and 28. Tumors of the Pancreas. Washington, D.C.: Armed Forces Institute of Pathology 1959.
- ⁸¹ Kosmahl M, Pauser U, Peters K, et al. Cystic neoplasms of the pancreas and tumor-like lesions with cystic features: a review of 418 cases and a classification proposal. *Virchows Arch* 2004;445:168-78. <https://doi.org/10.1007/s00428-004-1043-z>
- ⁸² Konukiewitz B, Enosawa T, Klöppel G. Glucagon expression in cystic pancreatic neuroendocrine neoplasms: an immunohistochemical analysis. *Virchows Arch* 2011;458:47-53. <https://doi.org/10.1007/s00428-010-0985-6>
- ⁸³ Hruban RH, Pitman MB, Klimstra DS. Tumors of the pancreas. American Registry of Pathology in collaboration with the Armed Forces Institute of Pathology 2007.
- ⁸⁴ Abraham SC, Klimstra DS, Wilentz RE, et al. Solid-pseudopapillary tumors of the pancreas are genetically distinct from pancreatic ductal adenocarcinomas and almost always harbor beta-catenin mutations. *Am J Pathol* 2002;160:1361-9. [https://doi.org/10.1016/s0002-9440\(10\)62563-1](https://doi.org/10.1016/s0002-9440(10)62563-1)
- ⁸⁵ Machado MC, Machado MA, Bacchella T, et al. Solid pseudopapillary neoplasm of the pancreas: distinct patterns of onset, diagnosis, and prognosis for male versus female patients. *Surgery* 2008;143:29-34. <https://doi.org/10.1016/j.surg.2007.07.030>
- ⁸⁶ Klöppel G, Morohoshi T, John HD, et al. Solid and cystic acinar cell tumour of the pancreas. A tumour in young women with favourable prognosis. *Virchows Arch A Pathol Anat Histol* 1981;392:171-83.
- ⁸⁷ Dong PR, Lu DS, Degregario F, et al. Solid and papillary neoplasm of the pancreas: radiological-pathological study of five cases and review of the literature. *Clin Radiol* 1996;51(10):702-5. [https://doi.org/10.1016/s0009-9260\(96\)80242-x](https://doi.org/10.1016/s0009-9260(96)80242-x)
- ⁸⁸ Buetow PC, Buck JL, Pantongrag-Brown L, et al. Solid and papillary epithelial neoplasm of the pancreas: imaging-pathologic correlation on 56 cases. *Radiology* 1996;199:707-11. <https://doi.org/10.1148/radiology.199.3.8637992>
- ⁸⁹ Kang CM, Choi SH, Kim SC, et al. Predicting recurrence of pancreatic solid pseudopapillary tumors after surgical resection: a multicenter analysis in Korea. *Ann Surg*. 2014;260:348-55. <https://doi.org/10.1097/SLA.0000000000000583>
- ⁹⁰ Kim SA, Kim MS, Kim MS, et al. Pleomorphic solid pseudopapillary neoplasm of the pancreas: degenerative change rather than high-grade malignant potential. *Hum Pathol* 2014;45:166-74. <https://doi.org/10.1016/j.humpath.2013.08.016>
- ⁹¹ Marchegiani G, Andrianello S, Massignani M, et al. Solid pseudopapillary tumors of the pancreas: Specific pathological fea-

- tures predict the likelihood of postoperative recurrence. *J Surg Oncol* 2016;114:597-601. <https://doi.org/10.1002/jso.24380>
- ⁹² Kim MJ, Jang SJ, Yu E. Loss of E-cadherin and cytoplasmic-nuclear expression of beta-catenin are the most useful immunoprofiles in the diagnosis of solid-pseudopapillary neoplasm of the pancreas. *Hum Pathol* 2008;39:251-8. <https://doi.org/10.1016/j.humpath.2007.06.014>
- ⁹³ Cao D, Antonescu C, Wong G, et al. Positive immunohistochemical staining of KIT in solid-pseudopapillary neoplasms of the pancreas is not associated with KIT/PDGFR mutations. *Mod Pathol* 2006;19:1157-63. <https://doi.org/10.1038/modpathol.3800647>
- ⁹⁴ Amato E, Mafficini A, Hirabayashi K, et al. Molecular alterations associated with metastases of solid pseudopapillary neoplasms of the pancreas. *J Pathol* 2019;247:123-34. <https://doi.org/10.1002/path.5180>
- ⁹⁵ Bartsch D, Bastian D, Barth P, et al. K-ras oncogene mutations indicate malignancy in cystic tumors of the pancreas. *Ann Surg* 1998;228:79-86. <https://doi.org/10.1097/00006658-199807000-00012>
- ⁹⁶ Fléjou JF, Boulange B, Bernades P, et al. p53 protein expression and DNA ploidy in cystic tumors of the pancreas. *Pancreas* 1996;13:247-52. <https://doi.org/10.1097/00006676-199610000-00006>