

RADIOGRAPHIC DENTAL IMPLANTS RECOGNITION FOR GEOGRAPHIC EVALUATION IN HUMAN IDENTIFICATION

E. Nuzzolese, S. Lusito, B. Solarino, G. Di Vella

Sezione di Medicina Legale, Università degli Studi di Bari, Italy

ABSTRACT

Dental implants for prosthetic rehabilitation with fixed crown or mobile partial/total dentures is a very common oral treatment among the population in Italy as elsewhere. There is a great number of implant systems of different designs. However, a catalogue of radiographic images and a description of the dental implants available in Italy would be useful in order to identify the manufacturer and the type of implant encountered in forensic casework. When an unidentified body is found with one or more implants in the jaws, and no dental record is available, clues gleaned from the type of implants used could give direction to the investigation.

In this study Italian implant manufactures were contacted and asked to provide specimen implants. Digital radiographs were taken of all the implants donated at 0°, 30°, and 60° horizontal rotation, combined with -20°, -10°, 0°, +10°, and +20° vertical inclination relative to the radiographic beam and the X-ray sensor. A total of 15 images per implant were taken and examined to identify consistent, unique features that would aid in implant recognition. Only those observations made from radiographs between -10° and +10° vertical inclination would ever be used for definite identification of any implant.

The information from this study should be considered a survey of the commercial distribution of dental implants in Italy through their digital radiographic images. It is also a starting point for a wider geographical evaluation of different manufacturers in other countries and continents. The radiographic images provided should help both the forensic odontologist and the prosthodontist to identify pre-existing implants which they may discover from their radiographic images.

(J Forensic Odontostomatol 2008;27:1:8-11)

Keywords: dental implants, forensic odontology, human identification, dental records

INTRODUCTION

Dental prosthetic rehabilitation with oral implantology has become a very common treatment choice among the Italian population, as in the rest of the world. It is a direct consequence of modern dentistry to promote dental implants, as surgical technique and results have become more predictable and costs have been reduced, making

this treatment generally affordable to every patient. Dental implants can be juxtaosseous or endosseous. The type of dental implants accepted by the scientific dental community are endosseous titanium screws or cylinders, with a rough surface, etched or titanium plasma sprayed. A great number of implant systems with different designs have been manufactured. Some of them are leading worldwide manufacturers and thus are distributed in many countries. Nevertheless, increasing demand from the domestic dental market has seen many national implant system manufacturers responding to international competition, and developing systems of their own. In this regard Italian dental implant manufacturers have a unique design and generally have a national distribution. For this reason we believe a creation of an Italian radiographic dental images' catalogue would assist the human forensic identification process allowing manufacturer recognition and a geographical evaluation.

Identification of human remains is accomplished by fingerprint, dental, anthropological, genetic and radiological examination. Human bones and teeth survive both natural and unnatural processes and therefore can nearly always be examined radiographically¹. In 1992 Sewerin² first described and analyzed radiographic images of ten dental implants from different viewing angles. The aim of the study was to identify implants previously inserted by other dental surgeons to help the clinician in their prosthetic final work. Increased patient mobility, and the large number of implants systems with different designs, has determined the need for a radiographic catalogue of dental implant images.^{3,4} Unfortunately, it is rather difficult to keep up with the continuous development of new implants. The identification of old and new dental implants can become a problem for the dentist treating a patient with no dental records available and also for the forensic odontologist while attempting the identification of an unknown cadaver.⁵ Forensic dental identification is based on the morphological comparison and matching of dental records, mainly available as radiographic images.^{6,7} Postmortem dental records are compared with ante-mortem records pertaining to some

presumed identity.⁷ However, if no previous papers are found identification may be difficult. Morphological features of dental implants depicted on radiographs may be used to develop a dental profile of the individual and provide information that can narrow the search to a smaller number of individuals, or eliminate certain candidates by taking into account the dental system employed.⁸⁻¹⁰ The matching of two sets of radiographs is performed with post mortem periapical X-ray of the implants against the dental implants' images of the various implant systems stored in the archive. Some implant systems have peculiar characteristics making recognition easy, but others which share very similar characteristics, require the analysis of fine structures¹¹.

The aim of this study is to create an archive of radiographic images of Italian dental implants to be employed in forensic caseworks to narrow the investigation of unidentified victims with one or more dental implants. Investigators should be able to identify the type of implant by comparing radiographic images, thus narrowing the search.

This archive would represent a starting point for a wider dental implant archive and geographical evaluation in other countries.

MATERIALS AND METHODS

In this study Italian implant manufactures, advertised in professional national journals, were contacted and asked to provide specimen implants of various diameter, but all as close as possible to 10 mm in length. At present 10 Italian manufacturers (Sweden & Martina, Micerium, Endoimplant, Geass, Primary Healing Implant PHI, Life Support Systems LSS, Leone, Leader Italia, Krugg, IdiEvolution) have replied and sent multiple implants of various design. A device was fabricated to make standardized radiographs at different vertical inclinations and horizontal rotations. This range of angles is meant to mimic clinical situations as implants are inserted in the jaws by the dental surgeon with various angulations and thus determine a different radiographic image. Digital radiographs were taken of all the implants donated at 0°, 30°, and 60° of horizontal rotation combined with -20°, -10°, 0°, +10° and +20° vertical inclination relative to the radiographic beam and the X-ray sensor. A total of 9 images per implant were taken and catalogued. All radiographs were made in the same sequence, starting at 0° horizontal rotation and 0° vertical inclination. Thereafter, the inclination remained constant and the rotation was changed to 30° and 60°. The vertical inclination was then changed to +10° (10° toward the cone) and -10°. In

fact we decided that only those observations made from radiographs between -10° and +10° vertical inclination would ever be used for definite identification of any implant. The digital image obtained was in TIFF format and was named with the position parameters, and then all pictures of the implant were inserted in a folder named with the manufacturer and the type of implant. Observations were also recorded on a data collection sheet to verify the correct sequence and avoid mislabeling of the image file.

All radiographs were made with a Trophy X-Ray appliance and Trophy Radiovideography sensor connected to a computer, using 0,02 seconds exposure time and 68 Kv.

RESULTS

Digital images in TIFF format were compiled for inclination from -10° to +10° and for 0°, 30° and 60° of rotation. An archive of 9 images per implant type was stored together with the implant system name (Figs.1 and 2). The images archive has been duplicated also into JPG format and saved in a cd available to forensic odontologists upon request. As the archive is composed of several hundred radiographic images, only four examples were chosen.

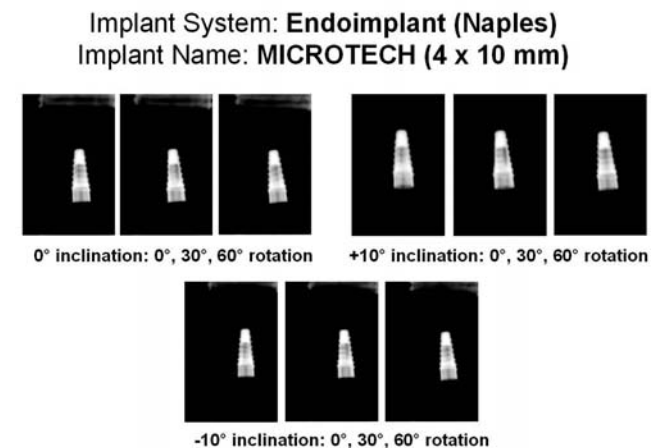


Fig.1: Examples of the nine images archived per each implant stored in the database together with the implant system name.

DISCUSSION

Knowledge of implant designs and implantology is fundamental for the radiographic recognition of the implant system. Familiarity with implant design not only helps with radiographic identification but also may be an asset in radiological procedures and techniques. During the post mortem implant radiography the positioning of the X-ray device and

sensor has to reproduce the geometry of the implant design most adaptable to the comparison against our implants X-ray images' archive¹². This has also to take into account the muscular rigor mortis. For this reason it is important, in a real identification case, to get as many different X-ray projections so that a clear geometrical implant image is obtained but also certain implant details are revealed.




Fig. 2: Examples of the nine images archived per each implant stored in the database together with the implant system name.

Some implants have perforations, grooves, apical chambers, and threads which are visible only at certain rotation or angulations (Fig.3). These features may be unique and enable recognition of specific products. Some other features may confuse the interpretation of an implant which is a clone of another more diffused large international implant company. Yet the present is intended to create only a radiographic images database, with no design description, of dental implants manufactured in Italy

Due to the great number of implant systems available on the market and to the continuous development of new dental implants, designs, we cannot consider our archive to be complete. For this reason the collection of Italian dental implants has to be considered as ongoing research. An update of the archive will be available every 12 months with newly designed implants or implant systems not included in the present study.

For the purpose of this work and the necessity of data transmitting, the use of digital X-ray is necessary and cannot be substituted by traditional X-ray processing.

Implant System: **Geass (Udine)**
Implant Name: **ERGONE (4 x 11 mm)**

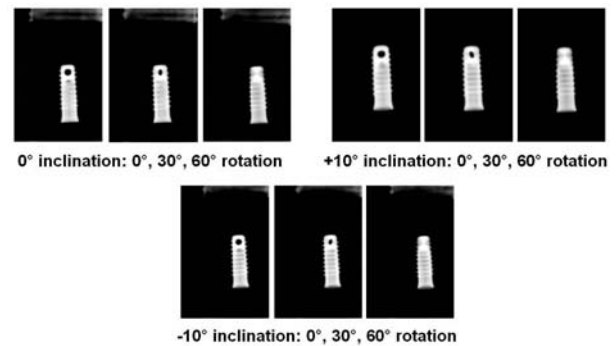


Fig. 3: Example of dental implant with apical perforation visible only at certain rotation.

CONCLUSION

The information from this study should be considered a survey of the commercial distribution of dental implants in Italy through their digital radiographic images. It should help both the forensic odontologist and the prosthodontist to identify pre-existing implants which may be discovered from their radiographic images.

In the human identification process of unknown victims with no dental records available, the recognition of dental implants detected may give auxiliary information to narrow the search to a smaller number of individuals or eliminate certain candidates altogether. In performing the forensic evaluation and superimposition, forensic odontologists must be familiar with implant designs and implant therapy.

In order to cover as many as possible of the implant systems available in Italy our research should be considered a work in progress, and the archive has still to be enlarged. A worldwide radiographic implant image database, including similar "cloned" implants, is needed for a wider geographical evaluation of the different manufacturers in other countries.

DISCLOSURE

The authors highlight they have no commercial benefits or interests with dental implants' manufacturers employed in this work.

ACKNOWLEDGEMENTS

The donation of all implants by their respective manufacturers (Sweden & Martina, Micerium, Endoimplant, Geass, Primary Healing Implant PHI, Life Support Systems LSS, Leone, Leader Italia,

Krugg, IdiEvolution) is acknowledged and appreciated.

We would like to thank Professor John G. Clement, Inaugural Chair in Forensic Odontology, University of Melbourne, Director, Centre for Human Identification, Victorian Institute of Forensic Medicine, for his support towards our research projects.

Address for correspondence:

Emilio Nuzzolese, DDS, PhD
Forensic Odontologist
Viale J.F. Kennedy 77
I-70124 Bar - Italy
 E-mail: emilionu@tin.it

REFERENCES

1. Kahana T, Hiss J. Identification of human remains: forensic radiology. *J Clin Foren Med* 1997;4:7-15.
2. Sewerin I. Identification of dental implants on radiographs. *Quintessence Int* 1992;23:611-8.
3. Sahiwal IG, Woody RD, Benson BW, Guillen GE. Radiographic identification of threaded endosseous dental implants. *J Prosthet Dent* 2002;87:563-77.
4. Sahiwal IG, Woody RD, Benson BW, Guillen GE. Radiographic identification of nonthreaded endosseous dental implants. *J Prosthet Dent* 2002 May;87:552-62.
5. Sahiwal IG, Woody RD, Benson BW, Guillen GE. Macro design morphology of endosseous dental implants. *J Prosthet Dent* 2002;87:543-51.
6. Tai CC, Blenkinsop BR, Wood RE. Dental radiographic identification utilizing computerized digital slice interposition: a case report. *J Forensic Odontostomatol* 1993;11:22-30.
7. Jain AK, Chen H. Matching of dental X-ray for human identification. *Pattern Recognition* 2004;37:1519-32.
8. Pretty IA, Addy LD. Associated post-mortem dental findings as an aid to personal identification. *Sci Justice* 2002;42:65-74.
9. Bell GL. Dentistry's role in the resolution of missing and unidentified persons cases. *Dent Clin North Am* 2001;45: 293-308.
10. Zhou J, Abdel-Mottaied M. A content-based system for human identification based on bitewing dental X-ray images. *Pattern Recognition* 2005;2132-42.
11. Sainio P, Syrjanen SM, Komakow S. Positive identification of victims by comparison of ante-mortem and post-mortem dental radiographs. *J Forensic Odontostomatol* 1990; 8: 11-6.
12. Georget G, Fronty P, Sapanet M. L'identification comparative. *Fontaine Imprimeur - Poitier* 2001;55-9.
13. Gruber J, Kameyama MM. Role of radiology in forensic dentistry. *Pesqui Odontol Bras* 2001;15: 263-8.