

# Thymosin beta-4 prenatal administration improves fetal development and halts side effects due to preterm delivery

G. FAA<sup>1,7</sup>, M. PIRAS<sup>1</sup>, L. MANCUSO<sup>2</sup>, P. CONI<sup>1</sup>, G. PICHIRI<sup>1</sup>, G. ORRÙ<sup>3</sup>,  
D. FANNI<sup>1</sup>, C. GEROSA<sup>1</sup>, G. CAO<sup>2</sup>, R. TAIBI<sup>4</sup>, P. PAVONE<sup>5</sup>, M. CASTAGNOLA<sup>6</sup>

<sup>1</sup>Department of Medical Sciences and Public Health, Division Pathological Anatomy, Cagliari, Italy

<sup>2</sup>Department of Mechanical Energy, Chemistry And Materials, University of Cagliari, Cagliari, Italy

<sup>3</sup>Department of Surgical Sciences, Molecular Biology Service (MBS), University of Cagliari, Cagliari, Italy

<sup>4</sup>Department of Medical Oncology, Istituto Nazionale Tumori, Centro di Riferimento Oncologico-CRO, IRCCS, Aviano (PN), Italy

<sup>5</sup>Section of Pediatrics and Child Neuropsychiatry, Department of Clinical and Experimental Sciences, University of Catania, Catania, Italy

<sup>6</sup>Proteomics and Metabolomics Laboratory-IRCCS Foundation Santa Lucia, Rome, Italy

<sup>7</sup>Adjunct Professor Department of Biology, College of Science and Technology, Temple University, Philadelphia, PA, USA

**Abstract.** – **OBJECTIVE:** Thymosin beta 4 (TB4) is the most abundant member of the beta-thymosin family in humans. The main physiological role of TB4 is the regulation of actin polymerization. TB4 is also involved in angiogenesis, cell survival, cell migration and fetal development. The aim of this study was to evaluate the activity of TB4 as a fetal growth promoter when administered during pregnancy.

**MATERIALS AND METHODS:** Our protocols have been carried out in full conformity with the rules and guidelines expected for this kind of trial. 10 pregnant mice received the same injection regimen. Only 6 of these 10 are part of this experiment because they were pregnant. At 10:00 a.m. on day E14 and E17 of gestation mice were weighed and treated with an intraperitoneal injection of TB4 (Regene RX, Rockville, MD, USA; 6 mg/kg in PBS).

**RESULTS:** The mothers treated with TB4 for two days precisely E14 and E17, showed a higher cranio-caudal length when compared to control newborns. At histology, maternal TB4 treatment was associated with more advanced development of lungs, heart, kidney, cerebral cortex and notochord.

**CONCLUSIONS:** Our study shows that TB4 administration during gestation may act as a powerful fetal growth promoter, by accelerating the development of newborn organs and tissues.

*Key Words:*

ThymosinBeta-4, Fetal development, Growth promoter.

## Introduction

Thymosin beta-4 (TB4) is an endogenous peptide with protective and regenerative effects in models of cellular and organ injury<sup>1</sup>. In earlier attempts to define the role of Beta-thymosins in human development, our team evidenced the high values of TB4 in the saliva crevicular fluid of human newborn<sup>2</sup>. Further immunohistochemical studies, carried out on human fetal salivary glands, revealed the high expression of TB4 during gestation and a switch of secretion in the late phases of gestation<sup>3</sup>. Studies on TB4 expression in fetal tissues, disclosed a major role for TB4 in fetal development: high levels of TB4 were found in the developing gut<sup>4,5</sup>, in the fetal skin<sup>6</sup>, in the developing kidney<sup>7</sup> and in fetal salivary glands<sup>8</sup>. Moreover, TB4 expression was found to be downregulated in different tissues and in saliva after birth<sup>8</sup>. On the contrary, TB4 expression appeared upregulated in tumor cells<sup>9</sup>. In particular, high levels of TB4 were detected in intestinal adenomas<sup>10</sup>, in colon cancer<sup>11</sup> and in hepatocellular carcinoma<sup>12</sup>. TB4 has been evaluated in recent years for its clinical potential for wound healing, including corneal wounds<sup>13</sup>, brain healing following stroke or neurological diseases, and repair of spinal cord<sup>14</sup>. TB4 is also involved in the activation of stem-progenitor cells, being able to induce adult

epicardial progenitor cells in mice, priming silent progenitors and inducing them to differentiate into vascular precursors for neovascularization<sup>15</sup>. Since those early studies, TB4 research has made vast leaps in progress, and TB4 has emerged as having a possible significant clinical potential. Clinical applications for TB4 include kidney and liver diseases, bone and ligament damage, viral infections and halting of aging<sup>3-5,7-9,16</sup>. In light of these results the target of our work was to evaluate the ability of TB4, when given to pregnant mice, to improve the development of fetal organs and tissues.

## Materials and Methods

Ten CD1 adult nulliparous female mice, 2-5 months old were maintained with ten males in standard polycarbonate cages in windowless rooms, on a 12 h light (7.00 to 19.00 h) and dark cycle and controlled temperature (22°± 2°C), for 3 days. At the end of this period, the females were checked for the presence of vaginal plugs. Plug's day corresponds to E0.5. All experimental procedures were approved by the Ethics Experimentation Committee, University of Cagliari. In this context, all protocols have been carried out in full conformity with the rules and guidelines expected for this kind of trial. All pregnant mice received the same injection regimen. Only 6 of 10 were pregnant. At 10:00 a.m. on day E14 and E17 of gestation mice were weighed and treated with an intraperitoneal injection of TB4 (Regen-

eRX, Rockville, MD, USA; 6 mg/kg in PBS). Three pregnant mice received treatment with TB4 and three mice were used as a control group. To keep the same conditions of stress, the mice of the control group underwent corresponding intraperitoneal injections of vehicle (PBS). On the day E19 of gestation, caesarean sections were performed. The mothers were anaesthetized with chloroform. At birth, the length of each newborn was obtained. Then, newborn mice were sacrificed with chloroform and fixed in 10% formalin. Fetuses were subdivided into two symmetrical parts along the sagittal axis and routinely processed and paraffin-embedded.

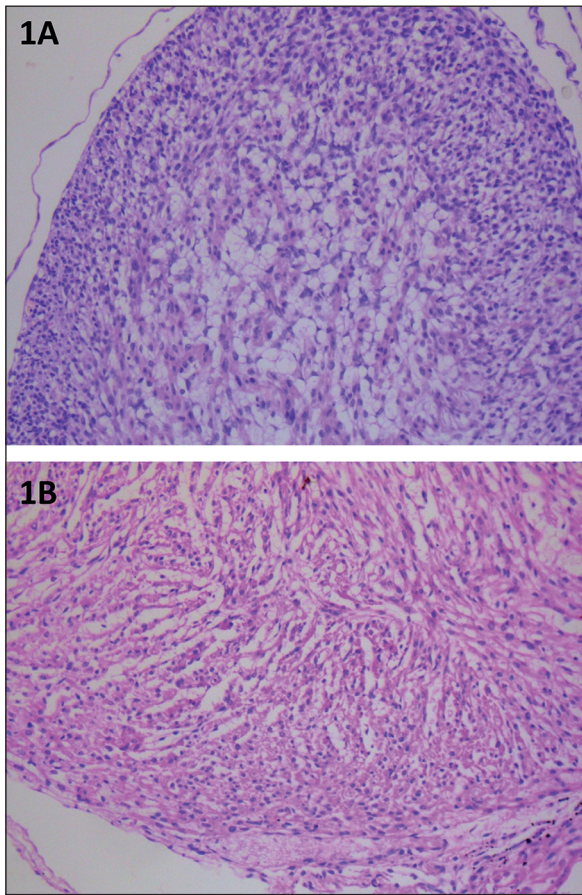
## Results

The length of the newborns from the TB4-treated mice and from the control group evidenced marked differences between treated and control animals (Table I). The 4 cranio-caudal length in treated animals ranged from 1.1 up to 1.8 cm (median value: 1.5 cm). In control neonates, the cranio-caudal length ranged from 0.6 up to 1.0 cm (median value: 0,8 cm). The histological study (Figures 1 to 7) of the various organs and tissues evidenced remarkable differences regarding the maturation of multiple fetal organs.

**HEART:** Marked differences were observed regarding maturation of cardiomyocytes<sup>5</sup> between controls (Figure 1A) and treated animals (Figure 1B). In control newborn mice,

**Table I.** Length of new born mice (delivery at E19).

TB4 TREATED		CONTROL ANIMALS			
1	1,3 cm	4	0,6 cm	Same litter	Same litter
	1,1 cm		0,6 cm		
	1,3 cm		0,6 cm		
	1,3 cm		0,6 cm		
2	1,8 cm	5	0,8 cm	Same litter	Same litter
	1,8 cm		1,0 cm		
	1,7 cm		1,0 cm		
3	1,7 cm	6	1,0 cm	Same litter	Same litter
	1,8 cm		1,0 cm		
			0,8 cm		
			1,0 cm		
			0,9 cm		
			0,9 cm		



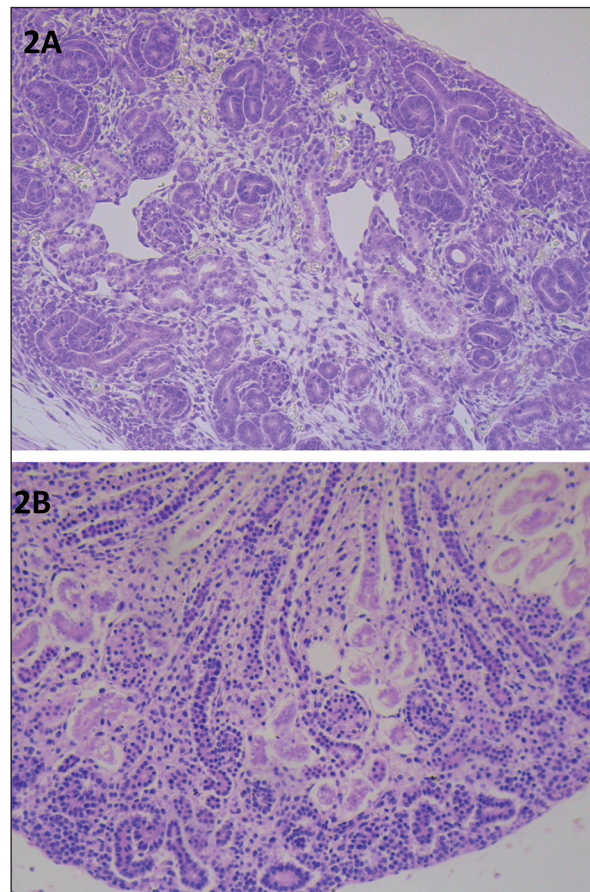
**Figure 1. A,** Heart E 19 in control group. Absence differentiation. Myxoid stroma (arrow) (magnification  $\times 20$ ). **B,** Heart E 19 in treated group. showed a higher degree of differentiation. (magnification  $\times 20$ ).

the periphery of the heart was formed by cardiomyocyte precursors, in the absence of any differentiation towards the cardiomyocyte phenotype. The central part of the developing heart was characterized by a myxoid stroma in which cords of eosinophilic scarcely differentiated cells were observed. In TB4-treated mice, the cardiac cells showed a higher degree of differentiation. At low power, cardiomyocytes were characterized by an abundant eosinophilic cytoplasm, lower nuclear/cytoplasmic ratio and a spindle shape (Figure 1B).

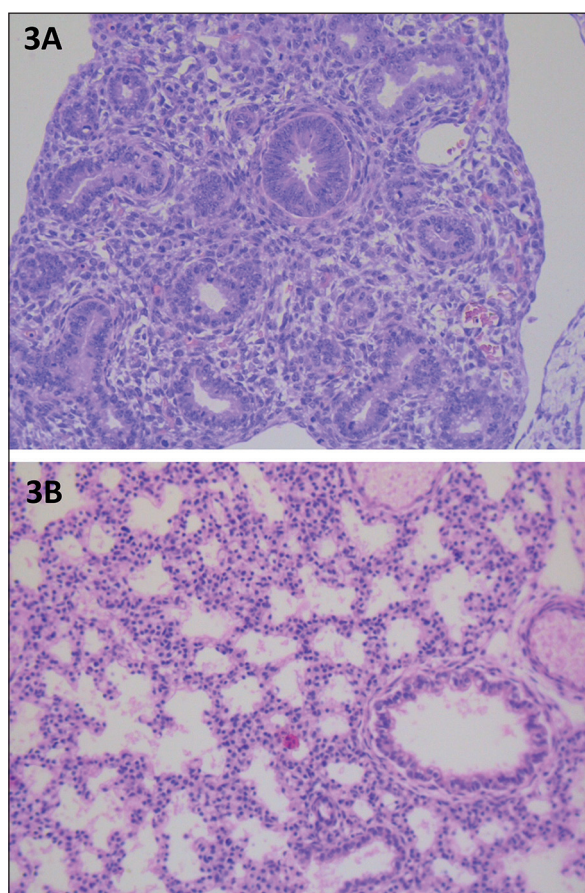
**KIDNEY:** The kidney of control animals (Figure 2A) showed a lower degree of differentiation as compared to controls. Kidney architecture was characterized by the presence of multiple metanephric stem/progenitors in the subcapsular zone. Metanephric precursors were in contact with the tips of ureteric bud-derived

ampullae. Renal vesicles, comma bodies and s-shape bodies were abundant, underlying the immaturity of developing kidneys (Figure 2A). In treated animals, the amount of metanephric precursors was significantly lower (Figure 2B) as compared with control kidneys. Well-formed glomeruli were observed. The differentiation of the specific epithelium of proximal and distal tubules was evident (Figure 2B).

**LUNG:** The architecture of the lungs was significantly different in treated and control animals. Focusing on the latter, lungs were in the pseudoglandular prealveolar stage of differentiation (Figure 3A). No well-formed alveolar spaces were found. On the other hand, in TB4-treated animals, the lungs were in the alveolar stage of development, with well-formed inter-alveolar septa and expanded alveoli. The epithelium of bronchioles appeared well differentiated (Figure 3B).



**Figure 2. A,** Kidney E 19 in control group shows high presence of comma and s-shaped bodies (arrow). (magnification  $\times 20$ ). **B,** Kidney E 19 in the treated group. Metanephric precursors were significantly lower. (magnification  $\times 20$ ).



**Figure 3.** **A**, Lung E 19 in the control group. The lung appears to be in the pseudoglandular prealveolar stage of differentiation. (magnification  $\times 20$ ). **B**, Lung E 19 in the treated group. Lungs is in the alveolar stage of development. The epithelium of bronchioles is well differentiated (arrow). (magnification  $\times 20$ ).

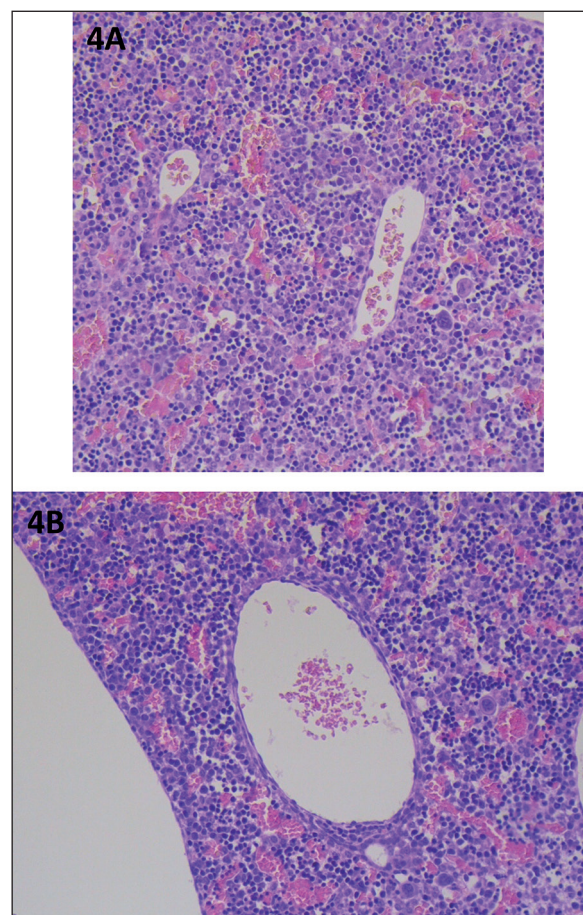
**LIVER:** No significant differences were found regarding liver architecture and development between treated and control animals (Figure 4A, B). In both livers, the hematopoietic component was higher than liver cell precursors.

**GUT:** Major differences were found regarding gut development. In treated animals the villous architecture of enterocytes, including goblets cells, was evident. In the intestinal wall, cells undergoing muscle cell differentiation were easily found (Figure 5B). On the contrary, in control animals the villous architecture was less evident and enterocytes appeared less differentiated. No clear sign of muscular differentiation was observed in the intestinal wall (Figure 5A).

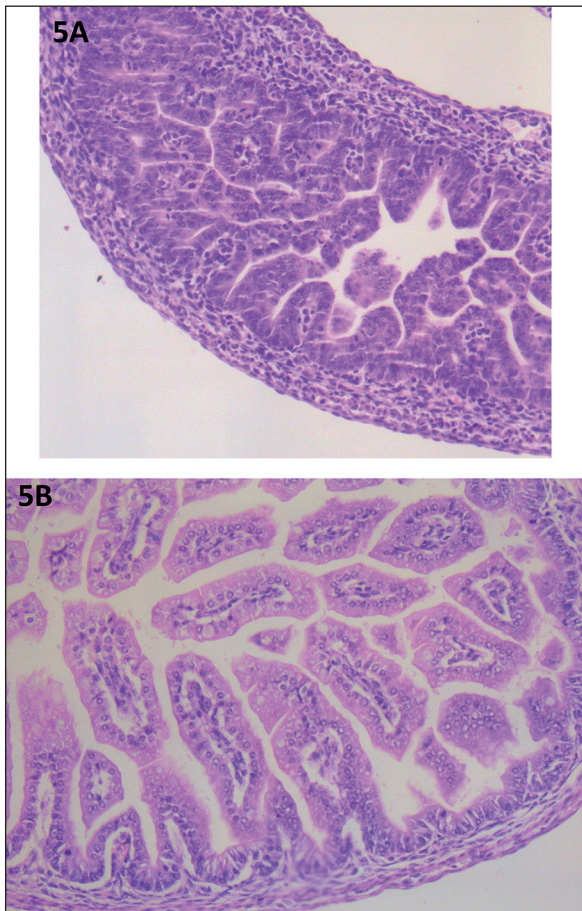
**CEREBRAL CORTEX:** The degree of differentiation of the cerebral cortex was much higher in treated animals as compared to control

mice. In TB4-treated animals, the thickness of the cerebral cortex was significant increased as compared to control brains (Figure 6B). The periventricular layer of the pre-mitotic neurons was thicker; the intermediate layer was formed by an eosinophilic fiber layer in which migrating neurons were embedded. The external layer of post mitotic neurons showed initial differentiation of cortical neurons (Figure 6B). In control animals, the degree of differentiation of all cell types of the brain cortex was significant lower, with prevalence of undifferentiated neuronal and glial precursors (Figure 6A).

**NOTOCHORD:** The degree of differentiation of the notochord appeared markedly different between controls and TB4-treated animals. In TB4-treated mice, chondroblasts of the vertebral body and nucleus pulposus were clearly



**Figure 4.** **A**, Liver E 19 in the control group. The hematopoietic component appears more represented than liver cell precursors. (magnification  $\times 20$ ). **B**, Liver E 19 in the treated group. No significant differences with the control group. The hematopoietic component appears more represented than liver cell precursors. (magnification  $\times 20$ ).



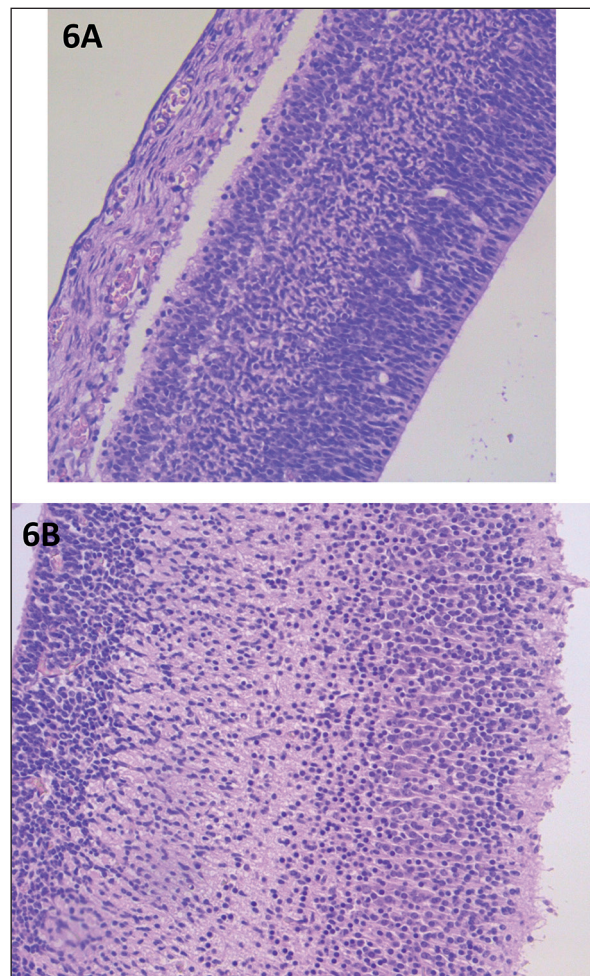
**Figure 5.** **A**, Intestine E 19 in the control group. The villous architecture was less evident and enterocytes appeared less differentiated. (magnification  $\times 20$ ). **B**, Intestine E 19 in the treated group. The villous architecture is evident. (magnification  $\times 20$ ).

seen (Figure 7B). In reverse, in controls animals both vertebral body and nucleus pulposus were lacking, suggesting a lower degree of differentiation of the notochord stem/progenitor cells.

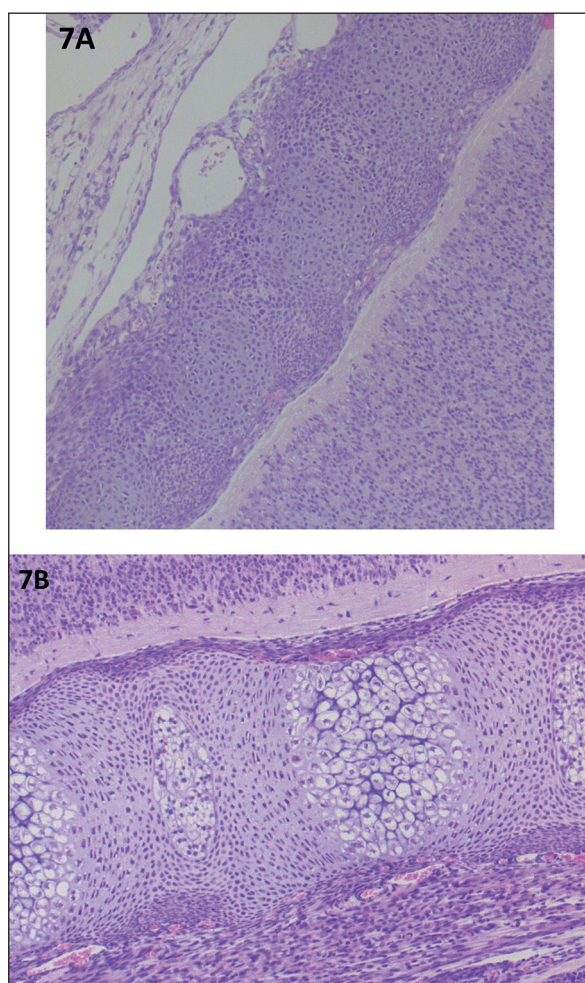
### Discussion

In this study, for the first time, TB4, a peptide naturally produced by the body, was administered during pregnancy in order to determine a possible effects on fetal development. Our data clearly demonstrate that TB4, when administered to pregnant mice in the last week of gestation, is capable of accelerating the development of the entire fetus and fetal organs. Regarding the body length at birth, newborns of TB4-treated

animals showed a length always higher than the neonates of non treated mice. In particular, the length of control newborns was constantly below or equal to 1 cm, whereas the length of TB4-treated animals ranged from 1.1 up to 1.8 cm. In some cases, the length of treated newborns was two times higher as compared to the length of control neonates. The effects of TB4 administered in the last part of gestation on fetal development were evidenced by the histological examination of multiple organs, including heart, kidney, lungs, gut, notochord and cerebral cortex. In all these organs, the degree of differentiation of stem/precursor cells was accelerated by the maternal administration of TB4, leading to the appearance of a more mature organ architecture.



**Figure 6.** **A**, Cerebral cortex E 19 in the control group. The degree of differentiation of all cell types is significant lower, and neuronal and glial precursors are undifferentiated. (magnification  $\times 20$ ). **B**, Cortex E 19 in the treated group. A higher degree of differentiation of the cerebral cortex is evident. (magnification  $\times 20$ ).



**Figure 7.** **A**, Developing notochord E 19 in the control group. Vertebral bodies and nucleus pulposus are lacking. (magnification  $\times 20$ ). **B**, Developing notochord E 19 in the treated group, showing a higher degree of maturation. The vertebral body (arrowheads) and the nucleus pulposus (arrows) are clearly seen. (magnification  $\times 20$ ).

Of particular interest is the accelerated development of lung being the crucial organ for postnatal survival in the newborns from TB4-treated mice. The presence of a high number of well-formed alveoli following TB4-administration during the last part of gestation, represents the most important finding emerging from this study suggesting that TB4 might act as a powerful accelerator of lung development in preterm neonates. No significant differences in development were observed only in liver tissue. All these data taken together evidence that TB4 administered during the last week of gestation plays a relevant role in the development of the entire fetus, as shown by the differences in size of the fetuses delivered from TB4-treated mothers. With a certain variability,

these results were common to all the fetuses delivered from the TB4-treated mothers, compared to controls, and were not dependent on the number of offspring, because they were observed also in mothers with the same number of fetuses. It is interesting to note that direct administration of TB4 to 8 newborn mice at birth had no effect on their postnatal development (data not showed). As always, the translation of these results to humans remains to be established. Nonetheless, our preliminary results highlighted the possibility for the prenatal treatment of programmed human premature births. Prematurity in humans is defined as a birth occurring before 37 full weeks of gestation. Depending on how early a baby is born, preterm babies may be subdivided into late preterms, born between 34 and 36 weeks, moderately preterm, 32 and 34 weeks, very preterm, less than 32 weeks and extremely preterm, born at or before 25 weeks of pregnancy. Prematurity is associated with an increased risk of perinatal death, cerebral palsy, vision impairment, and cognitive or hearing impairment. The risk of these complications are directly correlated with increasing immaturity, infants born before 25 weeks of gestation having the highest mortality rate and the greatest risk for severe impairment in survivors<sup>17</sup>. The incidence and prevalence of prematurity is increasing around the world. Recently, the high percentage of premature babies has prompted a great deal of research into etiology of prematurity and development of effective prevention of short-term and long-term complication associated to preterm delivery. Regarding the long-term consequences related to a premature birth, the interruption of the physiological development of tissues and organs has been hypothesized to play a relevant role in our susceptibility to develop severe diseases not only in the perinatal period, but even in adulthood.

## Conclusions

Our preliminary data show for the first time that a natural peptide physiologically present in the human body, when given to pregnant mothers during the last part of gestation, may accelerate fetal development and improve structural development of the fetal organs critical for the survival of the newborn. On these premises, the preliminary data of this study have to be further investigated on a larger number of subjects in order to establish the optimal doses and time of

administration, as well as to ascertain the consequences of the administration on the development after birth<sup>9</sup>. Nonetheless, they provide a consistent hope for new clinical treatment for preterm delivery cases.

### Conflict of Interest

The Authors declare that they have no conflict of interests.

### References

- 1) Tan WKY, Purnamawati K, Pakkiri LS, Tan SH, Yang X, Chan MY, Drum CL. Sources of variability in quantifying circulating thymosin beta-4: literature review and recommendations. *Expert Opin Biol Ther* 2018; 18: 141-147.
- 2) Inzitari R, Cabras T, Pisano E, Fanali C, Manconi B, Scarano E, Fiorita A, Paludetti G, Mani A, Nemolato S, Faa G, Castagnola M, Messina I. HPLC-ESI-MS analysis of oral human fluids reveals that gingival crevicular fluid is the main source of oral thymosins beta(4) and beta(10). *J Sep Sci* 2009; 32: 57-63.
- 3) Nemolato S, Messina I, Cabras T, Manconi B, Inzitari R, Fanali C, Vento G, Tirone C, Romagnoli C, Riva A, Fanni D, Di Felice E, Faa G, Castagnola M. Thymosin beta(4) and beta(10) levels in pre-term newborn oral cavity and foetal salivary glands evidence a switch of secretion during foetal development. *PLoS One* 2009; 4; e5109.
- 4) Nemolato S, Cabras T, Cau F, Fanari MU, Fanni D, Manconi B, Messina I, Castagnola M, Faa G. Different thymosin Beta 4 immunoreactivity in foetal and adult gastrointestinal tract. *PLoS One* 2010; 9.
- 5) Nemolato S, Cabras T, Fanari MU, Cau F, Fanni D, Gerosa C, Manconi B, Messina I, Castagnola M, Faa G. Immunoreactivity of thymosin beta 4 in human foetal and adult genitourinary tract. *Eur J Histochem* 2010; 54-43.
- 6) Nemolato S, Cabras T, Fanari MU, Cau F, Frascini M, Manconi B, Messina I, Castagnola M, Faa G. Thymosin beta 4 expression in normal skin, colon mucosa and in tumor infiltrating mast cells. *Eur J Histochem* 2010; 16-23.
- 7) Gerosa C, Fanni D, Nemolato S, Locci A, Marinelli V, Cabras T, Messina I, Castagnola M, Monga G, Fanos V, Faa G. Thymosin beta-10 expression in developing human kidney. *J Matern Fetal Neonatal Med* 2010; 23: 125-128.
- 8) Fanni D, Gerosa C, Nemolato S, Locci A, Marinelli V, Cabras T, Messina I, Fanos V, Castagnola M, Faa G. Thymosin beta 10 expression in developing human salivary glands. *Early Hum Dev* 2011; 87: 779-783.
- 9) Faa G, Nemolato S, Cabras T, Fanni D, Gerosa C, Fanari M, Locci A, Fanos V, Messina I, Castagnola M. Thymosin  $\beta$ 4 expression reveals intriguing similarities between fetal and cancer cells. *Ann N Y Acad Sci* 2012; 1269: 53-60.
- 10) Nemolato S, Cabras T, Restivo A, Zorcolo L, Di Felice E, Fanni D, Gerosa C, Messina I, Castagnola M, Faa G, Casula G. Thymosin  $\beta$ 4 expression in colorectal polyps and adenomas. *Clinics (Sao Paulo)* 2013; 68: 1220- 1224.
- 11) Nemolato S, Restivo A, Cabras T, Coni P, Zorcolo L, Orrù G, Fanari M, Cau F, Gerosa C, Fanni D, Messina I, Castagnola M, Casula G, Faa G. Thymosin  $\beta$  4 in colorectal cancer is localized predominantly at the invasion front in tumor cells undergoing epithelial mesenchymal transition. *Cancer Biol Ther* 2012; 13: 191-197.
- 12) Theunissen W, Fanni D, Nemolato S, Di Felice E, Cabras T, Gerosa C, Van Eyken P, Messina I, Castagnola M, Faa G. Thymosin beta 4 and thymosin beta 10 expression in hepatocellular carcinoma. *Eur J Histochem* 2014; 58.
- 13) Sosne G, Qiu P, Kurpakus-Wheater M. Thymosin beta 4: a novel corneal wound healing and anti-inflammatory agent. *Clin Ophthalmol* 2007; 1: 201-207.
- 14) Goldstein AL, Kleinman HK. Advances in the basic and clinical applications of thymosin  $\beta$ 4. *Expert Opin Biol Ther* 2015; 15: 139-145.
- 15) Smart N, Risebro CA, Melville AA, Moses K, Schwartz RJ, Chien KR, Riley PR. Thymosin beta4 induces adult epicardial progenitor mobilization and neovascularization. *Nature* 2007; 445: 177-182.
- 16) Desiderio C, Martelli C, Rossetti DV, Di Rocco C, D'Angelo L, Caldarelli M, Tamburrini G, Iavarone F, Castagnola M, Messina I, Cabras T, Faa G. Identification of thymosins  $\beta$ 4 and  $\beta$  10 in paediatric craniopharyngioma cystic fluid. *Childs Nerv Syst* 2013; 29: 951-960.
- 17) Fanaroff AA, Stoll BJ, Wright LL, Carlo WA, Ehrenkranz RA, Stark AR, Bauer CR, Donovan EF, Korones SB, Lupton AR, Lemons JA, Oh W, Papile LA, Shankaran S, Stevenson DK, Tyson JE, Poole WK. Trends in neonatal morbidity and mortality for very low birth-weight infants. *Am J Obstet Gynecol* 2007; 196: 147-148.