

# Atypical fibroxanthoma/pleomorphic dermal sarcoma of the scalp with aberrant expression of HMB-45: a pitfall in dermatopathology

Viviana Piras<sup>1</sup>, Caterina Ferreli<sup>1</sup>, Laura Atzori<sup>1</sup>, Giampietro Pinna<sup>2</sup>, Luca Pilloni<sup>2</sup>

<sup>1</sup> Department of Medical Sciences and Public Health, Unit of Dermatology, University of Cagliari, Italy;

<sup>2</sup> Department of Medical Sciences and Public Health, Unit of Pathology, University of Cagliari, Italy

## Summary

Atypical fibroxanthoma (AFX) has been considered as the non-infiltrating precursor lesion of pleomorphic dermal sarcoma (PDS), which shows an aggressive clinical behavior, because of its extensive invasion of the deeper skin layers. Although these two tumors may represent two stages of the same disease, it can be difficult to differentiate between them, because of their similar clinical and histological features<sup>1</sup>. Furthermore, they must be distinguished from a spindle variant of squamous carcinoma, melanoma and leiomyosarcoma<sup>2</sup>. AFX/PDS still remains a diagnosis of exclusion, that needs to combine immunohistochemical markers for a definitive diagnosis. Usually AFX/PDS shows positivity for CD10, CD99, CD68, vimentin and lysozyme, while S100, HMB45, MART-1, cytokeratins, CD34, CD31, desmin and h-caldesmon are absent.

We report a case of 89-year-old male, with a history of squamous cell carcinoma removed from the right ear, presented to our department with a recently growing, ulcerated and bleeding 2 cm nodule on the scalp. After surgery the tumor recurred with infiltration to the cranial theca. The final histological diagnosis was "pleomorphic dermal sarcoma" (PDS), which showed an unexpected positivity for HMB45. We present, to the best of our knowledge, the first case of AFX/PDS with an aberrant diffuse expression of HMB45 and an aggressive biological behavior, that leads us to a difficult exclusion diagnosis.

**Key words:** atypical fibroxanthoma, HMB45, pleomorphic dermal sarcoma

Received: December 19, 2019

Accepted: May 25, 2020

## Correspondence

Viviana Piras

Department of Medical Sciences and Public Health, Unit of Dermatology, University of Cagliari, Italy

E-mail: vivy.piras@gmail.com

## Conflict of interest statement

The Authors declare no conflict of interest.

**How to cite this article:** Piras V, Ferreli C, Atzori L, et al. Atypical fibroxanthoma/pleomorphic dermal sarcoma of the scalp with aberrant expression of HMB-45: a pitfall in dermatopathology. *Pathologica* 2020;112:105-109. <https://doi.org/10.32074/1591-951X-39-19>

© Copyright by Società Italiana di Anatomia Patologica e Citopatologia Diagnostica, Divisione Italiana della International Academy of Pathology



OPEN ACCESS

This is an open access journal distributed in accordance with the CC-BY-NC-ND (Creative Commons Attribution-NonCommercial-NoDerivatives 4.0 International) license: the work can be used by mentioning the author and the license, but only for non-commercial purposes and only in the original version. For further information: <https://creativecommons.org/licenses/by-nc-nd/4.0/deed.en>

## Introduction

Since 1960, when Helwing described for the first time AFX as a cutaneous tumor with marked pleomorphism, but with a benign course, the entire spectrum of AFX and related neoplasms have been a topic of ongoing debate<sup>3-7</sup>.

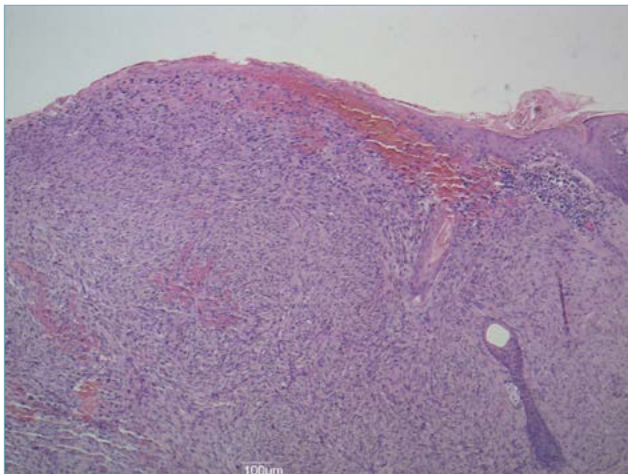
In 1964, Kempson defined AFX as histologically malignant, but biologically benign. In 1991, Murphy and Elder consider AFX as a fibrohistiocytic neoplasm of the skin, showing malignant histological features and locally aggressive course, fitting with a low-grade variant of "malignant fibrous histiocytoma" (MFH)<sup>8,9</sup>.

Improperly and for many years the terms AFX and MFH were used interchangeably or referring to superficial (AFX) or deeper (MFH) tumors. The term MFH has been supplanted by the term "Undifferentiated pleomorphic sarcoma" (UPS). Tumors that in the past have been referred to as cutaneous UPS, or as superficial MFH, are now defined as Pleomorphic Dermal Sarcoma (PDS)<sup>7,10,11</sup>.

AFX and PDS are rare mesenchymal tissue tumors that are clinically and morphologically similar, which can be considered two stages of the same disease, rather than two different entities. AFX is considered the non-infiltrating precursor lesion of PDS which shows an aggressive behavior and high grade of malignancy<sup>2,12</sup>. Often the diagnosis of AFX and PDS remains a diagnosis of exclusion, because of the absence of discriminatory morphological or immunohistochemical features<sup>7</sup>.

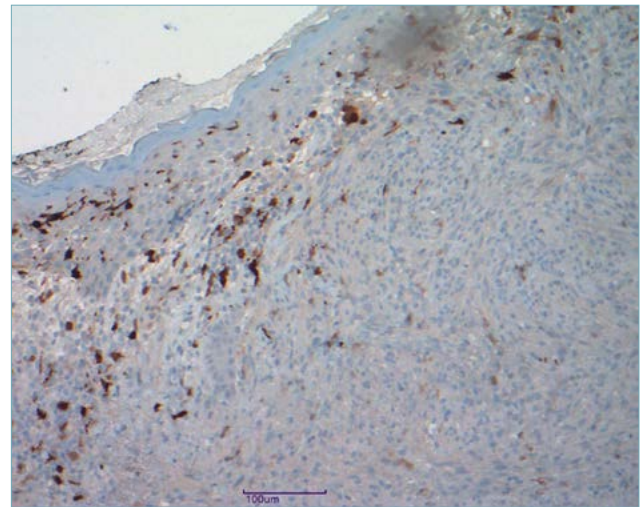
## Case report

In January 2017 a 89-year-old male, with a history of squamous cell carcinoma removed from the right ear, presented to our department with a recently growing nodular, ulcerated and bleeding nodule on scalp, measuring 1 cm x 2 cm. Excision was performed and histopathological examination showed a dermal highly vascularized, ulcerated tumor composed of atypical spindle cells, arranged in fascicles, elongated nucleus, often in mitosis (Fig. 1). Immunohistochemistry showed tumor cells negativity for S100 protein (Fig. 2), cytokeratins (AE1-AE3- 34 betaE12), smooth muscle actin, desmin, p16, CD31, CD34, Melan-A, SOX10, tyrosinase. Vimentin, CD10 (Fig. 3), CD68, p53, HMB45 were positive (Fig. 4) and Ki-67 expression rate was 50%. Sometimes Perls positive cytoplasmic granules (hemosiderin deposits) and Fontana-Masson positive blackish granules (melanin deposits) were detectable. Based on immunomarking squamous cell carcinoma (negativity of cytokeratins, 34betaE12 and p16), leiomyosarcoma (negativity of smooth muscle actin and desmin), superficial dermatofibrosarcoma protuberans (negativity of CD34) and melanoma (negativity for S100 protein, Melan-A and tyrosinase) was excluded, although there was an unexpected cytoplasmic positivity for HMB45. In the presence of CD10 and CD68 positivity a diagnosis of atypical fibroxanthoma with aberrant expression of HMB45 was done. Wide excision was performed, but due to the size of the tumor

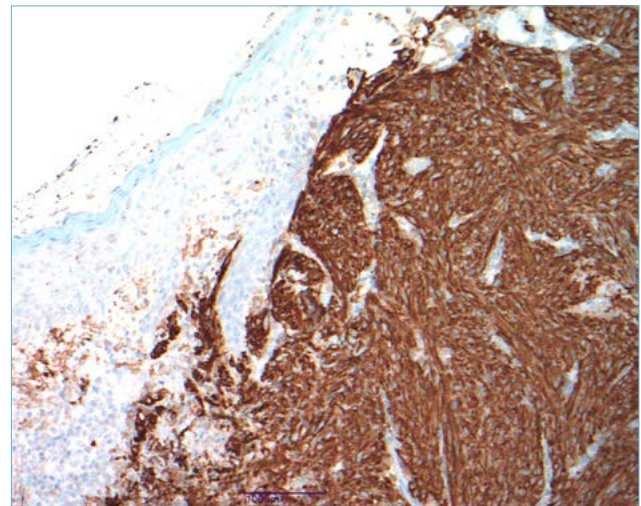


**Figure 1.** Dermal highly vascularized, ulcerated tumor composed of atypical spindle cells, arranged in fascicles, elongated nucleus, often in mitosis (H&E staining: 10x).

myosarcoma (negativity of smooth muscle actin and desmin), superficial dermatofibrosarcoma protuberans (negativity of CD34) and melanoma (negativity for S100 protein, Melan-A and tyrosinase) was excluded, although there was an unexpected cytoplasmic positivity for HMB45. In the presence of CD10 and CD68 positivity a diagnosis of atypical fibroxanthoma with aberrant expression of HMB45 was done. Wide excision was performed, but due to the size of the tumor

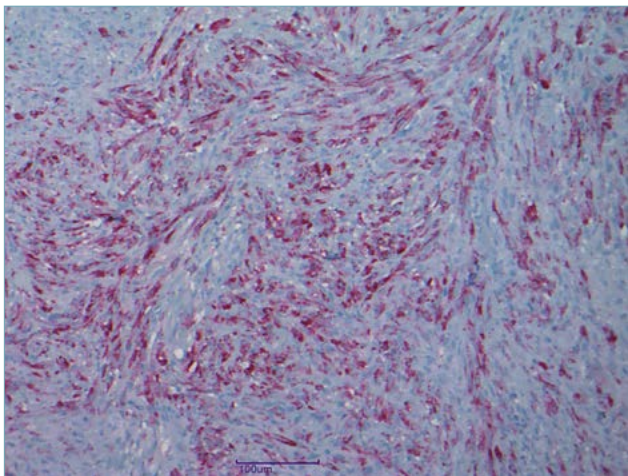


**Figure 2.** Immunohistochemical analysis showing tumor cells negativity for S100 protein (10x).

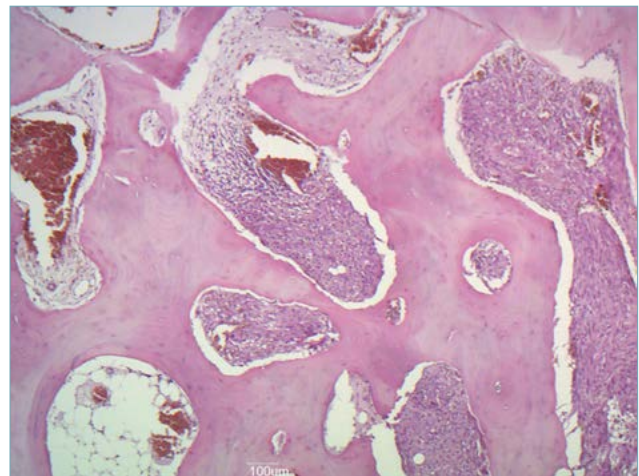


**Figure 3.** Diffuse positive staining with CD10 (10x).

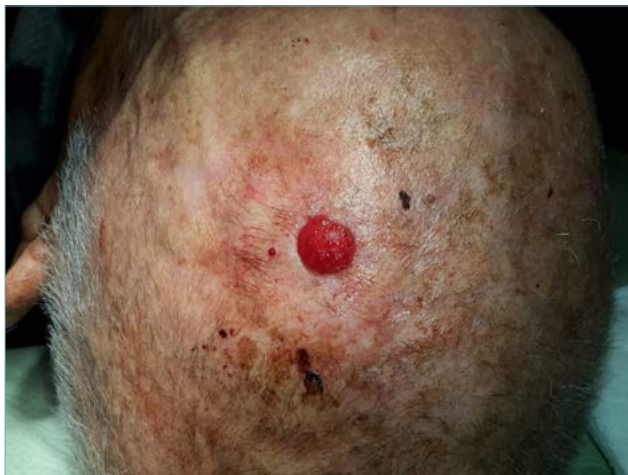



**Figure 4.** Aberrant cytoplasmic positivity with HMB45 staining (20x).



**Figure 6.** Recurrent tumor with invasion of the skull (10x).



**Figure 5.** Clinical recurrence on the patients' scalp after wide surgical excision.

that reached the lateral margins of surgical resection, the tumor recurred with invasion of the cranial theca (Figs. 5, 6). Chest radiography and neck lymph nodes ultrasound were negative.

We referred the patient to the department of plastic surgery in order to perform radical surgery and final histological diagnosis, based on infiltration of the cranial theca, was PDS with aberrant HMB45 expression. Molecular biology investigation on BRAF V600E was performed to complete the histological study and was negative.

## Discussion

AFX is an uncommon cutaneous neoplasm, with uncertain etiology, that mainly arises from either fibrocytic or myofibrocytic cells<sup>13</sup>. It represents up to 0.2% of all skin tumors and has a male predominance (70%). Commonly the tumor occurs on sun damaged skin of elderly people, between 7<sup>th</sup> and 8<sup>th</sup> decade of life<sup>5, 6, 14-16</sup>. Usually it is described as a solitary, exophytic, painless, firm, skin-colored or brown-red, often eroded or ulcerated nodule. It can grow up rapidly, but the tumor size rarely exceeds 2 cm. Head and neck are involved in the 80% of cases (especially the scalp). The lesions might also appear on ears, cheeks and nose, while on forearms or on dorsa of hands are rare. Histologically, tumor cells are located in the dermis with sometimes a grenz zone present between epidermis and tumor, but more commonly tumor reaches the epidermis, that can be atrophic and ulcerated. Tumor cells show spindle and epithelioid features with pleomorphic vesicular or hyperchromatic nuclei. Usually giant cells are present. Mitoses are often numerous and may show atypia. The most common morphological pattern is dominated by spindle cells mixed with epithelioid cells, followed by variants with predominantly spindle cells, exclusively spindle cells, or predominantly epithelioid cells. Unusual variants of AFX exist. They include clear cell, osteoid, osteoclastic, chondroid pigmented, granular cell variant. There are not necrosis or vascular invasion<sup>3,5,15-18</sup>. Atypical fibroxanthoma has been considered as a precursor lesion of PDS which shows an aggressive clinical behavior. Although those two tumors may represent two stages of the same disease, it can be difficult to differentiate between them,

because of their similar clinical and histological features. The only morphological features that allow us to distinguish that two lesions are the larger tumor size, deeper subdermal involvement, invasion of fascia or muscle, lymphovascular or perineural invasion and/or necrosis<sup>2,10</sup>. Furthermore, the bizarreness and atypia seen in AFX and PDS cells might suggest a diagnosis of malignant tumor, for that reason it is vital to distinguish AFX/PDS from other cutaneous neoplasms for diagnosis and management. The main histological differential diagnosis is a spindled variant of squamous carcinoma, melanoma (especially spindle or desmoplastic type), or leiomyosarcoma. Immunohistochemistry can help in this distinction<sup>3,14-18</sup>.

Considering that in AFX/PDS several morphological features overlap those found in mesenchymal epithelial malignant tumors, immunohistochemistry assumes a very important role in the differential diagnosis of AFX/PDS. AFX shows a positive reactivity to vimentin, CD10, CD68 and sometimes actin, whereas it is usually negative for CAM5.2, CD34, Melan-A, S100, HMB45, cytokeratins A1/A3 14. Indeed, focal staining for single additional melanocytic marker has been reported<sup>19,20</sup>.

Based on these considerations, AFX/PDS still remains a diagnosis of exclusion, which needs to combine immunohistochemical markers for a definitive diagnosis. Usually AFX/PDS show positivity for CD10 (in 95-100% cases), CD99, CD68 (in more than half cases), vimentin and lysozyme. Sometimes smooth muscle actin expression has been reported in some AFX. While S100, HMB45, MART-1, cytokeratins, CD34, CD31, desmin and h-caldesmon are absent in AFX/PDS. CD10 (or the common acute lymphoblastic leukaemia antigen, CALLA) is considered a useful marker for AFX (positive in 95-100% of cases), but also 1/3 of malignant melanomas, about half cases of squamous cell carcinomas and half cases of leiomyosarcomas are positive<sup>3,6,21,22</sup>. CD99 is a glycoprotein, indicative of myofibroblastic differentiation with a positive rate in AFX between 35% and 73%<sup>19,20</sup>. However, malignant melanoma (10-60% cases) might show a positivity for CD99, but no cases of SCC positive for CD99 have been reported. CD68 is positive in more than half of all AFX, but it is also detectable in 86% of malignant melanoma. Procollagen-1 was strongly positive in 87% of AFX cases, but also in 1/3 of the desmoplastic malignant melanomas and desmoplastic squamous cell carcinomas. AFX is distinguished from leiomyosarcoma, which has a smooth muscle differentiation, with positivity for calponin and h-caldesmon<sup>5</sup>. Cytokeratins are epithelial markers, positive in squamous cell carcinoma, very useful to exclude sarcomatoid or spindle cell SCC. S100 protein, used to mark Schwann cells,

is a melanogenesis marker, used for initial screening for melanocytic tumors, positive in melanoma. HMB-45 and MART-1 are melanocyte specific markers to confirm the melanocytic nature of S100 positive lesions<sup>10</sup>. However, poorly differentiated SCC might not express cytokeratins and not all melanomas show staining positivity for S100 and HMB45. Furthermore, sometimes also AFX may express focal positivity for S100, because of dendritic Langerhans cells entrapped inside<sup>6,23</sup>. Moreover, in the literature two cases of AFX, which show focal expression of HMB45 and MART1, are described<sup>17,24</sup>. Therefore, caution is advisable in interpreting focal and slight positivity for additional melanocytic markers<sup>19,20</sup>. We presented a similar case of AFX with aberrant expression of HMB-45, and we reported theories suggested by Smith-Zagone et al. concerning for reason of HMB45 expression in a non-melanocytic neoplasia. HMB-45 recognizes the gp100, whereas MART-1 recognizes a protein called PMe117. Both proteins are localized in the inner membranes of premelanosomes. They are not specific only for the melanocytic lineage, they are positive in angiomyolipomas, lymphangioliomyomatosis, tumors of the lung, adrenal cortical tumors and sex cord tumors of gonads. This may be explained by the presence of premelanosomes in some of these tumors or by an antibody cross reactivity against an antigenic epitope similar to gp100 in steroidogenic tumors. In AFX premelanosomes are not demonstrated, consequently the positivity could be explained by a cross reactivity with an antigen similar to that observed in steroidogenic tumors, which do not contain premelanosomes. The expression seems to be more important in the cells with vacuolated cytoplasm, suggesting that a lipid could be possibly considered the cross-reacting substance. Another theory could be that some of these tumor cells have phagocytized fragments of melanocytes<sup>17,24</sup>.

## Conclusion

We present, to the best of our knowledge, the first case of AFX/PDS with an aberrant diffuse expression of HMB45 and an aggressive biological behavior, which led to a difficult diagnosis of exclusion<sup>14</sup>. It is critical to distinguish AFX from PDS, because of their clinical and morphological similarities. Often it is difficult to distinguish those two entities, considered to be the two extremities of the same clinical-pathological tumor spectrum, especially without evidence of extensive invasion of the deeper layer<sup>7</sup>. The clinical progression of our case supports that AFX could be actually considered as the initial lesion of a spectrum

of a tumor, in which PDS represents the final manifestation. For that reason we agreed to call it “cutaneous pleomorphic sarcoma” or with a more appropriate name “AFX/PDS”<sup>11,12</sup>.

According to our experience, we regard S100 as the most important stains in the main differential diagnosis of AFX and melanoma. We suggest considering HMB45 as a non-specific marker to exclude the diagnosis of AFX, in order to avoid diagnostic mistakes. If there is a correlation between HMB45 positivity and AFX evolving to the PDS is yet to be assessed on a larger series.

## References

- 1 Klebanov N, Hoang MP, Reddy BY. Pleomorphic dermal sarcoma of the scalp. *Cureus* 2018;10:e2979. <https://doi.org/10.7759/cureus.2979>
- 2 Ackerman L. *Surgical pathology*. 4<sup>th</sup> ed. London: Kimpton 1968.
- 3 Ziemer M. Atypical fibroxanthoma. *J Dtsch Dermatol Ges* 2012;10:537-50. <https://doi.org/10.1111/j.1610-0387.2012.07980.x>
- 4 Helwig EB, May D. Atypical fibroxanthoma of the skin with metastasis. *Cancer* 1986;57:368-76. [https://doi.org/10.1002/1097-0142\(19860115\)57:2<368::AID-CNCR2820570230>3.0.CO;2-n](https://doi.org/10.1002/1097-0142(19860115)57:2<368::AID-CNCR2820570230>3.0.CO;2-n)
- 5 López L, Vélez R. Atypical fibroxanthoma. *Arch Pathol Lab Med* 2016;140:376-9. <https://doi.org/10.5858/arpa.2014-0495-RS>
- 6 Sakamoto A. Atypical fibroxanthoma. *Clin Med Oncol* 2008;2:117-27. <https://doi.org/10.4137/cmo.s506>
- 7 Soleymani T, Aasi SZ, Novoa R, et al. Atypical fibroxanthoma and pleomorphic dermal sarcoma: updates on classification and management. *Dermatol Clin* 2019;37:253-9. <https://doi.org/10.1016/j.det.2019.02.001>
- 8 Glodblum JR, Folpe AL, Weiss SW. *Enzinger and Weiss's, Soft Tissue Tumors*. Philadelphia: Elsevier 1985.
- 9 Murphy GF, Elder DE. Fibrohistiocytic tumors. In: *Atlas of tumor pathology. Non-melanocytic tumors of the Skin*. Washington DC: Amer Registry of Pathology, 1991 pp. 229-231.
- 10 Griewank KG, Wiesner T, Murali R, et al. Atypical fibroxanthoma and pleomorphic dermal sarcoma harbor frequent NOTCH1/2 and FAT1 mutations and similar DNA copy number alteration profiles. *Mod Pathol* 2018;31:418-28. <https://doi.org/10.1038/modpathol.2017.146>
- 11 Rongioletti F. Atypical fibroxanthoma/undifferentiated pleomorphic sarcoma (superficial malignant fibrous histiocytoma). In: *Rare malignant skin tumors*. New York, NY: Springer, 2015 pp. 141-6.
- 12 Kapasi F, Cabral M, Ameerally P, et al. Remedy Publications LLC. Atypical fibroxanthoma and pleomorphic dermal sarcoma - two stages of the same disease? *World J Oral Maxillofac Surg* 2018;1:1009.
- 13 Rosai J. *Rosai and Ackerman's Surgical Pathology*. 9<sup>th</sup> ed. Edinburgh: Mosby 2004.
- 14 Sachdev R, Goel R, Gajendra S. Atypical fibroxanthoma of scalp: a paradoxical benign tumour. *J Clin Diagn Res JCDR* 2015;9(12):EL02-EL3. <https://doi.org/10.7860/JC-DR/2015/16495.6937>
- 15 Koch M, Freundl AJ, Agaimy A, et al. Atypical fibroxanthoma-Histological diagnosis, immunohistochemical markers and concepts of therapy. *Anticancer Res* 2015;35:5717-35.
- 16 Tuthill RJ. *Weedon's skin pathology*. LWW 2011.
- 17 Smith-Zagone MJ, Prieto VG, Hayes RA, et al. HMB-45 (gp103) and MART-1 expression within giant cells in an atypical fibroxanthoma: a case report. *J Cutan Pathol* 2004;31:284-6. <https://doi.org/10.1111/j.0303-6987.2004.00173.x>
- 18 Greene LA, Cooper K. Atypical fibroxanthoma: an immunohistochemistry update. *Adv Anat Pathol* 2008;15:374-5. <https://doi.org/10.1097/PAP.0b013e31818a64d3>
- 19 Choy B, Hyjek E, Montag AG, et al. High prevalence of MiTF staining in undifferentiated pleomorphic sarcoma: caution in the use of melanocytic markers in sarcoma. *Histopathology* 2017;70:734-45. <https://doi.org/10.1111/his.13139>
- 20 Helbig D, Mauch C, Buettner R, et al. Immunohistochemical expression of melanocytic and myofibroblastic markers and their molecular correlation in atypical fibroxanthomas and pleomorphic dermal sarcomas. *J Cutan Pathol* 2018;45:880-5. <https://doi.org/10.1111/cup.13346>
- 21 Nergard J, Glener J, Reimer D, et al. Atypical fibroxanthoma of the scalp with recurrent and multiple regional cutaneous metastases. *JAAD Case Rep* 2016;2:491-3. <https://doi.org/10.1016/j.jcdr.2016.09.016>
- 22 Hall JM, Saenger JS, Fadare O. Diagnostic utility of P63 and CD10 in distinguishing cutaneous spindle cell/sarcomatoid squamous cell carcinomas and atypical fibroxanthomas. *Int J Clin Exp Pathol* 2008;1:524-30.
- 23 Folpe AL, Cooper K. Best practices in diagnostic immunohistochemistry: pleomorphic cutaneous spindle cell tumors. *Arch Pathol Lab Med* 2007;131:1517-24.
- 24 Cai J-P, Randall MB. HMB-45 expression in a clear cell variant of atypical fibroxanthoma. *J Cutan Pathol* 2006;33:186-8. <https://doi.org/10.1111/j.0303-6987.2006.00406.x>