



TITLE:

# Reconstruction of the Midfoot Area with Vascularized Chimeric Osteocutaneous Scapula Flap: A Case Report

AUTHOR(S):

Arata, Jun; Tsuge, Itaru; Kumakiri, Masanori; Yamashita, Teruyo; Kaito, Shuko; Yong, Yoon; Yamada, Shigeru

---

CITATION:

Arata, Jun ...[et al]. Reconstruction of the Midfoot Area with Vascularized Chimeric Osteocutaneous Scapula Flap: A Case Report. *Plastic and Reconstructive Surgery Global Open* 2021, 9(3): e3361.

ISSUE DATE:

2021-03

URL:

<http://hdl.handle.net/2433/276622>

RIGHT:

Copyright © 2021 The Authors. Published by Wolters Kluwer Health, Inc. on behalf of The American Society of Plastic Surgeons; This is an open-access article distributed under the terms of the Creative Commons Attribution-Non Commercial-No Derivatives License 4.0 (CCBY-NC-ND), where it is permissible to download and share the work provided it is properly cited. The work cannot be changed in any way or used commercially without permission from the journal.

# Reconstruction of the Midfoot Area with Vascularized Chimeric Osteocutaneous Scapula Flap: A Case Report

Jun Arata, MD, PhD\*  
Itaru Tsuge, MD, PhD†  
Masanori Kumakiri, MD\*  
Teruyo Yamashita, MD\*  
Shuko Kaito, MD\*  
Yoon Yong, MD\*  
Shigeru Yamada, MD, PhD‡

**Summary:** We report a case of reconstruction of a left midfoot defect with a chimeric partial scapula and skin flap in a 20-year-old man. After radical debridement, bone and soft tissue defects were reconstructed with a chimeric scapula and skin flap. The postoperative course was uneventful. The patient could walk well without support, and bone union was achieved 6 months after surgery. In 14 months of follow-up, no clinical complications (including new ulcer or stress fracture) were noted and full ambulation was achieved, with the patient returning to his previous work. We suggest that the chimeric scapula and skin flap may be a useful alternative option for midfoot reconstruction. (*Plast Reconstr Surg Glob Open* 2021;9:e3361; doi: [10.1097/GOX.0000000000003361](https://doi.org/10.1097/GOX.0000000000003361); Published online 15 March 2021.)

**M**anagement of open fractures with severe tissue defects in the midfoot has long been a serious therapeutic challenge. Failure to achieve skin coverage or reconstruction of bony structures can lead to osteomyelitis and potential amputation. The ideal bone graft technique should allow the patient to pursue early mobilization while maintaining reliable full weight-bearing capability over the long term. We herein report a case in which a free vascularized chimeric osteocutaneous scapula flap was used for reconstruction of the left midfoot after high-energy trauma.

## CASE REPORT

A 20-year-old man was admitted to our hospital after a traffic accident for the treatment of an injury to the left foot that caused comminuted fractures of the base of the second, third, fourth, and fifth metatarsal; medial, intermediate, and lateral cuneiform; and cuboid bones with some bone loss and extensive soft tissue loss in the lateral dorsal region (Fig. 1). The soft tissue defect involved the skin and

extensor digitorum longus tendons from the second to fifth toes. The trauma disrupted the dorsalis pedis artery.

In an emergency setting, surgical debridement and multiple-pin fixation of the comminuted fracture were performed. In the absence of local infection, we planned to use a chimeric partial scapula and perforator-based skin flap to reconstruct each area of tissue loss at 3 weeks after the trauma. A left chimeric scapula and scapular circumflex artery skin flap were therefore harvested to reconstruct the wound. First, the flap (7 × 17 cm) was designed to include the triangular space and the transverse branch of the circumflex scapular artery. The skin flap was raised from the medial side and circumflex scapular artery, and the angular branch of the thoracodorsal artery and main pedicle of the subscapular artery were detected in turn. The scapula was then raised, with care taken to avoid damaging the descending branch of the circumflex scapular artery and the angular branch of the thoracodorsal artery. Bone (3 × 11 cm) was harvested from the lateral border of the scapula and extended medially to include the thin bone of the scapula. The scapula was separated, keeping the blood supply intact. The composite tissue was then planted at the defect and the separated scapular bones were fixed with Kirschner wires (Figs. 2 and 3). The skin flap was used to cover the exposed tendons reconstructed by a tendon graft. End-to-end anastomosis was performed from the pedicle to the tibialis anterior artery and its accompanying veins.

The postoperative course was uneventful, and a complete flap survival was observed. At 2 weeks after reconstruction, rehabilitation of the left foot began with an external splint. The splint was removed 4 weeks later. Rehabilitation of the donor site started 7 days after the operation, and after 3 weeks, the patient had no difficulty

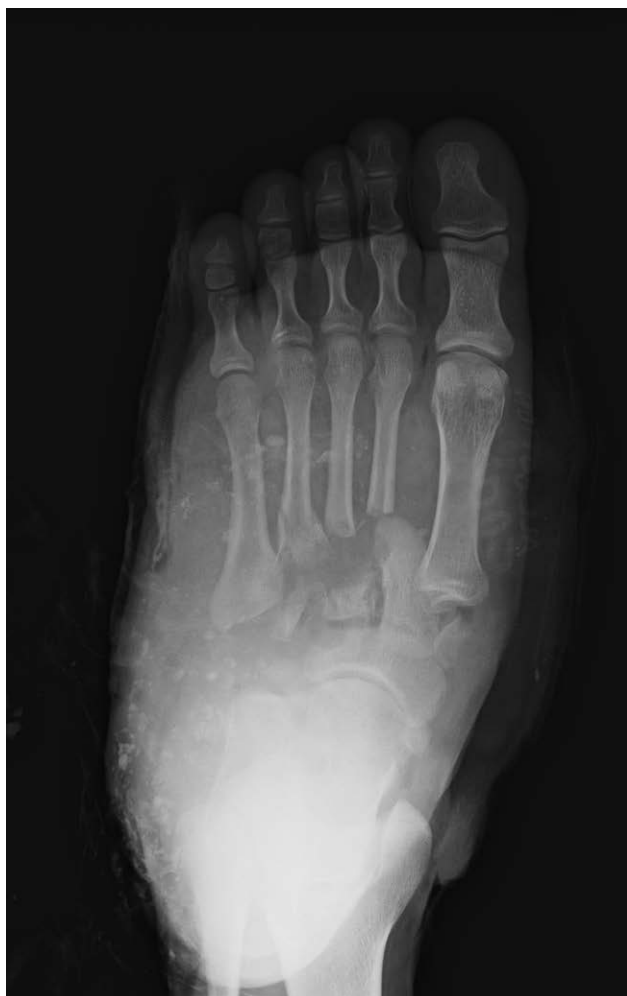From the \*Department of Plastic and Reconstructive Surgery, National Hospital Organization Kyoto Medical Center, Japan; †Department of Plastic and Reconstructive Surgery, Graduate School of Medicine, Kyoto University, Kyoto, Japan; ‡Department of Orthopedic Surgery, National Hospital Organization Kyoto Medical Center, Japan.

Received for publication August 25, 2020; accepted November 13, 2020.

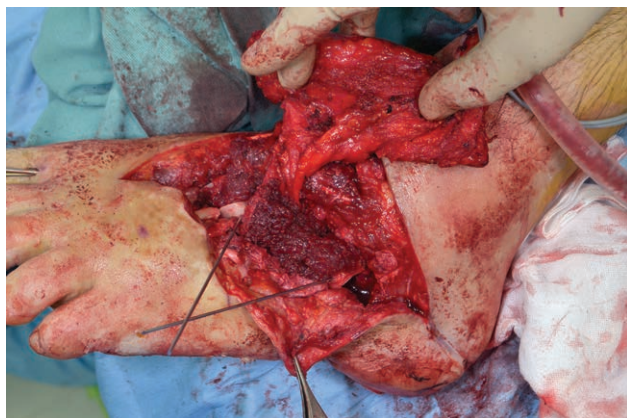
Copyright © 2021 The Authors. Published by Wolters Kluwer Health, Inc. on behalf of The American Society of Plastic Surgeons. This is an open-access article distributed under the terms of the [Creative Commons Attribution-Non Commercial-No Derivatives License 4.0 \(CCBY-NC-ND\)](https://creativecommons.org/licenses/by-nc-nd/4.0/), where it is permissible to download and share the work provided it is properly cited. The work cannot be changed in any way or used commercially without permission from the journal.

DOI: [10.1097/GOX.0000000000003361](https://doi.org/10.1097/GOX.0000000000003361)

**Disclosure:** The authors have no financial interest to declare in relation to the content of this article.

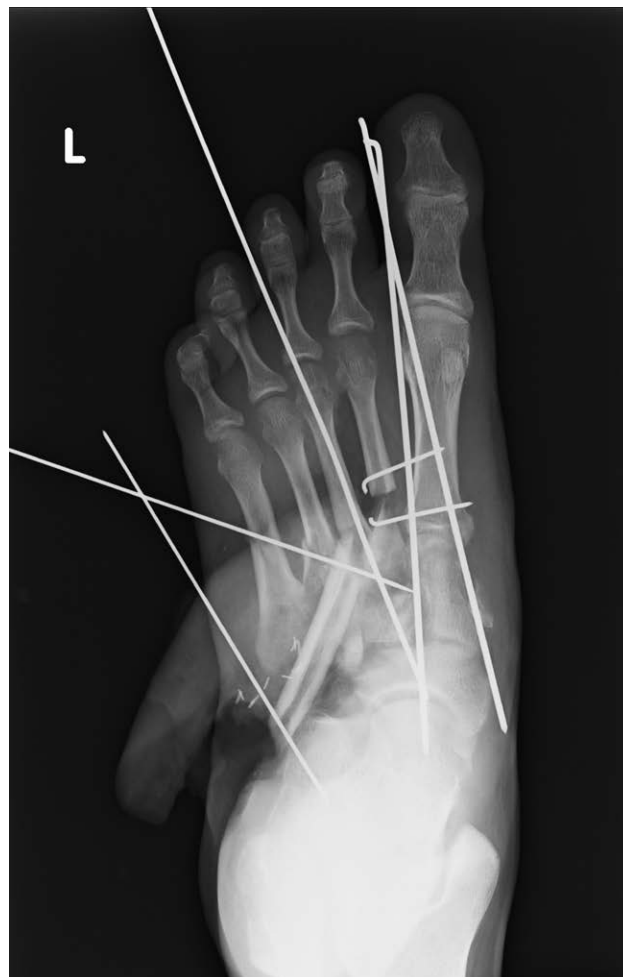

**Fig. 1.** Comminuted fractures of the base of the second, third, fourth, and fifth metatarsals; medial, intermediate, and lateral cuneiform; and cuboid bones with some bone loss and extensive soft tissue loss in the left leg.



**Fig. 2.** The separated scapula was implanted at the defect.

in performing daily activities involving his left shoulder. After 6 months, the patient was able to wear shoes and walk without support, and radiographs confirmed bone union. At a 14-month follow-up examination, no clinical



**Fig. 3.** An anteroposterior radiograph after reconstruction.

complications (including new ulcer, stress fracture, longitudinal flattening of the arch, or the disturbance of the range of motion at the shoulder joint) were noted (Fig. 4).

## DISCUSSION

Untreated bone defects in the midfoot may become associated with foot instability, pain, and a loss of function.<sup>1</sup> Thus, these lesions require a bone graft to avoid foot pain, instability, and late term longitudinal or transverse flattening of the arch.<sup>2</sup> Furthermore, a vascularized bone graft will enable faster healing, reduce the risk of subsequent fracture, and enable remodeling under physiological loading.<sup>3</sup>

Segmental bone and extensive soft tissue defects, such as those that were observed in the present case, can be appropriately repaired in 1-stage reconstruction with single multicomponent vascularized flaps.<sup>4</sup> The osteocutaneous radial forearm flap, fibula flap, iliac crest flap, and scapula flap have been used in weight-bearing areas.<sup>5-7</sup> When an osteocutaneous radial forearm flap is used, it is necessary to scarify the radial artery, leaving the skin graft with a potentially undesirable appearance. A free fibula flap can provide a bone segment with a longitudinal

Arata et al. • Midfoot Reconstruction with a Scapula Flap

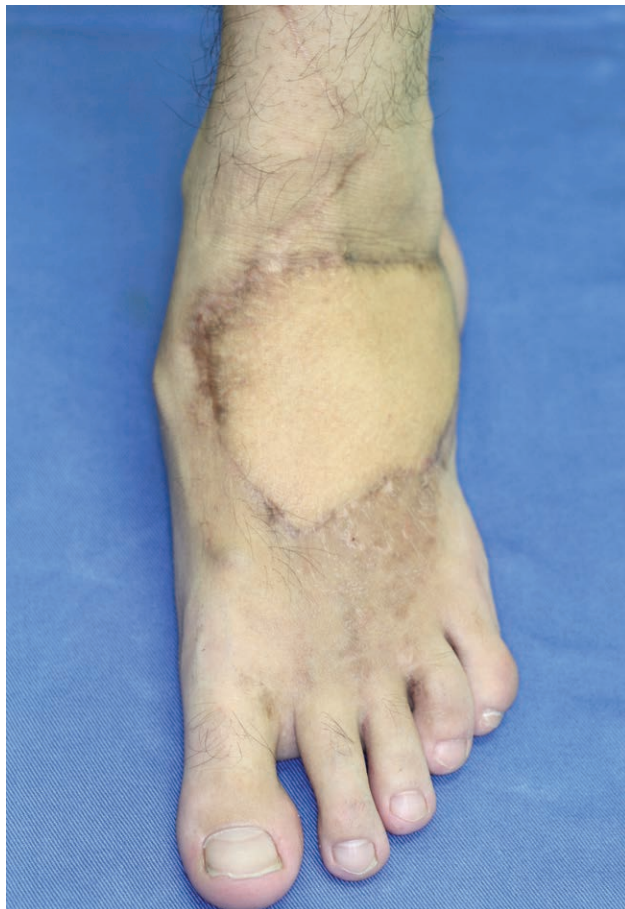

Fig. 4. A dorsal view of the left leg at 6 months after the operation.

configuration, high vascularity, and acceptable donor site appearance.<sup>8,9</sup> However, cases of donor site morbidity have been reported, including reduced ankle mobility and post-operative deformation of the big toe.<sup>6</sup> For lower extremity reconstruction, it is necessary to use the opposite leg to obtain an adequate pedicle, which may make rehabilitation more difficult.<sup>8</sup> The possibility of ongoing peripheral arterial occlusive disease must also be considered because it is necessary to scarify the peroneal artery. The iliac crest flap has an inconstant donor site anatomy and short vascular pedicle and often has a thick layer of subcutaneous fat. In the present case, a large amount of bone was not needed and the patient was relatively young. We chose a partial scapula and skin flap for reconstruction, considering the cosmetic aspect at the donor site. Furthermore, the scapula and skin were fed by different branches of the circumflex scapular artery. Thus, the skin flap could be rotated and easily placed to resurface the wounds.

Seromas are not uncommon at the donor site, but can be managed with intraoperative hemostasis and prolonged

drainage.<sup>10</sup> Problems such as abduction or rotation of the upper arm may occur after the operation. Early activity at the donor site can reduce their occurrence.<sup>2</sup> Compared with other composite flaps used for lower extremity reconstruction, the strength of the scapula is controversial. However, the scapula has a greater amount of cancellous bone than the fibula, and may resist stress fracture after bone union.<sup>10</sup>

In critical areas, such as the dorsal foot, we believe that the selection of flaps with robust, well-vascularized bone in combination with a thin skin paddle is mandatory to allow for full weight bearing, walking without restriction, and the wearing of regular shoes. The use of a chimeric partial scapula and skin flap provides vascularized bone to stabilize the midfoot and can resurface large midfoot wounds, making it a viable alternative to other commonly used flaps.

Jun Arata, MD, PhD

Department of Plastic and Reconstructive Surgery  
National Hospital Organization Kyoto Medical Center  
1-1 Mukaihatacho, Fukakusa Fusimiku  
Kyoto 612-8555, Japan  
E-mail: j-arata@bu.ij4u.or.jp

#### REFERENCES

1. Gomez MM, Casal D. Reconstruction of large defect of foot with extensive bone loss exclusively using a latissimus dorsi muscle free flap: A potential new indication for this flap. *J Foot Ankle Surg.* 2012;51:215–217.
2. Chen CC, Lin CH, Lin YH. Chimeric partial scapula and latissimus dorsi muscle flap for midfoot reconstruction: A case report. *Microsurgery.* 2012;32:485–488.
3. Houdek MT, Wagner ER, Wyles CC, et al. New options for vascularized bone reconstruction in the upper extremity. *Semin Plast Surg.* 2015;29:20–29.
4. Huang WC, Chen HC, Wei FC, et al. Chimeric flap in clinical use. *Clin Plast Surg.* 2003;30:457–467.
5. Clements JR, Mierisch C, Bravo CJ. Management of combined soft tissue and osseous defect of the midfoot with a free osteocutaneous radial forearm flap: A case report. *J Foot Ankle Surg.* 2012;51:118–122.
6. Ozger H, Akgül T, Eren I, et al. Midfoot reconstruction with free vascularized fibular graft after wide resection: A case report. *Acta Orthop Belg.* 2011;77:702–706.
7. Wu K, Ren D, Hou S, et al. Vascularized iliac osteomuscular free flaps for composite soft tissue and bone defects of the lower extremity. *Ann Plast Surg.* 2009;63:53–58.
8. Chai YM, Wang CY, Zeng BF, et al. Peroneal artery perforator chimeric flap for reconstruction of composite defects in extremities. *Microsurgery.* 2010;30:199–206.
9. Wei FC, Seah CS, Tsai YC, et al. Fibula osteoseptocutaneous flap for reconstruction of composite mandibular defects. *Plast Reconstr Surg.* 1994;93:294–304; discussion 305.
10. Tachi M, Toriyabe S, Imai Y, et al. Versatility of chimeric flap based on thoracodorsal vessels incorporating vascularized scapular bone and latissimus dorsi myocutaneous flap in reconstructing lower-extremity bone defects due to osteomyelitis. *J Reconstr Microsurg.* 2010;26:417–424.