



Anesthetic (r)evolution from the conventional concept to the minimally invasive techniques in thoracic surgery – narrative review

Zsolt Szabo¹, Csongor Fabo², Adam Oszlanyi³, Fatime Hawchar², Tibor Géczi⁴, Judit Lantos⁵, Jozsef Furák⁴

¹Tritonlife Szeged Hospital, Szeged, Hungary; ²Department of Anesthesiology and Intensive Care, University of Szeged, Szeged, Hungary;

³Department of Cardiac Surgery, Zala County St. Raphael Hospital, Zalaegerszeg, Hungary; ⁴Department of Surgery, University of Szeged, Szeged, Hungary; ⁵Department of Neurology, Bács-Kiskun County Hospital, Kecskemét, Hungary

Contributions: (I) Conception and design: Z Szabo, C Fabo, A Oszlanyi; (II) Administrative support: J Lantos; (III) Provision of study materials or patients: All authors; (IV) Collection and assembly of data: F Hawchar, T Géczi; (V) Data analysis and interpretation: Z Szabo, C Fabo, A Oszlanyi; (VI) Manuscript writing: All authors; (VII) Final approval of manuscript: All authors.

Correspondence to: Zsolt Szabo. 25 Mikes Kelemen str, Makó, 6900, Hungary. Email: szabozsolt4@gmail.com.

Background and Objective: Thanks to the growing experience with the non-intubated anesthetic and surgical techniques, most pulmonary resections can now be performed by using minimally invasive techniques. The conventional method, i.e., surgery on the intubated, ventilated patient under general anesthesia with one-lung ventilation (OLV) was considered necessary for the major thoracoscopic lung resections for all patients. An adequate analgesic approach (regional or epidural anesthesia) allows video-assisted thoracoscopy (VATS) to be performed in anesthetized patients and thus the potential adverse effects related to general anesthesia and mechanical OLV can be minimized.

Methods: Multiple medical literature databases (PubMed, Google Scholar, Scopus) were searched, using the terms [(non-intubated) OR (nonintubated) OR (tubeless) OR (awake)] AND [(thoracoscopic surgery)] from 2004 to December 2021. Thirty hundred and six scientific papers were collected. The editorials, commentaries, letters, and papers were excluded, that focus on other than the non-intubated (aka awake or tubeless) VATS technique, as well as the full text scientific papers available in languages other than English.

Key Content and Findings: After reviewing the literature, we identified “schools” with different techniques but with very similar results. Most of the differences were in the anesthetic technique, oxygenation and analgesia, however, the immunological results, and the qualitative parameters (inpatient hospital care days, complication rate, mortality) of the perioperative period showed great similarity, in addition, all three schools identified the same risk factors (hypoxia, hypercapnia, airway safety). The combination of spontaneous ventilation with double lumen tube intubation, called VATS-spontaneous ventilation with intubation (SVI) method seems to be suitable for reducing these risk factors, which may serve as an alternative for patients not suitable for the non-intubated technique in the near future.

Conclusions: Based on the results, non-intubated thoracic surgery appears to be an increasingly widespread, safe procedure, that will be available to a wider range of patients as experience expands and by the implication of the constantly evolving new processes.

Keywords: Intubation; double-lumen tube; spontaneous breathing (SB); non-intubated video-assisted thoracoscopic surgery (NIVATS)

Submitted Jan 18, 2022. Accepted for publication Jul 16, 2022.

doi: 10.21037/jtd-22-80

View this article at: <https://dx.doi.org/10.21037/jtd-22-80>

Introduction

In the field of surgical techniques, the last 20 years were dominated by the development of minimally invasive techniques and the methods for major pulmonary resections were no exceptions to that (1). Since the first series of thoracoscopy cases by Jacobaeus in 1921, video-assisted thoracoscopy (VATS) has become a widespread and well-established diagnostic and therapeutic tool in thoracic surgery (2). In the surgical aspect, the VATS technique combines the good exposure of the pleural cavity, and the possibility of an extensive dissection with the advantages of minimally invasive intervention, resulting in reduced tissue trauma, shorter recovery times, reduction of morbidity, improvement of pulmonary function parameters, reduced pain, and smaller scars (3).

The patients undergoing the first thoracotomies were mildly anesthetized and they were breathing spontaneously, however, the outcome of these procedures was unfavorable. Soon after the invention of the endotracheal tube by Guedel in 1928, the idea of advancing it into the main bronchus of the healthy lung arose in order to avoid the ventilation of the surgical site, thus the one-lung ventilation (OLV) technique was born (1,4). OLV was combined with mechanical ventilation after its appearance in the 1960s. In addition, a multimodal technique including the blockade of the phrenic, and vagus nerves (in the neck), and an extensive intercostal nerve blockade, combined with lung hilum block was introduced by Vischnevski, which allowed him the performance of hundreds of major lung surgeries. The method was followed by Ossipov applying a similar technique (2).

Around the turn of the millennium, general anesthesia was used for the major thoracic surgical procedures such as lobectomy, however, epidural anesthesia in itself was sufficient for carrying out minor surgical interventions. The functional separation of the lungs by OLV is performed under general anesthesia and muscle relaxation. OLV is achieved by either the proper placement of a double lumen tube (DLT) or the use of a bronchial blocker. As every invasive procedure, general anesthesia and endobronchial intubation have adverse effects, such as the intubation-related trauma, an increased risk of pneumonia, ventilator-associated lung injury (VALI), impaired cardiac performance, negative effects of the neuromuscular blocking agents (NMBAs), and postoperative nausea and vomiting. A somewhat lesser-known fact is that general anesthesia and especially OLV combined with surgical stress

and extensive tissue trauma negatively affect the response lymphocytes and natural killer population, which play a key role against tumors and infections thanks to their cytotoxic activity (5).

Approximately 10 years ago, there were successful attempts for minimal sedation in major thoracic surgical cases (1,6), as one-lung spontaneous ventilation is more physiological than controlled mechanical ventilation: a European cohort study of 22,803 surgical patients showed that the use of NMBAs during anesthesia was associated with an increased risk of postoperative pulmonary complications irrespective of dose (7).

From the anesthesiologist's point of view, the evolution of surgical techniques opens the possibility to avoid the use of intubated general anesthesia by maintaining spontaneous ventilation together with mild sedation. Gonzalez-Rivas *et al.* published the first report of a single-port thoracoscopic major pulmonary resection in a patient with spontaneous ventilation (non-intubated surgery) in 2014 (8). Since then, the evolution of non-intubated thoracic surgery made it possible to carry out more elaborate operations despite the different severe pathological conditions in some patients, and non-intubated surgery was found to be a minor trigger of inflammation resulting in better preservation of the immunological function compared to the intubated methods performed under general anesthesia and muscle relaxation (9). In cases of surgical difficulties emerging during non-intubated video-assisted thoracoscopic surgery (NIVATS), surgical conversion to thoracotomy was reported to be successful by Furák *et al.*, while maintaining the patient's non-intubated state (NIS) (10).

Non-intubated procedures, however, may worsen pulmonary ventilation and gas exchange as the patient might move, cough, and produce unintentional movements, causing e.g., a mediastinal shift, which can make the intervention difficult and challenging (11).

To exclude the disadvantages of non-intubated VATS, a new technique, spontaneous ventilation combined with double-lumen tube intubation was introduced by Furák and Szabó in 2021 (12).

Our review aims to provide a summary of the literature available on anesthesia for minimally invasive thoracic surgery.

Basic principles of spontaneous breathing (SB)

The physiology of respiration is a complex mechanism based on the interaction between the chest wall and the

lungs through the contacting layers of the pleura. The basic physical driving force is the pressure gradient generated by the respiratory muscles, the elastic components of the chest wall, and the lungs between the alveolar pressure and the atmospheric pressure. This gradient results in an airflow between the alveolar space and the outer environment. Gas exchange takes place in the alveoli (13).

In the intraoperative settings due to the use of anesthetics, analgesics, and NMBAs, the respiratory drive and respiratory muscle strength may be significantly altered, or in most cases completely extinguished, requiring the ventilator to apply positive pressure to generate an adequate airflow. In summary, the pressure difference across the respiratory system, regardless of its source, is essential (14). This pressure difference (gradient) is determined by the following universal equation:

$$P_{ao} + P_{mus} = PEEP + (E_{rs} \times V) + (R_{rs} \times Flow) \quad [1]$$

In this equation P_{ao} represents the pressure at the airway opening and P_{mus} is the pressure generated by respiratory muscles. Positive end-expiratory pressure (PEEP) is positive end-expiratory pressure, E_{rs} is the respiratory system elastance and R_{rs} is the resistance of the respiratory system, V stands for tidal volume, and $Flow$ means the airflow (15).

As the pressure gradient, elastance (or the inverse of elastance, the compliance), tidal volume, resistance, and the airflow determine ventilation, these parameters should be monitored carefully and continuously during mechanical ventilation (14,16).

Pathophysiology

Several factors influence the ventilation-perfusion matching during a thoracic surgical procedure. Before the surgical incision, the patients are anesthetized and are moved to the lateral decubitus position which have a marked effect on the respiratory physiology. In awake patients, the lateral decubitus position has only a moderate effect on the ventilation-perfusion ratio (V/Q), as the greater perfusion of the dependent lung (due to the gravitational effect) is balanced by improved ventilation, achieved by the more effective contraction of the dependent hemidiaphragm, and by the fact that the dependent lung is on a more favorable part of the compliance curve. A decrease in functional residual capacity (FRC) occurs by induction of anesthesia, resulting in a shift on the compliance curve, so the dependent lung lies on a less, while the nondependent

lung lies on a more favorable part of the compliance curve, with unchanged perfusion. Thus, induction of anesthesia together with the lateral decubitus position can lead to a ventilation-perfusion mismatch. With the use of NMBAs, the normal diaphragmatic excursion is eliminated, thus the above-described effects can be augmented.

By the surgical incision, surgical pneumothorax (defined as open pneumothorax) develops, which has potentially troublesome pathophysiological consequences in a spontaneously breathing patient: mediastinal shifting and paradoxical respiration (pendelluft), may lead to hypoxemia and hypercapnia.

Ventilation-perfusion mismatch leads to a right-to-left transpulmonary shunt. Shunt fraction can be defined as the proportion of the total pulmonary blood flow that does not take part in gas exchange. Transpulmonary right-to-left shunting of 6–10% of cardiac output is a physiologically existing, anatomical phenomenon, arising mainly from the bronchial and the Thebesian veins and pathways (17).

In most cases OLV is mandatory for optimal view and appropriate accessibility for the surgical field and during mechanical OLV only the dependent lung is ventilated while the nondependent lung is excluded from the gas exchange with lower perfusion. This can lead to as high a shunt fraction as 20–30%, that understandably decreases the arterial oxygen content, as a higher fraction of the cardiac output is passed through from right to left without gas exchange. The elevated shunt fraction has another really important effect on oxygenation, that can be read from the Nunn's iso-shunt diagram, namely, as the shunt fraction increases, an increase in the fraction of inhaled oxygen (FiO_2) can exert a lower arterial oxygen content elevating effect (18,19).

This condition is known to be intolerable in the long term, and would lead to severe hypoxemia. A compensation mechanism, described by Euler and Liljestrand in 1946, called hypoxic pulmonary vasoconstriction (HPV) is liable for the pulmonary arterial vasoconstriction in response to low alveolar oxygen tension (20,21). In the pulmonary artery smooth muscle cells (PASMCs), the resting membrane potential is maintained by outward potassium current, which is inhibited in a hypoxic environment, leading to membrane depolarization, and the opening of the calcium channels, that would result in an elevation in the cytoplasmic Ca^{2+} level, finally causing contraction of the pulmonary arteries (22–24).

HPV helps to divert blood from the nondependent (non-ventilated) lung fields to the dependent areas in a fast-

acting, biphasic manner. HPV activates seconds after the hypoxic stimuli and has its maximum effect in minutes, helping to decrease the transpulmonary right-to-left shunting, optimizing the oxygen delivery and restoring the ventilation-perfusion matching. Until vascular remodeling occurs, HPV is reversible, after a short hypoxic episode, HPV disappears on re-oxygenation, PVR and blood flow restore quickly. When normoxia is restored after a short hypoxic phase (<20 min), the HPV declines and PVR normalizes as pulmonary blood flow increases in the re-oxygenated areas. In contrast, after a prolonged period of hypoxia, the HPV only disappears after several hours despite full re-oxygenation, resulting in greater ventilation-perfusion (V/Q) mismatch and consequently larger alveolar-to-arterial O₂ pressure gradient (A-aPO₂). However, after a longer hypoxic period, HPV disappears completely only after hours of re-oxygenation (25-27).

Adequate HPV is inevitable for minimizing the perfusion of the dependent lung, and optimizing the shunt, and because of these factors, attenuating the effect of HPV should be avoided. HPV is influenced by several factors like demographic parameters, medications (analgesics, cardiovascular drugs, and anesthetic agents), acid-base balance, lung disease, and the degree of lung expansion. Mechanical ventilation is a double-edged sword as it has indisputable advantages in several cases, although it can also be harmful. Mechanical OLV and high positive airway pressures [PEEP, auto-PEEP, peak inspiratory pressure (PIP)] can indirectly worsen ventilation-perfusion matching by diverting blood flow from the ventilated lung fields to the nondependent areas (23,28,29).

Despite its benefits, mechanical ventilation can cause structural lung damage. The potential harmfulness of mechanical ventilation was observed as early as in 1744 by John Fothergill, and later, during the polio epidemic in 1967, and the topic played a central role, postmortem investigations described structural lung damage, hyaline membrane formation, and diffuse alveolar infiltrates and the term “respirator lung” was created (30-32). Determining the optimal ventilator setting is more than challenging, as on low tidal volumes, lung inhomogeneity and atelectotrauma are potential risk factors to be considered, while on high tidal volumes, overdistension and barotrauma are the matter of concern (33,34). Both scenarios have structural consequences, causing biological alterations, and physiological abnormalities and resulting in systemic effects. Ventilator-induced lung injury is mediated by inflammatory

cell infiltration, hyaline membrane deposition, increased capillary permeability, and pulmonary edema. These changes lead to alteration of respiratory physiology and gas exchange (35,36).

SB has several advantages but we should not forget that breathing efforts can worsen the lung injury by several ways. Patient-ventilator asynchrony is not rare and can result in patient distress, uncontrolled inspiratory effort and can potentiate lung injury by volutrauma and barotrauma (37-39). Due to the cyclic opening of the smaller airways, atelectotrauma may develop with regional atelectatic lung fields, and increased heterogeneity of ventilation (40). The increased alveolo-capillary pressure gradient potentially leads to interstitial edema (38,41).

Postoperative systematic inflammation response (SIR) can affect the clinical picture. Based on the changes in the cellular defense and cytokine levels SIR period can take for around 3–12 days, but it affects not only on the early postoperative morbidity, but also the 30-day mortality (9,42,43). Regarding the early postoperative morbidity, the reduced levels and functions of lymphocytes and NK cells can cause diminished cellular defense ability. This can manifest as postoperative pneumonia, wound infection, or other inflammation response. Postoperative pneumonia rates were 5% and 10%, and wound infection rates were 0.4% and 1% after VATS and open lobectomies (44). Postoperative morbidity is lower (5%) than in relaxed surgery cases (23%) (42). Generally due to less pro-inflammatory response, some postoperative morbidities can be reduced further during NIVATS, the postoperative fasting time, drainage time, and hospital stay were shorter than those in relaxed VATS cases (45). Furthermore better compliance with adjuvant chemotherapy was found after non-intubated VATS lobectomies than after relaxed VATS lobectomies, with less toxicity, and more patients (92%) could receive the adjuvant chemotherapy protocol, compared with 72% in relaxed surgery cases (46).

The paradigm shift and the development of minimally invasive techniques that has taken place in recent years allowed us to maintain the patient's SB during a thoracic procedure. Be it the increasingly popular non-intubated thoracic surgeries (NITS) or the recently introduced spontaneous ventilation with intubation (SVI) method. It seems that the advantages of the maintained SB can overcome concerns (47,48). We present the following article in accordance with the Narrative Review reporting checklist (available at <https://jtd.amegroups.com/article/>

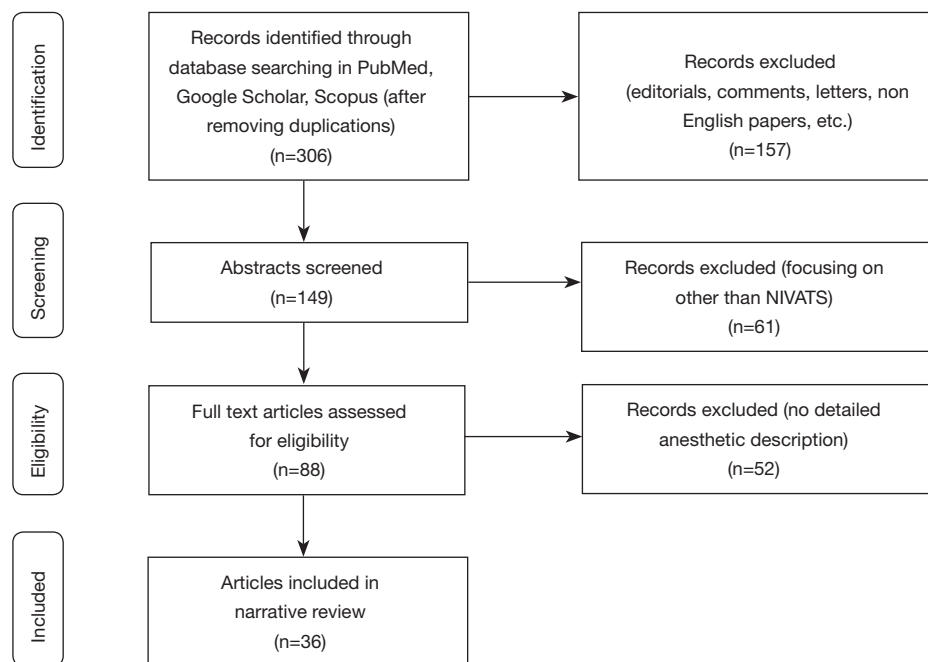


Figure 1 Flowchart of article selection. NIVATS, non-intubated video-assisted thoracoscopic surgery.

view/10.21037/jtd-22-80/rc).

Methods

Multiple medical literature databases (PubMed, Google Scholar, Scopus) were searched, using the terms [(non-intubated) OR (nonintubated) OR (tubeless) OR (awake)] AND [(thoracoscopic surgery)] as well as their Medical Subject Headings (MeSH) terms from 2004 to December 2021. Three hundred and six scientific papers were collected. The editorials, commentaries, letters were excluded and papers focusing on other than the non-intubated (aka awake or tubeless) VATS technique, as well as the full text scientific papers available in languages other than English. The selection process is illustrated in the *Figure 1* and summarized in *Table 1*. The findings of these articles are shown in *Table 2*.

Results

Conventional approach

Since the 1950s, when double-lumen tubes were invented and introduced into thoracic anesthesia by Carlens and Bjork, intubated general anesthesia with muscle relaxation, intubation, and controlled, positive pressure OLV has

become the gold standard in thoracic surgery. Another less popular alternative for lung isolation is the use of bronchial blockers. Since the 1980s, new types of BBs have emerged in clinical practice, and their positioning has become simplified when advanced under fiberoptic guidance (69,70).

This classic anesthetic technique has several well-known detrimental effects. Beyond the obvious disadvantages, such as the greater risk of airway trauma among the intubated patients, the technique has other drawbacks as well. In the “Post-anaesthesia pulmonary complications after use of muscle relaxants” (POPULAR) study, Kirmeier *et al.* showed that the use of NMBAs is associated with an increased incidence of postoperative pulmonary complications. Surprisingly, this study found that neither neuromuscular monitoring nor reversal agents reduce the incidence of postoperative pulmonary complications (7).

As already mentioned in the pathophysiology section of this article, OLV with positive pressure ventilation may worsen HPV and lead to structural damage due to the distension of the lung tissue.

The disadvantages mentioned above have led to the emergence of less invasive methods in thoracic anesthesia. There are numerous tubeless, awake, non-intubated anesthetic options accessible today. The goal of these procedures is to prevent intubation and general anesthesia,

Table 1 The search strategy summary

Items	Specification
Date of search (specified to date, month and year)	January 3, 2022
Databases and other sources searched	PubMed, Google Scholar, Scopus
Search terms used (including MeSH and free text search terms and filters)	Search terms: non-intubated, nonintubated, tubeless, awake, thoracoscopic surgery Search strategy of PubMed: [(non-intubated) OR (nonintubated) OR (tubeless) OR (awake)] AND [(thoracoscopic surgery)]
Timeframe	From January 1, 2004 to December 31, 2021
Inclusion and exclusion criteria (study type, language restrictions etc.)	Inclusion criteria: (I) Articles languages: English (II) Article topic: the non-intubated (aka awake or tubeless) video-assisted thoracic surgery technique Exclusion criteria: (I) Article types: Editorials, Commentaries, Letters (II) Full text not available
Selection process (who conducted the selection, whether it was conducted independently, how consensus was obtained, etc.)	Two authors (Szabo and Fabo) independently conducted the selection process, assessed all the identified studies based on the eligibility criteria. Disagreements resolved by consensus after discussion
Any additional considerations, if applicable	None

as well as any of their negative consequences.

Thoracic surgery with SB

Based on the literature data preserving of SB can diminish the potential harmful effect of conventional approach. But it is very important to emphasise the SB during thoracic procedure can be dangerous due to unusual circumstances (i.e., paradoxical breathing, mediastinal movement) that's why the application of NIVATS in the training programs of the professional perioperative teams is essential to ensure maximal patient safety and comfort for the teams (71,72).

After reviewing the literature, we identified different methods with very similar clinical results. Theirs main characteristics, advantages, limitations, exclusion criteria and indications for conversion are summarized in *Tables 3-5*.

The Italian technique

From the early 2000s, Pompeo and Mineo, two Italian researchers at Tor Vergata University, started to investigate their awake method. In the beginning, they used local and thoracic epidural anesthesia without sedation during VATS wedge resection of small pulmonary nodules (49). They

provided oxygen supplementation via face masks. It was found to be safe and feasible with better patient satisfaction, less nursing care, and shorter hospital stays. Through the years, the feasibility of this awake technique has been proven for increasingly complex VATS procedures (lung volume reduction surgeries, decortication, and bullectomy). Besides the fact that all of their studies have found the technique to be feasible, further advantages have also been proven, such as the shorter operating room times, reduction of costs, less immunological and stress responses, and shorter air leak duration in the postoperative period. Their approach has evolved from awake to midazolam- or remifentanyl based, bispectral index (BIS)-guided, mildly sedated states over time, and thoracic epidural analgesia (TEA) was replaced with intercostal blockade. In order to obtund the cough reflex, Guarracino and Mineo used an aerosolized local anesthetic (lidocaine) (42,49,51-53,55,73-76).

The Hungarian technique

The previously introduced techniques have shown many advantages and disadvantages during the thoracic procedures. The ever-growing experience has allowed us to perform increasingly difficult procedures, which

Table 2 Characteristics and key findings from most relevant articles on non- intubated surgery

Authors	DOI	Year	Number of patients	Study design	Context	Level of sedation	Drugs for sedation	Type of analgesia	Conversion rate	Key findings
Pompeo <i>et al.</i> (49)	10.1016/j.athoracsur.2004.05.083	2004	60 patients, 30 awake, 30 GA-OLV	RCT	Resection of small nodules	Awake	None	TEA	4%	Safe, feasible, better patient satisfaction, less nursing care and shorter stay
Al-Abdullatif (50)	10.1016/j.ejcts.2007.04.029	2007	79	Observational study	Various including thoracotomy, sternotomy	Light sedation	Midazolam, fentanyl	TEA	1%	Safe and feasible even with major procedures
Vanni <i>et al.</i> (51)	10.1016/j.athoracsur.2010.04.070	2010	50 patients, 25 NITS, 25 GA-OLV	RCT	Various minor-intermediate procedures	Awake	None	TEA	NR	Lesser impact on postoperative lymphocyte responses
Tacconi <i>et al.</i> (52)	10.1510/icvts.2009.224139	2010	21 patients, 11 awake VATS, 10 GA-OLV	NRC	Various minor-intermediate procedures	Awake	None	TEA	NR	Decreased stress response
Pompeo <i>et al.</i> (53)	doi:10.1016/j.ejcts.2010.11.071	2011	60 patients, 41 awake, 19 non awake	NRC	Nonresectional lung volume reduction surgery	Awake	None	TEA	2%	Better perioperative outcome, shorter hospital stay, and lower costs
Chen <i>et al.</i> (54)	10.3978/j.issn.2072-1439.2012.08.07	2012	285	CS	Various (lobectomy, segmentectomy, wedge resection)	Ramsay III	Fentanyl, Propofol	TEA	4.9%	Optimal feasibility
Pompeo <i>et al.</i> (55)	10.1016/j.jitcvs.2011.09.050	2012	63 patients, 32 awake, 31 GA	RCT	Nonresectional lung volume reduction surgery	Awake	None	TEA	2%	Shorter hospital stay
Hung <i>et al.</i> (56)	10.1093/ejcts/ezu054	2014	109	Cohort study	Lobectomy, segmentectomy, wedge resection, tumor excision	BIS: 40-60	Propofol, fentanyl	ICB	2.8%	Technically feasible and safe
Hung <i>et al.</i> (57)	10.1097/MD.00000000000000727	2015	238	Cohort study	VATS lobectomy	BIS: 40-60	Propofol, fentanyl	TEA or ICB	5.5%	Both group feasible and safe, improved haemodynamic stability and less intraoperative complications in ICB group

Table 2 (continued)

Table 2 (continued)

Author	DOI	Year	Number of patients	Study design	Context	Level of sedation	Drugs for sedation	Type of analgesia	Conversion rate	Key findings
Mineo et al. (5)	10.2217/fo-2016-0348	2016	1,000	CS	Various	BIS	NR	ICB, TEA	96%	Safe and feasible
Mineo et al. (42)	10.3390/ijms18071466	2017	68 patients, 55 NITS, 13 GA-OLV	NRC	VATS metastasectomy	Light sedation	midazolam or remifentanyl +/- propofol	ICB	NR	Less immunological and inflammatory response
Wang et al. (58)	10.1093/ejcts/ezx450	2018	60 patients, 30 THRIVE, 30 maszk	NRC	VATS wedge resection, segmentectomy, lobectomy	BIS 40–60	Fentanyl, propofol	ICB	0%	Higher arterial oxygen tension with nasal high-flow oxygen therapy during OLV
Mineo, Ambrogi (9)	10.21037/vats.2018.01.02	2018	984 patients, 878 NITS, 106 GA-OLV	NRC	Various uniportal VATS procedure	BIS	Midazolam, remifentanyl, propofol	ICB	NR	Lower impact on immunological response, shorter hospital stay, influence on long-term survival (malignant pleural effusion subgroup)
Liu et al. (59)	10.21037/jtd.2018.05.119	2018	36	CS	Uniportal tubeless VATS wedge resection	BIS	Midazolam, alfentanil, propofol	TEA	5% to intercostal drainage	Safe in selected patients
Hung et al. (60)	10.1016/j.athoracsur.2019.01.013	2019	1,025	CS	VATS wedge resection, segmentectomy, lobectomy/ bilobectomy	BIS 40–60	Fentanyl, propofol	TEA, ICB	20% (2%)	Safe and feasible
Li et al. (61)	10.1590/1414-431X20198645	2020	57	Cohort study	Wedge resection, segmentectomy, lobectomy, sympathectomy, mediastinal tumor removal	BIS 40–60	Dexmedetomidin, remifentanyl, propofol	ICB, PVB	1%	Safe and feasible
Furák et al. (46)	10.1111/1759-7714.13672	2020	66 patients, 28 NITS, 38 GA-VATS	NRC	Uniportal VATS lobectomy	BIS: 40–60	midazolam, fentanyl, propofol	ICB	NR	Improved adjuvant chemotherapy compliance and lower toxicity rates

Table 2 (continued)

Table 2 (continued)

Author	DOI	Year	Number of patients	Study design	Context	Level of sedation	Drugs for sedation	Type of analgesia	Conversion rate	Key findings
Furák <i>et al.</i> (10)	10.21037/jtd-19-3830	2020	160	CS	Various including thoracotomy	BIS: 40–60	midazolam, fentanyl, propofol	ICB	3%	Major lung resections can be performed safely
Liu <i>et al.</i> (62)	10.1016/j.athoracsur.2020.06.058	2021	43	NRC	Uniportal VATS segmentectomy	Ramsay III	Fentanyl, propofol	ICB	0%	Safe and feasible
Liu <i>et al.</i> (63)	10.1016/j.jfma.2020.03.021	2020	94 patients, 32 uniportal NITS, 62 multiportal VATS	NRC	Uniportal VATS segmentectomy	BIS 40–60	Fentanyl, propofol	ICB	0%	Safe and feasible
Liu <i>et al.</i> (64)	10.1093/ejcts/ezaa061	2020	135	CS	Uniportal tubeless VATS wedge resection	BIS 40–60	Midazolam, alfentanil, propofol	TEA/ICB	13+3% to intercostal drainage	Safe in selected patients
Hsu <i>et al.</i> (65)	/doi.org/10.1111/resp.13819	2020	5	CS	Uniportal non-intubated electromagnetic-guided localization and resection of small - indeterminate peripheralpulmonary nodules	BIS 40–60	Midazolam, alfentanil, propofol	TEA/ICB		Uniportal Non-intubated electromagnetic-guided localization and resection of small - indeterminate peripheral pulmonary nodules
Ke <i>et al.</i> (66)	10.1097/JCMA.0000000000000408	2020	150 patients, 81 NITS, 79 GA-OLV	NRC	VATS wedge resection	BIS 40–60	Midazolam, alfentanil, propofol	TEA	0%	Shorter hospital stay, shorter chest tube retention time, reduced intraoperative blood loss, higher intraoperative PaO ₂ level
Hung <i>et al.</i> (67)	10.1016/j.jfma.2021.03.029	2022	81 patients, 17 NITS, 64 GA-OLV	NRC	Penumothorax, wedge resection in children	BIS 40–60	Fentanyl, propofol or sevoflurane/desflurane	ICB	0%	Shorter hospital stay

Table 2 (continued)

Table 2 (continued)

Author	DOI	Year	Number of patients	Study design	Context	Level of sedation	Drugs for sedation	Type of analgesia	Conversion rate	Key findings
Hsu et al. (68)	10.1016/j.jtc.2021.09.032	2021	47 patients, 21 non-intubated, 25 intubated	NRC	Uniportal non-intubated electromagnetic-guided localization and resection of pulmonary nodules	BIS 40–60	Midazolam, alfentanil, propofol	TEA/ICB		Lower pH and pO ₂ levels, higher pCO ₂ levels and shorter operating room time in NITS group. No difference in postop recovery. Uniportal non intubated VATS with electromagnetically guided percutaneous localization is feasible for small lung nodules

GA, general anesthesia; OLV, one-lung ventilation; RCT, randomized controlled trial; TEA, thoracic epidural anesthesia; NITS, non-intubated thoracic surgeries; NR, not reported; VATS, video-assisted thoracic surgery; NRC, non-randomized comparison; CS, case series; BIS, bi-spectral index; BIS, bi-spectral index; PVB, paravertebral block.

required the same anesthetic abilities than during the intubated thoracic surgeries, such as the intraoperative re-insufflation of the lung or performing bronchoscopy. Furák and Szabó *et al.* have presented a mixed technique using the laryngeal mask with targeted propofol sedation—guided by the bispectral index scale-, which allowed to perform these intraoperative procedures and other complicated surgical treatments, such as conversion to thoracotomy or complicated sleeve resections (77).

The same workgroup published a new method, called VATS-SVI, which combined the positive physiological effects of SB with those of the gold standard technique applying double-lumen tube intubation and providing safe airway. Anesthetic management for VATS-SVI has been described previously (11). Briefly, patients received premedication with midazolam and fentanyl. Induction and maintenance of anesthesia was guaranteed by propofol target controlled infusion dosed to reach a BIS value between 40 to 60.

They found better intraoperative cardiopulmonary stability and similar postoperative results of spontaneous ventilation combined with intubation than non-intubated thoracic surgery (12,78). According to this paper, the duration of mechanical ventilation could be reduced by 76.6%, preserving all the beneficial effects of NITS. From the non-surgical aspects, Furák *et al.* have found advantages among oncological patients. Among the non-intubated patients, 92% completed the planned chemotherapy protocol, compared to 71% of patients in the intubated group. These results showed that the non-intubated procedure resulted in improved adjuvant chemotherapy compliance and lower toxicity rates after lobectomy (46).

The Asian technique

Asian researchers, in parallel with the work of their European colleagues, developed their own method, which differed from that of the Italians in several aspects. The pioneers of these studies applied intravenous propofol anesthesia with a target-controlled infusion system, depth of anesthesia monitoring, and targeted sedation maintaining a BIS value between 40 and 60 during their non-intubated anesthetic procedure. In the beginning, TEA was performed, but later they switched to the intercostal nerve blockade for its simplicity, safety, and providing better hemodynamic stability (54,56,57). In order to prevent coughing, intrathoracic vagal blockade was routinely applied. With their approach, intubation could be avoided in the course of major surgeries such as segmentectomy,

Table 3 Cornerstones of anesthetic management in thoracic surgery

Methods	Type of operation	Airway	Level of sedation	Drugs for sedation	Type of analgesia	Advantages	Limitations
Conventional method		DLT, BB	BIS 40–60	Propofol/volatile anesthetic agents+ muscle relaxant	TEA	Safe airway Isolated lungs Possibility of fibroscopy Possibility of intraoperative lung recruitment	Intubation trauma Muscle relaxation Hemodynamic consequences of TEA
Italian method	NIVATS	Facemask/ (LMA)	Awake, mild sedation (BIS guided)	None, then midazolam, remifentanyl	TEA/ICB + Aerosolized lidocaine	No muscle relaxation Maintained spontaneous breathing	No safe airway
Asian method	NIVATS	Facemask/ THRIVE	BIS 40–60	Propofol	TEA/ICB + vagal blockade	No muscle relaxation Maintained spontaneous breathing	No safe airway
Hungarian method	NIVATS	LMA	BIS 40–60	Midazolam, fentanyl, propofol	ICB, PVB + vagal blockade	No muscle relaxation Possibility of intraoperative. lung recruitment	Semi-safe airway
	VATS-SVI	DLT	BIS 40–60	Midazolam, fentanyl, propofol	ICB, PVB + vagal blockade	Safe airway Spontaneous breathing after elimination of muscle relaxant Isolated lungs Possibility of fibroscopy Possibility of intraoperative lung recruitment Higher BMI limit (<32)	Intubation trauma Increased airway resistance
Other method (Al-Abduallatief)	NIVATS	Facemask	Light sedation	Midazolam, fentanyl	TEA + Stellate ganglion blockade	No muscle relaxation Maintained spontaneous breathing	No safe airway No DOA monitoring

DLT, double lumen tube; BB, bronchial blocker; TEA, thoracic epidural anesthesia; NIVATS, non-intubated video-assisted thoracoscopic surgery; LMA, laryngeal mask airway; BIS, bi-spectral index; ICB, intercostal block; VATS-SVI, video-assisted thoracoscopic surgery with spontaneous ventilation combined with double-lumen tube intubation; THRIVE, transnasal humidified rapid-insufflation ventilatory exchange; PVB, paravertebral blockade; BMI, body mass index; DOA, depth of awareness.

and lobectomy, not only during the VATS procedures, but also during thoracotomies and even in sternotomies (62). The way of oxygen supplementation has also changed from using face masks to transnasal humidified rapid-insufflation ventilatory exchange (THRIVE) devices due to the larger oxygen reserve during OLV (54,58,62).

Their results proved this method to be safe, feasible, even in the elderly and in children. However, obese patients

whose BMI exceeds 25 kg/m² are not optimal candidates for NITS due to the excessive mediastinal movements and have a higher risk of conversion to intubated anesthesia (59-61,63-68,79,80).

Other technique

Besides the Italian and Asian approaches, other modifications to the NITS procedure have also been developed. Al-Abdullatief *et al.* from Saudi Arabia performed major operations, such as lobectomy and thymectomy, in awake or mildly sedated individuals. After iv. midazolam–fentanyl premedication thoracic epidural anesthesia was done and the ipsilateral stellate ganglion was blocked to diminish the cough reflex (50).

Conclusions

NIVATS can be a safe and acceptable method for performing minor or even major pulmonary resections. Patient safety is a cornerstone of the non-intubated techniques, and can be enhanced by using clear inclusion and exclusion criteria, completed with well-defined conversion strategies. The combination of regional anesthesia and intravenous sedation strategies gives the opportunity to prevent perioperative complications like hemodynamic imbalance, hypoxia, or severe hypercapnia.

Although evaluation of the long-term effects of non-

Table 4 Exclusion criteria

Exclusion criteria from non-intubated thoracic surgery
Hemodynamically unstable patients
INR >1.5, or any bleeding disorder
Sleep apnea syndrome
Anticipated difficult airway
BMI ≥30 kg/m ²
Persistent cough or high airway secretion
Elevated risk of regurgitation
Raised intracranial pressure, unable to cooperate
Procedures requiring lung isolation to protect the contralateral lung
Patient refusal

INR, international normalized ratio; BMI, body mass index.

Table 5 Indications for conversion during non-intubated surgery (main indications for conversion to thoracotomy and/or DLT intubation)

Surgical indications	Anesthetic indications
Persistent cough due to ineffective vagal block	Hypoxemia: PaO ₂ <60 mmHg, or SpO ₂ <92% on FiO ₂ : 1.0, conversion may be avoided by reinflation of the operated (non-dependent) lung
Intolerable diaphragm and mediastinal movements	Hypercapnia: if PaCO ₂ >75 mmHg, or pH <7.15, conversion may be avoided by applying low PEEP and pressure support on the circle
Extended surgery (e.g., pneumonectomy, thoracotomy)	Persistent hemodynamic instability
Bleeding	Intraoperative airway difficulties
Serious pleural adhesions	Bleeding in the airways
Large tumor size	Ineffective analgesia

DLT, double-lumen endobronchial tube; PaO₂, partial pressure of oxygen; SpO₂, oxygen saturation; FiO₂, fraction of inhaled oxygen; PaCO₂, partial pressure of carbon dioxide in artery; PEEP, positive end-expiratory pressure.

intubated techniques has to be the focus of further studies, NIVATS seems to be a feasible, safe and attractive alternative to the conventional VATS technique performed under general anesthesia (GAVATS) by preventing muscle relaxation and the use of controlled OLV method.

With the introduction of the VATS-SVI technique, a secure airway is guaranteed in parallel with the maintenance of spontaneous ventilation, moreover, a reduction in the duration of controlled ventilation and a lower incidence of perioperative pulmonary complications can be achieved. We suggest this renders the VATS-SVI approach a more attractive and feasible alternative to NIVATS, although further research is inevitable in this field to evaluate the effectiveness of the procedure.

Extensive educational programs, based on experience gained in routine thoracic procedures, are required to acquire proper knowledge and practice with NIVATS and VATS-SVI, as both of these techniques are challenging to surgeons and anesthetists as well.

Acknowledgments

Funding: None.

Footnote

Reporting Checklist: The authors have completed the Narrative Review reporting checklist. Available at <https://jtd.amegroups.com/article/view/10.21037/jtd-22-80/rc>

Peer Review File: Available at <https://jtd.amegroups.com/article/view/10.21037/jtd-22-80/prf>

Conflicts of Interest: All authors have completed the ICMJE uniform disclosure form (available at <https://jtd.amegroups.com/article/view/10.21037/jtd-22-80/coif>). The authors have no conflicts of interest to declare.

Ethical Statement: The authors are accountable for all aspects of the work in ensuring that questions related to the accuracy or integrity of any part of the work are appropriately investigated and resolved.

Open Access Statement: This is an Open Access article distributed in accordance with the Creative Commons Attribution-NonCommercial-NoDerivs 4.0 International License (CC BY-NC-ND 4.0), which permits the non-commercial replication and distribution of the article with

the strict proviso that no changes or edits are made and the original work is properly cited (including links to both the formal publication through the relevant DOI and the license). See: <https://creativecommons.org/licenses/by-nc-nd/4.0/>.

References

- Gonzalez-Rivas D, Bonome C, Fieira E, et al. Non-intubated video-assisted thoracoscopic lung resections: the future of thoracic surgery? *Eur J Cardiothorac Surg* 2016;49:721-31.
- Kao MC, Lan CH, Huang CJ. Anesthesia for awake video-assisted thoracic surgery. *Acta Anaesthesiol Taiwan* 2012;50:126-30.
- Bodner J, Wykypiel H, Wetscher G, et al. First experiences with the da Vinci operating robot in thoracic surgery. *Eur J Cardiothorac Surg* 2004;25:844-51.
- Guedel AE, Waters RM. A new intratracheal catheter. *Curr Res Anesth Analg* 1928;7:238-9.
- Mineo TC, Tamburrini A, Perroni G, et al. 1000 cases of tubeless video-assisted thoracic surgery at the Rome Tor Vergata University. *Future Oncol* 2016;12:13-8.
- Pompeo E, Sorge R, Akopov A, et al. Non-intubated thoracic surgery-A survey from the European Society of Thoracic Surgeons. *Ann Transl Med* 2015;3:37.
- Kirmeier E, Eriksson LI, Lewald H, et al. Post-anaesthesia pulmonary complications after use of muscle relaxants (POPULAR): a multicentre, prospective observational study. *Lancet Respir Med* 2019;7:129-40.
- Gonzalez-Rivas D, Fernandez R, de la Torre M, et al. Single-port thoracoscopic lobectomy in a nonintubated patient: the least invasive procedure for major lung resection? *Interact Cardiovasc Thorac Surg* 2014;19:552-5.
- Mineo TC, Ambrogio V. Immune effects after uniportal nonintubated video-thoracoscopic operations. *Video-assist Thorac Surg* 2018;3:4.
- Furák J, Szabó Z, Tánzos T, et al. Conversion method to manage surgical difficulties in non-intubated uniportal video-assisted thoracic surgery for major lung resection: Simple thoracotomy without intubation. *J Thorac Dis* 2020;12:2061-9.
- Kaseda S, Aoki T, Hangai N, et al. Better pulmonary function and prognosis with video-assisted thoracic surgery than with thoracotomy. *Ann Thorac Surg* 2000;70:1644-6.
- Furák J, Szabó Z. Spontaneous ventilation combined with double-lumen tube intubation in thoracic surgery. *Gen Thorac Cardiovasc Surg* 2021;69:976-82.

13. Sivieri EM, Bhutani VK, Introduction I. Manual of Neonatal Respiratory Care. *Man Neonatal Respir Care* 2012;27-37.
14. Ruzskai Z, Szabó Z. Maintaining spontaneous ventilation during surgery—a review article. *J Emerg Crit Care Med* 2020;4:5.
15. Mygdalou A, Psarakis C, Vassiliou P, et al. Evaluation of the end-expiratory pressure by multiple linear regression and Fourier analysis in humans. *Respir Med* 2002;96:499-505.
16. Grinnan DC, Truwit JD. Clinical review: respiratory mechanics in spontaneous and assisted ventilation. *Crit Care* 2005;9:472-84.
17. Naeije R, Chemla D, Dinh-Xuan AT, et al. Physiology in respiratory medicine. *Eur Respir J* 2013;41:7.
18. Nunn JF. The lung as a black box. *Can Anaesth Soc J* 1966;13:81-97.
19. Campos JH, Feider A. Hypoxia During One-Lung Ventilation—A Review and Update. *J Cardiothorac Vasc Anesth* 2018;32:2330-8.
20. Euler US, Liljestrand G. Observations on the Pulmonary Arterial Blood Pressure in the Cat. *Acta Physiol Scand* 1946;12:301-20.
21. Lumb AB, Slinger P. Hypoxic pulmonary vasoconstriction: physiology and anesthetic implications. *Anesthesiology* 2015;122:932-46.
22. Coppock EA, Martens JR, Tamkun MM. Molecular basis of hypoxia-induced pulmonary vasoconstriction: role of voltage-gated K⁺ channels. *Am J Physiol Lung Cell Mol Physiol* 2001;281:L1-12.
23. Dunham-Snary KJ, Wu D, Sykes EA, et al. Hypoxic Pulmonary Vasoconstriction: From Molecular Mechanisms to Medicine. *Chest* 2017;151:181-92.
24. Post JM, Hume JR, Archer SL, et al. Direct role for potassium channel inhibition in hypoxic pulmonary vasoconstriction. *Am J Physiol* 1992;262:C882-90.
25. Baraka AS, Taha SK, Yaacoub CI. Alarming hypoxemia during one-lung ventilation in a patient with respiratory bronchiolitis-associated interstitial lung disease. *Can J Anaesth* 2003;50:411-4.
26. Sylvester JT, Shimoda LA, Aaronson PI, et al. Hypoxic pulmonary vasoconstriction. *Physiol Rev* 2012;92:367-520.
27. Licker M, Hagerman A, Jeleff A, et al. The hypoxic pulmonary vasoconstriction: From physiology to clinical application in thoracic surgery. *Saudi J Anaesth* 2021;15:250-63.
28. Garutti I, Quintana B, Olmedilla L, et al. Arterial oxygenation during one-lung ventilation: combined versus general anesthesia. *Anesth Analg* 1999;88:494-9.
29. Mahmood SS, Pinsky MR. Heart-lung interactions during mechanical ventilation: the basics. *Ann Transl Med* 2018;6:349.
30. Fothergill J. Observations on a Case Published in the Last Volume of the Medical Essays, &c. of Recovering a Man Dead in Appearance, by Distending the Lungs with Air. Printed at Edinburgh, 1744; by John Fothergill, Licent. Coll. Med. Lond. Available online: <https://ui.adsabs.harvard.edu/abs/1744RSP...43..275F/abstract>
31. Avignon PD, Hedenstrom G, Hedman C. Pulmonary complications in respirator patients. *Acta Med Scand Suppl* 1956;316:86-90.
32. Respirator lung syndrome. *Minn Med* 1967;50:1693-705.
33. Slutsky AS, Hudson LD. PEEP or no PEEP—lung recruitment may be the solution. *N Engl J Med* 2006;354:1839-41.
34. Maunder RJ, Pierson DJ, Hudson LD. Subcutaneous and mediastinal emphysema. Pathophysiology, diagnosis, and management. *Arch Intern Med* 1984;144:1447-53.
35. Slutsky AS, Ranieri VM. Ventilator-induced lung injury. *N Engl J Med* 2013;369:2126-36.
36. Pavone LA, Albert S, Carney D, et al. Injurious mechanical ventilation in the normal lung causes a progressive pathologic change in dynamic alveolar mechanics. *Crit Care* 2007;11:R64.
37. Mirabella L, Cinnella G, Costa R, et al. Patient-Ventilator Asynchronies: Clinical Implications and Practical Solutions. *Respir Care* 2020;65:1751-66.
38. Yoshida T, Uchiyama A, Matsuura N, et al. Spontaneous breathing during lung-protective ventilation in an experimental acute lung injury model: high transpulmonary pressure associated with strong spontaneous breathing effort may worsen lung injury. *Crit Care Med* 2012;40:1578-85.
39. Yoshida T, Torsani V, Gomes S, et al. Spontaneous effort causes occult pendelluft during mechanical ventilation. *Am J Respir Crit Care Med* 2013;188:1420-7.
40. Yoshida T, Uchiyama A, Fujino Y. The role of spontaneous effort during mechanical ventilation: normal lung versus injured lung. *J Intensive Care* 2015;3:18.
41. Eckstein JW, Hamilton WK. Changes in transmural central venous pressure in man during hyperventilation. *J Clin Invest* 1958;37:1537-41.
42. Mineo TC, Sellitri F, Vanni G, et al. Immunological and Inflammatory Impact of Non-Intubated Lung Metastasectomy. *Int J Mol Sci* 2017;18:1466.
43. Breunig A, Gambazzi F, Beck-Schimmer B, et al.

- Cytokine & chemokine response in the lungs, pleural fluid and serum in thoracic surgery using one-lung ventilation. *J Inflamm (Lond)* 2011;8:32.
44. Villamizar NR, Darrabie MD, Burfeind WR, et al. Thoracoscopic lobectomy is associated with lower morbidity compared with thoracotomy. *J Thorac Cardiovasc Surg* 2009;138:419-25.
 45. Liu J, Cui F, Pompeo E, et al. The impact of non-intubated versus intubated anaesthesia on early outcomes of video-assisted thoracoscopic anatomical resection in non-small-cell lung cancer: a propensity score matching analysis. *Eur J Cardiothorac Surg* 2016;50:920-5.
 46. Furák J, Paróczai D, Burián K, et al. Oncological advantage of nonintubated thoracic surgery: Better compliance of adjuvant treatment after lung lobectomy. *Thorac Cancer* 2020;11:3309-16.
 47. Mauri T, Cambiaghi B, Spinelli E, et al. Spontaneous breathing: a double-edged sword to handle with care. *Ann Transl Med* 2017;5:292.
 48. Hess DR. Respiratory mechanics in mechanically ventilated patients. *Respir Care* 2014;59:1773-94.
 49. Pompeo E, Mineo D, Rogliani P, et al. Feasibility and results of awake thoracoscopic resection of solitary pulmonary nodules. *Ann Thorac Surg* 2004;78:1761-8.
 50. Al-Abdullatif M, Wahood A, Al-Shirawi N, et al. Awake anaesthesia for major thoracic surgical procedures: an observational study. *Eur J Cardiothorac Surg* 2007;32:346-50.
 51. Vanni G, Tacconi F, Sellitri F, et al. Impact of awake videothoracoscopic surgery on postoperative lymphocyte responses. *Ann Thorac Surg* 2010;90:973-8.
 52. Tacconi F, Pompeo E, Sellitri F, et al. Surgical stress hormones response is reduced after awake videothoracoscopy. *Interact Cardiovasc Thorac Surg* 2010;10:666-71.
 53. Pompeo E, Tacconi F, Mineo TC. Comparative results of non-resectional lung volume reduction performed by awake or non-awake anesthesia. *Eur J Cardiothorac Surg* 2011;39:e51-8.
 54. Chen KC, Cheng YJ, Hung MH, et al. Nonintubated thoracoscopic lung resection: a 3-year experience with 285 cases in a single institution. *J Thorac Dis* 2012;4:347-51.
 55. Pompeo E, Rogliani P, Tacconi F, et al. Randomized comparison of awake nonresectional versus nonawake resectional lung volume reduction surgery. *J Thorac Cardiovasc Surg* 2012;143:47-54, 54.e1.
 56. Hung MH, Hsu HH, Chan KC, et al. Non-intubated thoracoscopic surgery using internal intercostal nerve block, vagal block and targeted sedation. *Eur J Cardiothorac Surg* 2014;46:620-5.
 57. Hung MH, Chan KC, Liu YJ, et al. Nonintubated thoracoscopic lobectomy for lung cancer using epidural anesthesia and intercostal blockade: a retrospective cohort study of 238 cases. *Medicine (Baltimore)* 2015;94:e727.
 58. Wang ML, Hung MH, Chen JS, et al. Nasal high-flow oxygen therapy improves arterial oxygenation during one-lung ventilation in non-intubated thoracoscopic surgery. *Eur J Cardiothorac Surg* 2018;53:1001-6.
 59. Liu CY, Hsu PK, Chien HC, et al. Tubeless single-port thoracoscopic sublobar resection: indication and safety. *J Thorac Dis* 2018;10:3729-37.
 60. Hung WT, Hung MH, Wang ML, et al. Nonintubated Thoracoscopic Surgery for Lung Tumor: Seven Years' Experience With 1,025 Patients. *Ann Thorac Surg* 2019;107:1607-12.
 61. Li H, Huang D, Qiao K, et al. Feasibility of non-intubated anesthesia and regional block for thoracoscopic surgery under spontaneous respiration: a prospective cohort study. *Braz J Med Biol Res* 2020;53:e8645.
 62. Liu HY, Hsu HH, Tsai TM, et al. Nonintubated Versus Intubated Uniportal Thoracoscopic Segmentectomy for Lung Tumors. *Ann Thorac Surg* 2021;111:1182-9.
 63. Liu HY, Chiang XH, Hung MH, et al. Nonintubated uniportal thoracoscopic segmentectomy for lung cancer. *J Formos Med Assoc* 2020;119:1396-404.
 64. Liu CY, Hsu PK, Leong KI, et al. Is tubeless uniportal video-assisted thoracic surgery for pulmonary wedge resection a safe procedure? *Eur J Cardiothorac Surg* 2020;58:i70-6.
 65. Hsu PK, Chuang LC, Ting CK, et al. Non-intubated electromagnetic-guided localization and resection of small indeterminate peripheral pulmonary nodules. *Respirology* 2020;25:1095-6.
 66. Ke HH, Hsu PK, Tsou MY, et al. Nonintubated video-assisted thoracic surgery with high-flow oxygen therapy shorten hospital stay. *J Chin Med Assoc* 2020;83:943-9.
 67. Hung WT, Hsu HH, Hung MH, et al. Comparison of perioperative outcomes between intubated and nonintubated thoracoscopic surgery in children. *J Formos Med Assoc* 2022;121:278-84.
 68. Hsu PK, Lee YY, Chuang LC, et al. Nonintubated versus intubated "one-stage" preoperative localization and thoracoscopic lung resection. *JTCVS Tech* 2021;10:517-25.
 69. Tamburrini A, Mineo TC. A glimpse of history: non-intubated thoracic surgery. *Video-assist Thorac Surg* 2017;2:52.

70. Neustein SM. The use of bronchial blockers for providing one-lung ventilation. *J Cardiothorac Vasc Anesth* 2009;23:860-8.
71. Grande B, Zalunardo MP, Kolbe M. How to train thoracic anesthesia for residents and consultants? *Curr Opin Anaesthesiol* 2022;35:69-74.
72. Tacconi F, Mineo TC, Ambrogi V. Team Training for Nonintubated Thoracic Surgery. *Thorac Surg Clin* 2020;30:111-20.
73. Mineo TC, Tacconi F. From "awake" to "monitored anesthesia care" thoracic surgery: A 15 year evolution. *Thorac Cancer* 2014;5:1-13.
74. Tacconi F, Pompeo E. Non-intubated video-assisted thoracic surgery: where does evidence stand? *J Thorac Dis* 2016;8:S364-75.
75. Mineo TC, Pompeo E, Mineo D, et al. Awake nonresectional lung volume reduction surgery. *Ann Surg* 2006;243:131-6.
76. Guarracino F, Gemignani R, Pratesi G, et al. Awake palliative thoracic surgery in a high-risk patient: one-lung, non-invasive ventilation combined with epidural blockade. *Anaesthesia* 2008;63:761-3.
77. Szabó Z, Tanczos T, Lebak G, et al. Non-intubated anaesthetic technique in open bilobectomy in a patient with severely impaired lung function. *J Thorac Dis* 2018;10:E275-80.
78. Furák J, Barta Z, Lantos J, et al. Better intraoperative cardiopulmonary stability and similar postoperative results of spontaneous ventilation combined with intubation than non-intubated thoracic surgery. *Gen Thorac Cardiovasc Surg* 2022;70:559-65.
79. Wu CY, Chen JS, Lin YS, et al. Feasibility and safety of nonintubated thoracoscopic lobectomy for geriatric lung cancer patients. *Ann Thorac Surg* 2013;95:405-11.
80. Hung MH, Hsu HH, Cheng YJ, et al. Nonintubated thoracoscopic surgery: state of the art and future directions. *J Thorac Dis* 2014;6:2-9.

Cite this article as: Szabo Z, Fabo C, Oszlanyi A, Hawchar F, Géczi T, Lantos J, Furák J. Anesthetic (r)evolution from the conventional concept to the minimally invasive techniques in thoracic surgery—narrative review. *J Thorac Dis* 2022;14(8):3045-3060. doi: 10.21037/jtd-22-80