



Contents lists available at [ScienceDirect](https://www.sciencedirect.com)

JPRAS Open

journal homepage: [www.elsevier.com/locate/jpra](http://www.elsevier.com/locate/jpra)



Original Article

# Venous system mapping of the digits and the hand: An anatomical study and potential surgical applications <sup>☆</sup>

Martin Lhuire <sup>a,b,c,\*</sup>, Guillaume Wavreille <sup>c</sup>, Mikael Hivelin <sup>d</sup>, Aurélien Aumar <sup>c</sup>, Vincent Hunsinger <sup>a</sup>, Mohamed Derder <sup>a</sup>, Alexandre G. Lellouch <sup>a,e</sup>, Peter Abrahams <sup>f</sup>, Laurent Lantieri <sup>a</sup>, Christian Fontaine <sup>b</sup>

<sup>a</sup> Department of Plastic, Reconstructive and Aesthetic Surgery, Hôpital Européen Georges Pompidou, Assistance Publique des Hôpitaux de Paris, Université de Paris, Paris, France

<sup>b</sup> Institute of Anatomy and Organogenesis, Faculté de Médecine Henri Warembourg, Université de Lille, Lille, France

<sup>c</sup> SOS Hands and Fingers, Clinique Lille Sud, Lesquin, France

<sup>d</sup> Department of Plastic, Reconstructive and Aesthetic Surgery, Hôpital Ambroise Paré, Assistance Publique des Hôpitaux de Paris, Université Paris-Saclay, Paris, France

<sup>e</sup> Vascularized Composite Allotransplantation Laboratory, Center for Transplantation Sciences, Massachusetts General Hospital, Harvard Medical School, Boston, MA, USA

<sup>f</sup> Warwick Medical School, University of Warwick, Coventry, CV4 7AL, United Kingdom

## ARTICLE INFO

### Article history:

Received 31 October 2021

Accepted 21 April 2022

Available online 14 May 2022

## ABSTRACT

**Background:** Venous anatomy of the digits and the hand is poorly reported in the literature compared to arterial anatomy. While knowledge of the venous anatomy is crucial to ensure safe skin incisions, skin flap design, or blood return restoration for digital

<sup>☆</sup> **Presented at:** The 101st Congress of the Association des Morphologistes (AM), Rennes, France, March 14–16th, 2019; The Société Anatomique de Paris (SAP), Paris, France, April 19th, 2019; The International Congress of Anatomia Clinica (15th EACA), Madrid, Spain, June 24–26th, 2019; The 19th Congress of the International Federation of Associations of Anatomists (IFAA), London, UK, August 9–11th, 2019; 55th National Congress of the Société Française de Chirurgie de la Main (SFCM), Paris, France, December 19–21th, 2019.

\* Correspondence to: Dr Martin LHUAIRE, Department of Plastic, Reconstructive and Aesthetic Surgery, Hôpital Européen Georges Pompidou, Assistance Publique des Hôpitaux de Paris, 20 rue Leblanc, 75908, Paris Cedex 15, France. Tel: +33 1 56 09 58 71.

E-mail address: [martin.lhuire@etu.u-paris.fr](mailto:martin.lhuire@etu.u-paris.fr) (M. Lhuire).

<https://doi.org/10.1016/j.jpra.2022.04.008>

2352-5878/© 2022 The Author(s). Published by Elsevier Ltd on behalf of British Association of Plastic, Reconstructive and Aesthetic Surgeons. This is an open access article under the CC BY-NC-ND license (<http://creativecommons.org/licenses/by-nc-nd/4.0/>)

**Keywords:**

Hand anatomy  
 Vascular anatomy  
 Hand surgery  
 Hand venous anatomy  
 Digital replantation  
 Plastic surgery

replantations, data in anatomical and clinical textbooks are rather limited. The purpose of this anatomical study was to describe the venous anatomy of the digits and the hand.

**Method:** Our series reports descriptive results from 10 non-embalmed hand dissections from 5 different corpses. Hands were previously co-injected by arteries followed by veins with a different colored latex before being dissected under optical magnification (x4). Each anatomical specimen was photographed before being analyzed.

**Results:** Each injection revealed both arterial and venous vascular systems. Latex injections were a useful technique to show the dorsal, volar superficial, and deep venous system. There was a constant and reliable topographic vascular anatomy of the superficial venous system of the digits and hand. However, we could not observe a high density of dorsal superficial venous valves as previously reported.

**Conclusion:** The knowledge of the arrangement of the venous system of the digits and the hand should help the surgeon when performing surgical procedures in the hand. The surgeon should take into consideration this venous anatomy when performing skin incisions, skin flaps, or replantation procedures which would preserve the normal venous physiology as much as possible.

© 2022 The Author(s). Published by Elsevier Ltd on behalf of British Association of Plastic, Reconstructive and Aesthetic Surgeons.

This is an open access article under the CC BY-NC-ND license (<http://creativecommons.org/licenses/by-nc-nd/4.0/>)

## Introduction

Suitable veins to perform the anastomosis would ensure better return blood flow from the replants. Another aspect of hand venous anatomy knowledge would comprise an approach to the vascular safety of skin incision to avoid skin necrosis. Despite progress in microsurgical techniques, distal fingertip replantations are still clinically challenging due to the venous anastomoses, which are rarely performed due to the difficulty of finding suitable sites for anastomosis. Enhanced anatomical knowledge of the digital venous systems, as well as the better design of skin flaps, taking into account the venous anatomy would reduce or prevent flap necrosis.<sup>18-24</sup> The venous blood supply of the hand is, such as the lymphatics, extremely difficult to study. Despite its major clinical implications, injections are only presented in a few publications.<sup>10-13</sup> Currently, anatomical atlases and most hand surgery texts do not display a detailed anatomy of the venous system of the digits and the hand; in fact, very little attention is paid to this system, which we also know to be rather variable.<sup>1-4,6,7,9,14-16</sup> Hand surgeons still debate the existence of a deep venous system at the level of the digits; the number or the location of venous valves; and anastomoses between deep and superficial venous systems.<sup>10-13,17</sup>

The aim of this descriptive anatomical study was to use vascular injection and microdissection to delineate the digital venous anatomy and that of the hand to assist hand and plastic surgeons when performing digital and hand surgeries.

## Material and methods

A monocentric prospective observational cadaveric study was carried out from June 2017 to August 2019. Our series reports descriptive results from 10 hand dissections, from five different fresh cadavers (3 females and 2 males) available from the Institute of Anatomy of Lille Body Donation Program. All specimens underwent the same injection method. Radial and ulnar arteries were cannulated with

a 16-G vascular catheter (BD France S.A.S, Grenoble, France). Each medial dorsal vein between the DIP and PIP joints for fingers and between the IP and the MCP joints for the thumb were cannulated using an operative microscope with a 26-G vascular catheter (BD France S.A.S, Grenoble, France). Arterial and venous vascular beds were cleaned with a saline solution of heparin (5000 UI/L) at room temperature (20°C). Then, a red dye latex solution (Esprit Composite, Paris, France) was used to fill the arterial system and injected first with a 20 mL luer lock syringe (BD France S.A.S, Grenoble, France) through the ulnar and radial arteries at the wrist. An anterograde red latex injection was performed until a red cutaneous flush was visualized with no overpressure. Then, a blue dye latex solution (Esprit Composite, Paris, France) was used for the venous system. An anterograde blue latex injection with no increased pressure and a 20 mL luer lock syringe (BD France S.A.S, Grenoble, France) was performed until the dorsal veins were tumescent and resistance felt; 24 h thereafter, all injected hands were micro-dissected using an operative microscope (magnification x4) (Leica Microsystems, Wetzlar, Deutschland). The dissection procedure followed the same pattern, starting from the fingertips in a dorso-volar direction and going as far as the wrist. All injections and microdissections were performed by the same operator (ML). Each anatomical dissection was photographed before analysis. Quantitative data are systematically presented in terms of means, extremes, and standard deviations.

## Results

The mean age in this series was 80 years old (range: 67 - 91 years;  $\pm$  5.3 years). The mean weight and height were 63 kg (range: 40 - 85 kg;  $\pm$  14.2 kg) and 1.60 m (range: 1.50 - 1.75 m;  $\pm$  0.72 m), respectively. The mean BMI was 23 kg/m<sup>2</sup> (range: 17 - 25 kg/m<sup>2</sup>;  $\pm$  3.2 kg/m<sup>2</sup>).

### *Superficial venous dorsal system*

**Distal interphalangeal joint.** Two small veins which run collaterally to the nail plate and are located at the dorsopalmar junction of the fingertip in the fingers and thumb were constant (Figures 1A and 2A and 2B).

**Distal interphalangeal joint to proximal interphalangeal joint.** Longitudinal veins are present on the dorsal side of the middle phalanx and originate from the confluence of the eponychial and lateroungual veins (Figures 1A, 2A, 3A, and 2B).

**Proximal interphalangeal joint and metacarpophalangeal joint.** There are 2-4 longitudinal veins on the dorsal side of the proximal phalanx (Figures 1A and 2A, 3A and 2B).

**Metacarpophalangeal joint and radiocarpal joint.** The longitudinal dorsal veins of the fingers and thumb run together proximal to the MCP joints by converging at the interdigital web spaces and are formed by oblique veins from the palmar venous system (Figures 1A and 2A and 2B).

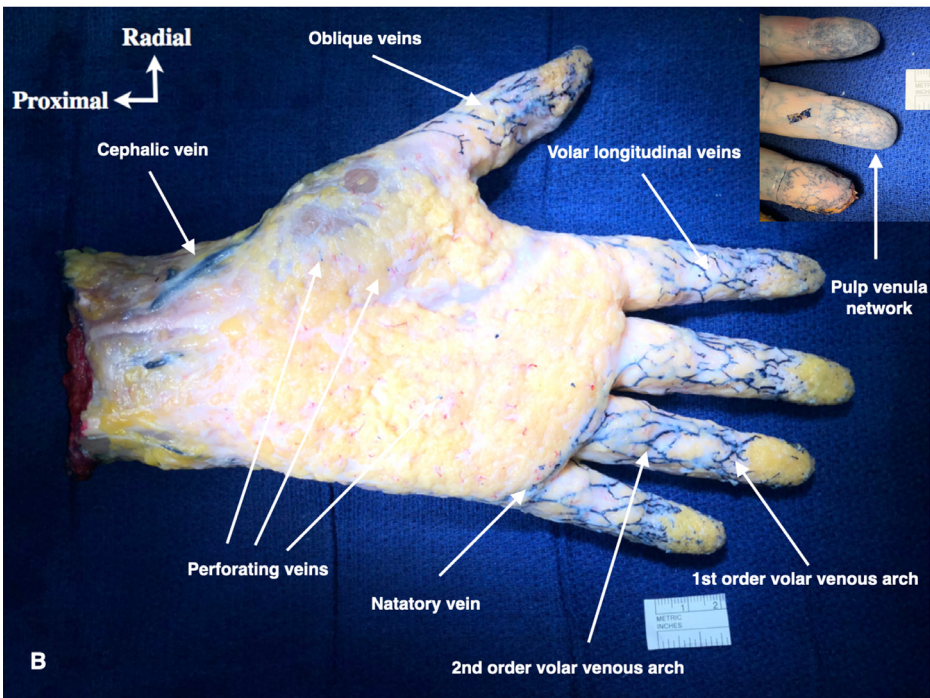
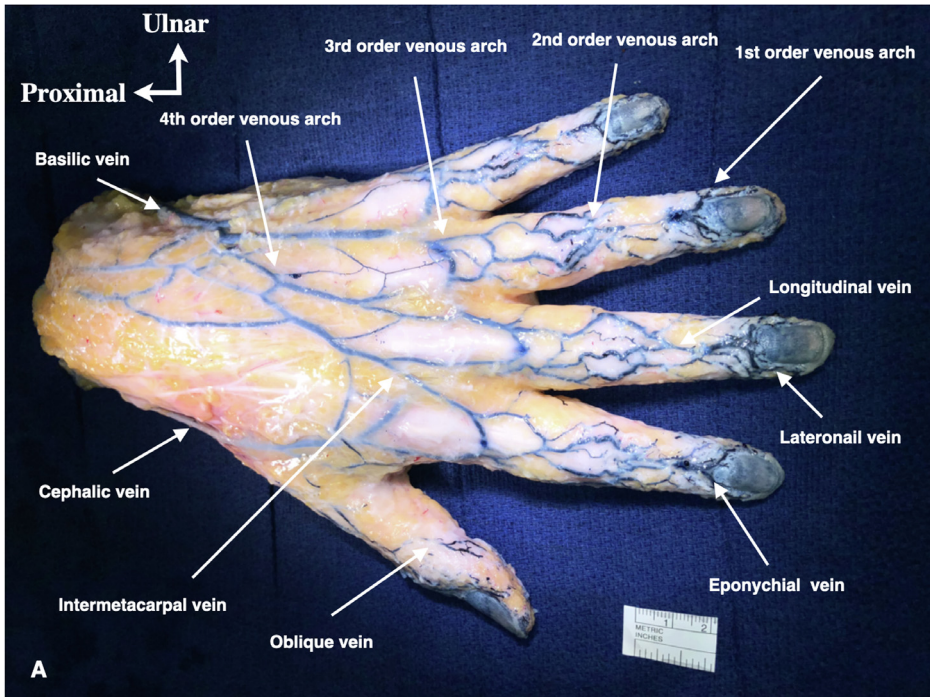
### *Superficial venous volar system*

**Distal interphalangeal joint.** The injections revealed a rich pulp venous network. This venous network adheres firmly to the dermis with a venous diameter of about a 100µm (Figures 1B and 2A).

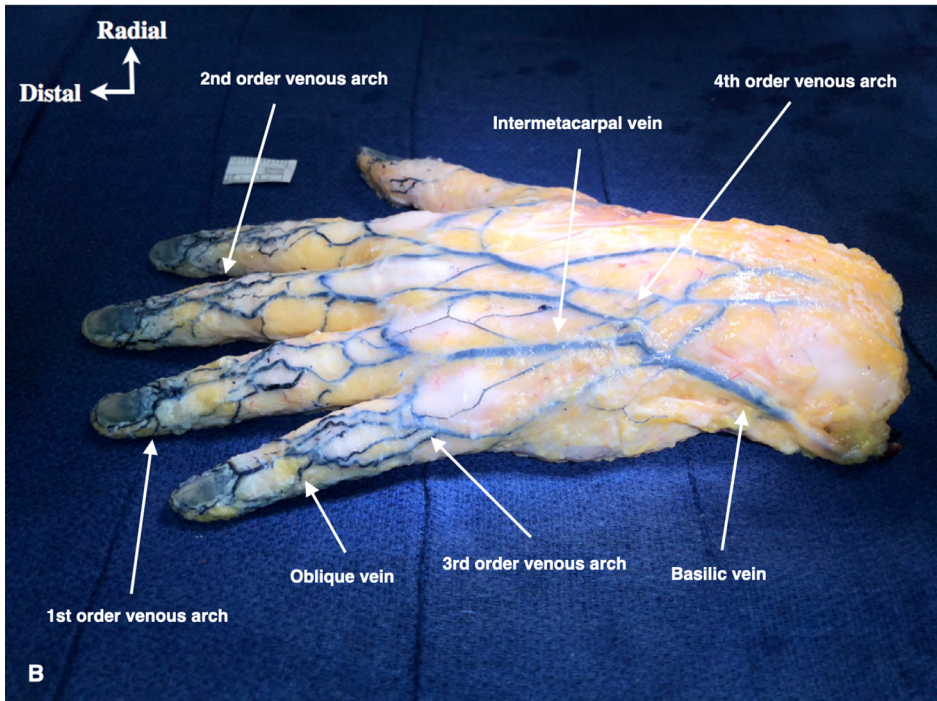
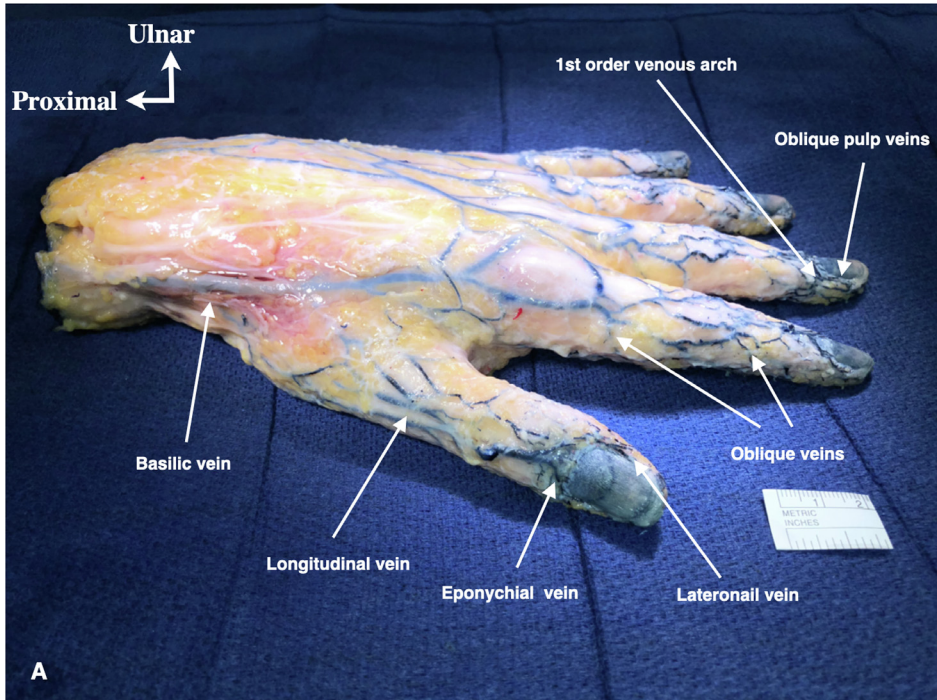
**Distal interphalangeal joint and proximal interphalangeal joint level.** The volar venous system appears more numerous than the dorsal one with a number of longitudinal veins varying from 3 to 5 and a diameter of less than a millimeter (Figures 1B and 2A and 2B).

**Proximal interphalangeal joint and metacarpophalangeal joint level.** The volar venous system at this level appears similar both in its density of veins (2 to 4 veins) and in its organization (longitudinal and oblique arrangements) compared to the palmar venous system between the DIP and PIP joints (Figure 1B and 2A and 2B).

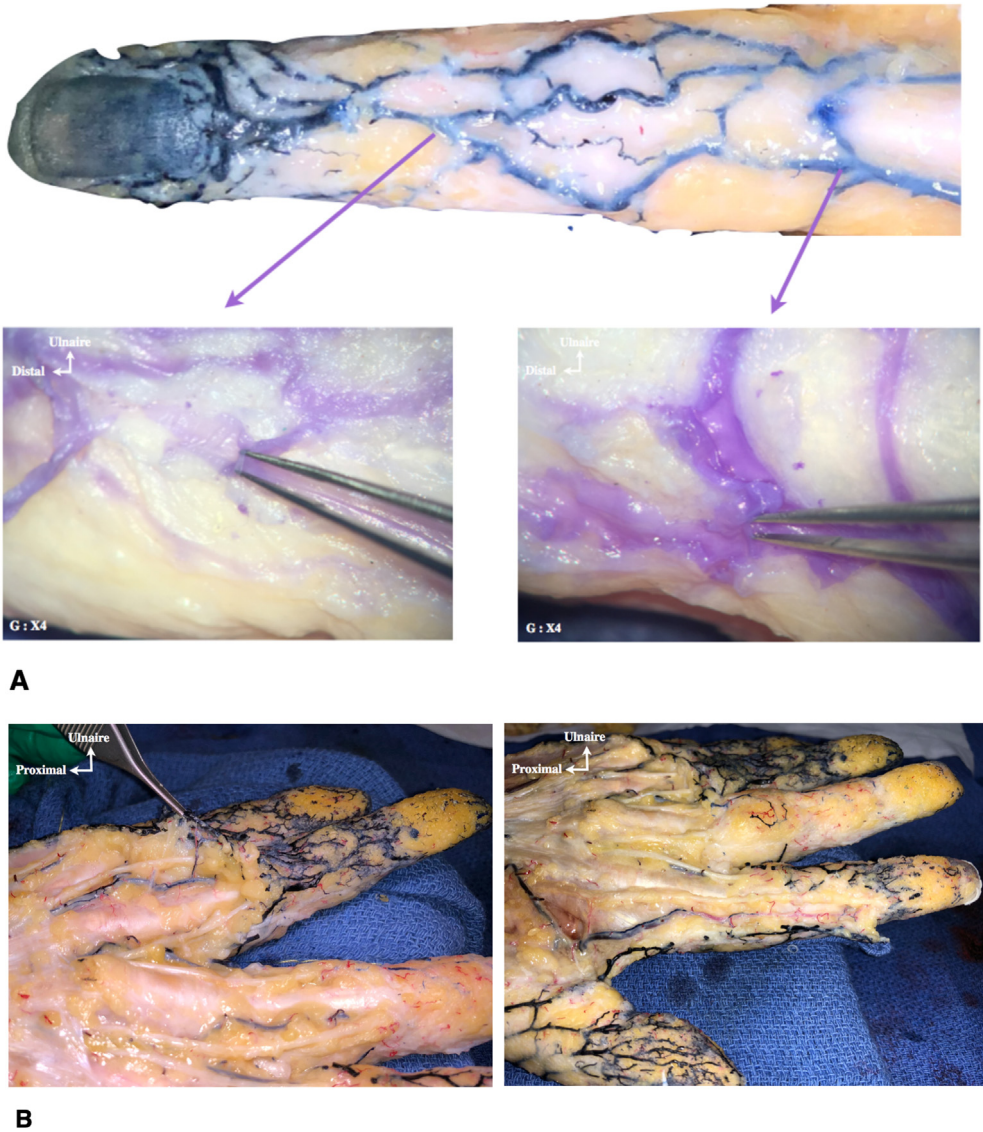
**Metacarpophalangeal joints and radiocarpal joint level.** The volar venous system at this level is represented by the natatory vein which runs superficially to the natatory ligament and ensures the venous drainage of the 3rd, 4<sup>th</sup>, and 5<sup>th</sup> digits (Figures 1B and 2A and 2B).



**Figure 1.** Dorsal view of the whole left hand with latex injection which shows the dorsal superficial venous system (A). Palmar view of the whole left hand with latex injection which shows the volar superficial venous system (B).



**Figure 2.** Dorsoradial view of the whole left hand with latex injection which shows the dorsal superficial venous system (A). Dorsoulnar view of the whole left hand with latex injection which shows the dorsal superficial venous system (B).

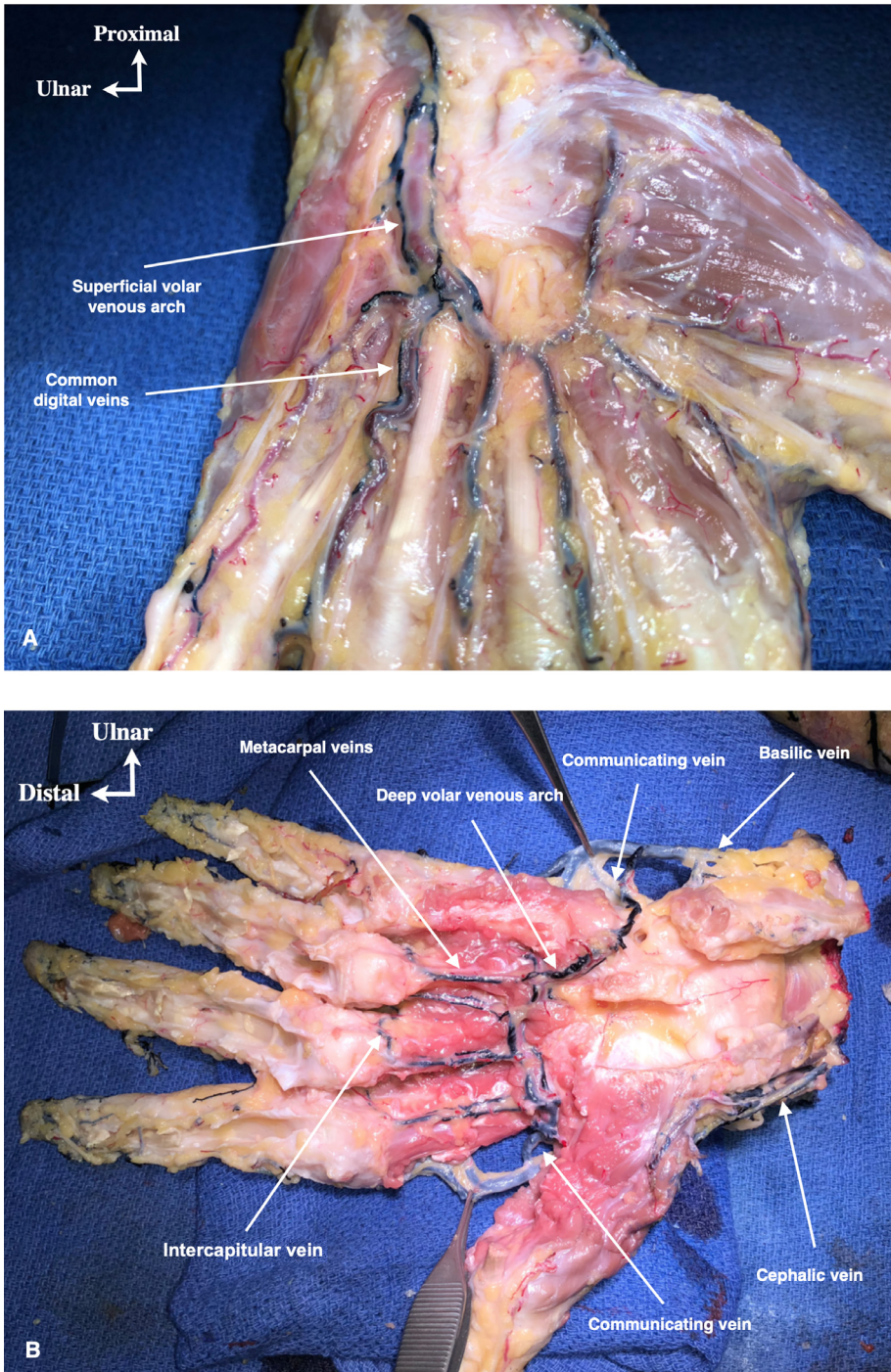


**Figure 3.** Venous valves on the dorsal superficial venous system of the digits (A). Deep volar venous system of the digits (B).

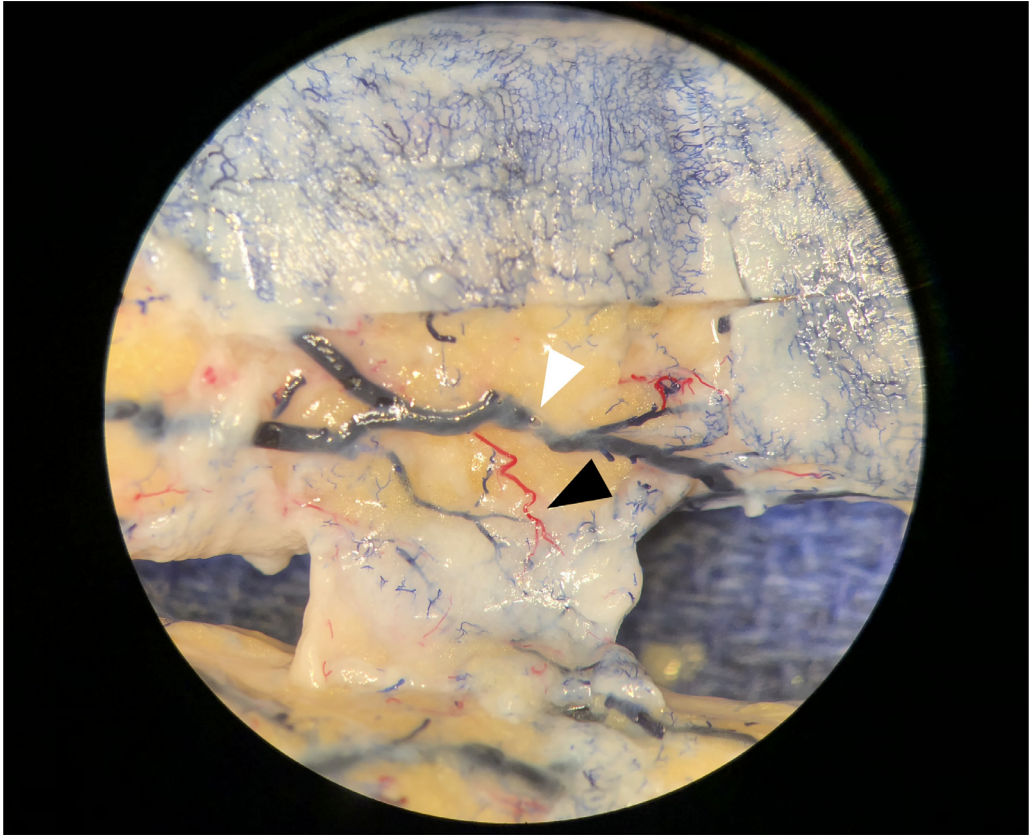
### Deep venous system

**At the level of the digits.** The injections allowed the identification of a deep collateral venous system alongside the digital arteries (Figure 3B).

**At the level of the palm of the hand.** The collateral veins of the digital arteries continue alongside the common palmar digital arteries at the level of the metacarpals. (Figure 4A, 4B).



**Figure 4.** Palmar view of the palm left hand with latex injection which shows the volar deep venous system at the level of the superficial vascular arch (A). Palmar view of the palm left hand with latex injection which shows the volar deep venous system at the level of the deep vascular arch (B).

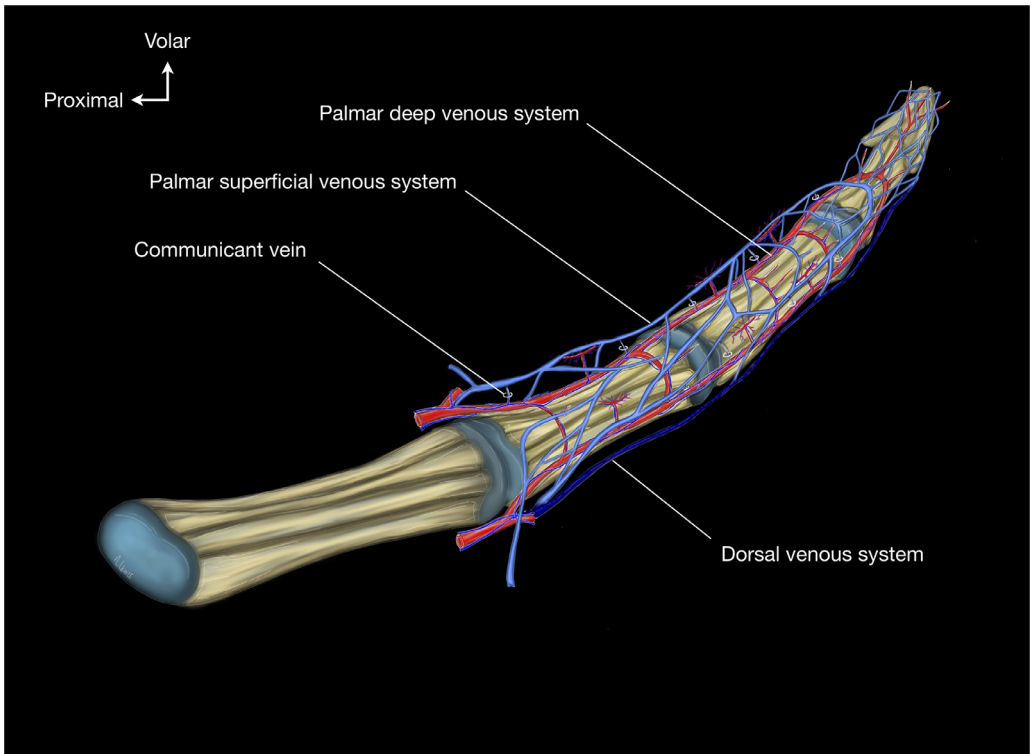


**Figure 5.** Magnifying view under operative microscope (x40) of the perforator vessels between DIP and PIP joints. Note the perforator artery and vein which join the deep venous system (black arrowhead). Superficial longitudinal volar vein (white arrowhead).

## Discussion

Vascular injections combined with microdissection allowed us to highlight all the superficial and deep venous systems of the digits and the hand. It gave us the opportunity to elaborate a detailed description of the distal superficial dorsal venous system distal to the DIP joint (Figures 5, 6). We observed the constant presence of two veins collateral to the nail plate which can be single or double. While the arterial anatomy of the fingertip is well described, no anatomical or clinical study, to our knowledge, has given a precise description of the venous system at the level of the fingertips.<sup>10-13,25</sup> The detailed knowledge of the venous anatomy of the fingertips is clinically important in distal digital replantation where the main concern is to ensure the venous outflow to prevent venous congestion which might result in failure of the replants. Indeed, performing a venous anastomosis during these distal digital replantations represents a real surgical challenge because of the lack of precise anatomical data of their topography, and their small diameter makes it difficult to find, especially when tissues are damaged in a traumatic amputation.<sup>20,22-25</sup> It is well established that the restoration of the venous return by venous anastomoses improves the success rate of the replantation.<sup>26-28</sup> We think a precise knowledge of the topographic anatomy and its constancy should allow a rapid finding of a suitable vein for anastomosis. The implementation of supermicrosurgical techniques would probably make distal fingertips replantations more reliable and improve their survival rates.





**Figure 6.** Schematic drawing showing the vascular anatomy of the digits.

The second anatomical finding revealed by our injections is the existence of the dorsal venous arches of the superficial venous system. In 1984, Lucas GL reported the results of an anatomical study of the digital veins using a trans osseous injection method. These results enabled him to describe for the first time the existence of these digital venous arches. He also proposed a schematic systematization of the digital venous vascularization in the form of stepped arches. He sketches the lateroungual veins without giving them a precise description.<sup>10</sup> Smith DO et al. also studied the venous vascularization of the fingers by dissecting a large series. The diagrams representing the venous vascularization of the distal phalanx showed the configuration that we observed in our series, but they lack a systematic anatomical framework, which leaves their description relatively imprecise.<sup>12</sup> In 1985, Moss et al. have carried out a comprehensive anatomical study of the venous anatomy of the fingers and the hand.<sup>11</sup> Concerning their description of the distal dorsal veins distal to the DIP joint, they described "a first venous arch with distal convexity where converge the veins located around the nail bed".<sup>11</sup> They also reported that this distal venous arch is the most constant of the venous arches.<sup>11</sup> In our observations, we also confirmed the constancy of the organization of this dorsal venous system distal to the DIP joint. We were also able to observe this arrangement with the formation of a first distal superficial dorsal arch (first order) distal to the DIP joint. This first-order dorsal venous arch arises from the meeting of the lateroungual veins as well as the laterodigital oblique veins of the fingertip which connect the palmar pulp venous system to the dorsal network. Regarding the presence of venous valves distal to the DIP joints, our observations were technically limited and did not allow us to highlight them. However, Moss et al. reported the presence of these venous valves all along the finger even on very distal small veins, while Dautel et al. did not confirm their presence in their study.<sup>11,13</sup>

Our observations also allowed us to give a detailed description of the dorsal venous anatomy between the DIP and PIP joints. Our results confirm the previous reported observations,<sup>10–12</sup> with the presence of a middle dorsal venous arch, in front of the base of the middle phalanx, in which the longitudinal median vein (sometimes double) originating from the confluence of the two eponychial veins and from the lateral oblique veins at the middle phalanx and at the DIP joint which drain the volar veins. We also observed the dorsal venous network between the PIP and MCP joints. Our results confirm the previous studies with the existence of a third-order dorsal horizontal venous arch.<sup>10–12</sup> Regarding the presence of venous valves, we were able to demonstrate, after longitudinal opening of the dorsal veins, the presence of venous valves at the level of the distal and intermediate dorsal venous arches, which were also observed by Moss et al. and Dautel et al.<sup>11,13</sup>

The third anatomical finding revealed by our injections is the existence of a deep venous system. It was identified during our dissections at the level of the proximal but also the middle phalanx. This deep venous system appears to be discontinuous alongside the proper palmar digital arteries and inconsistent from one finger to the other. We were also able to identify the existence of communications between the deep venous and superficial venous systems (Figure 6). It seems that a definition of these vessels varies between authors. Anatomists and vascular surgeons distinguish between a "perforating vein," which makes communication between the deep and the superficial venous systems, and a "communicating vein," which make communication of the same venous system, such as Giacomini's vein that links the small to the great saphenous system.<sup>29–31</sup> This definition must be precise to avoid confusion as regards of the venosome theory reported by Taylor.<sup>32,33</sup> Indeed, a cutaneous perforator (either artery or vein) is defined as any vessel that pierces the outer layer of the deep fascia to supply the skin. A "venosome" is defined as a venous territory drained by the same cutaneous perforator vein within a collateral vein that accompanies the source artery.<sup>34</sup> In our series, we assumed the definition given by Taylor; therefore, we named a vein that links the superficial to the deep venous system a "communicating vein" and a cutaneous perforating vein as a vein that drains a venosome.<sup>34</sup> The existence of a deep venous system alongside the proper palmar digital arteries is not unanimous among authors and is still the subject of debate in the literature, in particular on its existence, its continuity from the pulp to the root of the digits, as well as its consistency and variability.<sup>10,13,17,35</sup> In 1992, Dautel et al. gave a systematic description of this deep venous system from five hands of non-embalmed adult cadavers.<sup>13</sup> They reported that this committant venous system of the digital arteries was discontinuous and inconsistent. They also proposed a classification of the arrangement and variations of this deep venous system. The type I corresponds to the presence of a continuous digital collateral deep venous system. The type II corresponds to the absence of a deep venous network. The type III corresponds to the only presence of a proximal venous network and the last type (the type IV) which corresponds to a discontinuous deep venous system only segmental alongside the collateral digital artery.<sup>13</sup> In addition, Dautel et al. reported the existence of anastomotic venous arches connecting the deep venous system to the dorsal superficial system (communicating veins according to the Taylor's definition). It would seem that we have not observed this anatomical arrangement but rather a drainage toward the superficial palmar venous network via the communicating veins (Figure 3B). However, we partially confirm the observations of Dautel et al., since these collateral veins arise from interphalangeal joints and we confirm neither their constancy nor continuity along the digits.<sup>13</sup> However, this observation must be taken with precaution as further dissections with venous injections would be necessary before making any conclusions. The surgical application of these findings has implications for the design of the skin incision using the Brunner approach. Also, for the design of several skin flaps to ensure coverage of injured digits such as the Atasoy flap, the volar Hueston flap, or the homodigital island flap with a distal pedicle, each need consideration of this venous anatomy for preserving the venous system to ensure the reliability of the venous outflow of the flaps during reconstructive surgery.

The fourth anatomical finding revealed by our injections is the existence of large caliber communicating veins that connect the deep venous arch with the basilic and cephalic system on ulnar and radial sides, respectively. To our knowledge, this has never been reported in the literature. One hypothesis should be mentioned as regards to the venous drainage of the palm and the presence of these communicating veins that drain the venous outflow from the deep to the superficial venous system. We have shown that the venous drainage of the palm was represented by cutaneous perfo-

rating veins, which open into the superficial venous arch which in turn flows either by committant veins alongside the ulnar artery but also through communicating veins to the deep volar venous arch. This deep volar venous arch also receives the metacarpal veins that drain the intrinsic muscles. The main route of drainage of the deep venous system to the superficial one could be explained by the function of the palm adapted for grasping objects which inherently increases the venous pressure that directs the flow to the superficial dorsal system with no pressure constraints and which thus allows a reasonable venous return. Despite an object being grasped tightly within the palm, it might be a similar mechanism to the "pump effect" seen in the lower limb and the foot.<sup>30</sup> Finally, the morphology of this deep venous system seems inconstant and reduced in vessel size caliber compared to the superficial venous system which is made up of a larger size vessel caliber and richer in terms of number of veins. This leads us to hypothesize that this deep venous system would probably be incidental, but other studies, in particular dynamic ones, should be conducted to confirm this hypothesis. Functionally and in contrast to the venous return system of the lower limbs where the deep venous system participates 90% in venous return while the superficial venous system participates in turn at only 10%, our observations tend to show that in the upper limb, the superficial venous system would seem to participate in 90% of the venous return while the deep venous system would seem to participate only 10% in the absence of pathology. We could suggest this deep venous system as a latent system; for use as soon as an obstruction occurs on the superficial system, blood would then follow a redirection from the superficial venous system to the deeper one via the communicating veins. These findings are supported by embryological theory of the limb development in which the superficial venous system appears before the deep venous system during the human development and the differentiation of its system at the level of the upper limb follows a distal-to-proximal and from surface to deep sequence.<sup>5,8,34,36-38</sup> In 2015, Uhl et al. demonstrated at the level of the foot that the direction of drainage of the perforating veins (communicating veins according to the Taylor definition) at the level of the foot was reversed (from the depth to the surface) in opposite to what is admitted at the level of the lower limb (from the surface to the depth), thus increasing the flow in the saphenous superficial venous system during contraction movements of the calf.<sup>30,31</sup>

Our study presents several important aspects. To our knowledge, this study is the first to describe comprehensively the venous anatomy of the digital extremities, particularly at the fingertip level and the deep venous system of the digits and hand. From a methodological point of view, our study displays 12 of the 13 items on the Quality Appraisal for Cadaveric Studies (QUACS) scale.<sup>39</sup> However, this study has several weaknesses. The first is linked to the injection technique which probably does not guarantee injection of the digital veins and therefore will underestimate the density of this venous network but also the existence of certain veins which would not have been injected, especially within the deep venous system. The huge variability of injection methods confirms the extreme difficulty to fill this venous system in a comprehensive manner.<sup>10-13</sup> One of the possible ways to overcome this problem inherent in the technique would be to perform serial histological sections and to perform vascular immunostaining in order to carry out three-dimensional reconstructions.<sup>40</sup> This would be an additional tool to identify veins. The second weakness corresponds to the fact that only the superficial longitudinal dorsal middle phalanx was the origin of the injection due to technical access. However, Moss et al. described a system of venous valves up to the distal pulp veins.<sup>11</sup> This could explain why we did not succeed in injecting perfectly the palmar venous network, but our results and those of Dautel et al. seem to confirm Moss's statement of the presence of these valves at the level of the fingertips.<sup>11,13</sup> One of the solutions proposed to obviate this problem would be to inject the palmar veins. Finally, it would be interesting to add a radiopaque product to the injection solution in order to carry out acquisitions by micro-CT scan or micro-MRI, which would probably provide additional anatomical information.<sup>41</sup> The third weakness is the small number of specimens (n=5 cadavers), which did not allow us to draw a wide spectrum of veins variations of the hands, and as we know veins are always variable. One of the further objectives would be to increase the number of specimens of this study.

To conclude, we hope that these new insights into the vascular anatomy of the venous system of the digits, and the hand will help the surgeon in clinical practice to preserve this venous system and increase venous outflow thus preventing skin necrosis after surgical intervention and improving flap design as well as the vascular prognosis of distal digital replantation.

## Acknowledgement

We are grateful to the donors of the Institute of Anatomy and Organogenesis of Lille and their families without whom anatomical studies for the advancement of medical research and education of future healthcare providers would not be feasible. We thank Maurice De Meulaere, Fabien Descamps, and Franck Stevendart from the Institute of Anatomy and Organogenesis of Lille for their assistance throughout the dissections.

## Author Contributions

All persons listed as authors have contributed substantially to the design, performance, analysis, and reporting of this work. ML, GW, MH, AA, MD, VH, AL: collected data, analyzed data, literature review, and wrote paper. PA, LL: analyzed data and wrote paper. ML, GW, LL, CF: Designed study, analyzed data, and wrote paper.

## Declaration of Competing Interest

None.

## Funding

None.

## Ethical approval

Not required.

## References

- Gray H, Carter HV. *Anatomy Descriptive and Surgical*. London: Parker J.W and Son, West Strand; 1858.
- Testut L *Traité d'Anatomie Humaine. Tome deuxième: Angéiologie - Système nerveux central*. II. Septième ed. Paris: Gaston Doin; 1921.
- Rouvière H, Delmas A *Anatomie Humaine. Descriptive, topographique et fonctionnelle. Tome II. Tronc*. Tome II. 11e Édition ed. Paris: Masson, Paris; 1974.
- Netter FH. *Atlas of Human Anatomy*. 4th ed. Philadelphia, USA: Saunders Elsevier; 2006.
- Lhuair M, Hivelin M, Derder M, Hunsinger V, Delmas V, et al. Anatomical variations of the subscapular pedicle and its terminal branches: an anatomical study and a reappraisal in the light of current surgical approaches. *Surg Radiol Anat*. 2019;41(4):385–392.
- Mascagni, P. *Vasorum lymphaticorum corporis humani historia et ichnographia*. 1787, Senis.
- Sappey, M.P.C. *Anatomie, physiologie, pathologie des vaisseaux lymphatiques considérés chez l'homme et les vertébrés*. 1874, Paris: Ed A Delahaye.
- Lhuair M. *Étude Anatomique des pédicules épigastriques inférieurs, subscapulaire et thoracique interne: Applications chirurgicales. Thèse d'exercice N ° 2016REIMM136. Mention Médecine Spécialisée*. Reims, France: Université de Reims Champagne-Ardenne; 2016:1–217.
- Cruevilhier J *Traité d'Anatomie Descriptive. Tome I*. I. Paris: Labé; 1851.
- Lucas GL. The pattern of venous drainage of the digits. *The Journal of Hand Surgery*. 1984;9(3):448–450.
- Moss SH, Schwartz KS, von Drasek-Ascher G, Ogden LL, Wheeler CS, et al. Digital venous anatomy. *The Journal of Hand Surgery*. 1985;10(4):473–482.
- Smith D, Oura C, Kimura C, Toshimori K. The distal venous anatomy of the finger. *J Hand Surg Am*. 1991;16(2):303–307.
- Dautel G, Merle M. The blood supply of digital nerves: a microanatomical study of superficial and deep palmar venous networks. *J Hand Surg Br*. 1992;17(6):632–637.
- Tubiana R *Traité de chirurgie de la main*. 1. Paris: Masson; 1980.
- Wolfe SW, Hotchkiss RN, Pederson WC, Kozin SH. *Green's operative hand surgery*. 6th ed. USA: Elsevier Churchill Livingstone; 2011.
- Standring S. *Gray's Anatomy the anatomical basis for clinical practice*. 41st ed. Elsevier; 2016.
- Eaton RG. The digital neurovascular bundle. A microanatomic study of its contents. *Clin Orthop Relat Res*. 1968;61:176–185.
- Tsai T, McCabe S, Maki Y. A technique for replantation of the finger tip. *Microsurgery*. 1989;10(1):1–4.
- Kim WK, Lim JH, Han SK. Fingertip replantations: clinical evaluation of 135 digits. *Plast Reconstr Surg*. 1996;98(3):470–476.
- Dautel G, Ferreira A, Corcella D, Merle M La Main; 1997:329–335.
- Sukop A, Urban K, Tvrdek M. Types of vascular reconstructions in replantations of distal parts of the fingers. *Acta Chir Plast*. 2002;44(4):132–135.

22. Dautel G, Barbary S. Mini replants: fingertip replant distal to the IP or DIP joint. *J Plast Reconstr Aesthet Surg.* 2007;60(7):811–815.
23. Zhang X, Wen S, Wang B, Wang Q, Li C, et al. Reconstruction of circulation in the fingertip without vein repair in zone I replantation. *J Hand Surg Am.* 2008;33(9):1597–1601.
24. Barbary S, Dap F, Dautel G. Finger replantation: surgical technique and indications. *Chir Main.* 2013;32(6):363–372.
25. Nam YS, Jun YJ, Kim IB, Cho SH, Han HH. Anatomical Study of the Fingertip Artery in Tamai Zone I: Clinical Significance in Fingertip Replantation. *J Reconstr Microsurg.* 2017;33(1):45–48.
26. Hattori Y, Doi K, Ikeda K, Abe Y, Dhawan V. Significance of venous anastomosis in fingertip replantation. *Plast Reconstr Surg.* 2003;111(3):1151–1158.
27. Efanov JI, Rizis D, Landes G, Bou-Merhi J, Harris PG, et al. Impact of the number of veins repaired in short-term digital replantation survival rate. *J Plast Reconstr Aesthet Surg.* 2016;69(5):640–645.
28. Aksoy A, Gungor M, Sir E. Fingertip Replantation Without and With Palmar Venous Anastomosis: Analysis of the Survival Rates and Vein Distribution. *Ann Plast Surg.* 2017;78(1):62–66.
29. Gillot C. [Surgical anatomy of perforating veins of the leg]. *Phlebologie.* 1987;40(3):563–574.
30. Uhl JF, Gillot C. Anatomy of the veno-muscular pumps of the lower limb. *Phlebology.* 2015;30(3):180–193.
31. Uhl JF, Vuolo ML, Gillot C. Anatomy of foot and ankle perforator veins. *Phlebology.* 2017;24(2):105–112.
32. Taylor GI, Palmer JH. The vascular territories (angiosomes) of the body: experimental study and clinical applications. *Br J Plast Surg.* 1987;40(2):113–141.
33. Taylor GI, Caddy CM, Watterson PA, Crock JG. The venous territories (venosomes) of the human body: experimental study and clinical implications. *Plast Reconstr Surg.* 1990;86(2):185–213.
34. Taylor GI, Ives A. The angiosome concept, in *Operative microsurgery.* McGraw-Hill Education; 2015.
35. Lebreton E, Assouline A. [Venous drainage of Littler's neurovascular pedicle flap]. *Ann Chir Main.* 1988;7(2):126–129.
36. Hamilton WJ, Boyd JD, Mossman UW. *Human Embryology.* 4th ed. London: Macmillan Press LTD; 1978.
37. Chevrel JP, d'Anatomie eMdCMFdP *Anatomie Clinique. 1 Les membres.* 1. Paris, France: Springer-Verlag France; 1991.
38. Rodriguez-Niedenfuhr M, Burton GJ, Deu J, Sanudo JR. Development of the arterial pattern in the upper limb of staged human embryos: normal development and anatomic variations. *J Anat.* 2001;199(Pt 4):407–417.
39. Wilke J, Krause F, Niederer D, Engeroff T, Nurnberger F, et al. Appraising the methodological quality of cadaveric studies: validation of the QUACS scale. *J Anat.* 2015;226(5):440–446.
40. Lhuairé M, Tonnelet R, Renard Y, Piardi T, Sommacale D, et al. Developmental anatomy of the liver from computerized three-dimensional reconstructions of four human embryos (from Carnegie stage 14 to 23). *Ann Anat.* 2015;200:105–113.
41. Lhuairé M, Martínez A, Kaplan H, Nuzillard JM, Renard Y, et al. Human developmental anatomy: microscopic magnetic resonance imaging (muMRI) of four human embryos (from Carnegie Stage 10 to 20). *Ann Anat.* 2014;196(6):402–409.