

Contrast enhanced magneto-motive ultrasound in lymph nodes - modelling and pre-clinical imaging using magnetic microbubbles *

Sandra Sjöstrand, Marion Bacou, Adrian Thomson, Katarzyna Kaczmarek, Maria Evertsson, Ingrid Svensson, Susan M. Farrington, Susan Moug, Tomas Jansson *Member, IEEE*, Carmel M. Moran, Helen Mulvana *Member, IEEE*

Abstract— Despite advances in MRI, the detection and characterisation of lymph nodes in rectal cancer remains complex, especially when assessing the response to neo-adjuvant treatment. An alternative approach is functional imaging, previously shown to aid characterization of cancer tissues. We report proof-of-concept of the novel technique Contrast-Enhanced Magneto-Motive Ultrasound (CE-MMUS) to recover information relating to local perfusion and lymphatic drainage, and interrogate tissue mechanical properties through magnetically induced tissue deformations.

The feasibility of the proposed application was explored using a combination of pre-clinical ultrasound imaging and finite element analysis. First, contrast enhanced ultrasound imaging on one wild type mouse recorded lymphatic drainage of magnetic microbubbles after bolus injection. Second, preliminary CE-MMUS data were acquired as a proof of concept. Third, the magneto-mechanical interactions of a magnetic microbubble with an elastic solid were simulated using finite element software.

Accumulation of magnetic microbubbles in the inguinal lymph node was verified using contrast enhanced ultrasound, with peak enhancement occurring 3.7 s post-injection. Preliminary CE-MMUS indicates the presence of magnetic contrast agent in the lymph node. The finite element analysis explores how the magnetic force is transferred to motion of the solid, which depends on elasticity and bubble radius, indicating an inverse relation with displacement.

Combining magnetic microbubbles with MMUS could harness the advantages of both techniques, to provide perfusion information, robust lymph node delineation and characterisation based on mechanical properties.

Clinical Relevance— Robust detection and characterisation of lymph nodes could be aided by visualising lymphatic drainage of magnetic microbubbles using contrast enhanced ultrasound imaging and magneto-motion, which is dependent on tissue mechanical properties.

I. INTRODUCTION

Lymphatic spread is an important risk in the progression of colorectal cancer (CRC) [1] meaning that lymph node status must be considered during staging and to inform subsequent treatment planning in CRC [2], as well as other metastatic disease known to progress through lymphatic spread [3-6].

*Research supported by Cancer Research UK (A23333 / 24730).

H Mulvana is with the Department of Biomedical Engineering at the University of Strathclyde, Glasgow, UK. (helen.mulvana@strath.ac.uk).

S Sjöstrand, M Evertsson and I Svensson are with Department of Biomedical Engineering, Faculty of Engineering, Lund University, Lund, Sweden; M Bacou and SM Farrington are with Cancer Research UK Edinburgh Centre, Institute of Genetics and Cancer, University of Edinburgh, Edinburgh, UK;

Reliable lymph node assessment is critical to treatment pathway planning and to inform decision making around the need for neo-adjuvant therapy prior to surgery.

In the UK, all CRC patients undergo contrast CT and MRI imaging during pre-treatment staging [7], but these techniques are limited in their ability to detect and characterize lymph tissue or extra-nodal tumor deposits, especially in determining cancer spread and therefore assessing the need for neo-adjuvant therapy [8]. In many cases, a full assessment of disease extent can only be made through post-surgical pathology. The ability to accurately stage lymph nodes, in CRC in particular, holds significant potential to guide the level of surgical intervention required, and in some cases reduce the number of patients undergoing major surgery who it may have been possible to treat effectively with a smaller resection [9]. Such patients will benefit from a reduced risk of complications, faster post-surgical recovery, and potential improvements in post-surgical quality of life.

Ultrasound imaging is ubiquitous in clinical diagnostics, offering non-ionising, real-time imaging well suited to soft tissue. Contrast-enhanced ultrasound (CEUS) employs gas microbubbles as a contrast agent to deliver improved image quality and provide additional functionality, in particular, information relating to tissue perfusion. CEUS has recently been applied to lymph node imaging [10], and in our group to study the relationship between lymph node size and metastatic status [11].

Magneto-motive ultrasound (MMUS) is a relatively new technique also using ultrasound. In this case, the contrast agent is magnetic nanoparticles, which when excited using an externally-applied, alternating magnetic field, act to displace the tissue they are located within. High-resolution ultrasound is used to image the resulting tissue movement such that displacements in the micron range, and exceeding the diffraction limit of the ultrasound frequency being employed, are recovered [12]. MMUS has been used to identify lymph nodes in rats.

To harness the useful properties of both microbubbles and MMUS, we propose using magnetic microbubbles for contrast enhanced magneto-motive ultrasound (CE-MMUS). The aim of this study is to demonstrate the potential of CE-MMUS to

A Thomson and CM Moran are with the Centre for Cardiovascular Science, University of Edinburgh, Edinburgh UK; K Kaczmarek is with the Department of Biomedical Engineering at the University of Strathclyde, Glasgow, UK; S Moug is with the Department of Surgery, Royal Alexandra Hospital, Paisley, UK; T Jansson is with Department of Clinical Sciences Lund, Biomedical Engineering, Lund University, and Clinical Engineering Skåne, Digitalising IT/MT, Skåne Regional Council Lund, Sweden.

detect and evaluate lymph nodes in relation to metastatic spread in cancers such as colorectal cancer.

II. METHODS

Magnetic microbubble perfusion and magnetomotive response were investigated in two separate *in vivo* experiments and in a finite element simulation.

A. Animal model

Mice (C57BL/6J) were purchased from Charles River UK and maintained in groups of 2–5 in individually ventilated cages. All animal experiments were approved by the University of Edinburgh Animal Welfare and Ethical Review Body and were conducted in accordance with the Animal (Scientific Procedures) Act UK 1968, and performed under a UK Home Office project license (P02F16F82).

B. Contrast enhanced ultrasound imaging (CEUS)

Magnetic microbubbles were prepared by attaching magnetic nanoparticles (FluidMAG-CMX, 50 nm, chemicell, Berlin, Germany) to MicroMarker (FUJIFILM VisualSonics Inc. Toronto, Canada) through a biotin-streptavidin bond [13]. To determine suitability of the magnetic microbubbles for ultrasound contrast imaging of lymph nodes, a study was performed in a wild type mouse. Procedures were carried out under isoflurane anaesthesia, vital signs were monitored and remained within normal ranges throughout. The inguinal lymph node was imaged at 25 frames per second using a 20 MHz transducer (MX250, using the Vevo 3100, FUJIFILM VisualSonics, Toronto, Canada). A single bolus of magnetic microbubbles was injected in the tail vein and non-linear contrast mode data were acquired for 30 s from the time of injection. The animal was sacrificed whilst anaesthetised directly after imaging.

C. Contrast enhanced magneto-motive ultrasound imaging (CE-MMUS)

A magneto-motive field was generated using a solenoid (in-house construction) driven with signal generator (33220A, Agilent, Technologies UK) and amplifier (Behringer EP4000, Willich, Germany), such that a 4 Hz, 3.8 Vpp sinusoid was amplified by 29 dB. This resulted in a rms magnetic field of 0.14 T at a location 4 mm above the focus, which was the approximate location of the inguinal lymph node.

Magnetic nanoparticles (FluidMAG-CMX, 50 nm, chemicell, Berlin, Germany) were biotinylated [13] and administered intra-dermal (50 μ l) to the left hock to drain to the left inguinal lymph node for 24 hours prior to imaging. The right inguinal lymph node acted as a negative control. Target ready Micromarker (50 μ l) were administered IV to the tail vein immediately prior to CE-MMUS imaging.

To investigate the potential for magnetic particles and microbubbles to improve the ability to image lymph nodes, and demonstrate CE-MMUS, a study was performed on a wild type mouse. Procedures were carried out under isoflurane anaesthesia, vital signs were monitored and within normal ranges. MMUS and CE-MMUS imaging were performed using the MX550D transducer with centre frequency of 40 MHz and Vevo 3100 preclinical ultrasound scanner (VisualSonics, Toronto, Canada). The transducer was positioned opposite the solenoid and aligned with acoustic

focus coincident with the cone tip. The transducer was translated axially away from the cone tip to make space for the interrogation target (mouse) to be placed between the solenoid and ultrasound transducer. Couplant gel was used to provide acoustic coupling to the transducer and the mouse was adjusted to allow the inguinal lymph node to be visualized under B-mode imaging.

MMUS and CE-MMUS imaging of the inguinal lymph nodes was performed at 199 frames per second concurrent to the lymph nodes being subject to the magneto-motive field. Imaging of the left inguinal lymph node was undertaken prior to administration of Micromarker (MMUS), post administration of Micromarker (CE-MMUS) and post mortem (cervical dislocation). Imaging of the right inguinal lymph node was undertaken post mortem. Both lymph nodes were excised and placed in a volume of ultrasound couplant and imaged again.

Raw data was acquired as IQ (in-quadrature) files for post-processed in Matlab. The MMUS signal was received (custom script [12]) yielding mean rms tissue displacement in each lymph node interrogated. Acquisitions were repeated three times for each condition.

D. FEA

The mechanical response of a magnetic microbubble contacting an elastic solid was modelled using a finite element simulation software (COMSOL Multiphysics version 5.6, Stockholm, Sweden).

The magnetic microbubble was represented by a 2 nm thick elastic shell, Young's modulus 100 MPa, Poisson's ratio 0.499, density 1100 kg/m³, radius 1.05 μ m subjected to an internal (Young-Laplace) pressure due to the gaseous core, that depends on the 25 mN/m surface tension [14], and initial bubble radius. The rotational symmetry of the geometry was utilised to reduce analysis complexity and time. The solid was modelled as isotropic and linearly elastic, values of Young's modulus, Poisson's ratio and density of 24 kPa, 0.42 [15], and 1300 kg/m³ respectively were used [16]. A force of 1 pN was applied to the microbubble shell, adapted from estimate in [17], causing it to come into contact with, and deform, the elastic solid. The penalty method was used to make the contact definition and the deformation at the centre point of contact, or midpoint displacement, was compared for different ranges of Young's modulus of the solid and radii of the bubble. The model outputs were also compared to an analytical solution of frictionless contact between a sphere and an elastic half space [18].

III. RESULTS

A. CEUS

Contrast enhanced imaging of the left inguinal lymph node was performed using magnetic microbubbles and the echo-power within the lymph node recovered (Fig. 1).

The echo-power in the lymph node initially increased following microbubble administration, and decreased after reaching a maximum. At the end of the sequence the echo-power was still elevated as compared to before administration.

B. CE-MMUS

MMUS or CE-MMUS imaging of each lymph node was performed to reveal the mean displacement in microns in each (Fig. 2). In order to maintain consistency of imaging and preservation of the region of interest, all left lymph node imaging was completed prior to moving the ultrasound focus to image the right lymph node. No MMUS displacement was recorded in the right lymph node. This was as expected since magnetic nanoparticles were delivered to the left hock only.

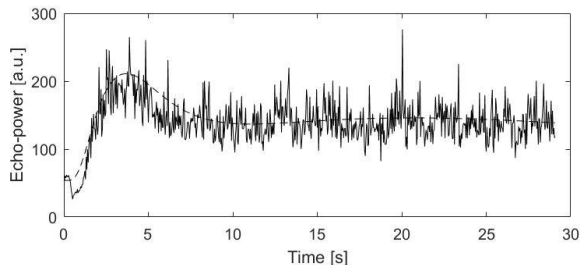


Figure 1: Echo-power in arbitrary unit (a.u.) in a region of interest representing the lymph node. A bolus injection of magnetic microbubbles was administered at the beginning of the recording (0 s). The filling of the region of interest has peak enhancement 3.7 s post injection.

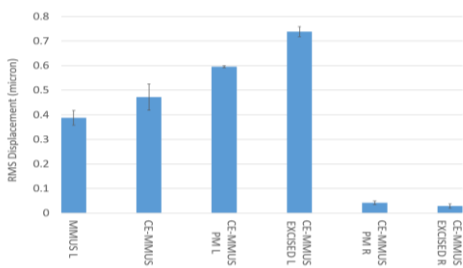


Figure 2: Mean MMUS and CE-MMUS displacement (rms) in microns for each lymph node and condition investigated, where the anatomical location of the lymph node is expressed as L (left) and R (right) and PM indicates post mortem condition. The right lymph node was not expected to show any MMUS signal as magnetic particles were only administered to the left hock. Errors are \pm standard deviation, $n=3$.

C. FEA

Finite element modelling illustrated displacement in tissue occurring as a result of a magnetic microbubble being forced into it. The influence of tissue stiffness and microbubble radius on displacement was investigated (Fig. 3).

Displacement decreases with increasing Young's Modulus, and is increased by decreasing microbubble radius. Smaller microbubbles induce a larger displacement, but the area over which force transfer takes place is reduced, due to reduced contact area (results not shown).

IV. DISCUSSION

Medical imaging is important in diagnosis, staging, and treatment planning [7] of cancer [19]. Information about the location and status of lymph nodes can guide treatment planning and holds the potential to allow a more conservative surgical procedure, with associated short and long-term benefits to the patient's quality of life. However, for some

cancers, targeted resection is not always possible due to the absence of robust methods for obtaining reliable and accurate lymph node assessment [20]. Contrast enhanced ultrasound using microbubbles [21] and magneto-motive ultrasound imaging [22] have been separately demonstrated as feasible methods for lymph node detection. It has been hypothesized that combining the methods could have synergistic effects and enhance sensitivity [23].

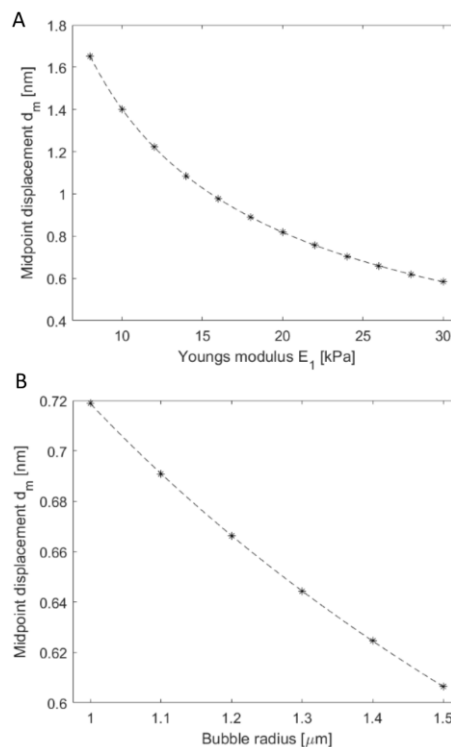


Figure 3: Midpoint displacement outputs for a magnetic microbubble contacting an elastic solid. Results are shown for ranges of two parameters, (A) Young's moduli of the solid ranging from 8 kPa to 30 kPa, (B) bubble radii, 1-1.5 μm . While one parameter was varied, the others were kept constant at 24 kPa and 1.05 μm , respectively. Curves fitted based on analytical theory of contact.

MMUS is capable of delineating lymph nodes in rat studies and of detecting relatively small alterations in stiffness in tissue phantom studies [24]. CEUS has previously been demonstrated for imaging lymph nodes, and can assess differences in flow dynamics, specifically the filling time, that arise in the vicinity of a cancerous growth [11]. Our results (Fig. 1) confirm utility is preserved in magnetic microbubbles, providing a foundation for the novel method of CE-MMUS.

Simulation studies (Fig. 3) indicate how a magnetic microbubble subject to an alternating magnetic field will interact with a local tissue boundary. Microbubble suspensions with a smaller mean diameter will induce larger tissue displacements, e.g. 2 μm diameter microbubbles will generate approximately 20% larger displacements as compared to those of a 3 μm diameter. Such data provides insight to optimise CE-MMUS through magnetic microbubble design.

Finally, we present first proof of principle data for CE-MMUS in a mouse model (Fig. 2). Our data indicate that when

target-ready microbubbles are used alongside biotinylated magnetic nanoparticles, the mean tissue displacement is increased *in vivo* ($0.47 \pm 0.03 \mu\text{m}$ as compared to $0.39 \pm 0.05 \mu\text{m}$). Further work is underway to determine the true nature of this enhanced displacement measurement and the role of magnetic microbubbles. Larger tissue displacement is also measured in lymph nodes post-mortem and once excised. The post mortem animal will not be subject to physiological movement, while the excised lymph node, also static, is more easily imaged, both factors which will improve MMUS signal recovery and therefore hold potential to improve sensitivity. Finally, the addition of microbubbles (with or without magnetic particles) is likely to improve image quality, even in B-mode acquisition, and this alone may improve sensitivity to MMUS displacement. Work continues to establish the role of microbubbles in improving MMUS image quality, accurate lymph node delineation and tissue stiffness estimation, however, data presented here indicate the potential of the technique as a novel addition to the diagnostic tools available to clinicians seeking to determine lymph node status to aid in treatment planning.

V. CONCLUSION

These preliminary data explore feasibility of combining MMUS and CEUS by using magnetic microbubbles for contrast enhanced MMUS (CE-MMUS). We demonstrate proof of principle of CE-MMUS and illustrate its potential to provide new diagnostic data that may aid in robust detection and characterisation of lymph nodes in cancer imaging.

ACKNOWLEDGMENT

This research was funded by CRUK-grant numbers A23333/24730, Program Award DRCPGM100012 (S.M.F.), Kamprad Family Foundation, ref no 20150065, Swedish Research Council, ref no 2015-05118, and Olle Engkvist Foundation, ref no 196-0143.

REFERENCES

- [1] Willaert W, Mareel M, Van De Putte D, Van Nieuwenhove Y, Pattyn P, Ceelen W. Lymphatic spread, nodal count and the extent of lymphadenectomy in cancer of the colon. *Cancer Treatment Reviews*. 2014;40(3):405-13.
- [2] Garcia-Aguilar J, Pollack J, Lee S-H, De Anda EH, Mellgren A, Wong WD, et al. Accuracy of endorectal ultrasonography in preoperative staging of rectal tumors. *Diseases of the colon & rectum*. 2002;45(1):10-15.
- [3] Specht MC, Fey JV, Borgen PI, Cody IIIHS. Is the clinically positive axilla in breast cancer really a contraindication to sentinel lymph node biopsy? *Journal of the American College of Surgeons*. 2005;200(1):10-14.
- [4] Barth A, Craig PH, Silverstein MJ. Predictors of axillary lymph node metastases in patients with T1 breast carcinoma. *Cancer*. 1997;79(10):1918-22.
- [5] Gann PH, Colilla SA, Gapstur SM, Winchester DJ, Winchester DP. Factors associated with axillary lymph node metastasis from breast carcinoma: descriptive and predictive analyses. *Cancer*. 1999;86(8):1511-19.
- [6] Kald BA, Boiesen P, Ronnow K, Jonsson PE, Bisgaard T. Preoperative assessment of small tumours in women with breast cancer. *Scandinavian journal of surgery : SJS : official organ for the Finnish Surgical Society and the Scandinavian Surgical Society*. 2005; 94(1):15-20.
- [7] Cunningham C, Leong K, Clark S, Plumb A, Taylor S, Geh I, et al. Association of Coloproctology of Great Britain & Ireland (ACPGBI): Guidelines for the Management of Cancer of the Colon, Rectum and Anus (2017) – Diagnosis, Investigations and Screening. *Colorectal Disease*. 2017;19(S1):9-17.
- [8] Lord AC, D'Souza N, Shaw A, Rokan Z, Moran B, Abulafi M, et al. MRI-Diagnosed Tumour Deposits and EMVI Status Have Superior Prognostic Accuracy to Current Clinical TNM Staging in Rectal Cancer. *Annals of surgery*. 2020.
- [9] Hurlstone DP, Sanders DS, Brown S, Shorthouse AJ, Cross SS. Endoscopic ultrasound miniprobe staging of colorectal cancer: Can management be modified? *Endoscopy*. 2005; 37(8): 710-14.
- [10] Liu, Y.-B.; Xia, M.; Li, Y.-J.; Li, S.; Li, H.; Li, Y.-L. Contrast-Enhanced Ultrasound in Locating Axillary Sentinel Lymph Nodes in Patients with Breast Cancer: A Prospective Study. *Ultrasound Med. Biol*. 2021, 47, 1475–1483.
- [11] Bacou M, Rajasekaran V, Thomson A, Sjöstrand S, Kaczmarek K, Ochocka-Fox AM, Gerrard AD, Moug S, Jansson T, Mulvana H, Moran CM and Farrington SM, Development of Preclinical Ultrasound Imaging Techniques to Identify and Image Sentinel Lymph Nodes in a Cancerous Animal Model, *Cancers* 2022, 14(3), 561.
- [12] Evertsson, M., Cinthio, M., Fredriksson, S., Olsson, F., Persson, H. W., & Jansson, T. (2013). Frequency- and Phase-Sensitive Magnetomotive Ultrasound Imaging of Superparamagnetic Iron Oxide Nanoparticles. *IEEE Transactions on Ultrasonics, Ferroelectrics and Frequency Control*, 60(3): 481-491.
- [13] Beguin E, Bau L, Shrivastava S, Stride E. Comparing strategies for magnetic functionalization of microbubbles. *ACS Applied Materials & Interfaces*. 2019;11(2):1829-40.
- [14] Borden MA, Longo ML. Dissolution Behavior of Lipid Monolayer-Coated, Air-Filled Microbubbles: Effect of Lipid Hydrophobic Chain Length. *Langmuir*. 2002;18(24):9225-33.
- [15] Fromageau J, Brusseau E, Vray D, Gimenez G, Delachartre P. Characterization of PVA cryogel for intravascular ultrasound elasticity imaging. *IEEE Transactions on Ultrasonics, Ferroelectrics, and Frequency Control*. 2003;50(10):1318-24.
- [16] Stasko J, Kalniņš M, Dzene A, Tupureina V. Poly (vinyl alcohol) hydrogels. *Proceedings of the Estonian Academy of Sciences*. 2009;58(1).
- [17] Chertok B, Langer R. Circulating magnetic microbubbles for localized real-time control of drug delivery by ultrasonography-guided magnetic targeting and ultrasound. *Theranostics*. 2018;8(2):341-57.
- [18] Hertz H. Über die berührung fester elastischer Körper *Journal für die reine und angewandte Mathematik*. 1881 92:pp.156-71.
- [19] Lord AC, Moran B, Abulafi M, Rasheed S, Nagtegaal ID, Terlizzo M, et al. Can extranodal tumour deposits be diagnosed on MRI? Protocol for a multicentre clinical trial (the COMET trial). *BMJ open*. 2020;10(10):e033395.
- [20] Ong ML, Schofield JB. Assessment of lymph node involvement in colorectal cancer. *World journal of gastrointestinal surgery*. 2016;8(3):179.
- [21] Sever AR, Mills P, Jones SE, Cox K, Weeks J, Fish D, et al. Preoperative sentinel node identification with ultrasound using microbubbles in patients with breast cancer. *AJR American journal of roentgenology*. 2011;196(2):251-56.
- [22] Evertsson M, Kjellman P, Cinthio M, Andersson R, Tran TA, In 'T Zandt R, et al. Combined Magnetomotive ultrasound, PET/CT, and MR imaging of (68)Ga-labelled superparamagnetic iron oxide nanoparticles in rat sentinel lymph nodes *in vivo*. *Scientific Reports*. 2017;7(1).
- [23] Sjöstrand S, Evertsson M, Thring C, Bacou M, Farrington SM, Moug S, Jansson T, Moran CM, Mulvana H, Contrast-enhanced magnetomotive ultrasound imaging (CE-MMUS) for colorectal cancer staging: Assessment of sensitivity and resolution to detect alterations in tissue stiffness. 2019 IEEE International Ultrasonics Symposium (IUS); 2019 6-9 Oct. 2019.
- [24] Sjöstrand S, Evertsson M, Jansson T, Magnetomotive Ultrasound Imaging Systems: Basic Principles and First Applications, *Ultrasound Med. Biol*, 2021, 46(10): 2636-2650.