



# Intracranial meningioma in two coeval adult cats from the same litter

Ivona Orgonikova<sup>1</sup> , Lorenzo Mari<sup>1</sup> ,  
 Chiara Giannasi<sup>1</sup>, Martí Pumarola i Batlle<sup>2</sup>,  
 Sebastien Behr<sup>3</sup> and Josep Brocal<sup>1</sup> 

*Journal of Feline Medicine and Surgery Open Reports*  
 1–7

© The Author(s) 2021

Article reuse guidelines:

sagepub.com/journals-permissions

DOI: 10.1177/20551169211025449

journals.sagepub.com/home/jfmsopenreports

This paper was handled and processed by the European Editorial Office (ISFM) for publication in *JFMS Open Reports*



## Abstract

**Case summary** In this report we describe the occurrence of intracranial meningioma in two adult cats from the same litter. The location of the meningioma varied: one tumour was at the level of the brainstem, and the other was affecting the temporal and piriform lobes. The cat with the brainstem meningioma was treated with radiotherapy and the littermate had a rostral tentorial craniectomy for tumour removal. Both cats had a histopathological diagnosis of grade I meningioma of a predominantly fibrous subtype.

**Relevance and novel information** Cases of familial meningioma in cats have not previously been described in the veterinary literature. However, familial meningioma is well described in humans and it is possible that cases are underestimated in animals. We discuss the possible genetic background and other causes, as well as challenges we may face in veterinary medicine in identifying these associations.

**Keywords:** Familial; siblings; brain tumour; seizures; neoplasia

**Accepted:** 27 May 2021

## Case description

### Case 1

A 13-year-old male neutered Norwegian Forest Cat (weight 6.6 kg) was presented with a 5-month history of jaw-chattering episodes lasting a few seconds, followed by sudden jerks of the head and limbs. Episodes were associated with touching the mouth and eating. As a result, the cat was hyporexic. These episodes were suspected to be focal epileptic seizures and myoclonus, and less likely to be a consequence of hyperaesthesia or paraesthesia. Previously diagnosed conditions included suspected triaditis, grade II right medial patellar luxation and left cruciate ligament rupture, feline asthma and T11–T12 vertebral canal stenosis. The cat was being treated with ursodeoxycholic acid (10 mg/kg q24h [Ursodiol; Zydus]), prednisolone (0.4 mg/kg q48h [Prednicortone; Le Vet Beheer]), liver supplement q24h (Hepatosyl Plus, VSL laboratories) and a gastrointestinal diet (Veterinary Gastrointestinal Cat; Royal Canin).

Neurological examination revealed mildly decreased postural reactions in the right thoracic limb, mild mydriasis and reduced pupillary light reflex in the left eye.

Considering the suspected focal epileptic seizures and the neurological examination findings, the neuroanatomical localisation was to the left forebrain and the parasympathetic component of the left oculomotor nerve. Neoplasia (ie, primary brain tumour) was considered the most likely differential diagnosis.

Haematology and biochemistry were unremarkable. MRI (1.5 T, Siemens Magnetom Essenza; Siemens) of the brain revealed a large, round, well-defined extra-axial space-occupying lesion on the left side of the brainstem at the level of mesencephalon and pons, causing mass

<sup>1</sup>Wear Referrals Veterinary Hospital, Bradbury, Stockton-on-Tees, UK

<sup>2</sup>Department of Animal Medicine and Surgery, Murine and Comparative Laboratory Unit, Autonomous University of Barcelona, Bellaterra (Cerdanyola del Vallès), Barcelona, Spain

<sup>3</sup>Willows Veterinary Centre and Referral Service, Solihull, UK

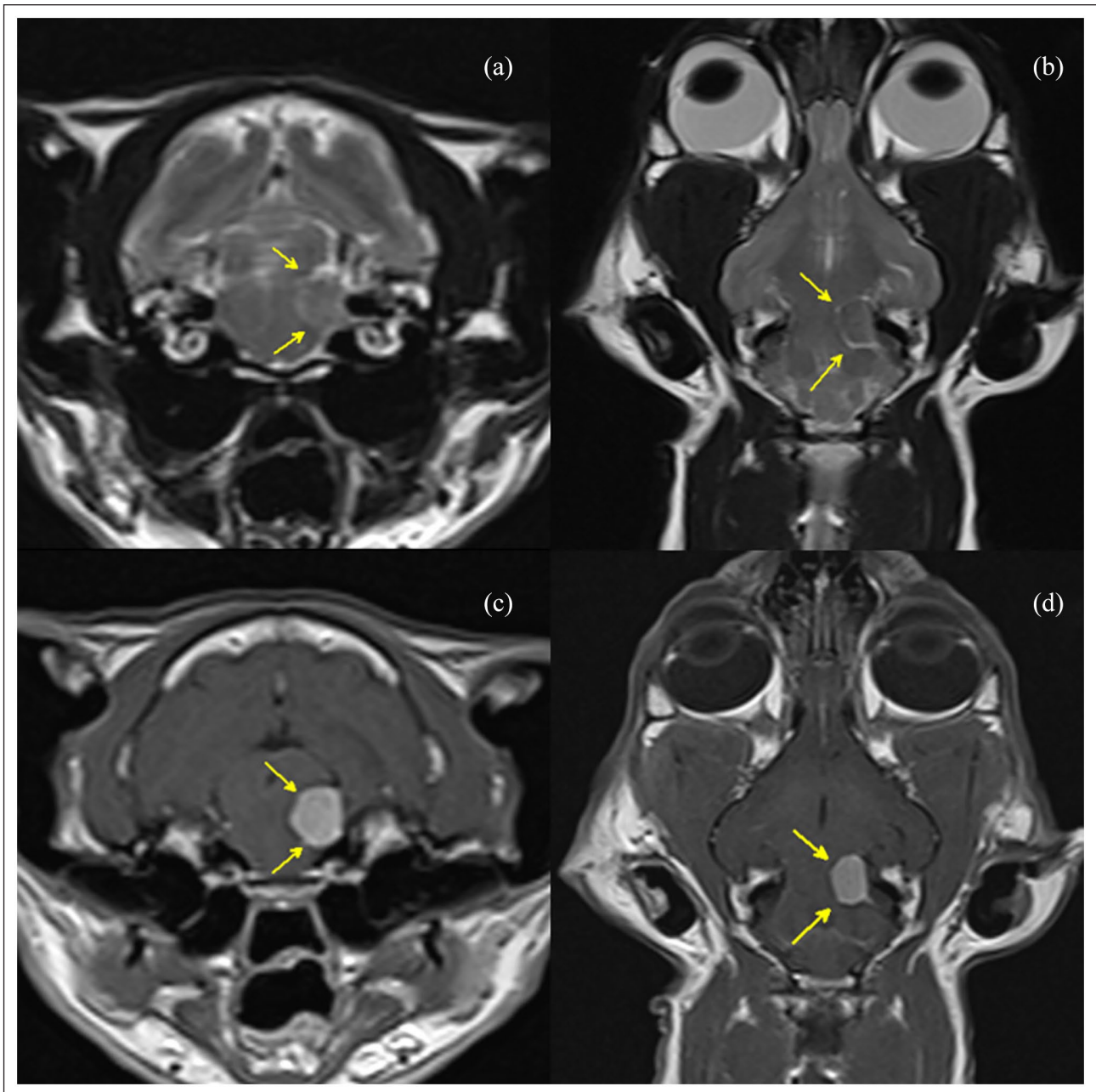
### Corresponding author:

Ivona Orgonikova MVDr, MRCVS, Wear Referrals Veterinary Hospital, Bradbury, Stockton-on-Tees TS21 2ES, UK  
 Email: iorgonikova@gmail.com



Creative Commons Non Commercial CC BY-NC: This article is distributed under the terms of the Creative Commons

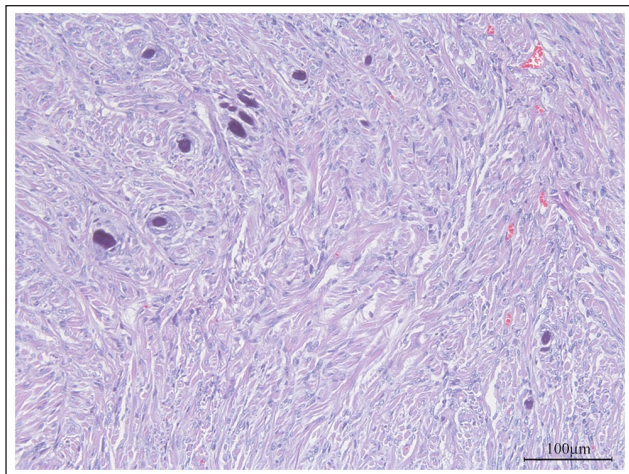
Attribution-NonCommercial 4.0 License (<https://creativecommons.org/licenses/by-nc/4.0/>) which permits non-commercial use, reproduction and distribution of the work without further permission provided the original work is attributed as specified on the SAGE and Open Access pages (<https://us.sagepub.com/en-us/nam/open-access-at-sage>).



**Figure 1** Head MRI of the cat from case 1. T2-weighted (a) transverse and (b) dorsal image of the large, round, well-defined extra-axial isohyperintense mass (arrows) located to the left of the mesencephalon and pons; and T1-weighted (c) transverse and (d) dorsal post-contrast images at the same levels showing the homogeneous contrast enhancement (arrows)

effect (Figure 1). The mass was isohyperintense in T2-weighted (T2W), and isointense in fluid-attenuated inversion recovery and T1-weighted (T1W) sequences, compared with the grey matter, and presented marked homogeneous contrast enhancement. Routine analysis of cerebrospinal fluid collected from the cerebellomedullary cistern, including cell count, protein quantification and cytology, was normal. A presumptive diagnosis of intracranial meningioma was made.

As the reflex nature of the suspected seizures, treatment with levetiracetam (20mg/kg q8h [Levetiracetam; Zentiva]) was initiated. Prednisolone was maintained at 0.4mg/kg q48h. The cat underwent palliative radiotherapy within 10 weeks of presentation. The protocol consisted of 12 fractions of 4Gy (total dose 48Gy), delivered using a three coplanar beam plan (at 6mV; Johnson Foundation Radiotherapy Unit). Treatment was delivered on a Monday–Wednesday–Friday basis.



**Figure 2** Histopathology of the brainstem tumour of case 1. Transitional meningioma with a predominant fibrous pattern; some concentric structures and multiple basophilic mineralised foci are present (haematoxylin and eosin stain)

Jaw-chattering episodes recurred after completion of the radiotherapy but with markedly reduced severity and frequency, and did not affect the cat's appetite. The neurological abnormalities resolved. At follow-up re-examinations, owing to the persistent hyperglycaemia combined with glucosuria, diabetes mellitus was diagnosed, and insulin treatment was initiated shortly after the radiotherapy, initially with protamine zinc insulin (1 unit SC q12h [ProZinc; Boehringer Ingelheim]), then lente insulin (2 units q12h [Caninsulin; MSD Animal Health]). Eleven months after radiotherapy the cat developed chronic small intestinal diarrhoea, polydipsia, pelvic limb weakness with plantigrade stance and lethargy that progressed to intermittent collapse and abnormal mentation. Further investigations were declined by the owner and humane euthanasia was elected.

The brain of the cat was submitted for histopathology. A full post-mortem examination was not performed. Histopathological diagnosis of transitional meningioma (grade I) was made.<sup>1</sup> The predominant pattern was fibrous with psammoma bodies and abundant areas of mineralisation (Figure 2).

### Case 2

A 13-year-old male neutered Norwegian Forest Cat (weight 7.4kg) from the same litter and same household as case 1 was presented to the same referral centre 4 months later with a cluster of generalised tonic-clonic epileptic seizures. The cat had been previously diagnosed with lumbosacral intervertebral disc protrusion, suspected triaditis, feline asthma, hypothyroidism following radioiodine ( $I^{131}$ ) treatment for hyperthyroidism, mild hypertrophic cardiomyopathy and a left gastric-phrenic portosystemic shunt, and was on treatment with

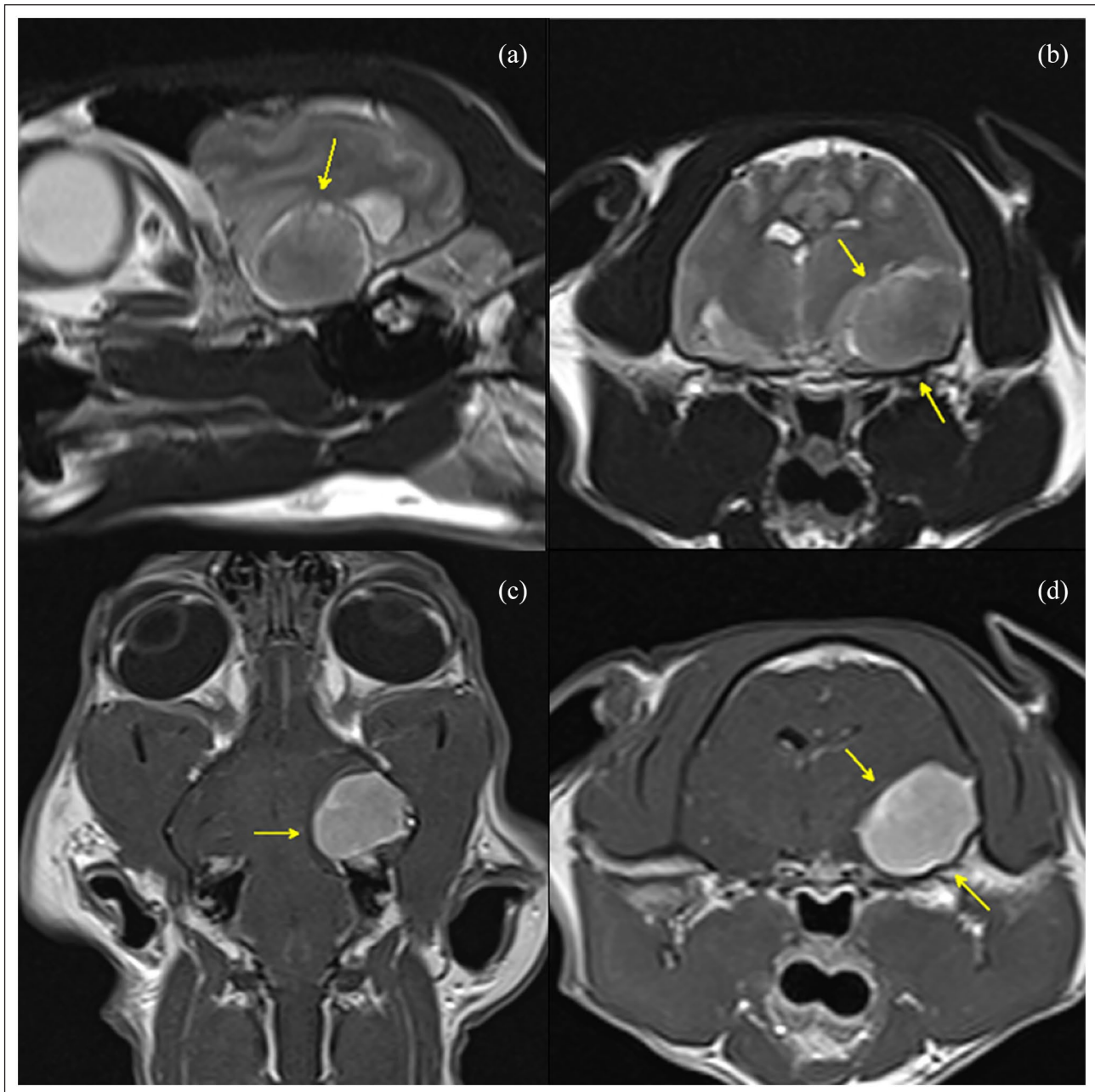
gabapentin (4mg/kg q12h [Gabapentin; Accord-UK]), amantadine (1mg/kg q24h [Symmetrel; Auden McKenzie]), albuterol sulfate inhaler (108µg q12h [Ventolin; GlaxoSmithKline]) and levothyroxine (5µg/kg q12h [Leventa; MSD Animal Health]). The portosystemic shunt was an incidental finding upon abdominal imaging for triaditis. No medical therapy was therefore initiated for the portosystemic shunt.

Clinical examination revealed grade II/VI left-sided systolic heart murmur. Neurological examination showed decreased postural reactions on the right thoracic and pelvic limb and decreased-to-absent menace response bilaterally. The neurolocalisation was focal left-sided forebrain. The most likely differential diagnosis was neoplasia (ie, primary brain tumour).

Haematology was unremarkable. Comprehensive biochemistry revealed markedly elevated creatine kinase (1421µkat/l; reference interval [RI] 10–290) and alanine aminotransferase (ALT; 2339U/l [RI 1–120]), and mildly elevated total protein (78g/l [RI 53–77]) and total thyroxine (46.3U/l [RI 13.3–44.7]). The rest of the parameters were within normal limits. Creatine kinase and ALT returned to normal 3 weeks later, suggesting that their transient increase was most likely the consequence of the recent epileptic activity. Feline immunodeficiency virus and feline leukaemia virus SNAP testing was negative. *Toxoplasma* serum titres were negative. Abdominal ultrasound findings were consistent with choledocholithiasis. MRI of the head showed a large, rounded, well-defined, extra-axial space-occupying lesion at the level of the left piriform and temporal lobes causing severe mass effect with midline shift, caudotentorial and foramen magnum herniation. The mass was T2W iso-hyperintense and T1W isohypointense, compared with grey matter, and was strongly homogeneously contrast enhancing (Figure 3). A presumptive diagnosis of intracranial meningioma was made.

A left sided rostral tentorial craniectomy was performed and the tumour was removed by en-bloc resection. Recovery from the surgery was uneventful. A tapering dose over 12 weeks of prednisolone (Prednicortone; Le Vet Beheer) starting at 0.4mg/kg q24h was initiated along with levetiracetam (30mg/kg q8h [Levetiracetam; Zentiva]). Histopathological diagnosis was a fibrous meningioma (grade I) with rare foci of mineralisation (Figure 4).

Three months after surgery the cat was diagnosed with alimentary, small-cell lymphoma after presenting with recurrent constipation and hyporhexia. The diagnosis was obtained based on the gastroduodenoscopy and colonoscopy findings, as well as on histopathology of the endoscopically biopsied tissues. Treatment with chlorambucil (0.3mg/kg q48h [Leukeran; GlaxoSmithKline Pharmaceuticals]) was initiated alongside the previously prescribed medical therapy. Six months postoperatively



**Figure 3** Head MRI of case 2. T2-weighted (a) sagittal and (b) transverse image of the isohyperintense extra-axial rounded mass at the level of the left piriform and temporal lobe (arrows), and post-contrast T1-weighted (T1W) (c) transverse and (d) T1W fat-saturated dorsal image at the same levels showing its marked homogeneous contrast enhancement (arrows)

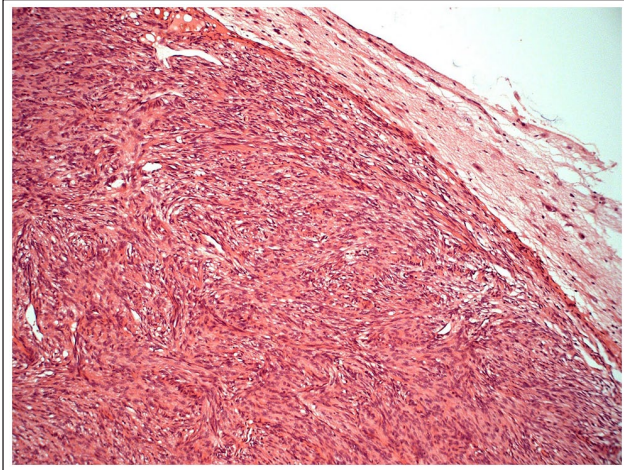
the cat had a cluster of generalised tonic–clonic epileptic seizures. Repeat MRI was declined. The cat continued to do well 18 months after the initial presentation, without further epileptic activity.

### Discussion

We described the occurrence of intracranial meningioma (grade I)<sup>1</sup> in two adult cats from the same litter and household that presented 4 months apart. To our knowledge, familial meningioma has not previously been

reported in cats. The possibility that these two cats simultaneously developed the same meningioma subtype by random chance has been considered. This was deemed unlikely, taking into the account that Norwegian Forest Cats were not an over-represented breed in previous studies of cat meningioma.<sup>2,3</sup>

Meningioma is the most common extra-axial intracranial brain tumour in cats (32.8–73%)<sup>2–4</sup> and people.<sup>5–8</sup> Human family history studies suggest a role for inherited susceptibility to many central nervous system (CNS)



**Figure 4** Histopathology of the lesion in the left temporal and piriform lobe of case 2. Fibrous meningioma. Intersecting streams of spindle cells amidst a prominent collagenous stroma. Haematoxylin and eosin  $\times 100$

tumours, including intracranial meningiomas.<sup>5,6,9,10</sup> There is a proven increased risk of intracranial meningioma in humans with a first-degree family history of meningioma,<sup>5,9,11</sup> and the association is even stronger when the diagnosis is made in people  $<55$  years of age.<sup>5</sup> Children, parents and siblings are considered first-degree family members,<sup>5,9</sup> like the two cats described herein.

In humans, many genetic syndromes predisposing to meningioma exist, with neurofibromatosis type 2 (NF2) being the most reported.<sup>6,12,13</sup> However, even when patients with NF2 are excluded from the population, familial relations for meningiomas remain evident.<sup>5,6,9</sup>

NF2 is a tumour predisposition syndrome characterised by the development of distinctive nervous system lesions (eg, schwannomas, meningiomas and ependymomas).<sup>12–20</sup> Although the typical lesions generally include vestibular schwannomas, and tend to present more in children, meningiomas are detected in approximately 50% of patients with NF2,<sup>15</sup> concurrently with, or occasionally also independently from, the presence of vestibular schwannomas, and the disease can manifest at older age.<sup>12–20</sup> NF2 results from germline mutations in the NF2 tumour suppressor gene located on chromosome 22q12 with autosomal dominant inheritance.<sup>15</sup> Apart from inherited NF2, in up to 60% of sporadic meningioma cases spontaneous mutations in NF2 were found.<sup>16–19</sup> NF2 is responsible for expression of the protein merlin (membrane-associated protein).<sup>15,21</sup> Abnormal or absent merlin function can disrupt tumour suppression via various mechanisms affecting the membrane organisation of proteins, cell–cell adhesion, cytoskeletal architecture or interaction with cytosolic proteins.<sup>15</sup> Interestingly, NF2-associated meningiomas may be of any histological

subtype, but are most often of the fibrous variant,<sup>22</sup> which was diagnosed in both cases presented herein. The reason behind the development of fibrous morphology in NF2-deficient tumours is not entirely clear. Relation to the dysregulation of cell–cell adhesion (due to merlin deficiency) leading to a more ‘mesenchymal’ spindled phenotype is hypothesised.<sup>14</sup> Likelihood of an identical histology of meningioma in two family members in humans is around 46%,<sup>11</sup> with low-grade tumours (World Health Organization grade I)<sup>23</sup> more likely to occur in familial cases, compared with sporadic cases.<sup>24</sup>

Experimental models have suggested that NF2 mutations alone may not be sufficient to promote tumorigenesis, and additional genetic alterations are likely required.<sup>25</sup> Other genetic mutations associated with meningioma exist in human medicine, affecting, for example, genes encoding enzymes involved in apoptotic mechanisms, cell-cycle control or DNA repair.<sup>13</sup> These mutations may predispose to other tumours as well.<sup>26–30</sup> For example, abnormalities in the tumour suppressor gene *PTEN* were found to play a role in the pathogenesis of meningiomas, as well as haematological malignancies.<sup>31</sup> Case 2 was also diagnosed with alimentary small-cell lymphoma, further supporting a possible underlying genetic background predisposing to tumours. Genomic profiling has the potential to differentiate between sporadic and familial meningiomas, and define the risk of occurrence in family members.<sup>24</sup> The pedigrees of the reported cats were analysed to identify other affected subjects in the family line and assess consanguinity, which was not detected in the five preceding generations. We unsuccessfully attempted to collect clinical information and DNA samples from relatives for whole-genome sequencing by contacting the Norwegian Forest Cat Club in the UK, making further genetic investigations impossible. Pedigrees containing information about diseases in individuals are lacking, likely making the occurrence of familial meningioma in cats underestimated. Such informative pedigree analysis would have a great potential to identify the genetic background in familial and sporadic cases of meningioma in cats.

A possible connection between genetic defects and feline meningioma has previously been hypothesised in a study describing meningioma in young cats in association with mucopolysaccharidosis (MPS) I. The authors of the study hypothesised that a gene locus important in meningioma tumorigenesis and the locus of the enzyme alpha-L-iduronidase (defective in MPS I) may be closely located. Another hypothesis was that accumulation of the metabolite products can be associated with tumorigenesis of the arachnoid cells and therefore predispose to meningioma.<sup>32</sup>

The possibility that the meningioma in these two cats from the same household was environmentally related has been considered. A human study found that spouses

(genetically unrelated people exposed to similar environments) of people with brain tumours were not at higher risk of brain tumours, while first-degree relatives were.<sup>9</sup> The role of specific environmental risk factors in humans (eg, cigarette smoking, mobile phone use, exposure to electromagnetic fields or to lead) has been investigated and was found to be insignificant or inconsistent.<sup>33</sup> All these findings support a predominant role of genetic factors vs environmental factors in the occurrence of primary brain tumours in people, and make an environmental cause for simultaneous development of meningioma in these two cats less likely.

Apart from genetic associations, other risk factors for the development of meningioma in humans exist such as exposure to ionising radiation.<sup>34–39</sup> Interestingly, developing meningioma after exposure to radiotherapy in humans appears to have an inherited component.<sup>40</sup> Neither reported cat underwent radiotherapy before the occurrence of the meningioma. The cat described in case 2 had radioactive iodine treatment 2 years before the meningioma diagnosis. An association between radioiodine treatment and meningioma has not been confirmed in humans or in cats.<sup>41–43</sup> In human meningiomas, female sex is another risk factor;<sup>8</sup> whereas, male cats (as the cats described herein) are more commonly reported in the veterinary literature.<sup>3</sup>

## Conclusions

To our knowledge, this is the first report to describe two cases of meningioma in cats from the same litter presented at the same age. Familial meningiomas are well documented in humans, and predisposing genetic factors, such as *NF2* mutation, are described. No similar predisposing factors have been identified in felids and further investigations in this field would be of great interest and may lead to a better understanding of this common feline primary CNS tumour pathogenesis.

Genetic analysis of feline relatives with meningioma may be challenging given that first-degree family members rarely stay in the same household. This is also a reason to suspect that the prevalence of familial meningioma in cats might be underestimated. Accessible, clinically updated pedigrees might be helpful.

**Conflict of interest** The authors declared no potential conflicts of interest with respect to the research, authorship, and/or publication of this article.

**Funding** The authors received no financial support for the research, authorship, and/or publication of this article.

**Ethical approval** The work described in this manuscript involved the use of non-experimental (owned or unowned) animals. Established internationally recognised high standards ('best practice') of veterinary clinical care for the individual

patient were always followed and/or this work involved the use of cadavers. Ethical approval from a committee was therefore not specifically required for publication in *JFMS Open Reports*. Although not required, where ethical approval was still obtained, it is stated in the manuscript.

**Informed consent** Informed consent (either verbal or written) was obtained from the owner of all animal(s) described in this work (either experimental or non-experimental animals, including cadavers) for all procedure(s) undertaken (either prospective or retrospective studies). For any animals or people individually identifiable within this publication, informed consent (verbal or written) for their use in the publication was obtained from the people involved.

**ORCID iD** Ivona Orgonikova  <https://orcid.org/0000-0001-8821-1467>

Lorenzo Mari  <https://orcid.org/0000-0002-5732-1011>

Josep Brocal  <https://orcid.org/0000-0002-3019-1317>

## References

- Higgins RJ, Bollen AW, Dickinson PJ, et al. **Tumors of the nervous system.** In: Tumors in domestic animals. 5th ed. Chichester: Wiley-Blackwell, 2016, pp 834–891.
- Tomek A, Cizinauskas S, Doherr M, et al. **Intracranial neoplasia in 61 cats: localisation, tumour types and seizure patterns.** *J Feline Med Surg* 2006; 8: 243–253.
- Troxel MT, Vite CH, Van Winkle TJ, et al. **Feline intracranial neoplasia: retrospective review of 160 cases (1985–2001).** *J Vet Intern Med* 2003; 17: 850–859.
- Troxel MT, Vite CH, Massicotte C, et al. **Magnetic resonance imaging features of feline intracranial neoplasia: retrospective analysis of 46 cats.** *J Vet Intern Med* 2004; 18: 176–189.
- Claus EB, Calvocoressi L, Bondy ML, et al. **Family and personal medical history and risk of meningioma.** *J Neurosurg* 2011; 115: 1072–1077.
- Hemminki K, Tretli S, Sundquist J, et al. **Familial risks in nervous-system tumours: a histology-specific analysis from Sweden and Norway.** *Lancet Oncol* 2009; 10: 481–488.
- Sun C, Dou Z, Wu J, et al. **The preferred locations of meningioma according to different biological characteristics based on voxel-wise analysis.** *Front Oncol* 2020; 10: 1412. DOI: 10.3389/fonc.2020.01412.
- Saraf S, McCarthy BJ and Villano JL. **Update on meningiomas.** *Oncologist* 2011; 16: 1604–1613.
- Malmer B, Henriksson R and Grönberg H. **Familial brain tumours-genetics or environment? A nationwide cohort study of cancer risk in spouses and first-degree relatives of brain tumour patients.** *Int J Cancer* 2003; 106: 260–263.
- Hemminki K, Li X and Collins VP. **Parental cancer as a risk factor for brain tumors (Sweden).** *Cancer Causes Control* 2001; 12: 195–199.
- Hemminki K and Li X. **Familial risks in nervous system tumors.** *Cancer Epidemiol Biomark Prev* 2003; 12: 1137–1142.
- Kerr K, Qualmann K, Esquenazi Y, et al. **Familial syndromes involving meningiomas provide mechanistic insight into sporadic disease.** *Neurosurgery* 2018; 83: 1107–1118.

- 13 Huntoon K, Toland AMS and Dahiya S. **Meningioma: a review of clinicopathological and molecular aspects.** *Front Oncol* 2020; 10: 579599. DOI: 10.3389/fonc.2020.579599.
- 14 Coy S, Rashid R, Stemmer-Rachamimov A, et al. **An update on the CNS manifestations of neurofibromatosis type 2.** *Acta Neuropathol (Berl)* 2020; 139: 643–665.
- 15 Asthagiri AR, Parry DM, Butman JA, et al. **Neurofibromatosis type 2.** *Lancet* 2009; 373: 1974–1986.
- 16 Seizinger BR, de la Monte S, Atkins L, et al. **Molecular genetic approach to human meningioma: loss of genes on chromosome 22.** *Proc Natl Acad Sci U S A* 1987; 84: 5419–5423.
- 17 Wellenreuther R, Kraus JA, Lenartz D, et al. **Analysis of the neurofibromatosis 2 gene reveals molecular variants of meningioma.** *Am J Pathol* 1995; 146: 827–832.
- 18 Ueki K, Wen-Bin C, Narita Y, et al. **Tight association of loss of merlin expression with loss of heterozygosity at chromosome 22q in sporadic meningiomas.** *Cancer Res* 1999; 59: 5995–5998.
- 19 Rutledge MH, Sarrazin J, Rangartnam S, et al. **Evidence for the complete inactivation of the NF2 gene in the majority of sporadic meningiomas.** *Nat Genet* 1994; 6: 180–184.
- 20 Halliday D, Emmanouil B, Pretorius P, et al. **Genetic Severity Score predicts clinical phenotype in NF2.** *J Med Genet* 2017; 54: 657–664.
- 21 Torp SH and Scheie D. **Advances in research on human meningiomas.** *Cancers* 2020; 12: 2702. DOI: 10.3390/cancers12092702.
- 22 Baser ME, Friedman JM, Aeschliman D, et al. **Predictors of the risk of mortality in neurofibromatosis 2.** *Am J Hum Genet* 2002; 71: 715–723.
- 23 Louis DN, Perry A, Reifenberger G, et al. **The 2016 World Health Organization Classification of Tumors of the Central Nervous System: a summary.** *Acta Neuropathol (Berl)* 2016; 131: 803–820.
- 24 Shen Y, Nunes F, Stemmer-Rachamimov A, et al. **Genomic profiling distinguishes familial multiple and sporadic multiple meningiomas.** *BMC Med Genomics* 2009; 2: 42. DOI: 10.1186/1755-8794-2-42.
- 25 Woods R, Friedman JM, Evans DGR, et al. **Exploring the “two-hit hypothesis” in NF2: tests of two-hit and three-hit models of vestibular schwannoma development.** *Genet Epidemiol* 2003; 24: 265–272.
- 26 Sestini R, Vivarelli R, Balestri P, et al. **Neurofibromatosis type 2 attributable to gonosomal mosaicism in a clinically normal mother, and identification of seven novel mutations in the NF2 gene.** *Hum Genet* 2000; 107: 366–371.
- 27 Li D-M and Sun H. **PTEN/MMAC1/TEP1 suppresses the tumorigenicity and induces G1 cell cycle arrest in human glioblastoma cells.** *Proc Natl Acad Sci* 1998; 95: 15406–15411.
- 28 Bayani J, Zielenska M, Marrano P, et al. **Molecular cytogenetic analysis of medulloblastomas and supratentorial primitive neuroectodermal tumors by using conventional banding, comparative genomic hybridization, and spectral karyotyping.** *J Neurosurg* 2000; 93: 437–448.
- 29 Weng L-P, Brown JL, Baker KM, et al. **PTEN blocks insulin-mediated ETS-2 phosphorylation through MAP kinase, independently of the phosphoinositide 3-kinase pathway.** *Hum Mol Genet* 2002; 11: 1687–1696.
- 30 Cairns P, Okami K, Halachmi S, et al. **Frequent inactivation of PTEN/MMAC1 in primary prostate cancer.** *Cancer Res* 1997; 57: 4997–5000.
- 31 Dahia PLM, Aguiar RCT, Alberta J, et al. **PTEN is inversely correlated with the cell survival factor Akt/PKB and is inactivated via multiple mechanisms in haematological malignancies.** *Hum Mol Genet* 1999; 8: 185–193.
- 32 Haskins ME and McGrath JT. **Meningiomas in young cats with mucopolysaccharidosis I.** *J Neuropathol Exp Neurol* 1983; 42: 664–670.
- 33 Barnholtz-Sloan JS and Kruchko C. **Meningiomas: causes and risk factors.** *Neurosurg Focus* 2007; 23: E2.
- 34 Al-Mefty O, Topsakal C, Pravdenkova S, et al. **Radiation-induced meningiomas: clinical, pathological, cytogenetic, and cytogenetic characteristics.** *J Neurosurg* 2004; 100: 1002–1013.
- 35 Harrison MJ, Wolfe DE, Lau TS, et al. **Radiation-induced meningiomas: experience at the Mount Sinai Hospital and review of the literature.** *J Neurosurg* 1991; 75: 564–574.
- 36 Hijjiya N, Hudson MM, Lensing S, et al. **Cumulative incidence of secondary neoplasms as a first event after childhood acute lymphoblastic leukemia.** *JAMA* 2007; 297: 1207–1215.
- 37 Mack EE and Wilson CB. **Meningiomas induced by high-dose cranial irradiation.** *J Neurosurg* 1993; 79: 28–31.
- 38 Moss SD, Rockswold GL, Chou SN, et al. **Radiation-induced meningiomas in pediatric patients.** *Neurosurgery* 1988; 22: 758–761.
- 39 Neglia JP, Robison LL, Stovall M, et al. **New primary neoplasms of the central nervous system in survivors of childhood cancer: a report from the Childhood Cancer Survivor Study.** *J Natl Cancer Inst* 2006; 98: 1528–1537.
- 40 Flint-Richter P and Sadetzki S. **Genetic predisposition for the development of radiation-associated meningioma: an epidemiological study.** *Lancet Oncol* 2007; 8: 403–410.
- 41 Damle NA, Bal C, Peepre K, et al. **Occurrence of symptomatic meningioma as a second neoplasm in patients with differentiated thyroid cancer treated with radioiodine.** *Indian J Endocrinol Metab* 2012; 16: 612–613.
- 42 Metso S, Auvinen A, Huhtala H, et al. **Increased cancer incidence after radioiodine treatment for hyperthyroidism.** *Cancer* 2007; 109: 1972–1979.
- 43 Carney HC, Ward CR, Bailey SJ, et al. **2016 AAFP guidelines for the management of feline hyperthyroidism.** *J Feline Med Surg* 2016; 18: 400–416.