

Effect of extracranial lesion severity on outcome of endovascular thrombectomy in patients with anterior circulation tandem occlusion: analysis of the TITAN registry

Mohammad Anadani,¹ Alejandro Spiotta,² Ali Alawieh,³ Francis Turjman,⁴ Michel Piotin,⁵ Henrik Steglich-Arnholm,⁶ Markus Holtmannspötter,⁷ Christian Taschner,⁸ Sebastian Eiden,⁶ Diogo C Hausen,⁹ Raul Nogueira,⁹ Panagiotis Papanagiotou,¹⁰ Maria Boutchakova,¹⁰ Adnan H Siddiqui,¹¹ Bertrand Lapergue,¹² Franziska Dorn,¹³ Christophe Cognard,¹⁴ Monika Killer-Oberpfalzer,¹⁵ Salvatore Mangiafico,¹⁶ Marc Ribo,^{17,18} Marios-Nikos Psychogios,¹⁹ Marc-Antoine Labeyrie,²⁰ Mikael Mazighi,⁵ Alessandra Biondi,²¹ René Anxionnat,^{22,23} Serge Bracard,²² Sébastien Richard,²¹ Benjamin Gory,²² on behalf of the TITAN (Thrombectomy In TANdem Lesions) Investigators

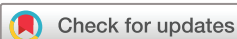► Additional material is published online only. To view please visit the journal online (<http://dx.doi.org/10.1136/neurintsurg-2018-014629>).

For numbered affiliations see end of article.

Correspondence to

Dr Mohammad Anadani, Neurology and Neurosurgery, Medical University of South Carolina, Charleston, SC 29425, USA; anadani@muscc.edu

Received 4 December 2018
Revised 2 February 2019
Accepted 9 February 2019
Published Online First
6 March 2019



© Author(s) (or their employer(s)) 2019. No commercial re-use. See rights and permissions. Published by BMJ.

To cite: Anadani M, Spiotta A, Alawieh A, et al. *J NeuroIntervent Surg* 2019;**11**:970–974.

ABSTRACT

Introduction Endovascular treatment (EVT) for tandem occlusion (TO) of the anterior circulation is complex but effective. The effect of extracranial internal carotid artery (EICA) lesion severity on the outcomes of EVT is unknown. In this study we investigated the effect of EICA lesion severity on the outcomes of tandem occlusion EVT.

Methods A multicenter retrospective TITAN (Thrombectomy In TANdem lesions) study that included 18 international endovascular capable centers was performed. Patients who received EVT for atherosclerotic TO with or without EICA lesion intervention were included. Patients were divided into two groups based on the EICA lesion severity (high-grade stenosis ($\geq 90\%$ North American Symptomatic Carotid Endarterectomy Trial) vs complete occlusion). Outcome measures included the 90-day clinical outcome (modified Rankin Scale score (mRS)), angiographic reperfusion (modified Thrombolysis In Cerebral Ischemia (mTICI) at the end of the procedure), procedural complications, and intracranial hemorrhage at 24 hours follow-up.

Results A total of 305 patients were included in the study, of whom 135 had complete EICA occlusion and 170 had severe EICA stenosis. The EICA occlusion group had shorter mean onset-to-groin time (259 ± 120 min vs 305 ± 202 min; $p=0.037$), more patients with diabetes, and fewer with hyperlipidemia. With respect to the outcome, mTICI 2b–3 reperfusion was lower in the EICA occlusion group (70% vs 81%; $p=0.03$). The favorable outcome (90-day mRS 0–2), intracerebral hemorrhage and procedural complications were similar in both groups.

Conclusion Atherosclerotic occlusion of the EICA in acute tandem strokes was associated with a lower rate of mTICI 2b–3 reperfusion but similar functional and safety outcomes when compared with high-grade EICA stenosis.

INTRODUCTION

Anterior circulation tandem occlusions (TO) represent 15–20% of ischemic strokes due to large vessel occlusions.^{1–5} TO is typically refractory to intravenous thrombolysis (IVT) and requires endovascular treatment (EVT).^{4,6} EVT for TO is complex because of the involvement of two large artery occlusions. It is clear that mechanical thrombectomy is the best approach for intracranial occlusions; in contrast, there is no consensus on the best treatment approach for extracranial internal carotid artery (EICA) lesions. Treatment of intracranial lesions requires advancing the thrombectomy catheters through the stenotic (or occluded) EICA. Therefore, one can hypothesize that the severity of the EICA lesion may affect the success of the EVT.

In this study we aimed to investigate the effect of the EICA lesion severity on the outcome of the EVT by comparing patients with TO who presented with atherosclerotic EICA high-grade stenosis with those with complete EICA occlusion.

METHODS

Study design and population

We used the TITAN (Thrombectomy In TANdem lesions) registry for this study. The TITAN registry gathered data on consecutive patients with anterior TO who underwent EVT at 18 participating international centers between January 2012 and September 2016. Detailed materials have been previously reported.^{6–8} The study was approved by the local Institutional Review Boards. In the present analysis, only patients with atherosclerotic TO were included to ensure homogeneity of our study cohort. TO was defined as EICA occlusion or high-grade stenosis ($\geq 90\%$ NASCET (North American Symptomatic Carotid Endarterectomy Trial))

with a proximal intracranial occlusion (distal internal carotid artery and/or proximal middle cerebral artery). All intracranial occlusions were treated with modern mechanical thrombectomy devices such as contact aspiration or a stent retriever. Intracranial thrombectomy was performed either immediately after the EICA treatment 'Neck-First' or before the EICA treatment 'Head-First'. The order of treatment differed between operators. There were three treatment options for the EICA: (1) EICA stenting; (2) EICA balloon angioplasty; and (3) no treatment. The choice of EICA treatment was left to the discretion of the operator. For the purpose of this study, patients were divided into two groups based on the EICA lesion severity (occlusion vs stenosis).

Definition of outcomes

The two primary endpoints were the 90-day functional outcome and the degree of reperfusion at the end of EVT. Functional outcome was assessed using the modified Rankin Scale (mRS)

score at 90 days, which was obtained either from face-to-face interviews or from telephone conversations. A favorable outcome was defined as mRS 0–2 at 90 days. Degree of reperfusion was assessed by the modified Treatment in Cerebral Ischemia (mTICI) score at the end of the EVT. Successful reperfusion was considered as mTICI 2b–3. mTICI was recorded by each local operators. The safety endpoints included symptomatic intracranial hemorrhage (sICH), procedural complications, and 90-day all-cause mortality. sICH was defined as any intraparenchymal, subarachnoid, or intraventricular hemorrhage with an increase of ≥ 4 points in the National Institute of Health Stroke Scale (NIHSS).⁹

Statistical analysis

Comparison of baseline characteristics and outcome between the occlusion and stenosis groups was performed using the Student's t-test for continuous variables (variables expressed

Table 1 Baseline characteristics

Variable	N	Extracranial ICA lesion		P value
		Occlusion (135)	Stenosis (170)	
Age (years)	305	68 (10)	67 (11)	0.90
Female	304	49 (36)	57 (33)	0.58
Smoker	274	36 (33)	49 (29)	0.56
Baseline NIHSS	305	16 (6)	16 (6)	0.66
ASPECTS ≥ 7	278	87 (77)	130 (79)	0.72
Intracranial occlusion	305			0.23
ICA		36 (27)	56 (33)	
MCA		99 (73)	114 (67)	
Onset-to-groin time (min)	207	259 (120)	305 (202)	0.037
Thrombolysis	305	77 (57)	108 (64)	0.24
Diabetes	283	27 (24)	21 (12)	0.01
Hypertension	282	58 (65)	114 (67)	0.12
Hyperlipidemia	283	28 (34)	79 (47)	0.03
General anesthesia	305	84 (62)	84 (49)	0.02
Puncture to recanalization (min)	300	81 (73)	84 (64)	0.70
EICA treatment				0.92
Stenting	305	90 (67)	115 (68)	
Angioplasty	305	18 (13)	24 (14)	
No treatment	305	27 (20)	31 (18)	
Thrombectomy technique	289			0.453
Stent retriever		105 (83)	141 (86)	
ADAPT		21 (17)	22 (14)	
Order of treatment	289			<0.001
Head-First		61 (48)	46 (28)	
Neck-First		65 (52)	117 (72)	
Peri-procedural antiplatelet	305			0.35
0		41 (34)	45 (27)	
1		38 (32)	58 (34)	
2		41 (34)	67 (39)	

Values are n (%) or mean (SD) or median.

X² test was used for categorical variables, Student's t-test was used for parametric variables, Mann–Whitney test was used for non-parametric variables.

ADAPT, A Direct Aspiration first Pass Technique; ASPECTS, Alberta Stroke Programme Early CT Score; EICA, extracranial internal carotid artery; MCA, middle cerebral artery; mRS, modified Rankin Scale; NIHSS, National Institutes of Health Stroke Scale.

Statistically significant values are in bold.

Table 2 Comparison of outcome measures between the two groups

Variable	N	Extracranial ICA lesion		P value	OR (95% CI)*†	P value*
		Occlusion (135)	Stenosis (170)			
mTICI 2b-3	305	95 (70)	137 (81)	0.03	0.57 (0.32 to 0.99)‡	0.049
mTICI 3	305	37 (27)	68 (40)	0.02	0.56 (0.34 to 0.92)‡	0.023
90-day mRS 0–2	300	67 (51)	87 (52)	0.95	0.91 (0.51 to 1.64)§	0.76
90-day mortality	300	13 (9.6)	19 (11.2)	0.66	0.73 (0.29 to 1.81)§	0.492
Procedural complications	296	21 (16)	19 (11)	0.24	1.41 (0.59 to 2.98)¶	0.35
sICH	305	5 (3)	10 (6)	0.38	1.45 (0.36 to 5.7) **	0.6
PH1-PH2	269	14 (12)	24 (16)	0.32	1.2 (0.47 to 3.12) **	0.7

Values are n (%) or mean (SD) or median.

χ² test was used for categorical variables, Student's t-test was used for parametric variables.

*Calculated after handling missing outcomes and covariates using multiple imputation.

†Stenosis is used as a reference group.

‡Adjusted for age, onset-to-groin time, smoking, IV tPA, admission NIHSS, ASPECTS, location of occlusion.

§Adjusted for age, smoking, hyperlipidemia, diabetes, admission NIHSS, ASPECTS, location of intracranial occlusion, stenting of ICA, onset-to-groin time, and puncture-to-recanalization time.

¶Adjusted for age, smoking, admission NIHSS, ASPECTS, number of antiplatelets used, onset-to-groin time, and puncture-to-recanalization time.

**Adjusted for age, hypertension, NIHSS, IV tPA, ASPECTS, heparin use, onset-to-groin time, number of antiplatelets, and puncture to recanalization time.

mRS, modified Rankin Scale; mTICI, modified Thrombolysis in Cerebral Ischemia; PH, parenchymal hemorrhage; sICH, symptomatic intracerebral hemorrhage.

Statistically significant results are in bold.

as mean ±SD), the Mann–Whitney test for non-Gaussian continuous or ordinal variables (variables expressed as median (IQR)), and the χ² test for categorical variables (variables expressed as N (%)). Missing data were handled with multiple imputations (n=10). Multivariate analysis was performed using mixed logistic regression models which included the center as a random variable. Independent models were performed for successful reperfusion (logistic), complete reperfusion (logistic), 90-day favorable outcome (logistic), 90-day mortality (logistic), and sICH (logistic). In addition to the stenosis versus occlusion variable (stenosis used as reference), variables were included in each model based on univariate analysis with p<0.1. Rubin's rule was applied for pooling of estimates from all imputations and to calculate final adjusted ORs. Statistical analyses were performed using SPSS v. 24

RESULTS

A total of 305 patients with atherosclerotic TO were included in the study, of whom 135 patients had complete EICA occlusions and 170 had EICA high-grade stenosis. Table 1 summarizes the baseline characteristics of the two groups. There was no difference in age, sex, admission NIHSS, ASPECTS (Alberta Stroke Programme Early CT Score), and intracranial occlusion locations. The EICA occlusion group had shorter mean onset-to-groin time (259 ± 120 min vs. 305 ± 202 min; p=0.037). More patients in the EICA occlusion group had diabetes (24% vs 12%; p=0.01) and fewer patients had hyperlipidemia (34% vs 47%; p=0.03). In addition, more patients in the EICA occlusion group had general anesthesia (62% vs 49%; p=0.02). With respect to the procedural variables, intracranial EVT was performed using a stent retriever in most cases with no difference between groups. EICA stenting was performed in 67% and 68% in the occlusion and stenosis groups, respectively (p=0.92). Other treatment options included angioplasty and no treatment (table 1). The order of treatment differed between groups, with 'Head-First' being more common in the occlusion group than in the stenosis group (48% vs 28%; p<0.001).

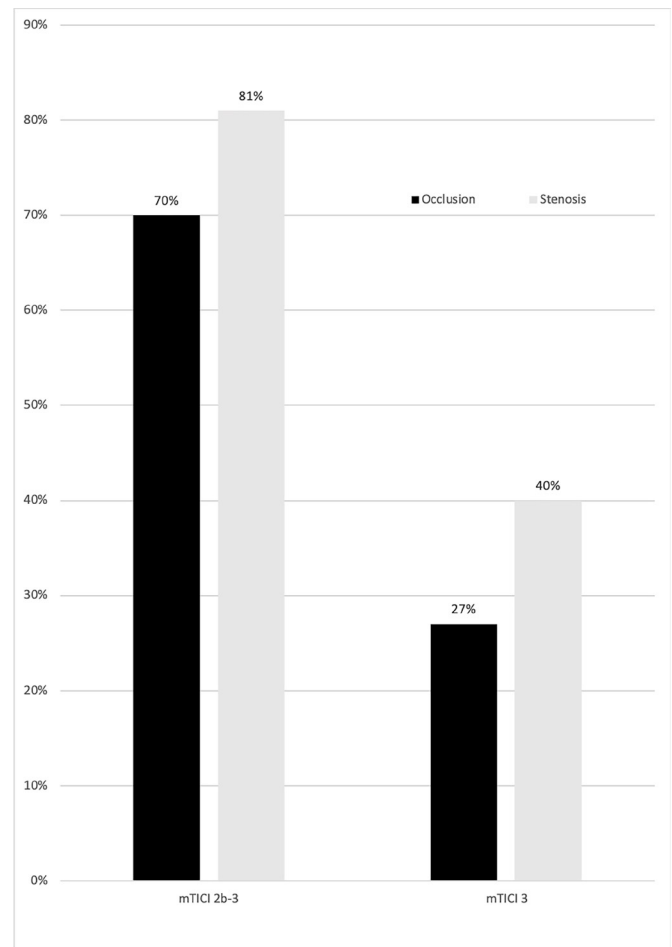


Figure 1 Comparison of successful and complete reperfusion according to the severity of the extracranial internal carotid artery lesion.

The rate of successful reperfusion was lower in the occlusion group (70% vs 81%; $p=0.03$) and the rate of mTICI 3 reperfusion was lower in the EICA occlusion group (27% vs 40%; $p=0.02$). Conversely, unsuccessful reperfusion (mTICI 0–2a) was more common in the occlusion group (30% vs 19%; $p=0.038$). The difference remained significant after adjusting for multiple confounders (mTICI 2b–3, OR=0.57; $p=0.049$; mTICI 3, OR=0.56; $p=0.023$) (table 2 and figure 1). The 90-day favorable outcome was achieved in similar proportions in both groups (51% vs 52%; $p=0.95$). There was no difference in the rate of sICH, parenchymal hemorrhage, and 90-day mortality between the two groups (table 2). With respect to procedure-related complications, emboli to new territories was the most common complication and was numerically higher in the occlusion group than the stenosis group (13% vs 6.6%; $p>0.05$) (see online supplementary table e1)

DISCUSSION

In the present study including 305 patients with acute ischemic stroke due to atherosclerotic TO, we found that EICA occlusion was associated with a lower rate of successful and complete reperfusion at the end of the endovascular procedure. However, we found no differences in the functional outcome or the safety endpoints between the two groups.

EVT of TO is complex and more challenging than non-TO due to involvement of more than one large vessel. Despite its complexity, successful reperfusion can be achieved in 60–80% of cases using modern mechanical devices.^{10–16} Data from the ESCAPE trial demonstrated a comparable rate of successful reperfusion between TO and non-TO large vessel occlusions.¹⁶ Thrombectomy is the standard of care for intracranial occlusions; in contrast, there is no consensus on the best treatment approach for extracranial lesions, with growing evidence supporting stenting for EICA lesions.⁸ A future prospective randomized controlled TITAN trial will evaluate the safety and efficacy of emergent stenting of the EICA lesion in addition to intracranial thrombectomy compared with intracranial thrombectomy alone.

Most of the previous studies did not differentiate between carotid stenosis or occlusion, so the difference in the outcome of EVT between the two groups is poorly understood. Post-hoc analysis of the Interventional Management of Stroke III study (IMS-III) showed that severe carotid stenosis was associated with a longer time to reperfusion but not with the functional outcome or the safety endpoints.¹⁷ We found here that EICA occlusion was associated with a lower rate of angiographic reperfusion compared with EICA stenosis, a finding that is similar to a previous report.¹⁸ The lower reperfusion rate in the occlusion group can be attributed to the difficulty of accessing the intracranial occlusion and the higher thrombus burden at the level of the atherosclerotic plaque. Another explanation could be related to the higher risk of distal intracranial thrombus migration after the first pass of the EICA lesion with endovascular devices in cases of complete occlusion.

EVT remarkably improved the outcome of TO. In a study of 44 patients with TO treated with intravenous thrombolysis, only 8 (18.2%) were independent (mRS 0–2) at 90 days.⁴ In contrast, functional independence was achieved in 40–50% of patients treated endovascularly.^{11–16} In our study, around 50% of our cohort achieved functional independence with no significant differences between the two groups. Reperfusion is an important predictor of functional outcome.^{4, 19} Thus, an argument can be made that a lower successful reperfusion rate should be translated to a worse functional outcome in the occlusion group. In the case of EICA occlusion, anterior circulation flow is mainly dependent on collateral flow; therefore, poor collateral flow

and acute carotid occlusion will likely result in a large volume infarct deeming patients not to be candidates for EVT. As such, we postulate that the carotid occlusion group likely had a robust collateral flow and therefore achieved a similar functional outcome despite lower successful reperfusion rate.

Another potential explanation is the difference in the baseline characteristics between the two groups; however, adjusting for the baseline characteristics did not change our results. Finally, it is possible that our study was underpowered to detect the difference in functional outcome between the two groups. Intracerebral hemorrhage is a potential complication of EVT, especially in cases of TO, giving the need for antiplatelet therapy in the acute phase of stroke. In our cohort the incidence of sICH was ~5%, which is similar to that reported in the HERMES meta-analysis.²⁰ The rate of sICH did not differ between groups.

Despite the remarkable advances in carotid revascularization techniques, the need for adjuvant techniques is not uncommon.²¹ The wire escalation technique was suggested as a possible adjuvant technique in cases of carotid occlusion with no clear entry point or heavily calcified occlusions.²¹ In this technique, navigation using regular guidewires with a microcatheter is first attempted. If unsuccessful, guidewires with stiffer tips are sequentially used to navigate through the occlusion. In the case of large clots, suction thrombectomy using a balloon guide catheter (BCG) and/or a large-bore shuttle sheath can be performed before stent retriever thrombectomy.²² In addition, BCG use in TO could reduce intracranial thrombus migration during EVT.²²

Study limitations

Our study has multiple shortcomings derived mainly from its retrospective non-randomized design. The degree of stenosis was reported by the local operators with no core laboratory assessment. Similarly, the final reperfusion score (mTICI) was reported by local operators, which raises concerns of overestimation. Finally, the EICA treatment strategies differed between centers which may have affected the reperfusion rate; notably, there was no difference in the rate of carotid stenting between the two groups.

CONCLUSION

EICA occlusion was associated with lower rates of successful reperfusion and complete reperfusion at the end of the EVT procedure when compared with EICA stenosis. However, EICA status (stenosis vs occlusion) was not associated with the 90-day functional outcome or the safety endpoints.

Author affiliations

¹Neurology and Neurosurgery, Medical University of South Carolina, Charleston, South Carolina, USA

²Neurosurgery, Medical University of South Carolina, Charleston, SC, USA

³Neurosciences, Medical University of South Carolina, Charleston, South Carolina, USA

⁴Department of Interventional Neuroradiology, Centre Hospitalier Universitaire de Lyon, Lyon, France

⁵Department of Interventional Neuroradiology, Fondation Rothschild Hospital, Paris, France

⁶Neurology, Rigshospitalet, Copenhagen, Denmark

⁷Kobenhavns Universitet Biologisk Institut, Kobenhavn, Denmark

⁸Neuroradiology, Albert-Ludwigs-Universität Freiburg, Freiburg im Breisgau, Germany

⁹Neurology, Emory University School of Medicine, Atlanta, Georgia, USA

¹⁰Department of Diagnostic and Interventional Neuroradiology, Hospital Bremen-Mitte, Bremen-Ost, Bremen, Germany

¹¹Departments of Neurosurgery and Radiology and Toshiba Stroke Research Center, University at Buffalo, State University of New York, Buffalo, New York, USA

¹²Department of Neurology, Stroke Center, Foch Hospital, Suresnes, France

¹³Department of Neuroradiology, LMU University Hospital of Munich, Munich, Germany

- ¹⁴Diagnostic and Therapeutic Neuroradiology, Hôpital Purpan, Toulouse, France
¹⁵Neurology/Research Institute of Neurointervention, Paracelsus Medical University, Salzburg, Austria
¹⁶Neuroradiologia Interventistica, Azienda Ospedaliero-Universitaria Careggi Firenze, Florence, Italy
¹⁷Stroke Unit, Neurology, Hospital Vall d'Hebron, Barcelona, Spain
¹⁸Universitat Autònoma de Barcelona
¹⁹Neuroradiology, University Medicine Goettingen, Goettingen, Germany
²⁰Departement of interventional neuroradiology, Hopita Lariboisiere, Paris, France
²¹Neuroradiology and Endovascular Therapy, Besançon University Hospital, Besançon, France
²²Department of Diagnostic and Interventional Neuroradiology, CHRU Nancy, Nancy, France
²³Université de Lorraine, Faculté de Médecine, Vandœuvre-lès-Nancy, France

Collaborators Jonathan Andrew Grossberg, Adrien Guenego, Julien Darcourt, Isabelle Vukasinovic, Anne-Christine Januel, Philippe Tall, Elisa Pomerio, Jason Davies, Leonardo Renieri, Corentin Hecker, Maria Muchada Muchada, Arturo Consoli, Georges Rodesch, Emmanuel Houdart, Raymond Turner, Aquilla Turk, Imran Chaudry, Johanna Lockau, Andreas Kastrup, Raphaël Blanc, Hocine Redjem, Daniel Behme, Hussain Shallwani, Maurer Christopher, Gioia Mione, Lisa Humbertjean, Jean-Christophe Lacour, François Zhu, Anne-Laure Derelle, Romain Tonnelet, Liang Liao.

Contributors All authors have provided a substantial contribution to the conception and design of the studies and/or the acquisition and/or the analysis of the data and/or the interpretation of the data. They have drafted the work or revised it for significant intellectual content and approved the final version of the manuscript. They agree to be accountable for all aspects of the work, including its accuracy and integrity.

Funding Funding for this study was provided by Stryker.

Competing interests MH has received honoraria for consultancy and proctoring for Medtronic, Stryker, and Microvention. RN has received honoraria from Stryker Neurovascular for TREVO 2 trial (Thrombectomy Revascularisation of Large Vessel Occlusions in Acute Ischemic Stroke) and DAWN Trial (Trevor and Medical Management Versus Medical Management Alone in Wake Up and Late Presenting Strokes), from Medtronic for SWIFT (Solitaire FR With the Intention for Thrombectomy) and SWIFT PRIME Trials (Solitaire FR With the Intention for Thrombectomy as Primary Endovascular Treatment for Acute Ischemic Stroke) Steering Committee, and STAR Trial core laboratory (significant), from Penumbra for 3D Separator Trial Executive Committee, and from Neuravi for ARISE-2 (Analysis of Revascularization in Ischemic Stroke With EmboTrap) Steering Committee; AHS reports grants from National Institutes of Health/NINDS/NIBIB, University at Buffalo, personal fees from Hotspur, Intratech Medical, StimSox, Valor Medical, Blockade Medical, and Lazarus Effect, non-financial support from Codman & Shurtleff, Concentric Medical, ev3/Covidien Vascular Therapies, GuidePoint Global Consulting, Penumbra, Stryker, Pulsar Vascular, MicroVention, Lazarus Effect, Blockade Medical, other from null, outside the submitted work. AS has stock from Penumbra and received honoraria for consultancy and proctoring for Penumbra, and Stryker. FT has received honoraria for consultancy and proctoring for Medtronic, Stryker Codman, and Balt.

Patient consent for publication Not required.

Provenance and peer review Not commissioned; externally peer reviewed.

Data sharing statement Additional data from this project can be acquired by contacting the corresponding author.

REFERENCES

- Rahme R, Abruzzo TA, Ringer AJ. Acute ischemic stroke in the setting of cervical carotid occlusion: a proposed management strategy. *World Neurosurg* 2011;76(6 Suppl):S60–5.
- Tallarita T, Lanzino G, Rabinstein AA. Carotid intervention in acute stroke. *Perspect Vasc Surg Endovasc Ther* 2010;22:49–57.
- Lescher S, Czeppan K, Porto L, et al. Acute stroke and obstruction of the extracranial carotid artery combined with intracranial tandem occlusion: results of interventional revascularization. *Cardiovasc Intervent Radiol* 2015;38:304–13.
- Rubiera M, Ribo M, Delgado-Mederos R, et al. Tandem internal carotid artery/middle cerebral artery occlusion: an independent predictor of poor outcome after systemic thrombolysis. *Stroke* 2006;37:2301–5.
- Meyer FB, Sundt TM, Piepgras DG, et al. Emergency carotid endarterectomy for patients with acute carotid occlusion and profound neurological deficits. *Ann Surg* 1986;203:82–9.
- Gory B, Haussen DC, Piotin M, et al. Impact of intravenous thrombolysis and emergent carotid stenting on reperfusion and clinical outcomes in patients with acute stroke with tandem lesion treated with thrombectomy: a collaborative pooled analysis. *Eur J Neurol* 2018;25:1115–20.
- Gory B, Piotin M, Haussen DC, et al. TITAN Investigators. Thrombectomy in acute stroke with tandem occlusions from dissection versus atherosclerotic cause. *Stroke* 2017;48:3145–8.
- Papanagiotou P, Haussen DC, Turjman F, et al. Carotid stenting with antithrombotic agents and intracranial thrombectomy leads to the highest recanalization rate in patients with acute stroke with tandem lesions. *JACC Cardiovasc Interv* 2018;11:1290–9.
- Hacke W, Kaste M, Bluhmki E, et al. Thrombolysis with alteplase 3 to 4.5 hours after acute ischemic stroke. *N Engl J Med* 2008;359:1317–29.
- Behme D, Mpotsaris A, Zeyen P, et al. Emergency stenting of the extracranial internal carotid artery in combination with anterior circulation thrombectomy in acute ischemic stroke: a retrospective multicenter study. *AJNR Am J Neuroradiol* 2015;36:2340–5.
- Wilson MP, Murad MH, Krings T, et al. Management of tandem occlusions in acute ischemic stroke: intracranial versus extracranial first and extracranial stenting versus angioplasty alone: a systematic review and meta-analysis. *J Neurointerv Surg* 2018;10:721–8.
- Spiotta AM, Lena J, Vargas J, et al. Proximal to distal approach in the treatment of tandem occlusions causing an acute stroke. *J Neurointerv Surg* 2015;7:164–9.
- Cohen JE, Gomori JM, Rajz G, et al. Extracranial carotid artery stenting followed by intracranial stent-based thrombectomy for acute tandem occlusive disease. *J Neurointerv Surg* 2015;7:412–7.
- Malik AM, Vora NA, Lin R, et al. Endovascular treatment of tandem extracranial/intracranial anterior circulation occlusions: preliminary single-center experience. *Stroke* 2011;42:1653–7.
- Stampf S, Ringleb PA, Möhlenbruch M, et al. Emergency cervical internal carotid artery stenting in combination with intracranial thrombectomy in acute stroke. *AJNR Am J Neuroradiol* 2014;35:741–6.
- Assis Z, Menon BK, Goyal M, et al. Acute ischemic stroke with tandem lesions: technical endovascular management and clinical outcomes from the ESCAPE trial. *J Neurointerv Surg* 2018;10:429–33.
- Gogela SL, Gozal YM, Zhang B, et al. Severe carotid stenosis and delay of reperfusion in endovascular stroke treatment: an Interventional Management of Stroke-III study. *J Neurosurg* 2018;128:94–9.
- Park SE, Choi DS, Baek HJ, et al. Endovascular therapy of acute ischemic stroke related to tandem occlusion: comparison of occlusion and severe stenosis of the proximal cervical internal carotid artery. *Br J Radiol* 2018;91:20180051.
- Dargazanli C, Consoli A, Barral M, et al. Impact of modified TIC1 3 versus modified TIC1 2b reperfusion score to predict good outcome following endovascular therapy. *AJNR Am J Neuroradiol* 2017;38:90–6.
- Goyal M, Menon BK, van Zwam WH, et al. Endovascular thrombectomy after large-vessel ischaemic stroke: a meta-analysis of individual patient data from five randomised trials. *Lancet* 2016;387:1723–31.
- Cohen JE, Leker RR, Gomori JM, et al. Wire escalation in emergent revascularization procedures of internal carotid artery occlusions: the use of high tip stiffness microguidewires. *J Neurointerv Surg* 2017;9:547–52.
- Kim BM. Causes and solutions of endovascular treatment failure. *J Stroke* 2017;19:131–42.