

## RESEARCH ARTICLE

# Integrating histology in the analysis of multispecies cremations: A case study from early medieval England

Katherine McCullough French<sup>1,2</sup>  | Christian Crowder<sup>3</sup> | Pam Jean Crabtree<sup>1</sup>

<sup>1</sup>Center for the Study of Human Origins, New York University, New York, New York, USA

<sup>2</sup>School of History, Archaeology and Religion, Cardiff University, Cardiff, UK

<sup>3</sup>Tarrant County Medical Examiner's Office, Fort Worth, Texas, USA

**Correspondence**

Katherine McCullough French, School of History, Archaeology and Religion, Cardiff University, John Percival Building, Colum Drive, Cardiff, CF10 3EU, UK.  
Email: frenchk@cardiff.ac.uk

**Present address**

Katherine McCullough French, School of History, Archaeology and Religion, Cardiff University, Cardiff, UK.

**Abstract**

Methodological options for differentiating commingled human from nonhuman calcined remains are limited. A zooarchaeological analysis of human cremations from three early medieval sites in the Avon Valley (Warwickshire, England) identified commingled animal remains in burials from the site of Bidford-on-Avon, but not at the contemporary sites of Wasperton and Alveston Manor. A histological study was conducted to further investigate whether additional fragments of nonhuman bone could be identified and to quantify potential differences in preservation or cremation intensity between the sites. Bone fragments ( $n = 92$ ) were selected from 44 cremation burials across the three sites for thin section preparation. Histological cross sections were observed to record the presence of fibrolamellar plexiform bone and secondary osteon banding, as well as to categorize the histological preservation and cremation intensity. The analysis did not identify any nonhuman remains from Wasperton or Alveston Manor, but nonhuman bone fragments were identified in the Bidford-on-Avon histology sample. These data supplement and support the findings of the macroscopic analysis that multispecies commingled cremations were only prevalent at Bidford-on-Avon. No statistically significant differences were identified in histological preservation or cremation intensity between the cemeteries. Variability in animal use in funerary rites between cemetery sites, rather than preservation bias, is therefore the likely explanation for the differential recovery of commingled nonhuman bone from excavated cremation burials. These results confirm that histomorphology is a useful tool to incorporate in the analysis of multispecies commingled cremations.

**KEYWORDS**

bone histology, cremations, histomorphology, medieval archaeology, mortuary archaeology

## 1 | INTRODUCTION

Commingled multispecies cremations present complex methodological challenges. Under ideal conditions, osteologists classify bone

fragments to species based solely upon gross morphology. Cremated bone is challenging given the high rates of fragmentation, cracking, and deformation (Shipman et al., 1984). Taxonomic identification is therefore not always possible when dealing with thermally-altered

This research was funded through a Lane Cooper Fellowship from the New York University Graduate School of Arts and Sciences and a New York University Provost's Global Initiatives Grant.

This is an open access article under the terms of the [Creative Commons Attribution-NonCommercial](https://creativecommons.org/licenses/by-nc/4.0/) License, which permits use, distribution and reproduction in any medium, provided the original work is properly cited and is not used for commercial purposes.

© 2022 The Authors. *International Journal of Osteoarchaeology* published by John Wiley & Sons Ltd.

bone, and species differentiation must be considered through other means. At a minimum, efforts should be made to distinguish human from nonhuman bone to comply with relevant legal and ethical frameworks.<sup>1</sup>

Methodological options are limited for differentiating human from nonhuman cremated bone. Proteomic and aDNA methods cannot be utilized due to the destruction of bone's organic fraction during the burning process (Cattaneo et al., 1999; Harbeck et al., 2011; Imaizumi et al., 2014; Mckinnon et al., 2021; Naihui et al., 2021). Therefore, histological methods developed for undecalcified bone should be considered to evaluate bone fragments. This can include histomorphometry or histomorphology.

Histomorphometric techniques use measurements of microstructural features, such as osteon circularity or osteon area, to differentiate human from nonhuman bone (Cattaneo et al., 1999; Dominguez & Crowder, 2012; Jowsey, 1966; Martiniaková et al., 2007; Urbanová & Novotny, 2005). Although these techniques have previously been attempted in archaeological contexts (Gigante et al., 2021; Sázelová et al., 2021), they were developed on samples of known anatomical position and have not been validated on fragmentary bone of unknown anatomical location. Variation in osteon size and geometry has been documented across elements and even within histological sections; therefore, controlling for anatomical location is essential (Cummaudo et al., 2018; Nganvongpanit et al., 2017). Additionally, histomorphometric techniques have not been validated for bone subjected to unknown cremation intensity (e.g., Cattaneo et al., 1999), which affects osteon size and circularity (Hanson & Cain, 2007). While some studies attempt to account for shrinkage (e.g., Sawada et al., 2014), this correction is insufficient without a priori knowledge of cremation intensity. Current histomorphometric methods are therefore not appropriate for discriminating human from nonhuman bone in archaeological cremation assemblages (Lagacé et al., 2020).

Histomorphological techniques use qualitative observations of bone microstructure and have been employed successfully in both forensic and archaeological contexts to differentiate human from nonhuman skeletal remains (Cuijpers, 2006, 2009; Dixon et al., 2011; Gigante et al., 2021; Hanson & Cain, 2007; Owsley et al., 1985; Sawada et al., 2014; Sázelová et al., 2021). Species differentiation by histomorphology is based on long-held observations that bone modeling rate determines primary bone organization (Amprino, 1947; de Margerie et al., 2002, 2004). Humans have a relatively long juvenile period and a slower rate of bone growth than nonhumans<sup>2</sup> (Bogin, 2020; Kuzawa et al., 2014; Zoetis et al., 2003). Therefore, the primary bone of humans and nonhuman animals differs in appearance microscopically. There are no bone types that are unique to humans, so histomorphological analysis cannot definitively identify human bone (Defense POW/MIA Accounting Agency, 2015); however, bone organization can be used to identify nonhuman bone. Fibrolamellar plexiform primary bone and osteon banding (Mulhern & Ubelaker, 2001) are the two most common diagnostic characteristics of bone organization for identifying nonhuman bone.

Primary fibrolamellar plexiform bone has a mixed matrix structure composed of a woven (fibrous) bone frame that is laid down quickly around primary blood vessels. Large voids in the bone matrix are slowly filled with lamellar bone to enclose vessel canals (Currey, 2002, p. 18). The vascular plexus is an interconnected, web-like network of blood vessels that extends three-dimensionally, with primary osteons oriented circumferentially, longitudinally, reticularly, and radially (de Ricqlès et al., 1991). Reports of plexiform bone in subadult humans complicate the simplistic identification of plexiform bone as definitively nonhuman (e.g., Hillier & Bell, 2007; Pfeiffer, 2006). A small study of subadult femur and skull fragments positively identified primary fibrolamellar plexiform bone in three out of eight individuals under the age of one and none from other age groups ( $n = 23$ ) (Caccia et al., 2016). Additional research incorporating larger samples with greater anatomical diversity is required to confirm, but evidence to date suggests that plexiform is rare in individuals older than 1 year. The possibility of plexiform bone in fetal or infant humans is important to consider when sampling.

Osteon banding is a common characteristic used to discriminate nonhuman bone and is defined as a row of five to six secondary osteons lining up in a field of otherwise lamellar bone (Mulhern & Ubelaker, 2001). Limited osteonal banding can be present in human bone (Andronowski et al., 2017), but multiple, long bands of osteons that are part of overall linearly organized histological field are characteristic of nonhuman bone, particularly when observed in conjunction with primary fibrolamellar tissue.

One potential application of histomorphology is in the analysis of commingled cremations where multiple species may be present, as in early medieval (fifth to seventh century CE) cemeteries in England. Research on early medieval multispecies cremations has traditionally been limited to what Hills and Lucy (2013) have termed the “Core Cremation Zone” of eastern England where the cremation rite predominates and cemeteries include several hundred to thousands of cremation burials (Bond, 1996; Bond & Worley, 2006; Squires et al., 2011; Rainsford, 2021). In contrast, mentions of multispecies cremation burials are extremely rare further inland where mixed-rite or inhumation cemeteries predominate (e.g., Dickinson & Speake, 1992), although it is unclear whether this discrepancy is a function of differential research efforts or this rite was in fact not practiced at inland cemeteries.

Three inland mixed-rite cemetery sites were chosen for zooarchaeological analysis to investigate whether animal bone was present within archived cremation burials. Sites were selected for availability of material, geographical and chronological proximity, and no record of previous zooarchaeological analysis. The macroscopic analysis produced disparate results: Animal bone was macroscopically identified in six of 25 burials (24%) from Bidford-on-Avon (Bidford), zero out of 21 burials from Alveston Manor (Alveston), and a single unburnt fragment from one of 28 burials (3.5%) at Wasperton. The macroscopic analysis identified other fragments suspected to be nonhuman, but which could not be confirmed morphologically. A histological analysis was therefore conducted to (1) confirm suspected nonhuman bone fragments and (2) determine whether differences in histological

preservation or cremation intensity between the sites could account for the differences in animal bone identification.

## 2 | MATERIALS

### 2.1 | Background

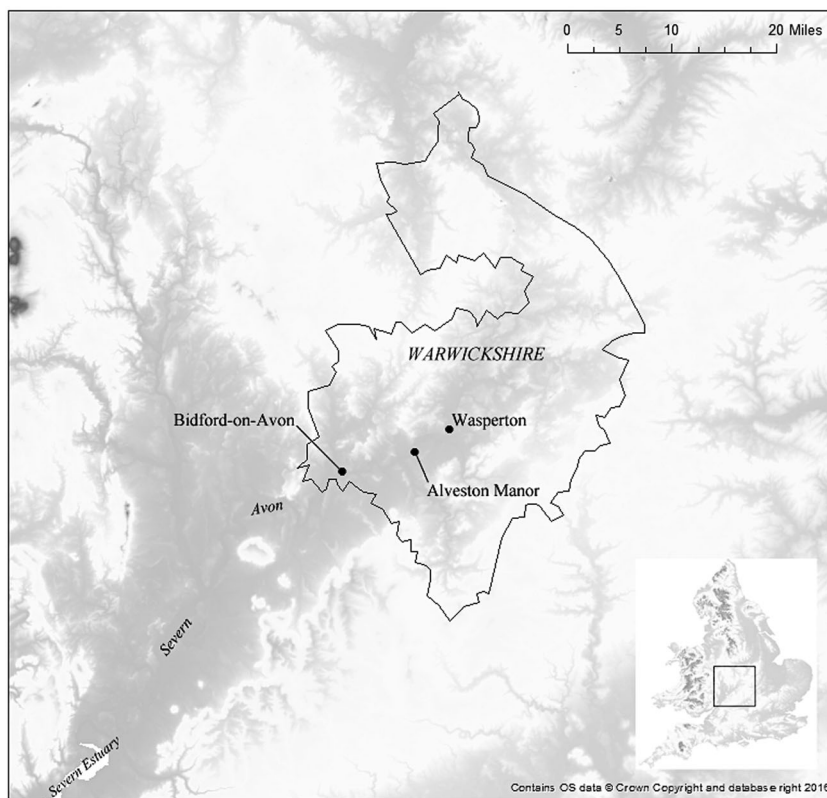
Alveston, Bidford, and Wasperton are early medieval inhumation and cremation mixed-rite cemeteries lying within a 12-mile radius in the Avon River Valley, Warwickshire (Figure 1). Alveston and Bidford were excavated in the 1920s (Dickinson, 2021; Humphreys et al., 1923, 1925), while the Wasperton burials were excavated using modern methods in the 1990s (Carver et al., 2009). Initial osteological investigations did not identify animal remains in cremation burials (Wellstood, n.d.; Carver et al., 2009; Dickinson, 2021; Humphreys et al., 1923, 1925), although animal remains were reported in non-burial contexts. For example, 21 hearths with animal remains were dispersed throughout the Alveston cemetery and interpreted as evidence of graveside funerary feasting (Wellstood, n.d., p. 8).

Systematic analysis of available cremation burials from these sites identified commingled, burned animal remains in Bidford in six burials (24%) from at least four taxa: horse, ovicaprid, chicken, and goose (Figure 2a–d, Table 1). Burial number 2 had at least three species present. Results contrasted with Alveston (zero nonhuman fragments) and Wasperton (one unburnt fragment). Obvious and overt


differences in excavation protocols (e.g., sieving) or post-excavation analytical techniques cannot account for the discrepancy, as Wasperton was the only site excavated using modern methods (Carver et al., 2009). Less obvious preservation biases may also exist between cemetery assemblages, such as differences in burial environment or intensity of cremation. Given the similarities between the sites in terms of chronology, location, mixed-rite burial practices, and cultural affinity, the difference in animal bone recovery deserved further consideration (Stodder, 2018).

### 2.2 | Histology sample selection

A total of 92 bone fragments (Bidford:  $n = 36$ , Alveston:  $n = 23$ , Wasperton:  $n = 33$ ) from 44 burials were sampled for histological analysis (Table S1). Per agreement with the archives, fewer than four bone fragments could be sampled from a single burial for destructive analysis. Each was a morphologically unidentifiable long bone fragment and at least 1 cm long. All fragments identified as possible nonhuman during the macroscopic zooarchaeological analysis were sampled. Tentative identifications were based on cortical thickness relative to the human bone fragments from the same burial. Thicker cortical bone is suggestive but not diagnostic of non-human bone (Crocker et al., 2016; Nor et al., 2015), as cortical thickness varies with anatomical location and individual robustness (Skedros et al., 1994). Relatively thicker cortical bone was also chosen to exclude possible fetal or infant human bone. Additional



**FIGURE 1** Location of cemetery sites in the Avon River valley, Warwickshire, England



**FIGURE 2** Examples of nonhuman bone identified from Bidford-on-Avon. (a) Inferior view of a horse proximal phalanx from burial 2. (b) Inferior view of calcined horse distal tibia from burial 2. (c) Two views of ovicaprid molar fragment from burial 25. (d) Anterior (left) and cranial (right) views of a charred ovicaprid proximal metacarpal from burial 39.

**TABLE 1** Overview of animal remains recorded from Bidford cremation burials

Burial number	Species	Skeletal elements
2	Chicken	Humerus, ulna, carpometacarpus
	Goose	Tibiotarsus
	Horse	Tibia, proximal phalanx
	Unspecified unknown size bird	Tibiotarsus, tarsometatarsus, radius, long bone shaft fragment
	Unspecified large mammal	Radius, long bone fragments
	Unspecified unknown size mammal	Teeth fragments
16	Unspecified unknown size mammal	Skull fragment
25	Ovicaprid	Molar
39	Ovicaprid	Metacarpal
55	Unspecified large mammal	Long bone fragment
144	Ovicaprid	Proximal phalanx

unidentifiable, but probable human, fragments were sampled as controls ( $n = 86$ ), with an approximately equal amount of control samples taken from each site. Specimens were assigned a random sample number (e.g., KF.01) so that prior knowledge would not influence the analyst.

### 3 | METHODS

#### 3.1 | Thin section preparation

Slide preparation followed protocols established for fresh bone (Crowder et al., 2012) and revised as required to process calcined bone, such as omitting sample dehydration. Bone samples were embedded in Buehler Epothin epoxy resin. A Buehler IsoMet 1000 saw was used to create a transverse waste cut. Cut blocks were polished and mounted to a slide using 3M Scotch Weld CA7

adhesive. An Exact 300 diamond band saw was used to cut a thick section approximately 100–300  $\mu\text{m}$  thick. A Buehler MetaServ250 wheel was used to grind then polish the sample using P800 and P1200 grit paper. Slides reached the desired thickness when individual histological structures were clearly defined, 70–100  $\mu\text{m}$  thick. Detailed methodology is available in Methods S1.

#### 3.2 | Nonhuman identification

Each sample was recorded as probable human (H) or nonhuman (NH) during the zooarchaeological analysis. Cortical bone was measured at the thickest location with sliding calipers. The entire available cross-sectional area was observed under bright field, plane-polarized light, and cross-polarized light conditions. Histological samples were assumed human unless extensive fibrolamellar plexiform bone or multiple instances of secondary osteon banding was observed. Secondary

osteon bands were recorded because the mineralized reversal line remains clearly defined in cremated samples whereas primary osteon banding can be more difficult to identify due to opaque carbon deposition.

### 3.3 | Preservation and cremation intensity

Taphonomic data were collected to determine whether differences in nonhuman bone identification correlated with differences in histological preservation or cremation intensity (Table 2). Bright field provided optimal contrast to observe burnt bone, but birefringence is assessed under polarized light. Birefringence loss is a function of collagen combustion and correlates with cremation intensity (Harbeck et al., 2011). Histological preservation was recorded using the Oxford Histological Index (OHI), which is the standard method in histotaphonomy to quantify destruction of histological structures in archaeological bone (Hedges et al., 1995). Developed to characterize bone diagenesis, the method has been used to quantify burning impacts on histological structures (e.g., Cuijpers, 2009). Cremation effects are not uniform throughout a bone cross section (Cambrá-Moo et al., 2018) so OHI values were recorded for the endosteal, midcortical, and periosteal zones using an overlay grid to divide the section into thirds of overall cortical surface area and averaged. Cremation intensity was recorded using Squires et al.'s method, which provides an illustrated catalogue of burning stages developed for recording early medieval cremations (Squires et al., 2011, p. 2401).

## 4 | RESULTS

### 4.1 | Nonhuman bone identification

None of the samples from Alveston or Wasperton were assessed as nonhuman (Table S2). Eight specimens from five Bidford burials were confirmed to be nonhuman (Table 3). Nonhuman remains were confirmed from two burials (97 and 145) in which no animal bone had been identified in the macroscopic zooarchaeological analysis. Six samples were identified as nonhuman because of the predominance of fibrolamellar bone tissue in the cross section (Figure 3). Two remaining samples had multiple observable secondary osteon bands. All other samples were assessed as human because the histological appearance was consistent with adult human tissue—primary lamellar bone with dense, nonlinearly organized secondary osteons. The complete dataset is available in Data S1–S3.

Mean cortical bone thickness was higher for the nonhuman sample from Bidford ( $\bar{x} = 6.073$  mm,  $SD = 2.692$ ), but with significant overlap with the human sample ( $\bar{x} = 4.24$  mm,  $SD = 1.291$ ) (Figure 4, Table S2). Single outliers in both groups (KF.13 and KF.47) had cortical thickness measurements nearly twice the respective median values, disproportionately increasing the means for both groups but with a greater effect on the nonhuman sample due to the smaller sample size ( $n = 8$ ) compared with the human sample ( $n = 83$ ). Results support the conclusion of Croker et al. (2016) that cortical bone thickness, when anatomical location is unknown, is not an independently discriminating factor between human and nonhuman bone.

**TABLE 2** Description of the data collected


	Type of data recorded	Description
Nonhuman identification		
Cortical bone thickness	In millimeters (mm)	Thicker cortical bone is generally associated with nonhuman mammals
Fibrolamellar plexiform bone (Cuijpers, 2009; de Ricqlès et al., 1991)	Presence/absence	If histologically observed, diagnostic of nonhuman <sup>a</sup> sample
Secondary haversian bone – osteon banding (Mulhern & Ubelaker, 2001)	Presence/absence	If multiple instances histologically observed, diagnostic of nonhuman sample
Preservation bias and cremation intensity		
Cremation stage (Squires et al., 2011, Table 2)	2 = less intensely cremated 1 = intensely cremated 0 = completely cremated	Measure of thermal alteration based on histological observations
OHI value (Hedges et al., 1995, Table 1)	5 = <95% intact bone 4 = <85% intact bone 3 = <67% intact bone 2 = <33% intact bone 1 = <15% intact bone 0 = <5% intact bone	Measure of preservation of histological (microscopic) structures

<sup>a</sup>Fetal and infant human bone may also have fibrolamellar plexiform bone.

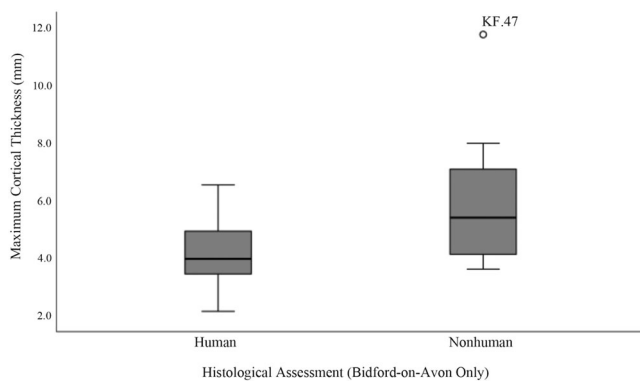**TABLE 3** Histology samples identified as nonhuman

Sample	Bidford burial	Preliminary assessment	Primary fibrolamellar plexiform	Secondary osteon banding	Final determination (H/NH)
KF.47	2	NH	N/A	Y	NH
KF.54	55	NH	Y	Y	NH
KF.55	97	H	Y	N	NH
KF.62	55	H	Y	Y	NH
KF.65	55	NH	Y	N	NH
KF.67	145	H	Y	Y	NH
KF.76	2	NH	N/A	Y	NH
KF.90	39	H	Y	Y	NH

Note: N/A indicates that poor histological preservation or carbon deposition obscured the sample so that this characteristic could not be assessed.



**FIGURE 3** Histological cross-sections illustrating (a) fibrolamellar plexiform bone. Bright field,  $\times 4$  objective lens. Source: Bidford-on-Avon, Sample KF.54, Burial 55. (b) Secondary osteon band (white arrows). Bright field,  $\times 10$  objective lens. Source: Bidford-on-Avon, Sample KF.76, Burial 2. (c) Dense secondary osteons with carbon deposition. Bright field,  $\times 10$  objective lens. Source: Wasperton, Sample KF.09, Burial 1a [Colour figure can be viewed at [wileyonlinelibrary.com](https://onlinelibrary.wiley.com)]

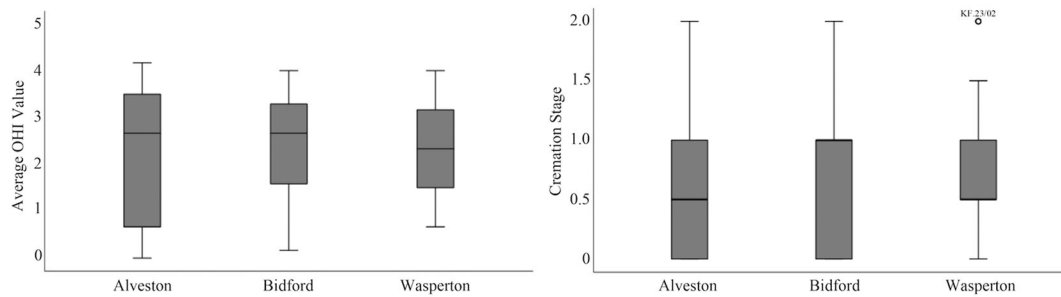


**FIGURE 4** Box-plot showing distribution of cortical bone thickness in samples histologically assessed as human and nonhuman at Bidford-on-Avon

## 4.2 | Preservation bias and cremation intensity

All samples exhibited histological characteristics of extensive burning, including color change, carbon deposition, microcracking, and partial or complete loss of birefringence. Cross-section color ranged from whitish-beige to reddish-ochre to dark black from carbon deposition. Microcracks concentrate along open space, such as between vascular canals or along secondary osteon reversal lines (also noted by Bhat et al., 2021; Lemmers et al., 2020).

OHI and cremation intensity results did not show significant differences between cemeteries (Figure 5). Mean OHI values for Alveston ( $\bar{x} = 2.2$ ,  $SD = 1.51$ ), Bidford ( $\bar{x} = 2.4$ ,  $SD = 1.12$ ), and Wasperton ( $\bar{x} = 2.3$ ,  $SD = 0.96$ ) are virtually identical. ANOVA results demonstrate that the between-group variance is not statistically significant,  $F(2, 89) = 0.249$ ,  $p = 0.78$ . All cremations averaged in



**FIGURE 5** Distribution of average OHI values (Hedges et al., 1995) and cremation stages (Squires et al., 2011) at each cemetery site


the Squires et al. (2011) “Intensely Cremated” stage (see Table 2): Alveston ( $\bar{x} = 0.6$ ,  $SD = 0.66$ ), Bidford ( $\bar{x} = 0.7$ ,  $SD = 0.64$ ), and Wasperton ( $\bar{x} = 0.7$ ,  $SD = 0.59$ ). This suggests that the fragments were calcined, although residual carbon deposition was noted in many fragments. ANOVA results show the between-group variance is not significant,  $F(2, 89) = 0.487$ ,  $p = 0.67$ , and there is no statistically significant difference in cremation intensity between cemeteries.

## 5 | DISCUSSION

Results confirmed and expanded upon the macroscopic zooarchaeological assessment. Histological analysis did not identify nonhuman fragments from Wasperton or Alveston, but nonhuman fragments were confirmed from Bidford, including burials the zooarchaeological assessment had not previously identified as multispecies. This increased the percentage of total cremation burials at Bidford that are multispecies from 24% to 32% (8 out of 25 burials), which is comparable to cemeteries in the Core Cremation Zone such as Loveden Hill, Spong Hill, and Sancton I (Bond, 1996; Hills & Lucy, 2013; McKinley & Bond, 1993).

Taphonomic analysis results indicate that there is no statistically significant difference in preservation between the cemeteries. Therefore, the difference in nonhuman bone identification from Bidford cannot be attributed to differences in bone preservation as measured by the OHI or cremation intensity. Results support the finding that early medieval funerary rites were variable even within very close distances (McKinley, 1994; Squires, 2016). Variability in early medieval funerary rites were traditionally attributed to ethnic differences, with “Anglian” groups cremating their dead and incorporating animals into the practice (Meaney, 1964). Subsequent research has revealed complex and heterogeneous cremation practices throughout the landscape and proved that earlier models based on ethnicity were overly simplistic (Mason & Williamson, 2017; Williams, 2010). In fact, this heterogeneity of practice may be a defining characteristic of early medieval paganism (Carver, 2010), a conclusion supported by our data from the Avon Valley.

Histological analysis provided meaningful data to broaden our understanding of the frequency of multispecies cremations outside of the Core Cremation Zone. However, it is not without limitations. Namely, histological techniques cannot positively identify human



**FIGURE 6** Example of charred bone micrograph with substantial carbon deposition obscuring the histological structures (average OHI value = 0.8). Bright field,  $\times 4$  objective lens. Source: Wasperton, Sample KF.24, Burial 9 [Colour figure can be viewed at [wileyonlinelibrary.com](http://wileyonlinelibrary.com)]

bone considering that the density and organization of secondary osteons is age- and mechanical load-dependent (Crowder & Stout, 2012; Gocha & Agnew, 2016) rather than species dependent. Logistically, the chief drawbacks are the time it takes to create thin sections and the high failure rate when working with friable calcined bone, although both issues are alleviated by well-honed laboratory protocols (French et al., 2022). Thin section production is destructive, which archaeologists have an ethical obligation to minimize, particularly when working with human remains (Advisory Panel on the Archaeology of Burials in England [APABE], 2013). However, sampling bone fragments with inconclusive identifications for histology would allow for higher confidence in human/nonhuman determinations.

Bone charring, or incomplete combustion of the organic fraction, is a confounding factor in the microscopic analysis of burned bone because deposited carbonate obscures histological structures (Figure 6). Isotopic studies show that deposited carbon is derived from both endogenous and exogenous sources, such as pyre fuel (Zazzo et al., 2012). Charred bone has been subjected to lower cremation intensities than calcined bone, but in practice charred bone tends to have lower OHI values because deposited carbon obscures

histological structures and a smaller percentage appears intact. Levels of exogenous carbon uptake in charred and calcined bone is highly variable and may not directly correlate with cremation intensity (Snoeck et al., 2014). In calcined samples where collagen is completely combusted but prior to melting of the hydroxyapatite, the mineralized scaffolding of the histological structures is maintained without extensive, opaque carbon deposition. In practice, this means a completely calcined bone could have an OHI value of 5 and a merely charred bone could have an OHI value approaching 0, which is the inverse of the actual cremation intensities. For this reason, OHI is a poor proxy for intensity of cremation and should be narrowly applied to quantifying other histotaphonomic impacts such as bioerosion or diagenesis (e.g., Booth & Madgwick, 2016; Lemmers et al., 2020).

## 6 | CONCLUSION

This case study illustrates how histological approaches to commingled assemblages help produce more precise skeletal inventories and detailed investigations of taphonomic impacts. Results demonstrated that nonhuman cortical bone was indeed overall thicker than human, but there was substantial overlap with the human distribution (Figure 4). This confirms cortical thickness is not a reliable discriminating factor to categorize human from nonhuman bone. In contrast, histological analysis successfully discriminated fragmentary nonhuman bone that would have otherwise been assumed human based on the burial context. Histomorphological analysis confirmed the results of the macroscopic analysis. Nonhuman remains were only identified from Bidford, but two additional multispecies cremations were confirmed, increasing the percentage of this burial type from 25% to 32% (8 of 25 burials). A future interobserver study using histomorphological methods for the analysis of commingled, thermally-altered deposits is warranted to assess its reproducibility.

Bone fragments are generally calcined with no statistically significant difference in cremation intensity observed between cemeteries. Disparate identification of nonhuman remains between sites cannot be attributed to differences in histological preservation or cremation intensities. Data demonstrate that multispecies cremation burials at Bidford were relatively common, making up about a third of all cremation burials, which mirrors cemetery data from the Core Cremation Zone (Bond, 1996). Results support the conclusion that there was heterogeneity of cremation practice in the Avon Valley but within the range of variation observed in the Core Cremation Zone of eastern England.

As a research tool, histological analysis provides valuable information not available through other approaches; however, this must be weighed against the time commitment required to produce and evaluate samples as well as the destructive nature of the process. While histological analysis can confirm the presence of nonhuman bone in archaeological contexts, it cannot positively identify human bone or discriminate nonhuman bone fragments to the genus or species level. Without comprehensive data on species or skeletal elements included on the pyre, we are unable to move beyond presence/absence studies

towards understanding the role particular species or food items played within mortuary ritual. These limitations must be considered when developing a research design. Active research in applied bone histology continues to advance histomorphometric methods (see Maggiano et al., 2021; Franklin & Marks, 2022). With robust data available to model shrinkage and warping effects of cremation on histological structures, objective metrics may one day be available to identify bone fragments to specific taxa through metric analysis of secondary osteons, spatial analysis of dense Haversian bone organization or relative abundance of histological morphotypes (Lagacé et al., 2020).

Multispecies cremations in early medieval cemeteries are now a well-recognized phenomenon, although questions remain about the ritual treatment and symbolism of the animal deposits (Rainsford, 2021; Williams, 2001). According to current standards for human remains recording, zooarchaeologists or comparative osteologists should be brought in early during excavation or post-excavation, with information about cremated animal bone documented in skeletal inventory reports (McKinley, 2017). A histological approach should be considered to supplement the macroscopic investigation to confirm the identification of nondiagnostic, but probable, nonhuman bone fragments and to document any differences in the cremation intensity between human and nonhuman fragments.

## ACKNOWLEDGMENTS

Invaluable feedback was provided by Drs. Randall White (NYU), Susan Antón (NYU), Aleksander Pluskowski (University of Reading), Richard Madgwick (Cardiff University), and our anonymous reviewers. Dr. Bradley Adams and staff at the Forensic Anthropology Lab at the New York City Office of the Chief Medical Examiner provided equipment and histological slides for training and comparative purposes. Dr. Timothy Bromage and staff at the NYU Dental School Hard Tissue Research Unit Laboratory provided training and equipment. The Shakespeare Birth Trust and Warwicksh Museum granted access and workspace to analyze the cemetery assemblages.

## CONFLICT OF INTEREST

There is no conflict of interest.

## DATA AVAILABILITY STATEMENT

The data that support the findings of this study are available in the supporting information of this article.

## ORCID

Katherine McCullough French  <https://orcid.org/0000-0002-3965-4269>

## ENDNOTES

<sup>1</sup> In the United Kingdom, these may include Human Tissue Act (2004); British Association for Biological Anthropology and Osteoarchaeology (BABAO) *Code of Ethics* (2019), ClfA Updated Guidance for Human Remains (Mitchell & Brickley, 2017), and DCMS *Guidance for the Care of Human Remains in Museums* (Swain, 2005).

<sup>2</sup> More precisely, these methods differentiate primate from non-primate bone. Primates have broadly similar biomechanics and life histories when



compared to fast-growing quadrupeds (Hillier & Bell, 2007; McFarlin, 2006), but the forensic and archaeological literature generally conflates nonhuman with non-primate. Considering the very low probability of nonhuman primate bone in early medieval English burial contexts, nonhuman primate histology is not considered here.

## REFERENCES

- Advisory Panel on the Archaeology of Burials in England (APABE). (2013). Science and the dead: a guideline for the destructive sampling of archaeological human remains for scientific analysis.
- Amprino, R. (1947). La Structure du Tissue Osseux Envisagée Comme Expression de Differences dans la Vitesse de L'accroissement. *Archives de Biologie*, 58, 315–330.
- Andronowski, J., Pratt, I. V., & Cooper, D. M. L. (2017). Occurrence of osteon banding in adult human cortical bone. *American Journal of Physical Anthropology*, 164, 635–642. <https://doi.org/10.1002/ajpa.23297>
- Bhat, M. S., Chinsamy, A., & Parkington, J. (2021). Histological investigations of burnt bones: A case study of angulate tortoises from the archaeological site, Diepkloof rock shelter, Western cape, South Africa. *International Journal of Osteoarchaeology*, 31, 742–757. <https://doi.org/10.1002/oa.2986>
- Bogin, B. (2020). *Patterns of human growth* (Third ed.). Cambridge University Press. <https://doi.org/10.1017/9781108379977>
- Bond, J. (1996). Burnt offerings: Animal bone in Anglo-Saxon cremations. *World Archaeology*, 28(1), 76–88. <https://doi.org/10.1080/00438243.1996.9980332>
- Bond, J., & Worley, F. (2006). Companions in Death: The roles of animals in Anglo-Saxon and Viking cremation rituals in Britain. In R. Gowland & C. Knüsel (Eds.), *Social archaeology of funerary remains* (pp. 89–98). Oxbow.
- Booth, T., & Madgwick, R. (2016). New evidence for diverse secondary burial practices in Iron age Britain: A histological case study. *Journal of Archaeological Science*, 67, 14–24. <https://doi.org/10.1016/j.jas.2016.01.010>
- British Association for Biological Anthropology and Osteoarchaeology (BABAO). (2019). Code of ethics. <https://www.babao.org.uk/assets/Uploads/BABAO-Code-of-Ethics-2019.pdf>
- Caccia, G., Magli, F., Tagi, V. M., Porta, D. G. A., Cummaudo, M., Márquez-Grant, N., & Cattaneo, C. (2016). Histological determination of the human origin from dry bone: A cautionary note for subadults. *International Journal of Legal Medicine*, 130, 299–307. <https://doi.org/10.1007/s00414-015-1271-6>
- Cambrá-Moo, O., Barroso Bermejo, R., García Gil, O., Bueno Ramírez, P., Rascón Pérez, J., González Martín, A., & de Balbín Behrmann, R. (2018). Can histomorphology enhance the analysis of cremated human bones in an archaeological context? A case from the Lagunita I archaeological site, Santiago de Alcántara (Cáceres), Spain. *Journal of Archaeological Science: Reports*, 20, 675–682. <https://doi.org/10.1016/j.jasrep.2018.06.012>
- Carver, M. (2010). Agency, intellect and the archaeological agenda. In M. Carver, A. Sanmark, & S. Semple (Eds.), *Signals of belief: Anglo-Saxon paganism revisited* (pp. 1–20). Oxbow.
- Carver, M., Hills, C., & Scheschkewitz, J. (2009). *Wasperton: A Roman, British and Anglo-Saxon community in Central England*. Boydell Press.
- Cattaneo, C., DiMartino, S., Scali, S., Craig, O. E., Grandi, M., & Sokol, R. J. (1999). Determining the human origin of fragments of burnt bone: A comparative study of histological, immunological and DNA techniques. *Forensic Science International*, 102, 181–191. [https://doi.org/10.1016/S0379-0738\(99\)00059-6](https://doi.org/10.1016/S0379-0738(99)00059-6)
- Crocker, S. L., Reed, W., & Donlon, D. (2016). Comparative cortical bone thickness between the long bones of humans and give common non-human mammal taxa. *Forensic Science International*, 260, 104.e1–104.e17. <https://doi.org/10.1016/j.forsciint.2015.12.022>
- Crowder, C., Heinrich, J., & Stout, S. (2012). Rib Histomorphometry for adult age estimation. In L. Bell (Ed.), *Forensic microscopy for skeletal tissues: Methods and protocols* (Vol. 915). Methods in molecular biology. (pp. 109–127). Humana.
- Crowder, C., & Stout, S. (2012). Bone remodeling, histomorphology and mistomorphometry. In S. Stout & C. Crowder (Eds.), *Bone histology: An anthropological perspective* (pp. 1–22). CRC Press.
- Cuijpers, A. G. F. M. (2006). Histological identification of bone fragments in archaeology: Telling humans apart from horses and cattle. *International Journal of Osteoarchaeology*, 16, 465–480. <https://doi.org/10.1002/oa.848>
- Cuijpers, S. (2009). Distinguishing between the bone fragments of medium-sized mammals and children: A histological identification method for archaeology. *Anthropologischer Anzeiger*, 67(2), 181–203. <https://doi.org/10.1127/0003-5548/2009/0021>
- Cummaudo, M., Cappella, A., Biraghi, M., Raffone, C., Márquez-Grant, N., & Cattaneo, C. (2018). Histomorphological analysis of the variability of the human skeleton: Forensic implications. *International Journal of Legal Medicine*, 132(5), 1493–1503. <https://doi.org/10.1007/s00414-018-1781-0>
- Currey, J. D. (2002). *Bones: Structures and mechanics*. Princeton University Press. <https://doi.org/10.1515/9781400849505>
- de Margerie, E., Cubo, J., & Castanet, J. (2002). Bone typology and growth rate: Testing and quantifying ‘Amprino’s rule’ in the mallard (*Anas platyrhynchos*). *CR Biologies*, 325, 21–230. [https://doi.org/10.1016/S1631-0691\(02\)01429-4](https://doi.org/10.1016/S1631-0691(02)01429-4)
- de Margerie, E., Robin, J. P., Verrier, D., Cubo, J., Groscolas, R., & Castanet, J. (2004). Assessing a relationship between bone microstructure and growth rate: A fluorescent labelling study in the king penguin chick (*Aptenodytes patagonicus*). *Journal of Experimental Biology*, 207(5), 869–879. <https://doi.org/10.1242/jeb.00841>
- de Ricqlès, A. J., Meunier, F. J., Castanet, J., & Francillon-Vieillot, H. (1991). Comparative microstructure of bone. In B. K. Hall (Ed.), *Bone volume 3: Bone matrix and bone specific products* (pp. 1–78). CRC Press.
- Defense POW/MIA Accounting Agency. (2015). Standard operative procedure 3.8: Histomorphology. *DPAA Laboratory Manual*. Revised 6 February.
- Dickinson, T. (2021). The Anglo-Saxon cemetery (phase 3). In S. Hirst & T. Dickinson (Eds.), *The archaeology of Bidford-on-Avon: Excavations 1970-94* (Vol. 123) (pp. 52–108). Birmingham and Warwickshire Archaeological Society: Transactions.
- Dickinson, T., & Speake, G. (1992). The seventh-century cremation burial in Asthall Barrow, Oxfordshire: A reassessment. In M. Carver (Ed.), *The age of Sutton Hoo: The seventh century in north-western Europe* (pp. 95–130). Boydell.
- Dixon, K., Novak, S. A., Robbins, G., Schablitsky, J. M., Scott, G. R., & Tasa, G. L. (2011). “Men, women, and children starving”: Archaeology of the Donner family camp. *American Antiquity*, 75(3), 627–656. <https://doi.org/10.7183/0002-7316.75.3.627>
- Dominguez, V. M., & Crowder, C. M. (2012). The utility of osteon shape and circularity for differentiating human and non-human Haversian bone. *American Journal of Physical Anthropology*, 149(1), 84–91. <https://doi.org/10.1002/ajpa.22097>
- Franklin, D., & Marks, M. K. (2022). The professional practice of forensic anthropology: Contemporary developments and cross-disciplinary applications. *Wiley Interdisciplinary Reviews: Forensic Science*, 4(2), e1442. <https://doi.org/10.1002/wfs2.1442>
- French K, Bricking A, Madgwick R. (2022). More than one way to thin section a cat: Comparing sample preparation protocols for bone histology. Poster presented at the United Kingdom Archaeological Sciences Conference. University of Aberdeen.
- Gigante, M., Nava, A., Paine, R. R., Fiore, I., Alhaique, F., Esposito, C. M., Sperduti, A., Bonetto, J., Cinquantaquattro, T. E., d’Agostino, B., & Bondioli, L. (2021). Who was buried with Nestor’s cup? Macroscopic and microscopic analyses of the cremated remains from tomb

- 168 (second half of the 8<sup>th</sup> century BCE, Pithekoussai, Ischia Island, Italy). *PLOS One*, 16(1), e0257368. <https://doi.org/10.1371/journal.pone.0257368>
- Gocha, T. P., & Agnew, A. M. (2016). Spatial variation in osteon population density at the human femoral midshaft: Histomorphometric adaptations to habitual load environment. *Journal of Anatomy*, 228, 733–745. <https://doi.org/10.1111/joa.12433>
- Hanson, M., & Cain, C. R. (2007). Examining histology to identify burned bone. *Journal of Archaeological Science*, 34, 1902–1913. <https://doi.org/10.1016/j.jas.2007.01.009>
- Harbeck, M., Schleuder, R., Schneider, J., Wiechmann, I., Schmahl, W. W., & Grupe, G. (2011). Research potential and limitations of trace analyses of cremated remains. *Forensic Science International*, 204(1–3), 191–200. <https://doi.org/10.1016/j.forsciint.2010.06.004>
- Hedges, R. E. M., Millard, A. R., & Pike, A. W. G. (1995). Measurements and relationships of diagenetic alteration of bone from three archaeological sites. *Journal of Archaeological Science*, 22, 201–209. <https://doi.org/10.1006/jasc.1995.0022>
- Hillier, M. L., & Bell, L. S. (2007). Differentiating human bone from animal bone: A review of histological methods. *Journal of Forensic Science*, 52(2), 249–263. <https://doi.org/10.1111/j.1556-4029.2006.00368.x>
- Hills, C., & Lucy, S. (2013). *Spong Hill IX: Chronology and synthesis*. McDonald Institute monographs. McDonald Institute for Archaeological Research.
- Human Tissue Act. (2004). (c.30). (pp. 1–215). The Stationary Office.
- Humphreys, J., Ryland, J. W., Barnard, E. A. B., Wellstood, F. C., & Barnett, T. G. (1923). An Anglo-Saxon cemetery at Bidford-on-Avon, Warwickshire. *Archaeologia*, 73, 89–116. <https://doi.org/10.1017/S0261340900010304>
- Humphreys, J., Ryland, J. W., Wellstood, F. C., Barnard, E. A. B., & Barnett, T. G. (1925). An Anglo-Saxon cemetery at Bidford-on-Avon, Warwickshire: A second report. *Archaeologia*, 74, 271–288. <https://doi.org/10.1017/S0261340900013163>
- Imazumi, K., Taniguchi, K., & Ogawa, Y. (2014). DNA survival and physical and histological properties of heat-induced alterations in burnt bones. *International Journal of Legal Medicine*, 128(3), 439–446. <https://doi.org/10.1007/s00414-014-0988-y>
- Jowsey, J. (1966). Studies of Haversian systems in man and some animals. *Journal of Anatomy*, 100(4), 857–864.
- Kuzawa, C. W., Chugani, H. T., Grossman, L. I., Lipo, L., Muzik, O., Hof, P. R., Wildman, D. E., Sherwood, C. C., Leonard, W. R., & Lange, N. (2014). Metabolic costs and evolutionary implications of human brain development. *PNAS*, 111(36), 13010–13015. <https://doi.org/10.1073/pnas.1323099111>
- Lagacé, F., Schmitt, A., Martrille, L., Benassi, J., & Adalian, P. (2020). Using histomorphometry for human and nonhuman distinction: A test of four methods on fresh and archaeological fragmented bones. *Forensic Science International*, 313, 110369. <https://doi.org/10.1016/j.forsciint.2020.110369>
- Lemmers, S. A. M., Gonçalves, D., Cunha, E., Vassalo, A. R., & Appleby, J. (2020). Burned fleshed or dry? The potential of bioerosion to determine the pre-burning condition of human remains. *Journal of Archaeological Method and Theory*, 27, 972–991. <https://doi.org/10.1007/s10816-020-09446-x>
- Maggiano, I. S., Maggiano, C. M., & Cooper, D. M. (2021). Osteon circularity and longitudinal morphology: Quantitative and qualitative three-dimensional perspectives on human Haversian systems. *Micron*, 140, 102955. <https://doi.org/10.1016/j.micron.2020.102955>
- Martiniaková, M., Grosskopf, B., Omelka, R., Dammers, K., Vondráková, M., & Bauerová, M. (2007). Histological study of compact bone tissue in some mammals: A method for species determination. *International Journal of Osteoarchaeology*, 17, 82–90. <https://doi.org/10.1002/oa.856>
- Mason, A., & Williamson, T. (2017). Ritual landscapes in pagan and early Christian England. *Fragments*, 6, 80–109.
- McFarlin, S. C. (2006). *Ontogenetic variation in long bone microstructure in catarrhines and its significance for life history research*. Ph.D. thesis. City University of New York Graduate Center.
- McKinley, J. (1994). Bone fragment size in British cremation burials and its implications for pyre technology and ritual. *Journal of Archaeological Science*, 21, 339–342. <https://doi.org/10.1006/jasc.1994.1033>
- McKinley, J. (2017). Compiling a skeletal inventory: Cremated human bone. In P. D. Mitchell & M. Brickley (Eds.), *updated guidelines to the standards for recording human remains* (pp. 14–19). Chartered Institute for Archaeologists.
- McKinley, J., & Bond, J. (1993). Cremated animal bone, summary discussion, animal accessory vessels. In J. Timby (Ed.), *Sancton I Anglo-Saxon cemetery excavations carried out between 1976 and 1980*. *The Archaeological Journal*, 150, 300–311. <https://doi.org/10.1080/00665983.1993.11078057>
- Mckinnon, M., Henneberg, M., & Higgins, D. (2021). A review of the current understanding of burned bone as a source of DNA for human identification. *Science & Justice*, 61(4), 332–338. <https://doi.org/10.1016/j.scijus.2021.03.006>
- Meaney, A. (1964). *Gazetteer of early Anglo-Saxon burial sites*. George Allen & Unwin.
- Mitchell, P., & Brickley, M. (Eds.) (2017). *Updated guidelines to the standards for recording human remains*. Chartered Institute for Archaeologists.
- Mulhern, D., & Ubelaker, D. H. (2001). Differences in osteon banding between human and nonhuman bone. *Journal of Forensic Science*, 46, 220–222. <https://doi.org/10.1520/JFS14952J>
- Naihui, W., Samantha, B., Peter, D., Sandra, H., Maxim, K., Sindy, L., Oshan, W., Stefano, G., Michael, C., Liora, H. K., Matthew, S., Glenn, S., Michael, S., Kristine, R. K., & Katerina, D. (2021). Testing the efficacy and comparability of ZooMS protocols on archaeological bone. *Journal of Proteomics*, 233, 104078. <https://doi.org/10.1016/j.jprot.2020.103078>
- Nganvongpanit, K., Pradit, W., Pitakarnop, T., Phatsara, M., & Chomdej, S. (2017). Differences in osteon structure histomorphometry between puppyhood and adult stages in the Golden retriever. *Anatomical Science International*, 92, 483–492. <https://doi.org/10.1007/s12565-016-0345-y>
- Nor, F. M., Pastor, R. F., & Schutkowski, H. (2015). Histological study to differentiate between human and non human long bone. *International Medical Journal*, 22(5), 413–417.
- Owsley, D. W., Mires, A. M., & Keith, M. S. (1985). Case involving differentiation of deer and human bone fragments. *Journal of Forensic Sciences*, 30(2), 572–578. <https://doi.org/10.1520/JFS11842J>
- Pfeiffer, S. (2006). Cortical bone histology in juveniles. In G. Grupe & J. Peters (Eds.), *Microscopic examinations of bioarchaeological remains: Keeping a close eye on ancient remains* (Vol. 4). Documenta Archaeobiologiae. (pp. 15–28). Verlag Maria Leidorf GmbH.
- Rainsford, C. (2021). One hoof in the grave? Animal remains as inhumation grave goods in early medieval eastern England. *Archaeological Journal*, 178(1), 146–165. <https://doi.org/10.1080/00665983.2020.1864613>
- Sawada, J., Nara, T., Fukui, J., Dodo, Y., & Hirata, K. (2014). Histomorphological species identification of tiny bone fragments from a Paleolithic site in the northern Japanese archipelago. *Journal of Archaeological Science*, 46, 270–280. <https://doi.org/10.1016/j.jas.2014.03.025>
- Sázelová, S., Boriová, S., & Šaliová, S. (2021). The upper Paleolithic hard animal tissue under the microscope: Selected examples from Moravian sites. *Quaternary International*, 587, 127–136. <https://doi.org/10.1016/j.quaint.2020.10.027>
- Shipman, P., Foster, G., & Schoeninger, M. (1984). Burnt bones and teeth: An experimental study of color, morphology, crystal structure and shrinkage. *Journal of Archaeological Science*, 11, 307–325. [https://doi.org/10.1016/0305-4403\(84\)90013-X](https://doi.org/10.1016/0305-4403(84)90013-X)

- Skedros, J. G., Bloebaum, R. D., Mason, M. W., & Bramble, D. M. (1994). Analysis of a tension/compression skeletal system: Possible strain-specific differences in the hierarchical organization of bone. *The Anatomical Record*, 239(4), 396–404. <https://doi.org/10.1002/ar.1092390406>
- Snoeck, C., Brock, F., & Schulting, R. J. (2014). Carbon exchanges between bone apatite and fuels during cremation: Impact on radiocarbon dates. *Radiocarbon*, 56(2), 591–602. <https://doi.org/10.2458/56.17454>
- Squires, K., Thompson, T., Islam, M., & Chamberlain, A. (2011). The application of histomorphometry and Fourier transform infrared spectroscopy to the analysis of early Anglo-Saxon burned bone. *Journal of Archaeological Science*, 38, 2399–2409. <https://doi.org/10.1016/j.jas.2011.04.025>
- Squires, K. E. (2016). Neighbours and networks: Funerary trends among cremation practicing groups in early medieval England and North-Western Europe. In *Le témoignage de la culture matérielle: mélanges offerts au Professeur Vera Evison* (pp. 116–135). Éditions Mergoïl.
- Stodder, A. L. W. (2018). Taphonomy and the nature of archaeological assemblages. In M. A. Katzenberg & S. R. Saunder (Eds.), *Biological anthropology of the human skeleton* (Third ed.) (pp. 71–114). Wiley & Sons. <https://doi.org/10.1002/9781119151647.ch3>
- Swain, H. (Ed.) (2005). *Guidance for the care of human remains in museums*. DCMS.
- Urbanová, P., & Novotny, V. (2005). Distinguishing between human and non-human bones: Histometric method for forensic anthropology. *L'Anthropologie*, 43, 77–85.
- Wellstood F.C. (n.d.). An Anglo-Saxon cemetery at Stratford-upon-Avon. Unpublished. On file at New Place Museum, Stratford-on-Avon, United Kingdom.
- Williams, H. (2001). An ideology of transformation: Cremation rites and animal sacrifice in early Anglo-Saxon England. In N. Price (Ed.), *The archaeology of shamanism* (pp. 193–212). Routledge.
- Williams, H. (2010). At the funeral. In M. Carver, A. Sanmark, & S. Semple (Eds.), *Signals of belief in early England: Anglo-Saxon paganism revisited* (pp. 67–82). Oxbow.
- Zazzo, A., Saliège, J. F., Lebon, M., Lepetz, S., & Moreau, C. (2012). Radiocarbon dating of calcined bones: Insights from combustion experiments under natural conditions. *Radiocarbon*, 54(3–4), 1–12. <https://doi.org/10.1017/S0033822200047500>
- Zoetis, T., Tassinari, M. S., Bagi, C., Walthall, K., & Hurtt, M. E. (2003). Species comparison of postnatal bone growth and development. *Birth Defects Research (Part B)*, 68, 86–110. <https://doi.org/10.1002/bdrb.10012>

## SUPPORTING INFORMATION

Additional supporting information can be found online in the Supporting Information section at the end of this article.

**How to cite this article:** French, K. M., Crowder, C., & Crabtree, P. J. (2022). Integrating histology in the analysis of multispecies cremations: A case study from early medieval England. *International Journal of Osteoarchaeology*, 1–11. <https://doi.org/10.1002/oa.3160>