Clinical Radiology 76 (2021) 88–98

Contents lists available at ScienceDirect

Clinical Radiology

journal homepage: www.clinicalradiologyonline.net

Review

Multimodality imaging in connective tissue disease-related interstitial lung disease☆

C.A. Ruano [a,b,c,*], M. Grafino [d], A. Borba [e], S. Pinheiro [f], O. Fernandes [a,b], S.C. Silva [g], T. Bilhim [c,h], M.F. Moraes-Fontes [i], K.L. Irion [j,k]

[a] *Radiology Department, Hospital de Santa Marta, Centro Hospitalar Universitário de Lisboa Central, Lisboa, Portugal*
[b] *Radiology Department, Hospital da Luz, Lisboa, Portugal*
[c] *NOVA Medical School, Universidade Nova de Lisboa, Lisboa, Portugal*
[d] *Pulmonology Department, Hospital da Luz, Lisboa, Portugal*
[e] *Pulmonology Department, Hospital de Santa Marta, Centro Hospitalar Universitário de Lisboa Central, Lisboa, Portugal*
[f] *Autoimmune Disease Unit, Unidade de Doenças Auto-imunes/Serviço Medicina 3, Hospital de Santo António dos Capuchos, Centro Hospitalar Universitário de Lisboa Central, Lisboa, Portugal*
[g] *Radiology Department, Hospital de São José, Centro Hospitalar Universitário de Lisboa Central, Lisboa, Portugal*
[h] *Interventional Radiology Unit, Hospital Curry Cabral, Centro Hospitalar Universitário de Lisboa Central, Lisboa, Portugal*
[i] *Autoimmune Disease Unit, Unidade de Doenças Auto-imunes/Serviço Medicina 7.2, Hospital Curry Cabral, Centro Hospitalar Universitário de Lisboa Central, Lisboa, Portugal*
[j] *Radiology Department, Manchester Royal Infirmary, Manchester, United Kingdom*
[k] *University of Manchester, Division of Infection Immunity & Respiratory Medicine, School of Biological Sciences, Manchester, United Kingdom*

ARTICLE INFORMATION

Article history:
Received 4 March 2020
Accepted 28 July 2020

Interstitial lung disease is a well-recognised manifestation and a major cause of morbidity and mortality in patients with connective tissue diseases. Interstitial lung disease may arise in the context of an established connective tissue disease or be the initial manifestation of an otherwise occult autoimmune disorder. Early detection and characterisation are paramount for adequate patient management and require a multidisciplinary approach, in which imaging plays a vital role. Computed tomography is currently the imaging method of choice; however, other imaging techniques have recently been investigated, namely ultrasound, magnetic resonance imaging, and positron-emission tomography, with promising results. The aim of this review is to describe the imaging findings of connective tissue disease-related interstitial lung disease and explain the role of each imaging technique in diagnosis and disease characterisation.

☆ A review of this topic has been previously presented as an electronic poster at the 2019 annual meeting of the European Society of Thoracic Imaging (ESTI), Paris, France. The electronic poster can be accessed at: https://dx.doi.org/10.26044/esti2019/P-0066.

* Guarantor and correspondent: C. A. S. Ruano, Radiology Department, Hospital de Santa Marta, Centro Hospitalar Universitário de Lisboa Central, Rua de Santa Marta 50, 1169-024, Lisboa, Portugal. Tel.: +351 916510702.
E-mail address: carina.s.ruano@gmail.com (C.A. Ruano).

https://doi.org/10.1016/j.crad.2020.07.035
0009-9260/

Introduction

Connective tissue diseases (CTDs) comprise several immune-mediated systemic disorders that may cause various thoracic abnormalities, of which interstitial lung disease (ILD) is a well-recognised manifestation and a major cause of morbidity and mortality.[1] The term ILD embraces a group of parenchymal lung disorders in which damage to the lungs results from different combinations of inflammation, remodelling, and fibrosis.[2]

Idiopathic versus CTD-related ILD

The distinction between idiopathic and secondary ILD is of major importance, as it impacts treatment and prognosis.[3,4] Secondary ILD may arise in the context of an established CTD or be the first, or sole, manifestation of an otherwise occult autoimmune disease. Serum antibodies, extra-pulmonary manifestations (such as Raynaud phenomenon and articular involvement) and multicompartment thoracic involvement (lungs, airways, pleura, cardiovascular system, and oesophagus) may aid the diagnosis (Electronic Supplementary Material Fig. S1). Demographic features should also be taken into account, as idiopathic pulmonary fibrosis (IPF) is more frequent in male patients in their sixth or seventh decade of life, while patients with CTD-ILD are usually younger, of female gender, and less likely to have a smoking history.[5,6]

The most common patterns of CTD-related ILD are non-specific interstitial pneumonia (NSIP), usual interstitial pneumonia (UIP), organizing pneumonia (OP), and lymphoid interstitial pneumonia (LIP). The pattern and frequency of ILD varies according to the underlying CTD (Table 1).[7,8]

Although NSIP is the histological hallmark of CTD-related ILD, UIP is most commonly associated with IPF; however, specific computed tomography (CT) features may signal the possibility of CTD-related UIP, such as concentration of fibrosis in the anterior aspect of the upper lobes with concomitant lower lobe involvement ("anterior upper lobe sign"; Electronic Supplementary Material Fig. S2), presence of exuberant honeycomb-like cysts constituting >70% of fibrotic portions of the lungs ("exuberant honeycombing" sign; Electronic Supplementary Material Fig. S3), and isolation of fibrosis to the lung bases with sharp demarcation in the cranio-caudal plane ("straight-edge" sign; Electronic Supplementary Material Fig. S4).[6]

Some patients with ILD may present with serological abnormalities or symptoms suggestive of an autoimmune disease without fulfilling established criteria for a specific CTD. These patients have recently been grouped under the term "interstitial pneumonia with autoimmune features" (IPAF). CT and histopathology patterns of NSIP, OP, NSIP with OP overlap, and LIP, in a patient with features indicative of, but not definitive for, CTD, should suggest this diagnosis (Electronic Supplementary Material Fig. S5).[9]

Table 1
Prevalence and patterns of ILD in CTD.

Prevalence and patterns of ILD in CTD						
CTD	*SSc*	*RA*	*SLE*	*PM/DM*	*MCTD*	*SS*
ILD overall	70%	20–30%	2–8%	20–50%	20–60%	Up to 25%
NSIP	+++	++	++	+++	++	+++
UIP	+	+++	+	+	+	+
OP	+	++	+	+++	+	-
LIP	-	+	+	-	-	++

LIP, lymphoid interstitial pneumonia; MCTD, mixed connective tissue disease; NSIP, non-specific interstitial pneumonia; OP, organising pneumonia; PM/DM, polymyositis/dermatomyositis; RA, rheumatoid arthritis; SLE, systemic lupus erythematosus; SS, Sjögren syndrome; SSc, systemic sclerosis; UIP, usual interstitial pneumonia; Adapted from references [5,8].

Imaging techniques in CTD-related ILD

Chest radiography

Chest radiography is usually the first-line imaging technique in routine clinical practice. The diagnosis of ILD on chest radiography is based on the presence of reticular or reticulonodular opacities with subpleural distribution, usually with reduced lung volumes (Fig 1). Due to the low sensitivity of this technique in the detection of ILD in comparison with CT (39% versus 90–100%), most patients will undergo CT imaging for diagnosis and disease characterisation (Figs. S6, S7).[10]

Computed tomography

CT is currently the imaging method of choice for ILD diagnosis, characterisation, and follow-up, allowing detection of ILD even in subclinical stages. Although CT has the disadvantage of using ionizing radiation (which is potentially worrisome in younger patients that are screened frequently),[11] technological refinement of CT systems, modification of imaging parameters, imaging filtering, and iterative reconstructions contribute to progressive reduction in radiation dose.[12–14] Whereas a limited imaging technique with only nine incremental sections has also been advocated (with significant reduction in radiation dose from 2.09±1.34 to 0.08±0.06 mSv in comparison with standard-dose full-lung-length helical CT),[15] it may limit the evaluation of temporal progression of disease and detection of lung cancer, which is not unusual in ILD patients. Low-dose helical CT is thus preferred in most centres, allowing reduction of radiation dose while maintaining the diagnostic capacity of the method.[16,17]

Besides characterising the ILD pattern, CT is also fundamental to identify associated findings, namely bronchial abnormalities, signs of pulmonary arterial hypertension (PAH), pleural or pericardial effusion, or oesophageal dilatation. In patients with pulmonary fibrosis, the ratio of the diameter of the pulmonary artery to the diameter of the ascending aorta (dPA/dAA) should be used to evaluate the possibility of PAH, as it is a more reliable indicator than the absolute diameter of the pulmonary artery. A dPA/dAA ratio >1 is suggestive of pulmonary hypertension in patients with interstitial fibrosis.[18]

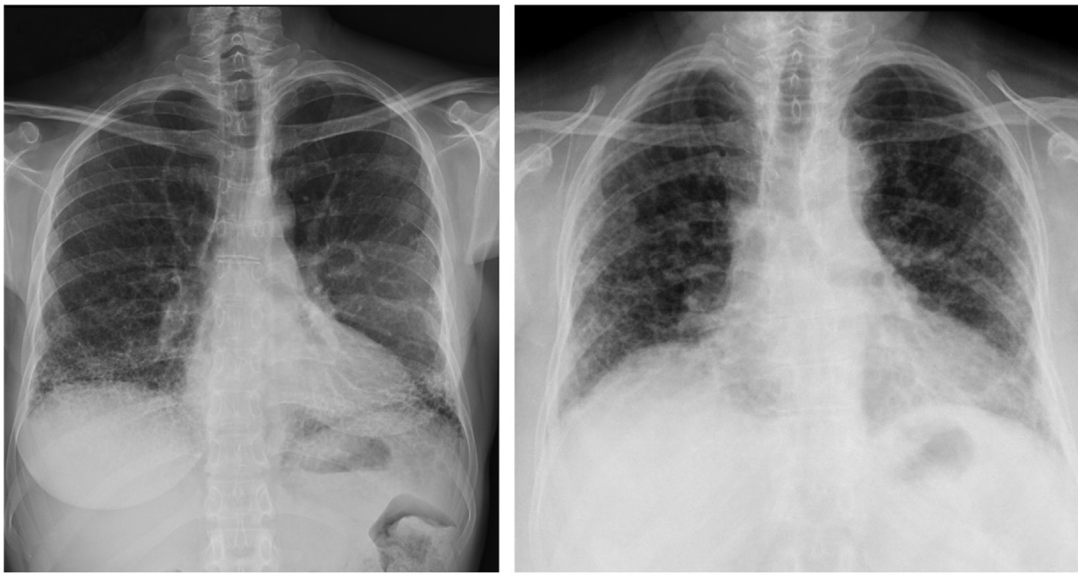

(a) (b)

Figure 1 Chest radiographs of patients with CTD-ILD. Chest radiographs show basal reticular opacities in a patient with SSc (a) and basal reticulonodular opacities with reduced lung volumes in a patient with anti-synthetase syndrome (b).

CT can also aid in the characterisation and differential diagnosis of acute exacerbations (Electronic Supplementary Material Fig. S8), pulmonary opportunistic infections, and drug-related ILD (Electronic Supplementary Material Fig. S9), as well as in the identification of possible concomitant malignancies.[19]

CT findings in specific CTDs

ILD in systemic sclerosis (SSc) is said to be present in up to 100% of patients at autopsy and up to 90% of patients by CT imaging, being more common and more severe than in any other CTD.[20,21] NSIP is the most common pattern of ILD (Fig 2), followed by UIP, the latter generally accounting for a worse prognosis.[22]

Patients can also present with PAH and cardiomyopathy, both of which may be responsible for clinical deterioration.[23,24] PAH is a frequent and often severe manifestation of SSc, which may be caused by small-vessel disease, be secondary to ILD or to myocardial fibrosis (leading to left ventricular dysfunction), or result from a combination of these mechanism.[25] Pulmonary veno-occlusive disease (PVOD), which may also be a cause of PAH in SSc, is characterized by intimal proliferation and fibrosis of the intrapulmonary veins and venules. This diagnosis should be considered if centrilobular ground-glass opacities and smooth interlobular septal thickening are seen in association with mediastinal lymphadenopathy and signs of PAH. This entity should not be overlooked, as patients will frequently develop pulmonary oedema in response to vasodilators.[26,27] Oesophageal dilatation is an extrapulmonary hallmark of SSc and should suggest the diagnosis when seen in combination with NSIP pattern and/or signs of PAH (Electronic Supplementary Material Fig. S1).[28]

Conversely to other CTDs, patients with rheumatoid arthritis (RA)-related ILD most frequently present with UIP pattern (Fig 3).[29] Once the UIP pattern is established, the prognosis is said to be similar to that of idiopathic UIP.[30,31] Although RA is more frequent in females, rheumatoid arthritis (RA)-related ILD is more frequent in males, particularly in smokers.[32] As demographic features and CT findings may overlap with those of IPF, a thorough clinical and serological investigation should be performed, particularly regarding musculoskeletal symptoms and positivity for rheumatoid factor and anti-CCP antibodies.[33] Additionally, patients with RA may also present with airways disease, pleural effusion or pleural thickening (which is typically unilateral and may lead to "trapped lung"), or with pulmonary necrobiotic rheumatoid nodules.[34]

ILD associated with polymyositis and dermatomyositis usually presents as NSIP, OP (Fig 4), or the combination of both.[35] Although clinical features in anti-synthetase syndrome may overlap with those from other inflammatory myopathies, it is associated with a higher prevalence and increased severity of ILD (Electronic Supplementary Material Fig. S10). The combination of NSIP and OP patterns should raise awareness for this diagnosis.[36]

The most characteristic pattern of Sjögren syndrome-related ILD is LIP; however, the most common pattern is NSIP (Fig 5). Additional findings include airway abnormalities, such as bronchiectasis, follicular bronchiolitis, and constrictive bronchiolitis.[37,38]

ILD in patients with mixed connective tissue disease follows that of the previous CTDs, with the most common pattern being NSIP.[5]

Unlike in other CTDs, ILD is rare in patients with systemic lupus erythematosus (SLE); however, pleural or pericardial disease, parenchymal consolidations (alveolar haemorrhage, pulmonary oedema or lupus pneumonitis) or the uncommon "shrinking lung syndrome" may occur.[39,40]

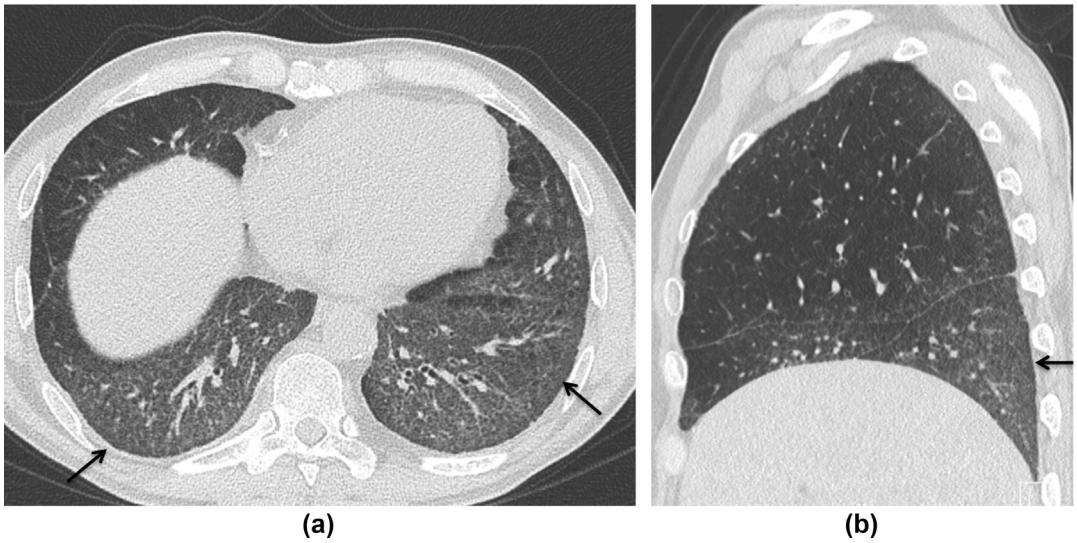

Figure 2 Typical NSIP pattern in a patient with SSc. Images show homogeneous bilateral ground-glass opacities with basal distribution, sparing the immediate subpleural lung (arrows). (b) Sagittal image shows reduced volumes of the right lower and middle lobes (indicated by displacement of the fissures), demonstrating that the ground-glass opacities represent fine fibrosis. The NSIP pattern may also present as irregular reticular opacities with traction bronchiectasis, mainly with central distribution (Fig 5b). Peribronchovascular predominance and sparing of the subpleural lung are helpful signs in differentiating NSIP from UIP.

Disease staging and prognosis

In addition to its fundamental part in disease characterization, CT also has an established role in disease staging and prognosis. In the last few decades several CT scoring systems have been developed, most of which applied to SSc,[41] one of the better-known scores being the Warrick score, which combines severity of ILD abnormalities with extent of disease.[42] Wells and colleagues first published a comparative score, followed by a quantitative score that estimated the extent of disease as a percentage of the evaluated anatomical region. In both, higher CT scores were correlated with low-diffusion capacity values of carbon monoxide (DL_{CO}), forced vital capacity (FVC), and total lung capacity (TLC).[43,44] More recently, Goh and Wells described a simple staging system for SSc-related ILD, in which the distinction between limited (<20%) and extensive (>20%) disease (Electronic Supplementary Material Fig. S11) was shown to be a strong predictor of mortality (HR=3.46; $p<0.0005$), being more discriminatory than CT extent or FVC in isolation.[45] Additionally, in a multivariate analysis, the extent of honeycombing and the severity of traction bronchiectasis have been defined as important independent predictors of mortality. Moreover, patients with a histopathological diagnosis of UIP and discordant radiological

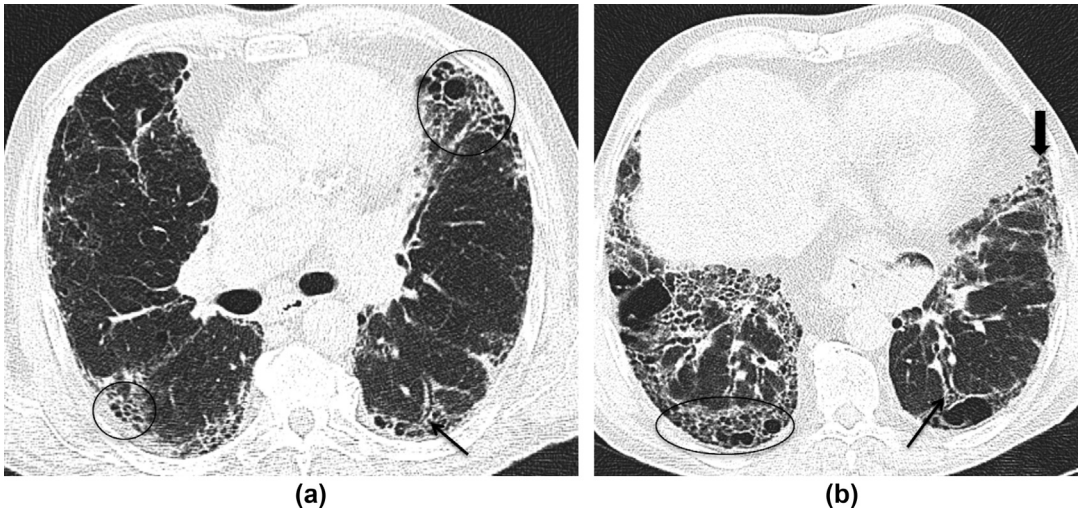

Figure 3 Typical UIP pattern in a patient with RA. Images display interstitial fibrotic abnormalities with heterogeneous distribution, characterised by honeycombing (circle) with basal and subpleural predominance, with peripheral traction bronchiectasis/bronchiolectasis (thin arrow). The presence of subtle ground-glass opacities admixed with reticulation or dilated bronchi (thick arrow), in the absence of acute exacerbation, is regarded as part of the fibrotic process and expected to represent fine fibrosis.

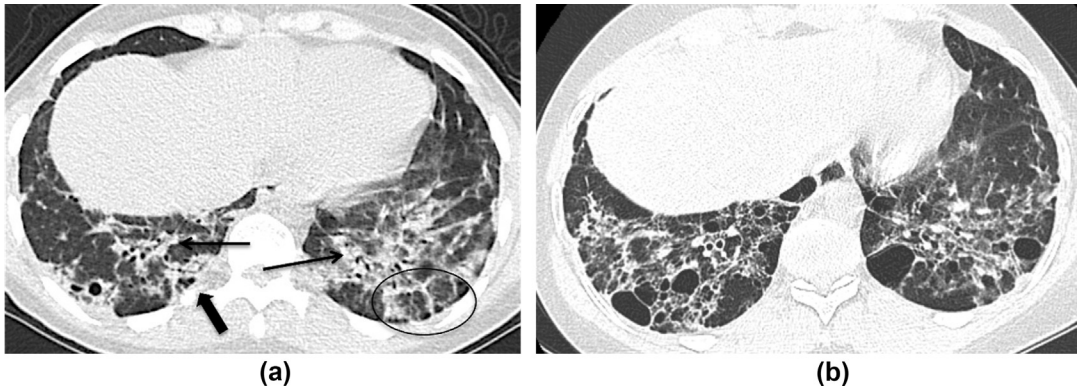

Figure 4 Fibrotic OP pattern in a patient with dermatomyositis. (a) Initial CT demonstrates patchy consolidations with peribronchial (thin arrows) and subpleural (thick arrow) distribution, in addition to subpleural perilobular opacities (circle). (b) CT 4 years later shows the fibrotic evolution of OP. Imaging findings in OP are highly variable, with the most common features being patchy subpleural, peribronchial, or band-like consolidations. The presence of migratory consolidation (Electronic Supplementary Material Fig. S5), perilobular opacities or reverse halo sign increases the diagnostic confidence.

features had a more favourable prognosis than those with radiological and histopathological UIP.[22]

Although disease progression in clinical practice is usually evaluated with visual assessment of CT imaging, there are often difficulties in the evaluation of subtle changes, as well as in the classification of the total disease burden. Quantitative imaging, which includes methods such as histogram analysis and texture-based analysis, is currently used in the research setting alone; however, it is expected to play a major role in the near future in disease staging and follow-up, overcoming the above-described limitations. Texture-based analysis associated with machine learning is able to determine the type of abnormality (ground-glass opacity, reticulation, honeycombing, and emphysema) as well as the severity and extent of disease (Fig 6), with several studies showing good correlation with lung function tests.[46,47] Although quantitative imaging has mostly been applied to patients with IPF,[48–50] it has recently been validated for patients with CTD, in which pulmonary vessel volume, a CALIPER (Computer Aided Lung Informatics for Pathology Evaluation and Rating)-derived parameter, has proven to be an independent predictor of mortality.[51] The quantification of ILD progression has also been shown to aid in the differentiation between CTD-NSIP and IPF without a typical UIP pattern, the latter demonstrating significant increase in reticulation between CT scans.[52]

Ultrasound

Ultrasound (US) is a low-cost, radiation-free imaging technique, which is usually used to study superficial pleural conditions, such as effusion or tumours, or to guide invasive procedures. Recently, US has also been applied to ILD, through detection and quantification of “B-lines”, which are defined as comet-tail artefacts fanning out from the lung surface (Fig 7). These artefacts are visible when the lung parenchyma air content is decreased or the interstitial space expanded, with thickened subpleural interlobular septa, namely in pulmonary oedema and ILD.[53]

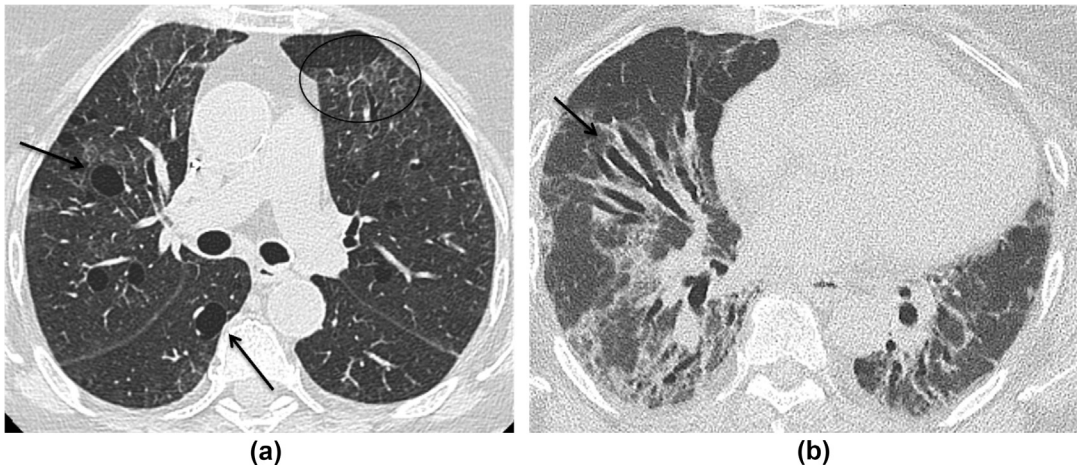

Figure 5 Sjögren syndrome-related ILD. (a) LIP, which is characterised by thin-walled perivascular cysts (arrows) and discrete reticular opacities (circle), is the most characteristic pattern of Sjögren syndrome-related ILD. (b) NSIP is also frequent and may be associated with severe central traction bronchiectasis (arrow).

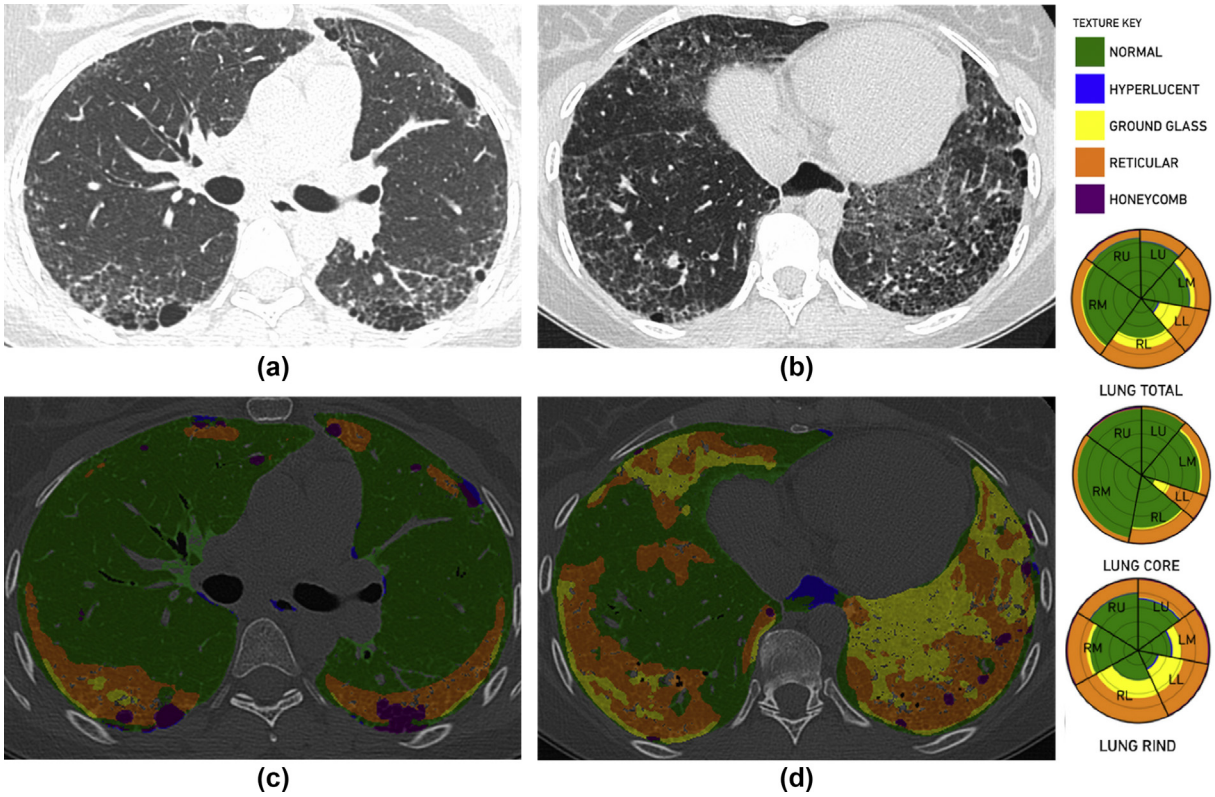

Figure 6 Texture-based CT quantification of ILD. In a patient with SSc-NSIP, (a, b) CT images and (c, d) corresponding parenchymal patterns illustrate the distribution and pattern of interstitial abnormalities (colour coding and glyphs shown in the right-side of the image; Lung Texture Analysis, Imbio, Minneapolis, MN, USA).

Lung US examination should be performed with a 2.5–3.5 MHz convex probe, and the number and location of B-lines should be recorded. There is still no consensus on the number and position of the intercostal spaces that should be analysed, as well as on the definition of a positive examination, ranging from two or more adjacent positive regions with three or more B-lines each, to a total of 10 or more B-lines (with this last criteria described as being highly predictable of significant ILD in patients with SSc).[54–56]

US demonstrated high sensitivity in the detection of ILD in patients with SSc, even in patients with very early SSc, in which a concordance rate of 83% with CT was achieved. Discordant cases were due exclusively to false-positive results, providing a sensitivity of 100%.[57–59] US has also been applied to other CTDs,[60,61] namely RA,[62] Sjögren syndrome,[63] and anti-synthetase syndrome,[64] with significant correlation with CT findings. Although a validated scoring system and a standardized US examination remains to be determined, lung US has the potential to become a useful tool for screening and guiding further investigation with CT, particularly in young patients.[65]

Magnetic resonance imaging

Magnetic resonance imaging (MRI) of the lungs has long been disregarded as it is technically challenging due to low lung proton density, susceptibility artefacts, and cardiorespiratory movement.[66] Although spatial resolution is still a relevant limitation, due to technical developments in MRI sequences and parallel imaging, the sensitivity of conventional MRI in comparison with CT in detection of interstitial abnormalities is generally satisfactory (Fig 8).[67,68] Ultrashort echo time (UTE) sequences, while still in the research setting, provide high-resolution images, with similar diagnostic performance to that of CT.[69,70]

A routine MRI protocol for ILD should include unenhanced breath-holding sequences (coronal single shot fast spin echo T2-weighted sequence; axial 3D gradient echo [GRE] T1-weighted sequence; axial fast spin echo fat-saturated T2-weighted sequence), and a steady-state free-precession GRE sequence acquired during free breathing (Electronic Supplementary Material Fig. S12). Contrast-enhanced sequences may be performed for further disease characterisation.[71,72]

In addition to allowing radiation-free monitoring of disease progression, MRI is able to add tissue contrast characterisation, namely in the differentiation of inflammatory-predominant and fibrotic-predominant ILD (Figs 9 and 10). A study by Yi and colleagues, correlating lung MRI and histopathology, demonstrated that inflammation-predominant biopsy sites showed early enhancement pattern on dynamic studies (82%, $p<0.001$) and high signal intensity on T2-weighted images (53%, $p=0.001$).[73] Recently, T2 mapping has also been described

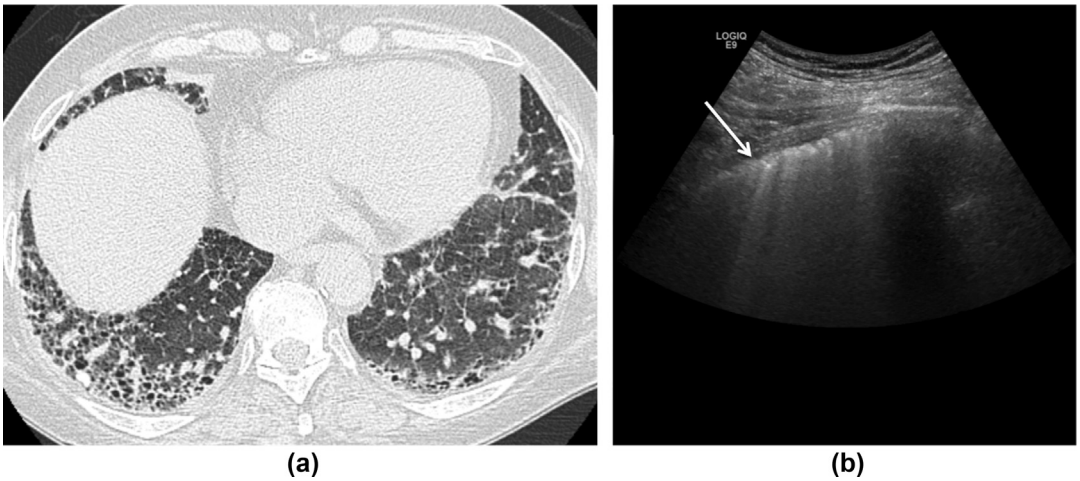

Figure 7 Ultrasound "B-lines". In a patient with interstitial pneumonia with autoimmune features (IPAF)-related ILD, comet-tail artefacts are seen fanning out from the lung surface (arrow in b), due to the presence of subpleural reticulation (illustrated in a).

as a promising technique in differentiating active-inflammatory from stable-fibrotic NSIP.[74,75]

A further advantage of MRI over conventional CT is the ability to provide functional information, particularly regarding ventilatory mechanics. Fibrotic ILD is associated with reduced elastic recoil, which increases the workload of the respiratory muscles, ultimately leading to reduced lung volumes. While diaphragmatic motion can be qualitatively assessed with free-breathing steady state free-precession GRE sequences, MR elastography can quantify pulmonary fibrosis by evaluating parenchymal shear stiffness at total lung capacity and residual volume.[76]

Although MRI is not generally used in routine clinical practice, it is expected to have a more active role in the near future, namely by combining morphological and functional information.

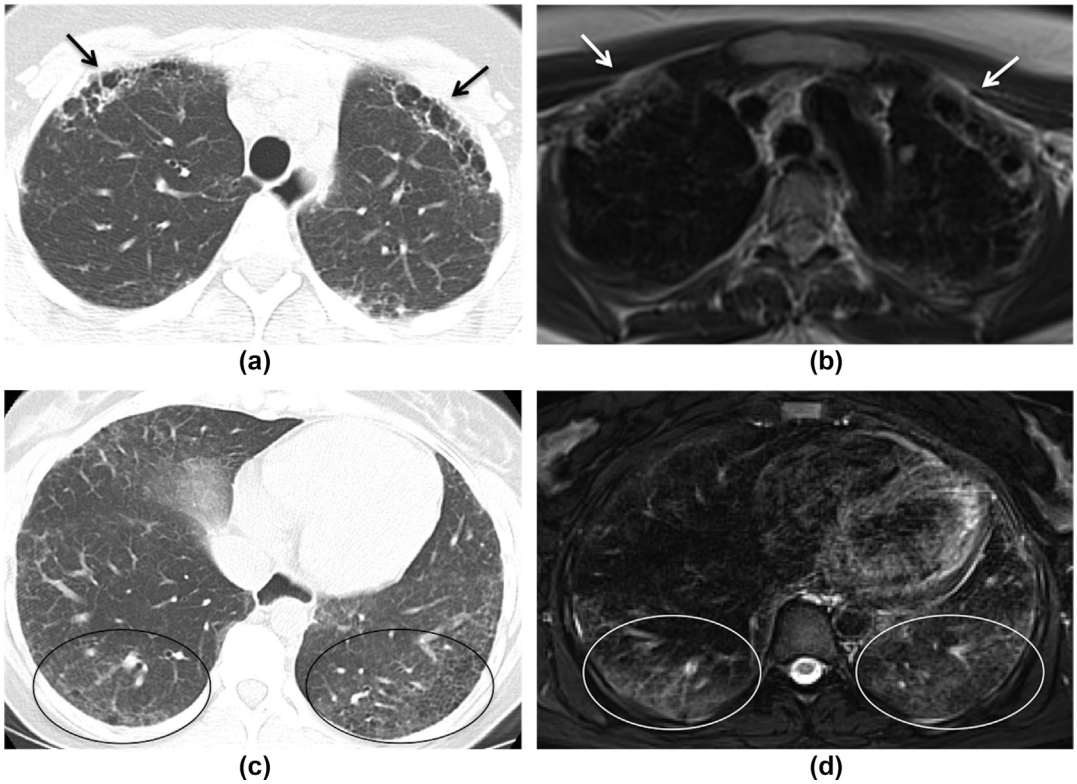

Figure 8 –MRI allows the identification of interstitial abnormalities with similar sensitivity to that of CT. In a patient with SSc, honeycombing (arrows in a and b) and ground-glass opacities (circles in c and d) are adequately depicted in both CT (a, c) and MRI images (b: fast spin echo T2-weighted image; d: fast spin echo fat-saturated T2-weighted image).

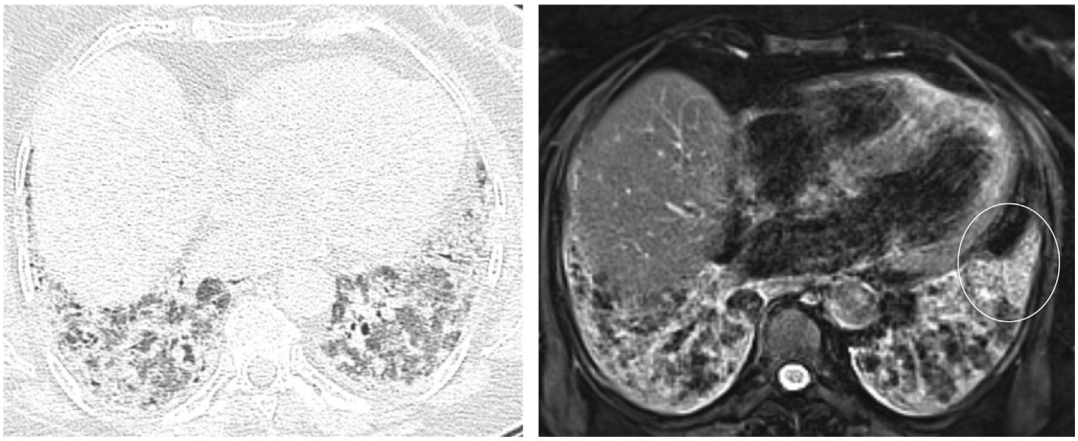

(a) (b)

Figure 9 MRI is able to provide additional information regarding tissue characterisation. In a patient with anti-synthetase syndrome, fast spin echo fat-saturated T2-weighted MRI image shows areas of increased signal intensity likely to represent inflammation (circle in b).

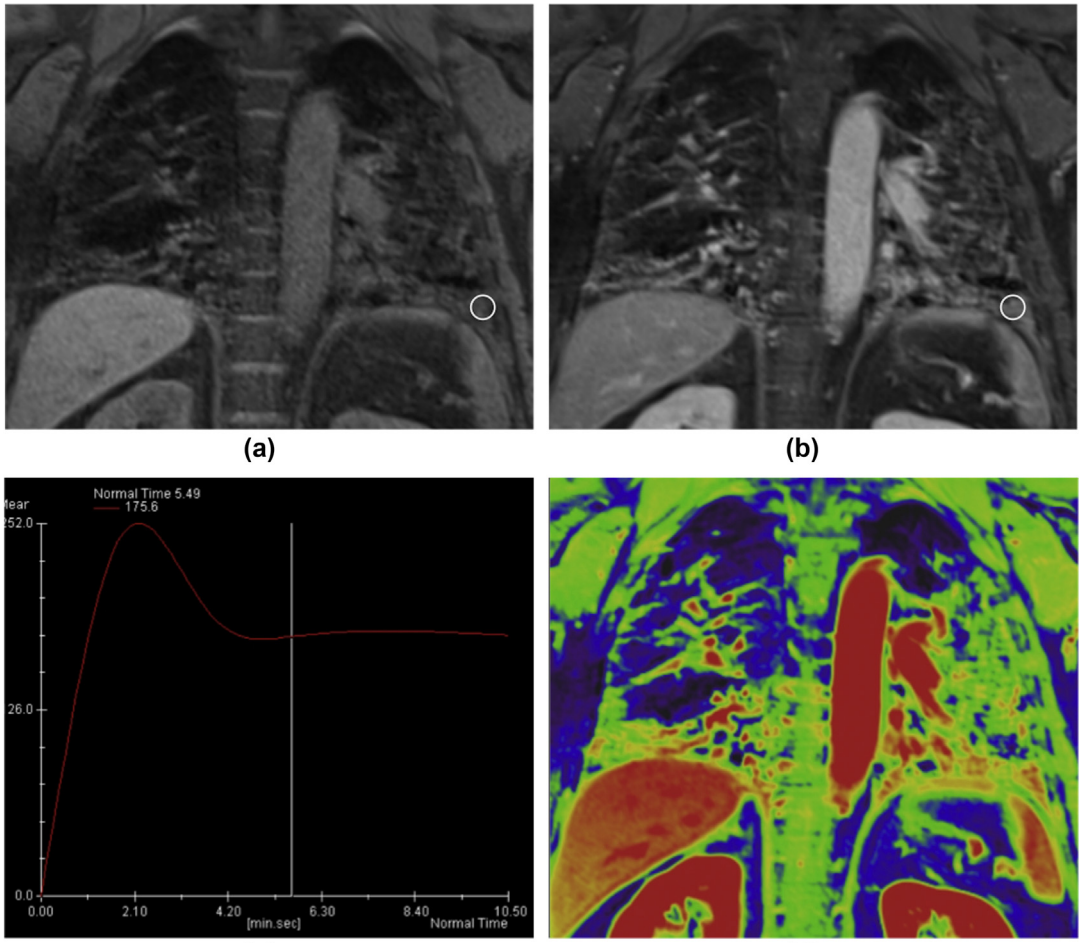

(a) (b)

(c) (d)

Figure 10 Dynamic contrast-enhanced MRI may contribute to the differentiation between inflammatory- and fibrotic-predominant interstitial abnormalities. In a patient with IPAF, coronal GRE fat-saturated T1-weighted images before (a) and after gadolinium administration (b) show enhancement of interstitial reticular abnormalities. Dynamic MRI (images acquired at 1, 3, 5, and 10 minutes) demonstrates early enhancement and washout (c) of the interstitial reticulation, suggesting inflammatory-predominant abnormalities (circles in a and b indicate the region of interest). Colour contrast scale (d) allows prompt detection of areas of maximum contrast enhancement.

Positron-emission tomography

2-[^{18}F]-fluoro-2-deoxy-D-glucose (FDG) positron-emission tomography (PET) is widely used for clinical oncologic imaging; however, it also has an established role in the evaluation of systemic inflammatory conditions, such as large-vessel vasculitis, and has recently been investigated as a molecular imaging method in ILD. In a study by Jacquelin and colleagues, FDG uptake was seen in all of the 18 patients with NSIP evaluated using PET (15 of which with CTD-NSIP), and the extent of FDG uptake was associated with lung function improvement after specific treatment.[77] Uehara *et al.* evaluated 45 CTD-ILD patients with deep-inspiration breath-hold FDG-PET, in which the maximum standardised uptake value (SUVmax) and the extent of FDG uptake were significantly higher in patients with active-phase disease, irrespective of the underlying CTD and CT findings.[78]

Although research on PET imaging in ILD is still in its early days, it has the potential to aid in treatment stratification and monitoring. Furthermore, research on novel PET tracers and targets, such as inducible nitric oxide synthase,[79] cathepsin protease,[80] labelled leucocytes,[81] and type I collagen,[82] may advance the knowledge on pathophysiology of lung inflammation and fibrosis and potentially serve as biomarkers for treatment response.[83]

Conclusion

CTD-ILD evaluation is challenging and requires a multidisciplinary approach. CT occupies a central role in diagnosis, staging, and follow-up of CTD-ILD, and is expected to continue to be the imaging technique of choice in the near future. Ultrasound, MRI, and PET may provide additional valuable information, namely in screening and disease characterisation, respectively; however, these imaging techniques require further optimization for use in routine clinical practice.

Conflict of interest

The authors declare no conflict of interest.

Appendix A. Supplementary data

Supplementary data to this article can be found online at https://doi.org/10.1016/j.crad.2020.07.035.

References

1. Fischer A, du Bois R. Interstitial lung disease in connective tissue disorders. *Lancet* 2012;**380**(9842):689–98. https://doi.org/10.1016/S0140-6736(12)61079-4.
2. Wallace WA, Fitch PM, Simpson AJ, *et al.* Inflammation-associated remodelling and fibrosis in the lung — a process and an end point. *Int J Exp Pathol* 2007 Apr;**88**(2):103–10. https://doi.org/10.1111/j.1365-2613.2006.00515.x.
3. Travis WD, Costabel U, Hansell DM, *et al.* An official American Thoracic Society/European Respiratory Society statement: update of the international multidisciplinary classification of the idiopathic interstitial pneumonias. *Am J Respir Crit Care Med* 2013;**188**(6):733–48. https://doi.org/10.1164/rccm.201308-1483ST.
4. Lynch DA, Sverzellati N, Travis WD, *et al.* Diagnostic criteria for idiopathic pulmonary fibrosis: a fleischner society white paper. *Lancet Respir Med* 2018 Feb;**6**(2):138–53. https://doi.org/10.1016/S2213-2600(17)30433-2.
5. Bryson T, Sundaram B, Khanna D, *et al.* Connective tissue disease-associated interstitial pneumonia and idiopathic interstitial pneumonia: similarity and difference. *Semin Ultrasound CT MR* 2014;**35**(1):29–38. https://doi.org/10.1053/j.sult.2013.10.010.
6. Chung JH, Cox CW, Montner SM, *et al.* CT features of the usual interstitial pneumonia pattern: differentiating connective tissue disease-associated interstitial lung disease from idiopathic fibrosis. *AJR Am J Roentgenol* 2018 Feb;**210**(2):307–13. https://doi.org/10.2214/AJR.17.18384.
7. Kim EA, Lee KS, Johkoh T, *et al.* Interstitial lung diseases associated with collagen vascular diseases: radiologic and histopathologic findings. *RadioGraphics* 2002:S151–65. https://doi.org/10.1148/radiographics.22.suppl_1.g02oc04s151.
8. Ahuja J, Arora D, Kanne JP, *et al.* Imaging of pulmonary manifestations of connective tissue diseases. *Radiol Clin North Am* 2016 Nov;**54**(6):1015–31. https://doi.org/10.1016/j.rcl.2016.05.005.
9. Fischer A, Antoniou KM, Brown KK, *et al.* An official European Respiratory Society/American Thoracic Society research statement: interstitial pneumonia with autoimmune features. *Eur Respir J* 2015 Oct;**46**(4):976–87. https://doi.org/10.1183/13993003.00150-2015.
10. Schurawitzki H, Stiglbauer R, Graninger W, *et al.* Interstitial lung disease in progressive systemic sclerosis: high-resolution CT versus radiography. *Radiology* 1990;**176**:755–9. https://doi.org/10.1148/radiology.176.3.2389033.
11. Picano E, Semelka R, Ravenel J, *et al.* Rheumatological diseases and cancer: the hidden variable of radiation exposure. *Ann Rheum Dis* 2014;**73**:2065–8. https://doi.org/10.1136/annrheumdis-2014-206585.
12. Kubo T, Ohno Y, Seo JB, *et al.* Securing safe and informative thoracic CT examinations—progress of radiation dose reduction techniques. *Eur J Radiol* 2017 Jan;**86**:313–9. https://doi.org/10.1016/j.ejrad.2016.10.012.
13. Kubo T. Vendor free basics of radiation dose reduction techniques for CT. *Eur J Radiol* 2019 Jan;**110**:14–21. https://doi.org/10.1016/j.ejrad.2018.11.002.
14. Singh S, Kalra MK, Ali Khawaja RD, *et al.* Radiation dose optimization and thoracic computed tomography. *Radiol Clin North Am* 2014 Jan;**52**(1):1–15. https://doi.org/10.1016/j.rcl.2013.08.004.
15. Frauenfelder T, Winklehner A, Nguyen TD, *et al.* Screening for interstitial lung disease in systemic sclerosis: performance of high-resolution CT with limited number of slices: a prospective study. *Ann Rheum Dis* 2014 Dec;**73**(12):2069–73. https://doi.org/10.1136/annrheumdis-2014-205637.
16. Xu X, Sui X, Song L, *et al.* Feasibility of low-dose CT with spectral shaping and third-generation iterative reconstruction in evaluating interstitial lung diseases associated with connective tissue disease: an intra-individual comparison study. *Eur Radiol* 2019 Sep;**29**(9):4529–37. https://doi.org/10.1007/s00330-018-5969-y.
17. Pontana F, Billard AS, Duhamel A, *et al.* Effect of iterative reconstruction on the detection of systemic sclerosis-related interstitial lung disease: clinical experience in 55 patients. *Radiology* 2016;**279**:297–305. https://doi.org/10.1148/radiol.2015150849.
18. Devaraj A, Wells AU, Meister MG, *et al.* The effect of diffuse pulmonary fibrosis on the reliability of CT signs of pulmonary hypertension. *Radiology* 2008 Dec;**249**(3):1042–9. https://doi.org/10.1148/radiol.2492080269.
19. Ruano CA, Lucas RN, Leal CI, *et al.* Thoracic manifestations of connective tissue diseases. *Curr Probl Diagn Radiol* 2015 Jan-Feb;**44**(1):47–59. https://doi.org/10.1067/j.cpradiol.2014.07.002.
20. Crestani B. The respiratory system in connective tissue disorders. *Allergy* 2005;**60**(6):715–34. https://doi.org/10.1111/j.1398-9995.2005.00761.x.
21. Morales-Cárdenas A, Pérez-Madrid C, Arias L, *et al.* Pulmonary involvement in systemic sclerosis. *Autoimmun Rev* 2016 Nov;**15**(11):1094–108. https://doi.org/10.1016/j.autrev.2016.07.025.
22. Walsh SL, Sverzellati N, Devaraj A, *et al.* Connective tissue disease related fibrotic lung disease: high resolution computed tomographic and pulmonary function indices as prognostic determinants. *Thorax* 2014 Mar;**69**(3):216–22. https://doi.org/10.1136/thoraxjnl-2013-203843.

23. McLaughlin V. Pulmonary arterial hypertension: the most devastating vascular complication of systemic sclerosis. *Rheumatology (Oxford)* 2009;**48**(Suppl. 3):iii25–31. https://doi.org/10.1093/rheumatology/kep107.
24. Kahan A, Coghlan G, McLaughlin V. Cardiac complications of systemic sclerosis. *Rheumatology (Oxford)* 2009;**48**(Suppl. 3):iii45–8. https://doi.org/10.1093/rheumatology/kep110.
25. Launay D, Sobanski V, Hachulla E, *et al*. Pulmonary hypertension in systemic sclerosis: different phenotypes. *Eur Respir Rev* 2017 Sep;**26**(145):170056. https://doi.org/10.1183/16000617.0056-2017.
26. Hassoun PM. Lung involvement in systemic sclerosis. *Presse Med* 2011 Jan;**40**(1 Pt 2):e3–17. https://doi.org/10.1016/j.lpm.2010.08.006.
27. Ali N, Loughborough WW, Rodrigues JCL, *et al*. Computed tomographic and clinical features of pulmonary veno-occlusive disease: raising the radiologist's awareness. *Clin Radiol* 2019 Sep;**74**(9):655–62. https://doi.org/10.1016/j.crad.2019.04.023.
28. Pandey AK, Wilcox P, O'Brien J, *et al*. Significance of various pulmonary and extrapulmonary abnormalities on HRCT of the chest in scleroderma lung. *Indian J Radiol Imaging* 2013 Oct;**23**(4):304–7. https://doi.org/10.4103/0971-3026.125570.
29. Salaffi F, Carotti M, Di Carlo M, *et al*. High-resolution computed tomography of the lung in patients with rheumatoid arthritis: prevalence of interstitial lung disease involvement and determinants of abnormalities. *Medicine (Baltimore)* 2019 Sep;**98**(38):e17088. https://doi.org/10.1097/MD.0000000000017088.
30. Kim EJ, Elicker BM, Maldonado F, *et al*. Usual interstitial pneumonia in rheumatoid arthritis-associated interstitial lung disease. *Eur Respir J* 2010 Jun;**35**(6):1322–8. https://doi.org/10.1183/09031936.00092309.
31. Park JH, Kim DS, Park IN, *et al*. Prognosis of fibrotic interstitial pneumonia: idiopathic versus collagen vascular disease-related subtypes. *Am J Respir Crit Care Med* 2007 Apr 1;**175**(7):705–11. https://doi.org/10.1164/rccm.200607-912OC.
32. Manjunatha YC, Seith A, Kandpal H, *et al*. Rheumatoid arthritis: spectrum of computed tomographic findings in pulmonary diseases. *Curr Probl Diagn Radiol* 2010 Nov-Dec;**39**(6):235–46. https://doi.org/10.1067/j.cpradiol.2009.06.002.
33. Kallianos KG, Elicker BM, Henry TS. Approach to the patient with connective tissue disease and diffuse lung disease. *Semin Roentgenol* 2019 Jan;**54**(1):21–9. https://doi.org/10.1053/j.ro.2018.12.002.
34. Massey H, Darby M, Edey A. Thoracic complications of rheumatoid disease. *Clin Radiol* 2013;**68**(3):293–301. https://doi.org/10.1016/j.crad.2012.07.007.
35. Douglas WW, Tazelaar HD, Hartman TE, *et al*. Polymyositis-dermatomyositis-associated interstitial lung disease. *Am J Respir Crit Care Med* 2001 Oct 1;**164**(7):1182–5. https://doi.org/10.1164/ajrccm.164.7.2103110.
36. Chartrand S, Swigris JJ, Peykova L, *et al*. A multidisciplinary evaluation helps identify the antisynthetase syndrome in patients presenting as idiopathic interstitial pneumonia. *J Rheumatol* 2016 May;**43**(5):887–92. https://doi.org/10.3899/jrheum.150966.
37. Taouli B, Brauner MW, Mourey I, *et al*. Thin-section chest CT findings of primary Sjögren's syndrome: correlation with pulmonary function. *Eur Radiol* 2002;**12**(6):1504–11. https://doi.org/10.1007/s00330-001-1236-7.
38. Parambil JG, Myers JL, Lindell RM, *et al*. Interstitial lung disease in primary Sjögren syndrome. *Chest* 2006 Nov;**130**(5):1489–95. https://doi.org/10.1378/chest.130.5.1489.
39. Goh YP, Naidoo P, Ngian GS. Imaging of systemic lupus erythematosus. Part I: CNS, cardiovascular, and thoracic manifestations. *Clin Radiol* 2013 Feb;**68**(2):181–91. https://doi.org/10.1016/j.crad.2012.06.110.
40. Gheita TA, Azkalany GS, El-Fishawy HS, *et al*. Shrinking lung syndrome in systemic lupus erythematosus patients; clinical characteristics, disease activity and damage. *Int J Rheum Dis* 2011;**14**(4):361–8. https://doi.org/10.1111/j.1756-185X.2011.01651.x.
41. Assayag D, Kaduri S, Hudson M, *et al*. High resolution computed tomography scoring systems for evaluating interstitial lung disease in systemic sclerosis patients. *Rheumatology* 2012;**3**:S1. https://doi.org/10.4172/2161-1149.S1-003.
42. Warrick JH, Bhalla M, Schabel SI, *et al*. High resolution computed tomography in early scleroderma lung disease. *J Rheumatol* 1991 Oct;**18**(10):1520–8.
43. Wells AU, Hansell DM, Corrin B, *et al*. High resolution computed tomography as a predictor of lung histology in systemic sclerosis. *Thorax* 1992;**47**:738–42. https://doi.org/10.1136/thx.47.9.738.
44. Wells AU, Hansell DM, Rubens MB, *et al*. Fibrosing alveolitis in systemic sclerosis: indices of lung function in relation to extent of disease on computed tomography. *Arthritis Rheum* 1997;**40**:1229–36. https://doi.org/10.1002/1529-0131(199707)40.
45. Goh NSL, Desai SR, Veeraraghavan S, *et al*. Interstitial lung disease in systemic sclerosis: a simple staging system. *Am J Respir Crit Care Med* 2008;**177**:1248–54. https://doi.org/10.1164/rccm.200706-877OC.
46. Walsh SLF, Devaraj A, Enghelmayer JI, *et al*. Role of imaging in progressive-fibrosing interstitial lung diseases. *Eur Respir Rev* 2018 Dec 21;**27**(150):180073. https://doi.org/10.1183/16000617.0073-2018.
47. Weatherley ND, Eaden JA, Stewart NJ, *et al*. Experimental and quantitative imaging techniques in interstitial lung disease. *Thorax* 2019 Jun;**74**(6):611–9. https://doi.org/10.1136/thoraxjnl-2018-211779.
48. Maldonado F, Moua T, Rajagopalan S, *et al*. Automated quantification of radiological patterns predicts survival in idiopathic pulmonary fibrosis. *Eur Respir J* 2014;**43**(1):204–12. https://doi.org/10.1183/09031936.00071812.
49. Park HJ, Lee SM, Song JW, *et al*. Texture-based automated quantitative assessment of regional patterns on initial CT in patients with idiopathic pulmonary fibrosis: relationship to decline in forced vital capacity. *AJR Am J Roentgenol* 2016;**207**(5):976–83. https://doi.org/10.2214/AJR.16.16054.
50. Romei C, Tavanti LM, Taliani A, *et al*. Automated computed tomography analysis in the assessment of idiopathic pulmonary fibrosis severity and progression. *Eur J Radiol* 2020 Jan 28;**108852**:124. https://doi.org/10.1016/j.ejrad.2020.108852.
51. Jacob J, Bartholmai BJ, Rajagopalan S, *et al*. Evaluation of computer-based computer tomography stratification against outcome models in connective tissue disease-related interstitial lung disease: a patient outcome study. *BMC Med* 2016 Nov;**14**(1):190. https://doi.org/10.1186/s12916-016-0739-7.
52. De Giacomi F, Raghunath S, Karwoski R, *et al*. Short-term automated quantification of radiologic changes in the characterization of idiopathic pulmonary fibrosis versus nonspecific interstitial pneumonia and prediction of long-term survival. *J Thorac Imaging* 2018 Mar;**33**(2):124–31. https://doi.org/10.1097/RTI.0000000000000317.
53. Wang Y, Gargani L, Barskova T, *et al*. Usefulness of lung ultrasound B-lines in connective tissue disease-associated interstitial lung disease: a literature review. *Arthritis Res Ther* 2017 Sep 18;**19**(1):206. https://doi.org/10.1186/s13075-017-1409-7.
54. Volpicelli G, Elbarbary M, Blaivas M, *et al*. International evidence-based recommendations for point-of-care lung ultrasound. *Intensive Care Med* 2012 Apr;**38**(4):577–91. https://doi.org/10.1007/s00134-012-2513-4.
55. Cogliati C, Antivalle M, Torzillo D, *et al*. Standard and pocket-size lung ultrasound devices can detect interstitial lung disease in rheumatoid arthritis patients. *Rheumatol* 2014;**53**(8):1497–503. https://doi.org/10.1093/rheumatology/keu033.
56. Tardella M, Di Carlo M, Carotti M, *et al*. Ultrasound B-lines in the evaluation of interstitial lung disease in patients with systemic sclerosis: cut-off point definition for the presence of significant pulmonar fibrosis. *Medicine* 2018;**97**(18):e0566. https://doi.org/10.1097/MD.0000000000010566.
57. Gargani L, Doveri M, D'Errico L, *et al*. Ultrasound lung comets in systemic sclerosis: a chest sonography hallmark of pulmonary interstitial fibrosis. *Rheumatology* 2009;**48**:1382–7. https://doi.org/10.1093/rheumatology/kep263.
58. Gigante A, Rossi Fanelli F, Lucci S, *et al*. Lung ultrasound in systemic sclerosis: correlation with high-resolution computed tomography, pulmonary function tests and clinical variables of disease. *Intern Emerg Med* 2016;**11**:213–7. https://doi.org/10.1007/s11739-015-1329-y.
59. Barskova T, Gargani L, Guiducci S, *et al*. Lung ultrasound for the screening of interstitial lung disease in very early systemic sclerosis. *Ann Rheum Dis* 2013;**72**(3):390–5. https://doi.org/10.1136/annrheumdis-2011-201072.
60. Tardella M, Gutierrez M, Salaffi F, *et al*. Ultrasound in the assessment of pulmonary fibrosis in connective tissue disorders: correlation with

high-resolution computed tomography. *J Rheumatol* 2012;**39**(8):1641–7. https://doi.org/10.3899/jrheum.120104.

61. Gutierrez M, Salaffi F, Carotti M, *et al*. Utility of a simplified ultrasound assessment to assess interstitial pulmonary fibrosis in connective tissue disorders—preliminary results. *Arthritis Res Ther* 2011;**13**(8):R134. https://doi.org/10.1186/ar3446.
62. Aghdashi M, Broofeh B, Mohammadi A. Diagnostic performances of high resolution trans-thoracic lung ultrasonography in pulmonary alveoli-interstitial involvement of rheumatoid lung disease. *Int J Clin Exp Med* 2013;**6**:562–6.
63. Vasco PG, de Luna CG, Garrido IM, *et al*. Assessment of interstitial lung disease in Sjogren's syndrome by lung ultrasound: a pilot study of correlation with high-resolution chest tomography. *Intern Emerg Med* 2017;**12**:327–31. https://doi.org/10.1007/s11739-016-1582-8.
64. Pinal Fernandez I, Pallisa Nunez E, Selva-O'Callaghan A, *et al*. Correlation of ultrasound B-lines with high-resolution computed tomography in antisynthetase syndrome. *Clin Exp Rheumatol* 2014;**32**:404–7.
65. Gutierrez M, Tardella M, Rodriguez L, *et al*. Ultrasound as a potential tool for the assessment of interstitial lung disease in rheumatic patients. Where are we now? *Radiol Med* 2019 Oct;**124**(10):989–99. https://doi.org/10.1007/s11547-019-01053-5.
66. Wild JM, Marshall H, Bock M, *et al*. MRI of the lung (1/3): methods. *Insights Imaging* 2012;**3**:345–53. https://doi.org/10.1007/s13244-012-0176-x.
67. Lutterbey G, Gieseke J, von Falkenhausen M, *et al*. Lung MRI at 3.0 T: a comparison of helical CT and high-field MRI in the detection of diffuse lung disease. *Eur Radiol* 2005;**15**:324–8. https://doi.org/10.1007/s00330-004-2548-1.
68. Rajaram S, Swift AJ, Capener D, *et al*. Lung morphology assessment with balanced steady-state free precession MR imaging compared with CT. *Radiology* 2012;**263**(2):569–77. https://doi.org/10.1148/radiol.12110990.
69. Ohno Y, Koyama H, Yoshikawa T, *et al*. Pulmonary high-resolution ultrashort TE MR imaging: comparison with thin-section standard- and low-dose computed tomography for the assessment of pulmonary parenchyma diseases. *J Magn Reson Imaging* 2016;**43**(2):512–32. https://doi.org/10.1002/jmri.25008.
70. Pinal-Fernandez I, Pineda-Sanchez V, Pallisa-Nuñez E, *et al*. Fast 1.5 T chest MRI for the assessment of interstitial lung disease extent secondary to systemic sclerosis. *Clin Rheumatol* 2016 Sep;**35**(9):2339–45. https://doi.org/10.1007/s10067-016-3267-0.
71. Lonzetti L, Zanon M, Pacini GS, *et al*. Magnetic resonance imaging of interstitial lung diseases: a state-of-the-art review. *Respir Med* 2019 Aug;**155**:79–85. https://doi.org/10.1016/j.rmed.2019.07.006.
72. Romei C, Turturici L, Tavanti L, *et al*. The use of chest magnetic resonance imaging in interstitial lung disease: a systematic review. *Eur Respir Rev* 2018 Dec 19;**27**(150):180062. https://doi.org/10.1183/16000617.0062-2018.
73. Yi CA, Lee KS, Han J, *et al*. 3-T MRI for differentiating inflammation- and fibrosis-predominant lesions of usual and nonspecific interstitial pneumonia: comparison study with pathologic correlation. *AJR Am J Roentgenol* 2008;**190**(4):878–85. https://doi.org/10.2214/AJR.07.2833.
74. Buzan MT, Eichinger M, Kreuter M, *et al*. T2 mapping of CT remodelling patterns in interstitial lung disease. *Eur Radiol* 2015;**25**(11):3167–74. https://doi.org/10.1007/s00330-015-3751-y.
75. Buzan MT, Wetscherek A, Heussel CP, *et al*. Texture analysis using proton density and T2 relaxation in patients with histological usual interstitial pneumonia (UIP) or nonspecific interstitial pneumonia (NSIP). *PLoS ONE* 2017;**12**(5):e0177689. https://doi.org/10.1371/journal.pone.0177689.
76. Marinelli JP, Levin DL, Vassallo R, *et al*. Quantitative assessment of lung stiffness in patients with interstitial lung disease using MR elastography. *J Magn Reson Imaging* 2017 Aug;**46**(2):365–74. https://doi.org/10.1002/jmri.25579.
77. Jacquelin V, Mekinian A, Brillet PY, *et al*. FDG-PET/CT in the prediction of pulmonary function improvement in nonspecific interstitial pneumonia. A Pilot Study. *Eur J Radiol* 2016 Dec;**85**(12):2200–5. https://doi.org/10.1016/j.ejrad.2016.10.001.
78. Uehara T, Takeno M, Hama M, *et al*. Deep-inspiration breath-hold 18F-FDG-PET/CT is useful for assessment of connective tissue disease associated interstitial pneumonia. *Mod Rheumatol* 2016;**26**(1):121–7. https://doi.org/10.3109/14397595.2015.1054099.
79. Huang HJ, Isakow W, Byers DE, *et al*. Imaging pulmonary inducible nitric oxide synthase expression with PET. *J Nucl Med* 2015 Jan;**56**(1):76–81. https://doi.org/10.2967/jnumed.114.146381.
80. Withana NP, Ma X, McGuire HM, *et al*. Non-invasive imaging of idiopathic pulmonary fibrosis using cathepsin protease probes. *Sci Rep* 2016 Jan;**6**:19755. https://doi.org/10.1038/srep19755.
81. Bondue B, Sherer F, Van Simaeys G, *et al*. PET/CT with ^{18}F-FDG- and ^{18}F-FBEM- labeled leukocytes for metabolic activity and leukocyte recruitment monitoring in a mouse model of pulmonary fibrosis. *J Nucl Med* 2015 Jan;**56**(1):127–32. https://doi.org/10.2967/jnumed.114.147421.
82. Desogere P, Tapias LF, Hariri LP, *et al*. Type I collagen-targeted PET probe for pulmonary fibrosis detection and staging in preclinical models. *Sci Transl Med* 2017 Apr;**9**(384):eaaf4696. https://doi.org/10.1126/scitranslmed.aaf4696.
83. Chen DL, Schiebler ML, Goo JM, *et al*. PET imaging approaches for inflammatory lung diseases: current concepts and future directions. *Eur J Radiol* 2017 Jan;**86**:371–6. https://doi.org/10.1016/j.ejrad.2016.09.014.