

Review Article

Indian J Med Res 145, April 2017, pp 425-436
DOI: 10.4103/ijmr.IJMR_1550_15



Genital tuberculosis in females

G. Angeline Grace, D. Bella Devaleenal & Mohan Natrajan

Department of Clinical Research, ICMR-National Institute for Research in Tuberculosis, Chennai, India

Received September 29, 2015

The morbidity and mortality due to tuberculosis (TB) is high worldwide, and the burden of disease among women is significant, especially in developing countries. *Mycobacterium tuberculosis* bacilli reach the genital tract primarily by haematogenous spread and dissemination from foci outside the genitalia with lungs as the common primary focus. Genital TB in females is a chronic disease with low-grade symptoms. The fallopian tubes are affected in almost all cases of genital TB, and along with endometrial involvement, it causes infertility in patients. Many women present with atypical symptoms which mimic other gynaecological conditions. A combination of investigations is needed to establish the diagnosis of female genital TB (FGTB). Multidrug anti-TB treatment is the mainstay of management and surgery may be required in advanced cases. Conception rates are low among infertile women with genital TB even after multidrug therapy for TB, and the risk of complications such as ectopic pregnancy and miscarriage is high. More research is needed on the changing trends in the prevalence and on the appropriate methods for diagnosis of FGTB.

Key words Anti-tuberculosis treatment - conception - fallopian tubes - genital tuberculosis - infertility - laparoscopy

Introduction

Tuberculosis (TB) is a major public health problem worldwide despite a declining trend in mortality, with effective diagnosis and treatment. An estimated 10.4 million people developed TB in 2015 and more than half of the TB cases (60%) were seen in South-East Asia and Western Pacific Regions¹. About 60 per cent of TB cases and deaths occur among males, but the disease burden is high among women also¹. In 2015 nearly 500,000 women died from TB, and among them, 28 per cent had human immunodeficiency virus (HIV) co-infection¹. Genital TB in females is well recognized as an important aetiological factor for infertility in countries with high prevalence of TB. Genital TB usually occurs secondary to TB in other sites

(primarily, the lungs). The spread is generally through haematogenous or lymphatic routes². Tuberculous infection of the female genital organs can result in infertility, dyspareunia, menstrual irregularities and chronic pelvic inflammatory disease (PID)³. Drug therapy for female genital TB (FGTB) is similar to the standard treatment regimens used for pulmonary TB. In patients with infertility, conception rate is not very encouraging after anti-TB treatment (ATT)². Here we review the epidemiology, clinical presentations, recent advances in diagnosis and treatment of FGTB.

Female genital tuberculosis - epidemiology and pathogenesis

Genitourinary TB is a common form of extrapulmonary TB (EPTB) worldwide (27%) with

genital TB alone accounting for 9 per cent of all EPTB cases⁴. However, the burden of genital TB in females is underestimated as most of the patients are asymptomatic and usually diagnosed during evaluation for infertility. A study on FGTB among patients with infertility from India has shown an incidence of 3-16 per cent⁵. Higher rates have been reported from tertiary referral hospitals in India probably due to referrals from different parts of the country for the diagnosis and management of difficult and complicated cases⁶. A study among women with infertility registered for *in vitro* fertilization in north India reported the prevalence of genital TB in patients with tubal factor infertility as 48.5 per cent⁷. A survey by the Indian Council of Medical Research (ICMR) reported that prevalence of FGTB in India has increased from 19 per cent in 2011 to 30 per cent in 2015. A multicentric ICMR study team is working on developing a nationally applicable algorithm for diagnosis and management of FGTB⁸. The existing literature on the prevalence of genital TB among women with infertility and conception rates (spontaneous or assisted) is shown in Table I⁹⁻¹⁵.

Genital TB is mostly secondary to pulmonary TB or extrapulmonary foci such as kidneys, meninges, skeletal system and gastrointestinal system. TB bacilli infect the genital tract by four routes - haematogenous route (with lungs as the common primary focus), descending direct spread, lymphatic spread and rarely as primary infection of the genitalia through sexual transmission⁵. The genital organs affected by *Mycobacterium tuberculosis* (in descending order of frequency) are as follows: fallopian tubes (95-100%),

uterine endometrium (50-60%), ovaries (20-30%), cervix (5-15%), uterine myometrium (2.5%) and vagina/vulva (1%)¹⁶.

The morphology of genital organs infected with TB varies widely. The organs appear normal in the early stages. The ampullary region of the fallopian tubes shows the earliest changes and the fimbrial processes become swollen later. TB endometritis is often focal, and pathological changes such as ulceration, caseous necrosis and haemorrhage are seen in advanced endometrial TB. In later stages, adhesions may occur between ovaries and adjacent pelvic organs resulting in adnexal mass. Intrauterine adhesions if occur can result in partial obliteration of the uterine cavity. Cervix, vulva and vagina are rarely affected^{16,17}.

Clinical presentations of female genital tuberculosis

M. tuberculosis affects the female genital organs, especially the fallopian tubes, and thereby causes infertility. It can occur in any age group, but women in the reproductive age group (15-45 yr) are the most affected¹⁸. In most cases, the disease is asymptomatic or can present with a few symptoms among which infertility is the most common. Other symptoms reported are menstrual irregularities such as oligomenorrhoea, hypomenorrhoea, amenorrhoea, menorrhagia, dysmenorrhoea, metrorrhagia, pelvic pain and abnormal vaginal discharge. In postmenopausal women, genital TB presents with symptoms resembling endometrial malignancy, such as postmenopausal bleeding, persistent leucorrhoea

Table I. Studies on the prevalence of genital tuberculosis among women with infertility reported in the literature

Author (s), country (yr)	Study design	Number of study participants	Prevalence of genital TB (%)	Conception rate (%)
Tripathy and Tripathy, India (2002) ⁹	Prospective study	91	3 (overall) 41 (in cases with tubal factor infertility)	19.2
Jindal, India (2006) ¹⁰	Retrospective record review	150	7.2	13.3
Shaheen <i>et al</i> , Pakistan (2006) ¹¹	Prospective study	534	2.43	23
Singh <i>et al</i> , India (2008) ⁷	Retrospective record review	140	48.5 (in tubal factor infertility)	-
Nadgouda <i>et al</i> , India (2010) ¹²	Prospective study	170	10	11.8
Khanna and Agrawal, India (2011) ¹³	Cross-sectional study	100	26	-
Shahzad, Pakistan (2012) ¹⁴	Cross-sectional study	150	20	-
Abdelrub <i>et al</i> , Yemen (2015) ¹⁵	Prospective study	682	6.9 (overall) 31.1 (in tubal factor infertility)	12.8

Superscript numerals denote reference numbers

and pyometra⁵. Genital TB can mimic or coexist with other gynaecological and abdominal pathologies such as genital carcinomas, acute appendicitis, ovarian cysts, PID, or ectopic pregnancy. Varied clinical presentations of FGTB are shown in Table II¹⁹⁻²⁸.

Diagnosis of female genital tuberculosis

The discovery of tubercle bacilli in 1882 and isolation of the bacilli in samples of urine and sputum in 1883 contributed immensely to the diagnosis and management of TB²⁹. Despite availability of various diagnostic techniques, diagnostic dilemma still exists, especially for genital TB. Hence, FGTB needs a thorough systematic clinical examination with high degree of suspicion and use of intensive investigations³⁰. The possibility of FGTB should be considered in patients with chronic PID not responding to standard antibiotic treatment, unexplained infertility or in women with irregular menstrual cycle or postmenopausal bleeding and persistent vaginal discharge (where genital neoplasias have been excluded)³¹. Risk factors include contact with a smear-positive pulmonary TB patient, past history of TB infection, residence in or recent travel to endemic areas, low socio-economic background, people living with HIV and drug abuse³². There is no single diagnostic test available to confirm the diagnosis of FGTB. High degree of clinical suspicion, elaborate history taking, systemic examination, battery of tests to document *M. tuberculosis* as well as imaging methodologies for characteristic structural changes are essential for the diagnosis³³.

Investigations

As per the WHO definition of EPTB, diagnosis of EPTB should be made on the basis of 'one culture-positive specimen, or positive histology or strong clinical evidence consistent with active EPTB'¹. A general examination to exclude a TB focus elsewhere in the body, X-ray chest, tuberculin skin test (TST), erythrocyte sedimentation rate (ESR) and complete blood count should be done at baseline. It has been reported that 10 to 75 per cent of patients with genital TB may have abnormal X-ray³⁴⁻³⁶. However, a negative chest X-ray does not rule out the possibility of genital TB. TST has limited utility in populations with high TB burden and where Bacille Calmette-Guérin (BCG) vaccination is followed as a routine. False-positive (non-TB mycobacterial, previous vaccination with BCG) and false-negative reactions (patients on steroid therapy, coexisting HIV infection, recent TB infection, chronic renal failure and people with typhoid fever,

typhus, brucellosis, leprosy, pertussis) can also occur with TST. Abdelrub *et al*¹⁵ showed that TST was positive in 42.6 per cent of patients with genital TB. Raut *et al*³⁷ reported sensitivity and specificity of TST as 55 and 80 per cent, respectively, in women with laparoscopically diagnosed TB.

Imaging techniques

The two imaging techniques useful in the diagnosis of FGTB are hysterosalpingography (HSG) and ultrasonography (USG)³⁶. HSG evaluates the internal structure of the female genital tract and tubal patency whereas USG allows simultaneous evaluation of ovarian, uterine and extrapelvic involvement³⁸.

Hysterosalpingography (HSG)

Genital TB is associated with characteristic structural changes in the organs involved, and HSG is a useful tool in visualizing the abnormalities. In HSG, presentation of tubal TB varies from non-specific changes such as tubal dilatation, tubal occlusion, irregular contour, diverticular outpouching (salpingitis isthmica nodosa), hydrosalpinx to specific pattern such as 'cotton wool plug', 'pipestem tube', 'golf club tube', 'cobblestone tube', 'beaded tube', 'leopard skin tube', tubal occlusion and adhesions in the peritubal region which may present as straight spill, corkscrew appearance and peritubal halo³⁹. TB should be strongly suspected in the presence of synechiae, tubal obstruction in the transition zone between the isthmus and ampulla⁴⁰, multiple constrictions, calcified lymph nodes, irregular linear or nodular calcifications in the adnexal area³⁸.

The uterine changes due to TB may be seen as specific features such as 'collar-stud abscess', 'T-shaped' uterus and 'pseudounicornuate' uterus or non-specific features such as synechiae formation, uterine contour distortion, obliteration of the uterine cavity, venous and lymphatic intravasations^{41,42}. Chronic infection may lead to extensive destruction of the endometrium and myometrium resulting in complete narrowing of the uterine cavity called Netter syndrome. It appears in the HSG as a gloved finger consisting of cervical canal and small part of the uterus⁴³. Cervical TB is rare as the stratified epithelium of the ectocervix is naturally resistant to bacterial penetration; hence, cervical TB is mostly secondary to TB of the fallopian tubes and endometrium⁴⁴. Cervical involvement is visualized in HSG as irregularity in contours and diverticular outpouching with a feathery appearance, cervical distortion and serrated

Table II. Varied clinical presentations of genital tuberculosis in females reported in the literature

Author (s), country	Clinical presentation	Symptoms	Salient findings	Learning points
Arakeri and Sinkar, India ¹⁹	A case of secondary vulval TB masquerading as a tumour in a 40 yr old female patient	Vulval growth as multiple nodules (with sinuses), yellowish-white discharge	Past history of incomplete treatment to pulmonary TB. Presented as hypertrophied cauliflower-like mass covering the entire labia. Partial vulvectomy was done; HPE of the excised mass suggested TB. Clinical improvement was seen after ATT.	Detailed history taking, thorough clinical examination, granulomatous changes in histopathology act as reliable tools to detect vulval TB in patients with atypical presentations.
Sachan <i>et al</i> , India ²⁰	Case series: One case of cervical TB and two cases of endometrial TB in women of reproductive age group	Case 1: Cervical TB-polymenorrhagia, post-coital bleeding Cases 2 and 3: Endometrial TB-vaginal discharge, post-coital bleeding, lower abdominal pain	Case 1: Speculum examination showed congested, angry-looking cervix. Cervical carcinoma was strongly suspected. HPE of cervical tissue revealed tubercular cervicitis. Remarkable improvement after 12 months of ATT Cases 2 and 3: Clinical examination raised a strong suspicion of carcinoma. Endometrial tissue sampling was positive for TB PCR. Both cases improved with 6-9 months of ATT. Case 3, a patient diagnosed with secondary infertility conceived after ATT.	In endemic areas, high degree of suspicion for TB is required in endometrial lesions and malignant-appearing lesions of cervix in females of reproductive age group.
Akbulut <i>et al</i> , Turkey ²¹	A case of tubercular tubo-ovarian cystic mass presenting as acute appendicitis in a 17 yr old female	Pain in the right lower quadrant of abdomen, nausea, vomiting	Ultrasound raised suspicion of retrocaecal appendicitis. Per operative finding was a mass arising from the right tubo-ovarian complex. Cystic mass was excised and HPE findings were suggestive of TB. Patient recovered completely with six months of ATT.	In TB-endemic areas among women of reproductive age group, genital TB is an important differential diagnosis of acute appendicitis.
Agrawal <i>et al</i> , India ²²	A case of cervical tuberculosis mimicking carcinoma in a 26 yr old female	Abdominal pain, vaginal discharge, post-coital bleeding, intermenstrual bleeding, loss of weight	Irregular friable cervical growth on speculum examination. Cervical smear was positive for AFB. Biopsy of cervical mass showed granulomatous inflammation and caseous necrosis on HPE. After six months of ATT, patient was totally symptom free and cervix was almost normal.	Tuberculosis is an important differential diagnosis of abnormal cervical lesions.

Contd...

Author (s), country	Clinical presentation	Symptoms	Salient findings	Learning points
Lobo and Wong, India ²³	Coexistence of tuberculosis and benign ovarian serous cystadenoma in a 29 yr old woman	Lower abdominal pain, abdominal distension, pallor, weight loss	Examination showed a cystic, non-tender, mobile pelvic mass. Ultrasound suggested left ovarian cystic neoplasm. Exploratory laparotomy was done. Due to strong suspicion of ovarian carcinoma, total abdominal hysterectomy and bilateral oophorectomy were performed. HPE of the cystic portion of the left ovary confirmed the diagnosis of benign serous cystadenoma. Ziehl-Neelsen stain of the ovary was positive for AFB. Diagnosed with genital TB, patient was started on ATT.	Synchronous occurrence of ovarian cystic neoplasms and genital TB pose a greater diagnostic challenge. Histopathological findings help in definitive diagnosis when clinical, radiographic and laboratory data are inconclusive.
Kokkayil <i>et al</i> , India ²⁴	Coexistence of <i>Mycobacterium tuberculosis</i> , <i>Mycoplasma genitalium</i> and <i>Chlamydia trachomatis</i> in a 34 yr old infertile woman	Inability to conceive after eight years of marriage	HSG showed left fallopian tube block with peritubal adhesions. Endometrial aspirate was positive for <i>M. tuberculosis</i> DNA by PCR. Endocervical swabs tested positive for <i>M. genitalium</i> and <i>Chlamydia trachomatis</i> . Patient was treated with ATT and single dose (1 g) of azithromycin. The follow up samples after treatment were negative.	In cases of infertility, chances of mixed infections exist which is quite often ignored. Treating physicians should screen patients with infertility for coexisting infections to give appropriate therapy and prevent further complications.
Neonakis <i>et al</i> , Greece ²⁵	A case of genital TB in a 61 yr old woman treated for breast cancer	Weight loss, lower abdominal pain, bloody vaginal discharge, leucorrhoea	Past history of lumpectomy for ductal carcinoma of breast and adjuvant radiotherapy and chemotherapy; HPE of endometrial sample suggested granulomatous disease and culture confirmed the diagnosis of FG TB. Patient was treated with daily regimen of isoniazid, rifampicin and ethambutol for nine months, and she showed marked improvement.	FGTB is an important differential diagnosis of vaginal bleeding in postmenopausal females.
Gascón and Ación, Spain ²⁶	Bilateral tubercular pyosalpinx in a 18 yr old female with pelvic kidney and septate uterus (genitourinary malformation)	Hypogastric discomfort, pelvic inflammatory disease, recurrent urinary tract infections	USG and tumour markers suggested ovarian malignancy. Laparotomy revealed large pelvic abscesses and bilateral pyosalpinx. HPE and culture confirmed tuberculous infection. Patient improved after six months of ATT.	This report highlights the necessity of suspecting genital TB, particularly in cases of large pyosalpinges.

Contd...

Author (s), country	Clinical presentation	Symptoms	Salient findings	Learning points
Güngördük <i>et al</i> , Turkey ²⁷	A case of postmenopausal TB	Irregular vaginal bleeding	USG showed heterogeneous endometrium with irregular surface. HPE of the endometrial curetting showed epithelioid granulomas with Langhans giant cells. Endometrial tissue was positive for TB PCR. Patient responded well to six months of ATT.	Genital TB is a rare cause of postmenopausal bleeding. Though uncommon, clinician needs to consider FG/TB during the diagnostic workup for postmenopausal bleeding, especially in areas with high TB prevalence.
Shirazi <i>et al</i> , Iran ²⁸	Tuberculous endometritis in a young woman initially diagnosed as uterine leiomyoma	Abdominal pain, pelvic mass, weight loss	Laparotomy revealed severe adhesions among bowel loops, omentum, uterus and fallopian tubes. HPE and culture confirmed tuberculous endometritis. Patient responded to nine-month course of ATT.	In women with pelvic masses and constitutional symptoms, clinicians should consider the diagnosis of genital tuberculosis.

TB, tuberculosis; ATT, anti-tuberculosis treatment; USG, ultrasonography; FG/TB, Female genital tuberculosis; PCR, polymerase chain reaction; HPE, histopathologic examination; AFB, acid-fast bacilli; HSG, hysterosalpingography

endocervical canal^{41,44}. As TB of the cervix will most frequently be misdiagnosed as cervical cancer, the need for ruling out the later immediately is critical in the management⁴⁵.

Ultrasonogram

The fallopian tubes may appear dilated, thickened and may be filled with clear fluid called hydrosalpinx or thick caseous material called pyosalpinx³⁸. The endometrium is affected in 60-90 per cent of cases with genital TB, and the uterine enlargement may be due to filling by caseous material⁴⁶. The endometrium may appear heterogeneous with hyperechoic areas representing foci of calcification or fibrosis, intrauterine adhesions and a distorted uterine cavity³⁸. Findings may vary from a normal scan to abnormalities such as thin or thickened endometrium, cornual obliteration, alteration in the endometrial vascularity during midcycle in stimulated menstrual cycles, calcification of the sub endometrium, variation in the uterine artery flow during midcycle, tubal fluid, free and loculated peritoneal fluid, heterogeneous enlargement of ovaries and adnexal fixation. Some findings with greater specificity are oligemic myometrial cysts, follicles with echogenic rims and presence of endometrial fluid along with a hydrosalpinx⁴⁷. Computed tomography and magnetic resonance imaging are employed in FG/TB in the presence of an abdominal or pelvic mass⁴⁸.

Laparoscopy

Although laparoscopy is an invasive procedure, it aids in visual inspection of the ovaries, fallopian tubes, peritoneal cavity and biopsy of the tuberculous lesions. The advantages of combining hysteroscopy with laparoscopy include not only the exclusion of endometrial involvement but also to do interventions such as lysis of synechiae or endometrial priming with oestrogen⁴⁹. The laparoscopic findings suggestive of genital TB may vary from normal appearance to tubercles on the surface, fimbrial block, fimbrial phimosis, tubal beading, peritubal adhesions, periovarian adhesions, tubo-ovarian mass, hydrosalpinx and rigid tubes^{50,51}. Baxi *et al*⁵¹ showed that the sensitivity, specificity and negative predictive value of endoscopic evaluations were 85.7, 22.2 and 77 per cent, respectively, when compared with polymerase chain reaction (PCR).

Histopathological examination (HPE)

HPE of the specimens shows typical features of TB infection in the form of granulomatous caseous

lesions. The demonstration of typical caseous granulomas with giant epithelioid cells is suggestive of TB; however, these lesions also appear in fungal infections, syphilis, leprosy, rheumatoid arthritis, systemic lupus erythematosus, pneumoconiosis and sarcoidosis⁵¹. Mondal⁵² reported histopathological findings from 110 FG TB patients which included isolated small-to-medium epithelioid cell granulomas in different stages, caseation and rare detection of acid-fast bacilli (AFB). Features of chronic salpingitis include occasional non-caseating granulomas in the early stage and single and/or multiple confluent epithelioid granulomas in the lamina propria in the later stage⁵². Caseation and AFB may be observed in the tissue sections of Fallopian tubes. In ovarian TB, caseation is rare and granulomas are usually observed in the cortical area of the ovaries⁵³. Epithelioid granulomas may be present in cervical TB and caseation, and AFB is a rare entity in vaginal and vulval TB⁵². As TB of the cervix is frequently misdiagnosed as carcinoma, it is critical to differentiate both at the earliest⁴⁵. For maximizing the yield in HPE, specimens should be collected from multiple sites as the infecting organisms are scarce in genital TB^{54,55}, sampling site may not be the infected site and cyclical shedding leads to inadequate granuloma formation in endometrium. Ideal time for endometrial sampling is the late secretory phase of the menstrual cycle¹⁶ which is favourable to identify the classic giant cells and tubercles.

Bacteriological evaluation

Acid-fast bacilli (AFB) staining and culture

Definitive diagnosis of TB requires the isolation of TB bacilli. Conventional methods for diagnosis of TB include microscopy and culture. Microscopy for AFB is a rapid test for diagnosis but with variable sensitivity⁵⁶. Acid-fast [Ziehl–Neelsen (ZN), Kinyon] staining or fluorescent (auramine, rhodamine) staining is generally used. For ZN staining to yield a positive result, a sample should contain 10⁴–10⁶ bacilli/ml. Culture for *Mycobacterium* is more sensitive and requires 10–100 bacilli/ml of tissue/fluid sample for the diagnostic yield¹⁶. Though bacteriologic examination of menstrual blood for smear and culture is recommended by some experts, the sensitivity of these tests is quite low³⁶. For diagnostic tests on menstrual blood, menstrual fluid can be collected from the vagina on the first day of menstruation⁵⁷. An acid-fast staining of the endometrial curetting is a rapid test and requires 10 organisms per ml for a positive result³⁶.

Culture methods

The diagnosis of TB is confirmed based on the identification of *M. tuberculosis* in culture. Solid cultures are usually performed on the egg-based Lowenstein–Jensen (LJ) medium or agar-based Middlebrook 7H10 medium, and the liquid culture is performed using automated BACTEC Mycobacterial Growth Indicator Tube 960 (MGIT 960) based on modified Middlebrook 7H9 Broth with an oxygen-sensitive fluorescent detection technology⁵⁸. The advantages of liquid culture include its sensitivity, identification of *Mycobacterium* species and ability to perform phenotypic drug susceptibility tests (DSTs) and genotyping for further molecular epidemiology studies. The disadvantage of culture methods is the time needed for the growth of mycobacteria. Liquid cultures require at least 9–10 days for positive results and six weeks for being considered negative and in LJ medium cultures, the minimum time-to-positivity is 4–8 weeks⁵⁴. Thangappah *et al*⁵⁵ showed that, among the 72 infertile women studied, AFB smear positivity and culture positivity were 8.3 and 5.2 per cent, respectively, when endometrial samples were tested. Goel *et al*⁵⁹ showed that the positivity in LJ medium and BACTEC for premenstrual samples were 1.83 and 8.8 per cent, respectively.

Molecular methods

Molecular techniques for the detection of TB are increasingly evaluated and used nowadays. The nucleic-acid amplification tests (NAAT) provide results in a few hours. PCR is a rapid molecular method for identification of nucleic acid sequences specific to *M. tuberculosis* and other mycobacteria in tissue samples of patients with FG TB. PCR assays can detect <10 bacilli/ml including dead bacilli and has a testing time of 8–12 h⁶⁰. Sensitivity of PCR is higher than culture and histopathology and specificity may be as high as 100 per cent in detecting FG TB^{30,61–63}. Recognition of genes encoding the virulence determinants, targets in genome and expressing factors are currently important biomarkers for the detection of FG TB⁶⁴. Clinicians should not initiate ATT for patients only on the basis of positive PCR due to high false positivity and should correlate with clinical evidence and laparoscopic findings⁶⁵.

Serology

The WHO has banned the usage of serological tests in individuals suspected of any form of active TB, regardless of their HIV status⁶⁶. A retrospective study

by Goel *et al*⁵⁹ compared different methods *i.e.*, HPE, smear microscopy, LJ culture, BACTEC culture and PCR-DNA for diagnosing endometrial TB in females with infertility. The study concluded that none of the available tests were sensitive enough to diagnose all cases of genital TB, but conventional methods such as HPE and LJ culture still have an important role in the diagnosis of endometrial TB in resource-limited settings. PCR has higher specificity and sensitivity, faster turnaround time but limited by high false-positive rates. Recently, GeneXpert MTB/RIF assay has been endorsed by the WHO for worldwide application that permits the simultaneous detection of *M. tuberculosis* and resistance to rifampicin. GeneXpert is a useful diagnostic test for all forms of EPTB and provides results in less than two hours⁶⁷. Further research is needed in identifying the role of Xpert in the diagnosis of FGTB.

Currently, there are no standard guidelines or algorithm for the diagnosis of FGTB, and extensive research is needed for early diagnosis and appropriate interventions. We suggest an algorithm which can aid the clinicians in the diagnosis of FGTB (Figure).

Differential diagnosis

Differential diagnosis of FGTB varies based on the site of involvement. Tripathy and Sapkal⁶⁸ have

elaborated a variety of conditions based on the site involved (Table III).

Treatment

Treatment of FGTB is similar to pulmonary TB. The regimen recommendation for many forms of EPTB is mostly not based on evidence from vigorous studies as those for PTB and the duration of treatment for six months though debatable is considered adequate⁶⁹. In patients with organisms sensitive to first-line drugs, six-month regimen is highly effective⁶⁹. The WHO treatment guidelines for TB (2010)⁷⁰ recommend that patients newly diagnosed with TB should receive a regimen containing rifampicin (R) for six months: intensive phase with isoniazid (H), R, ethambutol (E) and pyrazinamide (Z) for a duration of two months followed by continuation phase with HR for four months. Alternative to the daily regimen is that TB patients may receive a daily intensive phase followed by thrice weekly continuation phase [2HRZE/4(HR)₃] or thrice weekly dosing throughout therapy [2(HRZE)₃/4(HR)₃] provided that each dose is directly observed. Retreatment TB patients who default or relapse from their first treatment course may receive 2HRZES/1HRZE/5HRE. According to Standards for TB Care Guidelines for new TB patients, the initial

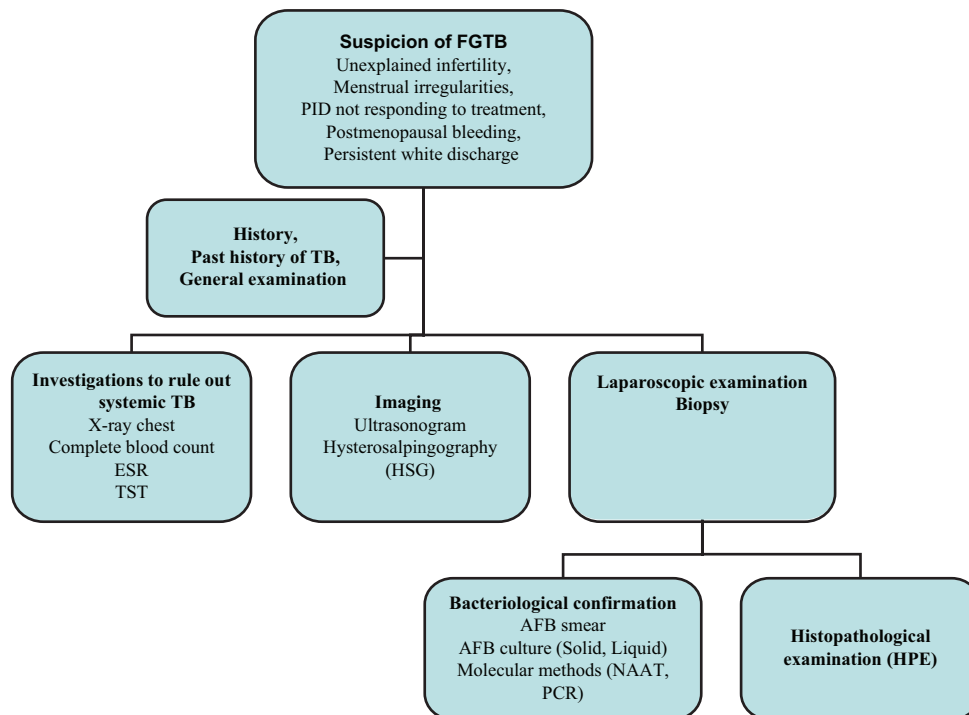


Figure. Diagnostic algorithm for female genital tuberculosis (FGTB). PID, pelvic inflammatory disease; ESR, erythrocyte sedimentation rate; TST, tuberculin skin test; AFB, acid-fast bacilli; NAAT, nucleic acid amplification test; PCR, polymerase chain reaction.

Table III. Differential diagnosis of female genital tuberculosis

Site of involvement	Differential diagnosis
Tuberculous salpingitis	Pelvic inflammatory disease
	Ectopic pregnancy
	Ovarian cyst
	Endometriosis
	Carcinoma of the colon
	Diverticulitis
Endometrial tuberculosis	Dysfunctional uterine bleeding
	Endometrial carcinoma
Ovarian tuberculosis	Ovarian malignancy
Cervical tuberculosis	Carcinoma of the cervix
Vulval tuberculosis	Elephantiasis vulva

Source: Ref 68

phase should consist of two months of HREZ followed by HR for four months⁷¹. Studies have reported the usage of ATT for duration of six months consisting of H, R, E, Z for two months, followed by H and R for the subsequent four months for the management of patients with genital TB^{15,72}. There is very limited literature available regarding randomized clinical trials which have investigated the optimal drugs and the duration of treatment for genital TB⁷³.

Patients should be monitored for adverse drug reactions during the course of treatment. Since all the four drugs can cause hepatitis, monitoring of liver function is absolutely necessary⁷⁰. Good adherence to first-line drugs is essential as irregular drug intake can lead to the development of treatment failure, development of multidrug resistant TB as well as TB recurrence and subsequent complications. The bacteriological confirmation of response to treatment is often not possible due to the difficulty in obtaining follow up samples and lack of follow up guidelines for these patients.

Treatment outcomes in women with genital tuberculosis

Laparoscopic findings such as tubercles, caseous tubercles and encysted ascites may disappear after ATT; however, severe findings such as adhesions may persist⁷⁴. Post-ATT hysteroscopy findings show significant differences in Grade I adhesions and Grade II-IIa adhesions⁷⁵. The spontaneous conception rate may vary from 31 to 59 per cent among patients treated with ATT for FGTB with better rates in patients diagnosed and treated earlier. The outcomes of pregnancy may be live birth, spontaneous abortion or ectopic pregnancy^{72,76}.

If the patient fails to conceive spontaneously, assisted reproduction techniques can be considered to increase the conception rate. In a prospective study done in India among patients treated for infertility due to genital TB, the conception rate was reported as 19.2 per cent, with a much lower live birth rate (7.2%)⁹. In a study by Jindall *et al*⁷⁷ among PCR-positive and PCR-negative FGTB patients with infertility, treatment with ATT and additional assisted reproduction techniques showed an overall pregnancy rate of 60 per cent.

Surgery was the treatment of choice before the chemotherapeutic era; however, its role is minimal now except in patients with recurrent pelvic pain, persistent pelvic mass or TB sinus and excessive bleeding⁷⁸. There may be a role for limited surgical procedures such as drainage from tubo-ovarian abscesses or pyosalpinx followed by ATT for improved treatment outcomes⁷⁹. Sharma *et al*⁸⁰ have reported complications during laparoscopic procedure among patients with genital TB which include an inability to create pneumoperitoneum, inability to visualize the pelvis, excessive bleeding, injury to the bladder and peritonitis. The surgical procedure of choice is total hysterectomy with bilateral salpingo-oophorectomy with proper chemotherapy coverage⁸¹. Vaginal hysterectomy in patients with FGTB may be associated with complications such as increased bleeding, peritonitis, bowel injury and flare up in the post-operative period⁸².

Prevention

Primary prevention of TB includes strategies to minimize the risk of exposure to mycobacteria. It is, therefore, essential to educate patients of pulmonary TB to follow respiratory hygiene at home and in public places and adhere to standard treatment. Specific to genital TB, adopting safe sexual practices may decrease the chances of acquiring genital infection. In countries with high TB burden like India, BCG immunization is used as a preventive strategy. The BCG vaccine is up to 80 per cent effective in preventing the development of severe forms of TB, but its protective effect varies widely in the population⁸³.

Conclusions

Genital TB is a major cause of infertility in women, and prevalence is generally underestimated because of the asymptomatic nature of the infection and diagnostic challenges. Large multicentric studies are needed to estimate the magnitude of FGTB and to identify the most sensitive test for diagnosis. Clinicians

need to be aware of this important cause of infertility and menstrual dysfunction in women. Screening for genital TB needs to be a part of evaluation of infertility and menstrual abnormalities. Most of the patients present in advanced stage with scarring, severe fibrosis and adhesions and treatment outcomes, especially with regard to infertility, are poor. Hence, early diagnosis and correct treatment is vital to avoid complications and to restore fertility.

Conflicts of Interest: None.

References

- WHO. WHO global tuberculosis report 2016. Available from: http://www.who.int/tb/publications/global_report/en/, accessed on April 27, 2017.
- Aliyu MH, Aliyu SH, Salihu HM. Female genital tuberculosis: A global review. *Int J Fertil Womens Med* 2004; 49 : 123-36.
- Namavar Jahromi B, Parsanezhad ME, Ghane-Shirazi R. Female genital tuberculosis and infertility. *Int J Gynaecol Obstet* 2001; 75 : 269-72.
- Golden MP, Vikram HR. Extrapulmonary tuberculosis: An overview. *Am Fam Physician* 2005; 72 : 1761-8.
- Sharma JB. Current diagnosis and management of female genital tuberculosis. *J Obstet Gynaecol India* 2015; 65 : 362-71.
- Gupta N, Sharma JB, Mittal S, Singh N, Misra R, Kukreja M. Genital tuberculosis in Indian infertility patients. *Int J Gynaecol Obstet* 2007; 97 : 135-8.
- Singh N, Sumana G, Mittal S. Genital tuberculosis: A leading cause for infertility in women seeking assisted conception in North India. *Arch Gynecol Obstet* 2008; 278 : 325-7.
- Indian Scientists Developing Diagnostic Algorithm for Female Genital TB. Hans India. Available from: <http://www.thehansindia.com/posts/index/2014-09-21/Indian-scientists-developing-diagnostic-algorithm-for-female-genital-TB-108475>, accessed on March 18, 2016.
- Tripathy SN, Tripathy SN. Infertility and pregnancy outcome in female genital tuberculosis. *Int J Gynaecol Obstet* 2002; 76 : 159-63.
- Jindal UN. An algorithmic approach to female genital tuberculosis causing infertility. *Int J Tuberc Lung Dis* 2006; 10 : 1045-50.
- Shaheen R, Subhan F, Tahir F. Epidemiology of genital tuberculosis in infertile population. *J Pak Med Assoc* 2006; 56 : 306-9.
- Nadgouda SS, Mukhopadhyaya PN, Acharya A, Nagee A, Kunjadia PD. A study on genital tuberculosis and infertility in Indian population. *Clin Pract* 2010; 2 : 1.
- Khanna A, Agrawal A. Markers of genital tuberculosis in infertility. *Singapore Med J* 2011; 52 : 864-7.
- Shahzad S. Investigation of the prevalence of female genital tract tuberculosis and its relation to female infertility: An observational analytical study. *Iran J Reprod Med* 2012; 10 : 581-8.
- Abdelrub AS, Al Harazi AH, Al-Eryani AA. Genital tuberculosis is common among females with tubal factor infertility: Observational study. *Alex J Med* 2015; 51 : 321-4.
- Das P, Ahuja A, Gupta SD. Incidence, etiopathogenesis and pathological aspects of genitourinary tuberculosis in India: A journey revisited. *Indian J Urol* 2008; 24 : 356-61.
- Rajamaheswari N. Pelvic tuberculosis. *Int J Microbiol* 2008; 27 : 361-3.
- Qureshi RN, Samad S, Hamid R, Lakha SF. Female genital tuberculosis revisited. *J Pak Med Assoc* 2001; 51 : 16-8.
- Arakeri SU, Sinkar P. An unusual gross appearance of vulval tuberculosis masquerading as tumor. *Case Rep Obstet Gynecol* 2014; 2014 : 815401.
- Sachan R, Patel ML, Gupta P, Verma AK. Genital tuberculosis with variable presentation: A series of three cases. *BMJ Case Rep* 2012; 2012. pii: Bcr2012006665.
- Akbulut S, Arikanoglu Z, Basbug M. Tubercular tubo-ovarian cystic mass mimicking acute appendicitis: A case report. *J Med Case Rep* 2011; 5 : 363.
- Agrawal S, Madan M, Leekha N, Raghunandan C. A rare case of cervical tuberculosis simulating carcinoma cervix: A case report. *Cases J* 2009; 2 : 161.
- Lobo FD, Wong MY. Coexistence of benign ovarian serous cystadenoma and tuberculosis in a young woman. *Singapore Med J* 2013; 54 : e154-7.
- Kokkayil P, Rawre J, Malhotra N, Dhawan B. Co-infection of *Mycoplasma genitalium* and *Chlamydia trachomatis* in an infertile female patient with genital tuberculosis. *Indian J Pathol Microbiol* 2013; 56 : 457-9.
- Neonakis I, Mantadakis E, Gitti Z, Mitrouska I, Manidakis LG, Maraki S, et al. Genital tuberculosis in a tamoxifen-treated postmenopausal woman with breast cancer and bloody vaginal discharge. *Ann Clin Microbiol Antimicrob* 2006; 5 : 20.
- Gascón J, Ación P. Large bilateral tubercular pyosalpinx in a young woman with genitourinary malformation: A case report. *J Med Case Rep* 2014; 8 : 176.
- Güngördük K, Ulker V, Sahbaz A, Ark C, Tekirdag AI. Postmenopausal tuberculosis endometritis. *Infect Dis Obstet Gynecol* 2007; 2007 : 27028.
- Shirazi M, Shahbazi F, Pirzadeh L, Mohammadi SR, Ghaffari P, Eftekhari T. Tuberculosis endometritis presenting as a leiomyoma. *Int J Fertil Steril* 2015; 8 : 481-4.
- Zajackowski T. Genitourinary tuberculosis: Historical and basic science review: Past and present. *Cent European J Urol* 2012; 65 : 182-7.
- Bhanothu V, Theophilus JP, Rozati R. Use of endo-ovarian tissue biopsy and pelvic aspirated fluid for the diagnosis of female genital tuberculosis by conventional versus molecular methods. *PLoS One* 2014; 9 : e98005.
- Varma TR. Tuberculosis of the female genital tract. *Glob Libr Women's Med* 2008. Available from: http://www.glowm.com/section_view/heading/Tuberculosis%20of%20the%20

- Female%20Genital%20Tract/item/34*, accessed on March 18, 2016.
32. Chowdhury NN. Overview of tuberculosis of the female genital tract. *J Indian Med Assoc* 1996; *94* : 345-6, 361.
 33. Bose M. Female genital tract tuberculosis: How long will it elude diagnosis? *Indian J Med Res* 2011; *134* : 13-4.
 34. Hoppe LE, Kettle R, Eisenhut M, Abubakar I; Guideline Development Group. Tuberculosis—diagnosis, management, prevention, and control: Summary of updated NICE guidance *BMJ* 2016; *352* : h6747.
 35. Diagnostic Standards and Classification of Tuberculosis in Adults and Children. This official statement of the American Thoracic Society and the Centers for Disease Control and Prevention was adopted by the ATS Board of Directors, July 1999. This statement was endorsed by the Council of the Infectious Disease Society of America, September 1999. *Am J Respir Crit Care Med* 2000; *161* (4 Pt 1) : 1376-95.
 36. Sengupta VB. *Gynaecology for postgraduate and practitioners*. India: Elsevier; 2007.
 37. Raut VS, Mahashur AA, Sheth SS. The Mantoux test in the diagnosis of genital tuberculosis in women. *Int J Gynaecol Obstet* 2001; *72* : 165-9.
 38. Shah HU, Sannanjanja B, Baheti AD, Udare AS, Badhe PV. Hysterosalpingography and ultrasonography findings of female genital tuberculosis. *Diagn Interv Radiol* 2015; *21* : 10-5.
 39. Ahmadi F, Zafarani F, Shahrzad G. Hysterosalpingographic appearances of female genital tract tuberculosis: Part I. Fallopian tube. *Int J Fertil Steril* 2014; *7* : 245-52.
 40. Khalaf Y. ABC of subfertility. Tubal subfertility. *BMJ* 2003; *327* : 610-3.
 41. Ahmadi F, Zafarani F, Shahrzad GS. Hysterosalpingographic appearances of female genital tract tuberculosis: Part II: Uterus. *Int J Fertil Steril* 2014; *8* : 13-20.
 42. Merchant SA, Bharati AH, Badhe PB. Female genital tract tuberculosis: A review of hysterosalpingographic appearances part 2-the uterus. *J Womens Imaging* 2004; *6* : 153.
 43. Netter A, Musset R, Lambert A, Salomon Y, Montbazet G. Tuberculous endo-uterine symphysis; an anatomo-clinical and radiologically characteristic syndrome. *Gynecol Obstet (Paris)* 1955; *54* : 19-36.
 44. Farrokh D, Layegh P, Afzalaghaee M, Mohammadi M, Fallah Rastegar Y. Hysterosalpingographic findings in women with genital tuberculosis. *Iran J Reprod Med* 2015; *13* : 297-304.
 45. Danforth WC. Tuberculosis of the cervix. *Ann Surg* 1937; *106* : 407-12.
 46. World Health Organization. *Manual of diagnostic ultrasound*. Geneva: WHO; 2013.
 47. Khurana A, Sahi G. OC14. 04: Ultrasound in female genital tuberculosis: A retrospective series. *Ultrasound Obstet Gynecol* 2013; *42* : 28.
 48. Gatongi DK, Gitau G, Kay V, Ngwenya S, Lafong C, Hasan A. Female genital tuberculosis. *Obstet Gynaecol* 2005; *7* : 75-9.
 49. Schaaf HS, Zumla A. *Tuberculosis: A comprehensive clinical reference*. St Louis (MO): Elsevier Health Sciences; 2009.
 50. Sharma JB, Roy KK, Pushparaj M, Kumar S, Malhotra N, Mittal S. Laparoscopic findings in female genital tuberculosis. *Arch Gynecol Obstet* 2008; *278* : 359-64.
 51. Baxi A, Neema H, Kaushal M, Sahu P, Baxi D. Genital tuberculosis in infertile women: Assessment of endometrial TB PCR results with laparoscopic and hysteroscopic features. *J Obstet Gynecol India* 2011; *61* : 301-6.
 52. Mondal SK. Histopathologic analysis of female genital tuberculosis: A fifteen-year retrospective study of 110 cases in Eastern India. *Turk J Pathol* 2013; *29* : 41-5.
 53. Altchek A, Deligdisch L, Kase N. *Diagnosis and management of ovarian disorders*. San Diego (CA): Academic Press; 2003.
 54. Norbis L, Alagna R, Tortoli E, Codecasa LR, Migliori GB, Cirillo DM. Challenges and perspectives in the diagnosis of extrapulmonary tuberculosis. *Expert Rev Anti Infect Ther* 2014; *12* : 633-47.
 55. Thangappah RBP, Paramasivan CN, Narayanan S. Evaluating PCR, culture & histopathology in the diagnosis of female genital tuberculosis. *Indian J Med Res* 2011; *134* : 40-6.
 56. Kashyap B, Srivastava N, R Kaur I, Jhamb R, K Singh D. Diagnostic dilemma in female genital tuberculosis- staining techniques revisited. *Iran J Reprod Med* 2013; *11* : 545-50.
 57. Simon HB, Weinstein AJ, Pasternak MS, Swartz MN, Kunz LJ. Genitourinary tuberculosis. Clinical features in a general hospital population. *Am J Med* 1977; *63* : 410-20.
 58. Tortoli E, Cichero P, Piersimoni C, Simonetti MT, Gesu G, Nista D. Use of BACTEC MGIT 960 for recovery of mycobacteria from clinical specimens: Multicenter study. *J Clin Microbiol* 1999; *37* : 3578-82.
 59. Goel G, Khatuja R, Radhakrishnan G, Agarwal R, Agarwal S, Kaur I. Role of newer methods of diagnosing genital tuberculosis in infertile women. *Indian J Pathol Microbiol* 2013; *56* : 155-7.
 60. Arora S, Merchant R, Allahbadia GN. *Reproductive medicine: Challenges, solutions and breakthroughs*. New Delhi: JP Medical Ltd.; 2014.
 61. Bhanu NV, Singh UB, Chakraborty M, Suresh N, Arora J, Rana T, *et al*. Improved diagnostic value of PCR in the diagnosis of female genital tuberculosis leading to infertility. *J Med Microbiol* 2005; *54* (Pt 10) : 927-31.
 62. Shrivastava G, Bajpai T, Bhatambare GS, Patel KB. Genital tuberculosis: Comparative study of the diagnostic modalities. *J Hum Reprod Sci* 2014; *7* : 30-3.
 63. Rana T, Singh UB, Kulshrestha V, Kaushik A, Porwal C, Agarwal N, *et al*. Utility of reverse transcriptase PCR and DNA-PCR in the diagnosis of female genital tuberculosis. *J Med Microbiol* 2011; *60* (Pt 4) : 486-91.
 64. Bhanothu V, Theophilus J, Lakshmi V, Rozati R, Aiman AV, Rosaline M, *et al*. Detection of female genital tuberculosis

- by using endo-ovarian tissue biopsy. *Octa J Biosci* 2013; *1* : 98-107.
65. Arora R, Sharma JB. Female genital tuberculosis – A diagnostic and therapeutic challenge. *Indian J Tuberc* 2014; *61* : 98-102.
 66. Steingart KR, Ramsay A, Dowdy DW, Pai M. Serological tests for the diagnosis of active tuberculosis: Relevance for India. *Indian J Med Res* 2012; *135* : 695-702.
 67. Raj A, Singh N, Mehta PK. Gene Xpert MTB/RIF assay: A new hope for extrapulmonary tuberculosis. *IOSR J Pharm* 2012; *2* : 83-9.
 68. Tripathy SN, Sapkal R. *Tuberculosis manual for obstetricians & gynecologists*. New Delhi: Jaypee Brothers Medical Publisher (P) Ltd.; 2015.
 69. Lee JY. Diagnosis and treatment of extrapulmonary tuberculosis. *Tuberc Respir Dis (Seoul)* 2015; *78* : 47-55.
 70. WHO. *Guidelines for treatment of tuberculosis*. Geneva: WHO; 2010.
 71. *Standards for TB Care in India*: Ministry of Health and Family Welfare. Available from: <http://www.tbcindia.nic.in/showfile.php?lid=3061>, accessed on March 23, 2016.
 72. Kulshrestha V, Kriplani A, Agarwal N, Singh UB, Rana T. Genital tuberculosis among infertile women and fertility outcome after antitubercular therapy. *Int J Gynaecol Obstet* 2011; *113* : 229-34.
 73. Abbara A, Davidson RN; Medscape. Etiology and management of genitourinary tuberculosis. *Nat Rev Urol* 2011; *8* : 678-88.
 74. Sharma JB, Sneha J, Singh UB, Kumar S, Roy KK, Singh N, *et al*. Comparative study of laparoscopic abdominopelvic and fallopian tube findings before and after antitubercular therapy in female genital tuberculosis with infertility. *J Minim Invasive Gynecol* 2016; *23* : 215-22.
 75. Bahadur A, Malhotra N, Mittal S, Singh N, Gurunath S. Second-look hysteroscopy after antitubercular treatment in infertile women with genital tuberculosis undergoing *in vitro* fertilization. *Int J Gynaecol Obstet* 2010; *108* : 128-31.
 76. Naredi N, Talwar P, Narayan N, Rai S, Vardhan S, Panda S. Spontaneous conception following anti-tubercular treatment for sub-fertile women with multiple imaging markers suggesting genital tuberculosis. *Fertil Sci Res* 2014; *1* : 44-9.
 77. Jindal UN, Verma S, Bala Y. Favorable infertility outcomes following anti-tubercular treatment prescribed on the sole basis of a positive polymerase chain reaction test for endometrial tuberculosis. *Hum Reprod* 2012; *27* : 1368-74.
 78. Sutherland AM. Surgical treatment of tuberculosis of the female genital tract. *BJOG Int J Obstet Gynaecol* 1980; *87* : 610-2.
 79. Sharma JB. *In vitro* fertilization and embryo transfer in female genital tuberculosis. *IVF Lite* 2015; *2* : 14-25.
 80. Sharma JB, Mohanraj P, Roy KK, Jain SK. Increased complication rates associated with laparoscopic surgery among patients with genital tuberculosis. *Int J Gynaecol Obstet* 2010; *109* : 242-4.
 81. Tripathy SN, Tripathy SN. Gynaecological tuberculosis - an update. *Indian J Tuberc* 1998; *45* : 193-8.
 82. Sharma JB, Mohanraj P, Jain SK, Roy KK. Increased complication rates in vaginal hysterectomy in genital tuberculosis. *Arch Gynecol Obstet* 2011; *283* : 831-5.
 83. Botha MH, Van der Merwe FH. Female genital tuberculosis. *S Afr Fam Pract* 2008; *50* : 12-6.

Reprint requests: Dr Mohan Natrajan, Department of Clinical Research, ICMR- National Institute for Research in Tuberculosis
No. 1, Mayor Sathyamoorthy Road, Chetpet, Chennai 600 031, Tamil Nadu, India
e-mail: mohan.n@nirt.res.in