

SENTINEL LYMPH NODE BIOPSY IN BREAST CANCER; OUR EXPERIENCE IN THE UNIVERSITY HOSPITAL FOR TUMORS, ZAGREB, CROATIA

DANKO VELIMIR VRDOLJAK, MLADEN STANEC, MIROSLAV LESAR and STJEPAN JUZBAŠIĆ

Department of Surgical Oncology, University Hospital for Tumors, Zagreb, Croatia

Summary

The study was aimed at analyzing metastatic involvement in sentinel lymph node in patients with primary breast cancer.

The study includes 51 female patients undergoing surgery for primary breast cancer at the University Hospital for Tumors, Zagreb, Croatia. Prior to the standard surgical procedure, sentinel lymph node biopsy was performed and pathohistologically and immunohistochemically analyzed.

Sentinel lymph node biopsy was done in 51 patients meeting the indication criteria for the procedure. In 39 (76.47%) biopsy samples immunohistochemical results were negative (no signs of metastases), in 11 (21.57%) the result was positive, and in 1 (1.96%) patient the sentinel lymph node was not located using the gamma probe following the preoperative lymphoscintigraphy.

Recently, a new phase in conserving surgery for breast cancer has started. Considering the presence of the so-called skip metastases in 2% of the cases, the idea of conserving surgery for axillary lymph nodes occurred, and thus the sentinel node surgery has been developed. In simple terms, in case the sentinel lymph node is negative, other axillary lymph nodes should not be removed; if the node is positive, a classic axillary dissection, i.e. the removal of axillary lymph nodes should be done.

KEY WORDS: *breast cancer, sentinel lymph node, tumor marker CA 15-3*

BIOPSIJA LIMFNOGA ČVORA «ČUVARA» KOD RAKA DOJKE; ISKUSTVO STEČENO U KLINICI ZA TUMORE, ZAGREB, HRVATSKA

Sažetak

U radu je analizirana metastatska zahvaćenost limfnoga čvora «čuvara» u bolesnica s primarnim rakom dojke.

Analizirana je 51 bolesnica s primarnim rakom dojke operirana u Klinici za tumore, Zagreb, Hrvatska u razdoblju. Prije standardnog kirurškog zahvata, učinjena je biopsija čimfnog čvora «čuvara», a potom su uzorci analizirani patohistološki i imunohistokemijski.

Biopsija limfnog čvora stražara je učinjena u 51 bolesnice koje su zadovoljavale indikaciju za navedeni postupak. U 39 (76,47%) uzoraka biopsije imunohistokemijska obrada dala negativan rezultat (nema znakova metastaza), u 11 (21,57%) uzoraka je nalaz pozitivan, a u jedne (1,96%) bolesnice limfni čvor "stražar" nije lociran gama-kamerom nakon preoperacijske limfoscintigrafije

U zadnje vrijeme teži se poštednim zahvatima u postupcima operacije raka dojke. Znajući da je postojanje tzv. "skip metastaza" negdje oko 2 %, pojavljuje se ideja o poštednoj operaciji aksilarnih limfnih čvorova. Tako je stvorena kirurgija "sentinel" limfnog čvora (limfnog čvora "stražara"). Pojednostavljeno, ako je "sentinel" limfni čvor negativan, ne bi trebalo uklanjati druge limfne čvorove u pazuhu, a ako je pozitivan, činila bi se i dalje klasična disekcija aksile s uklanjanjem aksilarnih limfnih čvorova.

KLJUČNE RIJEČI: *rak dojke, limfni čvor "čuvar", tumorski biljeg CA 15-3*

INTRODUCTION

The axillary lymph node status is among the most important information gained from surgery, regarding both the prognosis and further treatment. There are three anatomic levels of axillary lymph nodes, and routine surgical procedures usually involve removal of all lymph nodes. Recently, intraoperative sentinel lymph node biopsy has been used to avoid the unnecessary removal of healthy axillary nodes. Actually, numerous studies show that the lymphatic spread of cancer occurs through the first lymph node of the associated nodal basin - the so-called sentinel lymph node, and that metastatic skipping of the mentioned node (the so-called «skip metastases») is a very rare occurrence, developing in less than 2% of breast-cancer cases. Knowledge of the sentinel lymph node and its identification helps avoid the unnecessary dissection of uninvolved axillary lymph nodes, and reduce additional patient morbidity. The routine procedure will therefore include the lymph node removal only in case of the positive sentinel lymph node.

The study includes:

1. The presence of metastatic changes in the sentinel lymph node with the following indication: tumor not exceeding 3 cm, clinically negative axillary lymph nodes, no signs of breast tumor multicentricity, no previous operations or irradiation of the axilla.

PATIENTS AND METHODS

The study includes 51 female patients undergoing surgery for primary breast cancer at the University Hospital for Tumors, Zagreb, Croatia. Prior to the standard surgical procedure (segmentectomy or mastectomy with axillary dissection), sentinel lymph node biopsy was performed and pathohistologically and immunohistochemically analyzed.

The indication for sentinel node biopsy in breast cancer is as follows: a maximal tumor diameter not exceeding 3 cm, clinically negative axillary lymph nodes, no signs of breast cancer

multicentricity, no previous operation procedures or axillary irradiation. Following the indication, the patients underwent preoperative lymphoscintigraphy at the Department of Nuclear Medicine. Using colloid ^{99}Te solution, the regional lymphatic drainage area in primary tumor was determined, and the position of the sentinel lymph node marked; the sentinel node biopsy procedure should be done within 12 hours following the lymphoscintigraphy. The node is detected intraoperatively using a dual method: a) preoperative intracutaneous injection of 2 ml lymphazurin (blue dye) in the area surrounding the primary tumor, and b) intraoperative mapping with the α -probe. The sentinel lymph node is stained by the blue dye, and the γ -probe provides the highest numeric and auditory response to ^{99}Te . If the γ -probe did not provide signals of radioactivity, or if it showed minimum radioactivity at the site of a removed node, the node was considered a sentinel lymph node. The removed sentinel node was then further analyzed histochemically and immunohistochemically (Figures 1, 2, 3).

Immunohistochemical staining of lymph node metastases was performed using the PAP method and the equipment of TECH MATE™ HORIZON AUTOMATED IMMUNOSTAINER (Denmark), DAKO (Denmark) monoclonal antibodies – cytokeratine No M821, low-molecular-weight cytokeratine 8 No M631 and high-molecular-weight cytokeratine No M630.

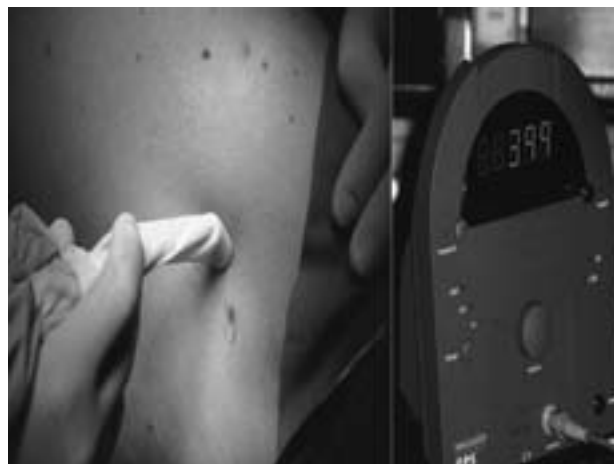


Figure 1. Increased auditory signal intensity during identification of the sentinel lymph node.

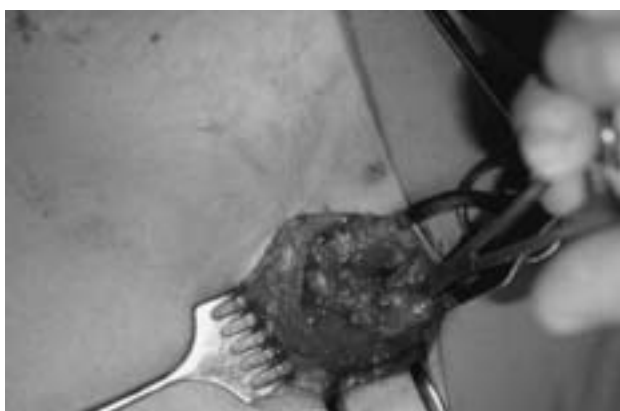

Figure 2. Identification of the sentinel lymph node.

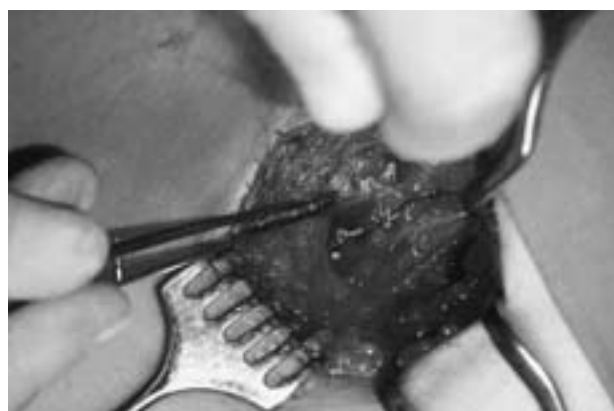

Figure 3. Sentinel lymph node.

RESULTS

Sentinel lymph node biopsy was done in 51 patients meeting the indication for the procedure, and all sentinel lymph nodes were immunohistochemically analyzed. Table 1 shows immunohistochemical findings which in 39 (76.47%) biopsy samples were negative (no signs of metastases), in 11 (21.57%) samples it was positive, and in one (1.96%) patient the sentinel lymph node was not located with the gamma

Table 1.

RESULTS OF THE SENTINEL LYMPH NODE BIOPSY – IMMUNOHISTOCHEMICAL RESULTS

Sentinel Lymph Node Biopsy (SLNB)			
Negative	Unidentified	Positive	Total
39 (76.47%)	1 (1.96%)	11 (21.57%)	51 (100.00%)

camera following preoperative lymphoscintigraphy (Table 1). In patients with sentinel node-negative findings, metastatic foci were found in none (0%) of the remaining axillary lymph nodes.

DISCUSSION

The progress of medicine, screening programs, raising consciousness on issues related to breast cancer, clinical examinations, mammography and US scanning, work together to contribute that the size of newly detected tumors is increasingly smaller. In smaller breast cancers, 70-80% of axillary lymph nodes are negative for malignancy. Although the axillary lymph nodes are the best indicator of the stage of the disease, in 70-80% of breast cancer patients their removal may be unnecessary as well as its associated morbidity (1-4).

Sentinel lymph node biopsy (SLNB) has been developed over 20 years. In 1977, Holmes et al. reported on a melanoma patient in whom radioactive gold colloid was used as a tracer of the regional lymph-node basin. Parallely, Cabanas used the procedure in a patient with penile carcinoma to trace the involved regional lymphatic field and introduced the term of sentinel node as the first lymph node that the regional lymph ducts drain into (5, 6).

Giuliano was the first to use a «patent blue» dye (lymphazurine) injecting it into the area surrounding the tumor, similar to the above case of melanoma (7, 8). Krag was among the first to in-

introduce lymphoscintigraphic mapping of the sentinel lymph node in breast cancer patients, with preoperative injecting radiocolloid Te^{99} into the tumor coupled with the intraoperative use of a radiosensitive probe (gamma-probe)(9). Many studies were published providing justification for the technique. In the studies, either the blue dye or radioisotope technique, and, occasionally, the combination of both were used, which proved to be the most reliable approach (10). Unreliable criteria for the sentinel lymph, and thus contraindications to this approach include (11-13):

1. positive axillary lymph nodes
2. tumor multicentricity
3. primary tumor size exceeding 3 cm

In time, the surgical technique known as sentinel lymph node biopsy has evolved and become the standard method for axillary staging in breast cancer patients with smaller tumors while avoiding routine axillary dissections (13-17).

Pathohistological analysis is a challenging problem in the sentinel lymph node surgery. Actually, routine intraoperative diagnostics with standard hematoxylin and eosin (H&E) staining of frozen sections requires an experienced pathologist and is time-consuming. This histological examination had to be complemented by immunohistochemical examination. Veronesi et al. reported 32.1% of false-negative results obtained by traditional H&E staining, while the immunohistochemical method achieved accuracy of over 98% (14,18-20).

Past studies suggest the necessity for removal of the sentinel lymph node after breast surgery. Following immunohistochemical evaluation, a second surgical procedure still includes standard removal of the axillary lymph nodes in case of immunohistochemical-positive sentinel lymph nodes (with metastatic changes); in case of negative immunohistochemical findings, however, additional mutilation of the axilla and its associated morbidity is considered unnecessary.

The above mentioned, of course, stands if the sentinel lymph node is among the axillary lymph nodes. A large portion of breast cancers do not have the lymphatic drainage into the axillary lymph nodes as the first nodes within the area of lymphatic drainage basin. Uren substantiated that some of lymphatic drainage goes

into the lymph nodes of the internal mammary artery, some into the supraclavicular lymph node, and some into the interpectoral (Rotter's), subclavicular and intramammary lymph nodes. These nodes can also be sentinel lymph nodes. However, they are, inaccessible by the above techniques, so, for the time being, the sentinel lymph node surgery is applicable only when the sentinel node is located in the axillary lymph nodes (21).

Besides all the above, the procedure requires a well experienced team of surgeons and pathologists; the European School of Oncology would not recommend tackling this problem unless by a surgeon or a pathologist who does at least fifty-odd such procedures per year (14, 17, 18).

CONCLUSION

Recently, a new phase in conserving surgery for breast cancer has started. Considering the presence of the so-called skip metastases in 2% of the cases, the idea of conserving surgery for axillary lymph nodes occurred. Thus, the sentinel lymph node surgery has been developed. In simple terms, in case of a negative sentinel lymph node, other lymph nodes in the axilla should not be removed; if the node is positive, a classic axillary dissection, i.e. the removal of axillary lymph nodes should be done.

Sentinel lymph nodes are identified by immunohistochemistry providing superior accuracy of the diagnosis.

Based on the study of 51 breast cancer patients with a reasonable indication for the sentinel lymph node biopsy, the sentinel node was found in 98% of the patients. The node was negative in 39 (76.5%) of the studied patients. In all of the sentinel node negative patients, other axillary lymph nodes were also negative for the presence of metastases.

REFERENCES

1. Mihelčić Z, Krajina Z, Budišić Z, Eljuga Lj, Žigante-Podolski P. Suvremena dijagnostika raka dojke u žena. Libri Oncol 1993; 22(Suppl. 1): 231-8.
2. Vrdoljak M, Knežević F, Šerman A, Vrdoljak VD, Nola N, Eljuga Lj, Tomljanović I. Ultrazvuk i

- mamografija u dijagnostici raka dojke. Libri Oncol 1993; 22 (Suppl 1): 239-42.
3. Vrdoljak M, Orešić V, Vrdoljak VD, Petrinc Z. Early detection of breast cancer screening programme of the University Hospital for Tumors, Zagreb, Croatia. Libri Oncol 1995; 24: 165-7.
 4. Turić M, Kolarić K, Eljuga D. Klinička onkologija. ed: Globus, Zagreb, 1996; 577-628.
 5. Holmes EC, Moseley HS, Morton DL et al. A rational approach to the surgical management of melanoma. Ann Surg 1977; 186: 481-90.
 6. Cabanas RM. An approach for the treatment of penile carcinoma. Cancer 1997; 39: 456-66.
 7. NcMaster KM, Giuliano AE, Ross MI, Reintgen DS, Hunt KK, Byird DR. Sentinel-lymph-node biopsy for breast cancer - Not yet the standard of care. N Engl J Med 1998; 339(14): 990-5.
 8. Giuliano AE, Haigh PI, Brennan MB. Prospective observational study of sentinel lymphadenectomy without further axillary dissection in patients with sentinel node-negative breast cancer. J Clin Oncol 2000; 18: 2553-9.
 9. Krag D, Weaver D, Ashikana T. The sentinel node in breast cancer – a multicenter validation study. New Engl J Med 1998; 339: 941-6.
 10. Cody HS, Fey J, Akhurst T. Complementarity of blue dye and isotope in sentinel localisation for breast cancer: univariate and multivariate analysis of 966 procedures. Ann Surg Oncol 2001; 8: 13-9.
 11. Weaver DL, Krag DN, Ashikaga T, Harlow SP, O Connell M. Pathologic analysis of sentinel and non sentinel lymph nodes in breast carcinoma. Cancer 2000; 88:1099-107.
 12. Lucci JRA, Keleman PR, Miller IIC, Chardkoff L, Wilson L. National practice patterns of sentinel lymph node dissection for breast carcinoma. J Am Coll Surg 2001; 192: 453-8.
 13. McIntosh SA, Purushotham AD. Lymphatic mapping and sentinel node biopsy in breast cancer. Br J Surg 1998; 85:1347-56.
 14. Veronesi U, Galimberti V, Zurrada S. Sentinel lymph node biopsy as an indicator for axillary dissection in early breast cancer. Eur J Cancer 2001; 37: 454-8.
 15. Uren RF, Howman-Giles R, Renwick SB, Gillett D. Lymphatic mapping of the breast: locating the sentinel lymph nodes. World J Surg 2001; 25(6): 789-93.
 16. Clarke D, Mansel R. Sentinel node biopsy in breast cancer. Eur J Surg Oncol 2001; 27:4-8.
 17. Veronesi U, Paganelli G, Galimberti V. Sentinel node biopsy to avoid axillary dissection in breast cancer with clinically negative lymph nodes. Lancet 1997; 349: 1864-7.
 18. Veronesi U, Zurrada S. Optimal surgical treatment of breast cancer. The Oncologist 1996; 1:340-6.
 19. Veronesi U, Zurrada S, Galimberti V. Consequences of sentinel node in clinical decision making in breast cancer and prospects for future studies. Eur J Surg Oncol 1998; 24:93-5.
 20. Veronesi U, Luini A, Galimberti V, Marchini S, Sacchini V, Rilke F. Extent of metastatic axillary involvement in 1446 cases of breast cancer. Eur J Surg Oncol 1990; 16:127-33.
 21. Bale A, Gardner B, Shende M, Fromowitz F. Can interpectoral nodes be sentinel nodes? Am J Surg 1999; 178(5): 360-1.

Received for publication: December 23, 2003

Author's address: Danko Velimir Vrdoljak, M.D., Department OF Surgical Oncology, University Hospital for Tumors, Ilica 197, 10 000 Zagreb, Croatia; E-mail: d.v.vrdoljak@kzt.hr