

## METASTATIC INVOLVEMENT IN INTERPECTORAL (ROTTER'S) LYMPH NODES IN BREAST CANCER PATIENTS

DANKO VELIMIR VRDOLJAK<sup>1</sup>, VESNA RAMLJAK<sup>2</sup>, DUBRAVKA MUŽINA<sup>1</sup>, MLADEN STANEC<sup>1</sup>,  
FABIJAN KNEŽEVIĆ<sup>3</sup>, STJEPAN JUZBAŠIĆ<sup>1</sup> and MARICA VRDOLJAK<sup>4</sup>

<sup>1</sup>Department of Surgical Oncology

<sup>2</sup>Department of Clinical Cytology

<sup>3</sup>Department of Clinical Pathology

<sup>4</sup>Department of Clinical Radiology, University Hospital for Tumors, Zagreb, Croatia

### Summary

The study was aimed at analyzing metastatic involvement in interpectoral (Rotter's) lymph nodes in patients with primary breast cancer.

The study includes 172 female patients undergoing surgery for breast cancer at the University Hospital for Tumors, Zagreb, Croatia from November 2001 to August 2003. In addition to the standard surgical procedure, interpectoral (Rotter's) lymph nodes were removed in all of the patients.

Rotter's lymph nodes were identified in 67% of the patients, with metastatic involvement revealed in 20% of the Rotter's nodes. Metastatic involvement of Rotter's nodes in patients with negative and positive axillary lymph nodes was 4% and 35%, respectively.

The results show that one-fifth of breast cancer patients, or even one-third of them with positive axillary lymph nodes, are discharged with positive interpectoral lymph nodes that remain undiagnosed and non-extirpated. As the nodes can be surgically removed without additional mutilation or resections, the exploration of Rotter's lymph nodes should be introduced into routine clinical practice for diagnostic and therapeutic reasons.

KEY WORDS: *breast cancer, interpectoral (Rotter's) lymph nodes*

### METASTATSKA ZAHVAĆENOST INTERPEKTORALNIH (ROTTEROVIH) LIMFNIH ČVOROVA U BOLESNICA S RAKOM DOJKE

#### Sažetak

U radu je analizirana metastatska zahvaćenost interpektoralnih (Rotterovih) limfnih čvorova u bolesnica s primarnim rakom dojke.

Analizirane su 172 bolesnice s rakom dojke operirane u Klinici za tumore u Zagrebu, Hrvatska u razdoblju od studenog 2001. do kolovoza 2003. U svih su bolesnica, uz standardni kirurški zahvat, uklonjeni i interpektoralni (Rotterovi) limfni čvorovi.

Rotterovi limfni čvorovi otkriveni su 67% bolesnica, od kojih je 20% bilo zahvaćeno metastazama. Metastatska zahvaćenost Rotterovih limfnih čvorova otkrivena je u 4% bolesnica s negativnim aksilarnim čvorovima, odnosno u 35% bolesnica s pozitivnim limfnim čvorovima aksile.

Rezultati pokazuju da je jedna petina bolesnica s rakom dojke, ili čak jedna trećina s pozitivnim aksilarnim limfnim čvorovima otpuštena iz bolnice s pozitivnim interpektoralnim limfnim čvorovima koji nisu dijagnosticirani, pa tako ni uklonjeni. Kako se ti čvorovi mogu ukloniti bez dodatne mutilacije, otkrivanje Rotterovih limfnih čvorova treba postati redovitom kliničkom praksom u dijagnostici i terapiji.

KLJUČNE RIJEČI: *rak dojke, interpektoralni (Rotterovi) limfni čvorovi*

### INTRODUCTION

The study is aimed at exploring the level of Rotter's lymph node involvement in breast can-

cer patients with positive (metastatically involved) axillary lymph nodes to obtain more detailed information about disease status and their prognostic value, which potentially have a sub-

stantial effect on adjuvant chemotherapy and postoperative irradiation. For many patients undergoing surgery without Rotter's lymph node removal, the nodes may be responsible for further spreading of the disease, indicating the therapeutic effect of this type of surgery. Finally, the obtained results may come in handy as guidelines on routine removal of Rotter's nodes in breast cancer patients.

The study includes 172 female patients operated for primary breast cancer.

A special attention is paid to the analysis of:

1. Overall, surgically confirmed presence of Rotter's lymph nodes
2. Metastatic involvement in Rotter's lymph nodes

## PATIENTS AND METHODS

The study includes 172 female patients undergoing surgery for breast cancer at the Department of Surgery, University Hospital for Tumors, Zagreb, Croatia from November 2001 to August 2003. All the patients were operated on by the same surgical team. Standard preoperative evaluations included x-ray test of the lungs, spine and pelvis, abdominal and breast ultrasonography, mammography, complete laboratory tests, tumor marker CA 15-3. All operations were performed under general anesthesia using ordinary endotracheal intubation (1, 2, 3). All patients underwent surgical tumor biopsy, and surgery for biopsy confirmed breast cancer (either segmentectomy or mastectomy) (4), as well as dissection of axillary nodes at all three levels and Rotter's lymph node extirpation (5). Pathohistologic evaluation of breast carcinoma performed with intraoperative frozen section biopsy was definitely confirmed on permanent tissue sections embedded in paraffin and stained with hemalaun-eosin. After a confirmed breast cancer diagnosis, a portion of the material was sent for testing of hormone receptors for both estrogen and progesterone (6, 7, 8, 9,10). Tumors were classified according to the World Health Organization Classification of Tumors (11), and the grade of differentiation according to the Bloom-Richardson grading scheme (12).

The statistical methods used to analyze the data were  $\chi^2$ - test and correlation test with the obtained values expressed in percentage.

## RESULTS

The study results showed that breast cancer patients were in the age bracket between 28 and 84 years of age (median 57.8 years). Regarding localization, in 89 patients the tumor was present in the right breast (51.7%), and in the remaining 83 it was located in the left breast (48.3%); 110 (64%) patients underwent breast cancer ablation, and in 62 (36%) segmentectomy was performed.

All of the patients underwent radical dissection of axillary lymph nodes and removal of interpectoral fat tissue with Rotter's lymph nodes. (Figure 1).

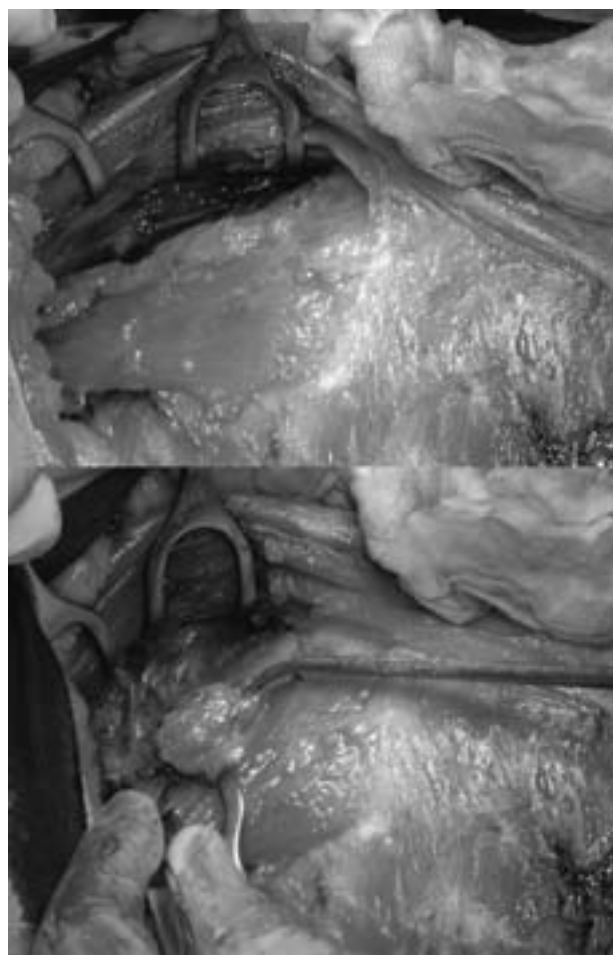


Figure 1 – Surgical removal of interpectoral (Rotter's) lymph nodes

Patohistologic diagnosis				
Invasive ductal carcinoma	Grade I	22		14,50%
	Grade II	86		56,60%
	Grade III	44	88,40%	28,90%
Lobular carcinoma		11		6,40%
Mucinous carcinoma		7		4,10%
Papillary carcinoma		1		0,60%
Medullary carcinoma		1		0,60%
		172		

Figure 2 – Patohistologic diagnosis of tumors in patients with breast cancer

Pathohistologic evaluation showed invasive ductal carcinoma in 152 (88.4%), mucinous carcinoma of the breast in 7 (4.1%), lobular carcinoma in 11 (6.4%) and papillary and medullary carcinoma of the breast in 1 (0.6%) patient each. Of 152 invasive ductal carcinomas, 22 (14.5%) were grade I, 86 (56.6%) grade II, and 44 (28.9 %) grade III (Figure 2).

Pathohistologic examination of axillary lymph nodes showed no metastatic involvement 80/172 (46.5%), while 92/172 (53.5%) patients were axillary lymph node positive. Interpectoral

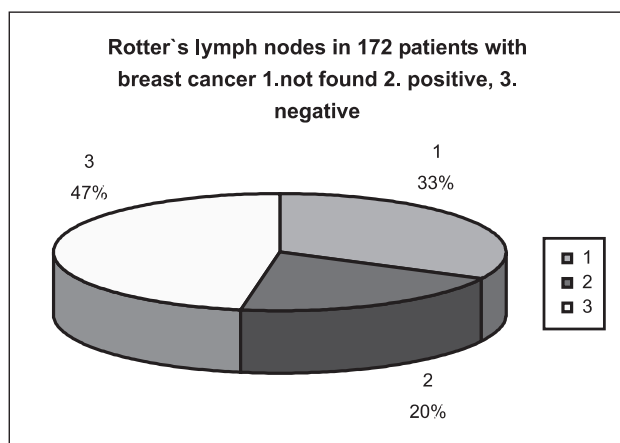


Figure 3 – Interpectoral lymph nodes (Rotter's lymph nodes) in patients with breast cancer

Axillary l.nodes		Rotter's l.n. +	Rotter's l.n. -	No Rotter's l.n.
Negative	80 (47 %)	3 (4%)	44 (55%)	33 (41%)
Positive	92 (53 %)	32 (35%)	37 (40%)	23 (25%)
All	172 (100%)	35 (20%)	81 (47%)	56 (33%)

Figure 4 – Rotter's lymph nodes in correlation with axillary lymph nodes in 172 patients with breast cancer

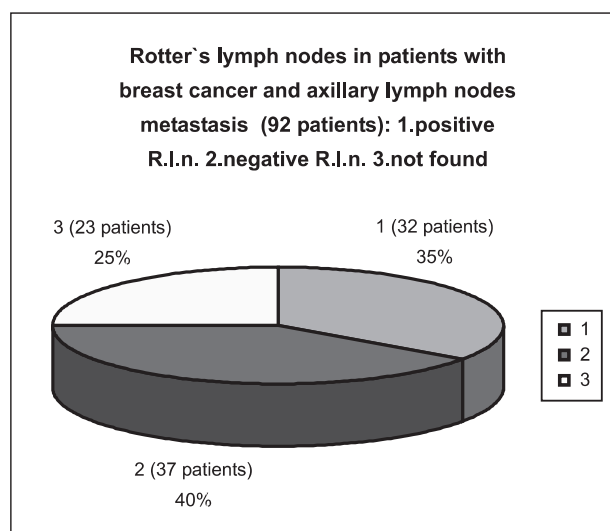


Figure 5 – Rotter's lymph nodes in patients with breast cancer with metastatically involved axillary lymph nodes

fat tissue of 56/172 (32.6%) patients did not contain any lymph nodes, while at least 1 lymph node was found in 116/172 (67.4 %). Tumor cell-positive Rotter's lymph nodes were found in 35/172 (20.3%), and 81/172 (47.1%) patients had tumor-negative nodes. Of patients with pathohistologically confirmed Rotter's nodes (116/172), 30.2% were positive (with metastatic tumor cells), and the remaining 69.8% were negative (Figures 3 and 4).

From a total of 80 patients with negative axillary lymph nodes, in 33/80 (41.2%) Rotter's lymph nodes were not found, and in 47/80 (58.75%) patients the presence of Rotter's nodes was pathohistologically confirmed; 3/80 (3.75%) had positive Rotter's lymph nodes.

Of patients with positive axillary lymph nodes (92/172 patients or 53.5%), in 23/92 (25.0%) Rotter's lymph nodes were not found, and in 69/92 (75.0%) the presence of Rotter's lymph nodes was not confirmed; 32/92 (34.8 %) had positive Rotter's lymph nodes, while the nodes were negative in 37/92 (40.2%) (Figure 5).

The median number of lymph nodes removed in 172 patients was 15.1 (minimum 5, maximum 28). The median number of positive lymph nodes in 92 axillary lymph node-positive patients was 5.4 (ranging from 1 to 21).

The average number of extirpated Rotter's lymph nodes in 116 patients with identified Rot-

ter's lymph nodes was 2.7 (ranging from 1 to 12). Lymph node-positive patients had 2.2 nodes (from 1 to maximum 5 positive Rotter's lymph nodes) extirpated on the average.

## DISCUSSION

The thesis that the removal of axillary lymph nodes should be considered both a therapeutic and diagnostic procedure, raises the question of Rotter's lymph nodes, whether the thesis applies to them too, how can Rotter's nodes fit into the International TNM Classification. Recently, there has been a tendency towards conservative surgery for breast cancer. As the incidence of the so-called «skip» metastases is known to be about 2%, an idea of conservative treatment of axillary lymph nodes has also occurred recently. Thus, sentinel lymph node dissection has been developed (13, 14, 15, 16, 17, 18). The results can also be used in the above conservative management of axillary nodes, but in case of positive lymph nodes, Rotter's lymph nodes should also be explored and removed.

Preoperative diagnosis of Rotter's lymph nodes in routine clinical practice is rather unsafe. According to some authors, Rotter's lymph nodes can be detected by ultrasound in 10-35% cases. Results obtained by a majority of authors show metastatic involvement in Rotter's lymph nodes in about 10% of patients (19). Cody and colleagues confirmed Rotter' node metastases in only 2.6% of patients, with no difference in both size and localization compared to other patients (20). In cases where special techniques for lymph node assessment are used, the percentage increases to 19% as shown by Durkin and Haagensen (21). Other authors show that metastatic involvement in Rotter's node is more frequent in younger patients with a larger primary tumor of about 4 cm in diameter. Like Cody et al, Dixon and colleagues also consider that the identification of Rotter's node in patients with early carcinoma of the breast is of no greater practical significance (20, 22). In a majority of cases, Rotter's node metastases are found in patients with already proven axillary metastases. However, some authors consider that patients with metastases in Rotter's lymph nodes alone have a better prognosis (23). Unlike them, Oran and col-

leagues report that 2 of 3 patients with metastases occurring only in interpectoral (Rotter's) lymph nodes will develop massive distant metastases within less than 12 months from diagnosis (24). Survival of lymph node-positive patients also depends upon the number of positive lymph nodes. Almost all authors, and among them Rotter himself, suggest that lymph drainage, thus the route of metastasis dissemination from upper and deep breast structures passes through interpectoral lymph nodes.

Our results show that Rotter's node metastases are not so rare, and that breast cancer can be locally controlled by surgery in the early stages of the disease. This problem of breast cancer treatment has been tackled by Yamasaki and Kodama (25).

In this study, Rotter's lymph nodes were identified in 116 patients, accounting for (compared to previous experience and literature data) a surprising 67.4 percent. Instead of in the expected one-third, Rotter's lymph nodes were verified pathohistologically in two-thirds of the patients studied. Of the 116 patients with Rotter's lymph nodes, 35 had at least one metastatic lymph node which accounts for 30.2%, or compared to the overall number of patients studied, an astonishing 20.3%. Referring back to the thesis that the removal of axillary lymph nodes is considered to be both a therapeutic and diagnostic procedure, the question remains whether in our standard, routine clinical practice we dismiss for further treatment one-fifth of patients with their tumor, a potential source of further disease dissemination, still present. Another question is how can Rotter's node-positive patients be fitted into the actual TNM classification that not only does not include, but also does not even mention Rotter's lymph nodes. Metastatic involvement in Rotter's lymph nodes was identified in 3 axillary lymph node-negative patients accounting for, not at all irrelevant, 3.75%. How do these patients fit into the TNM classification? There is also a question of whether Rotter's nodes could be considered as «sentinel nodes» in patients with tumor located in the upper breast quadrants, as suggested by other authors as well. Bale and colleagues who have also tackled the above question, discuss the occurrence of false-negative results of sentinel lymph node biopsy (26, 27).



## CONCLUSION

Taking into consideration the above, removal of Rotter's lymph nodes may play a particular role in the treatment of breast cancer. With good communication between diagnostic and experienced and profiled surgical-pathologic teams, the identification and removal of Rotter's lymph nodes with metastatic involvement should not be a technical problem, especially since with the early postoperative rehabilitation program, it does not make any difference to the patient. For many women undergoing surgery for breast cancer without Rotter's node removal, the nodes are responsible for further spreading of the disease, suggesting potential therapeutic benefits of this type of surgical management of breast cancer.

## REFERENCES

1. Mihelčić Z, Krajina Z, Budišić Z, Eljuga Lj, Žigante-Podolski P. Suvremena dijagnostika raka dojke u žena. Libri Oncol 1993; 22(Suppl. 1): 231-8.
2. Vrdoljak M, Knežević F, Šerman A, Vrdoljak VD, Nola N, Eljuga Lj, Tomljanović I. Ultrazvuk i mamografija u dijagnostici raka dojke. Libri Oncol 1993; 22 (Suppl 1):239-42.
3. Vrdoljak M, Orešić V, Vrdoljak VD, Petrincec Z. Early detection of breast cancer screening programme of the University Hospital for Tumors, Zagreb, Croatia. Libri Oncol 1995; 24:165-7.
4. Turić M, Kolarić K, Eljuga D. Klinička onkologija. ed: Globus, Zagreb, 1996; 577-628.
5. Rotter J. Zur Topographie des Mammacarcinos. Arch F Klin Chir 1899; 58: 346-56.
6. McGuire WL. Estrogen receptors in human breast cancer. J Clin Invest 1973; 52:739.
7. Gamulin S. Mehanizam hormonske ovisnosti raka dojke i izbor sistemske terapije. Libri Oncol 1981; 23:159-64.
8. James N, Ingle S. Additive hormonal therapy in women with advanced breast cancer. Cancer 1984; 53: 766-81.
9. Nola N, Šeparović V, Šarčević B. Estrogenski i progesteronski receptori kod uznapredovalog karcinoma dojke. Lijecn Vjesn 1995; 117: 117-20.
10. Brdar B, Graf D, Padovan R. Estrogen and progesterone receptors as prognostic factors in breast cancer. Tumori 1988; 74: 45-52.
11. Bears OH, Henson DE, Hutter RVP, Myers NF. Manual for staging of cancer. 3. ed. JB Lippincot, Philadelphia 1988; 145-50.
12. Bloom WC, Richardson WW. Histological grading and prognosis in breast cancer. Br J Cancer 1957; 11: 359-77.
13. Cote RJ, Peterson HF, Chaiwun B. Role of immunohistochemical detection of lymph node metastases in management of breast cancer. Lancet 1999; 354: 896-900.
14. Meyer JS. Sentinel lymph node biopsy: Strategies for pathologic examination of the specimen. J Surg Oncol 1998; 69: 212-8.
15. Clarke D, Mansel R. Sentinel node biopsy in breast cancer. Eur J Surg Oncol 2001; 27: 4-8.
16. Veronesi U, Zurrada S. Optimal surgical treatment of breast cancer. The Oncologist 1996; 1: 340-6.
17. Veronesi U, Paganelli G, Galimberti V. Sentinel node biopsy to avoid axillary dissection in breast cancer with clinically negative lymph nodes. Lancet 1997; 349: 1864-7.
18. Veronesi U, Zurrada S, Galimberti V. Consequences of sentinel node in clinical decision making in breast cancer and prospects for future studies. Eur J Surg Oncol 1998; 24: 93-5.
19. Kay S. Evaluation of Rotter's lymph nodes in radical mastectomy specimens as a guide to prognosis. Cancer 1965; 18: 1441-4.
20. Cody HS III, Egeli RA, Urban JA. Rotter's node metastasis. Therapeutic and prognostic considerations in early breast carcinoma. Ann Surg 1984; 199: 266-70.
21. Durkin K, Haagensen CD. An improved technique for the study of lymph nodes in surgical specimens. Ann Surg 1980; 191: 419-29.
22. Dixon JM, Dobie V, Chetty U. The importance of interpectoral nodes in breast cancer. Eur J Cancer 1993; 29A: 334-6.
23. Chandawarker RY, Shinde SR. Interpectoral nodes in carcinoma of the breast: requiem or resurrection. J Surg Oncol 1996; 62(3): 158-61.
24. Oran I, Mernis A, Ustun EE. Ultrasonographic detection of interpectoral (Rotter's) node involvement in breast cancer. J Clin Ultrasound 1996; 24: 519-22.
25. Yamasaki N, Kodama H. A role of interpectoral (Rotter's) lymph node dissection in modified radical mastectomy for breast cancer. Nippon Geka Gakkai Zasshi 1992; 11: 1427-32.
26. Bale A, Gardner B, Shende M, Fromowitz F. Can interpectoral nodes be sentinel nodes? Am J Surg 1999; 178(5): 360-1.
27. Uren RF, Howman-Giles R, Renwick SB, Gillett D. Lymphatic mapping of the breast: locating the sentinel lymph nodes. World J Surg 2001; 25(6): 789-93.

*Received for publication: May 20, 2003*

*Autor's address: Danko Velimir Vrdoljak, M.D., University Hospital for Tumors, Dept. of Surgical Oncology, Ilica 197, Zagreb 10 000, Croatia; Fax: 00 385 1 3775 536*