



HHS Public Access

Author manuscript

J Surg Res. Author manuscript; available in PMC 2021 February 01.

Published in final edited form as:

J Surg Res. 2020 February ; 246: 512–518. doi:10.1016/j.jss.2019.09.037.

Sildenafil As A Rescue Agent Following Intestinal Ischemia and Reperfusion Injury

Hannah M. Moore¹, Natalie A. Drucker, MD^{1,2}, Brian D. Hosfield, MD^{1,2}, W. Chris Shelley, BA^{1,2}, Troy A. Markel, MD^{1,2,3}

¹The Indiana University School of Medicine

²Department of Surgery, Section of Pediatric Surgery

³Riley Hospital for Children at Indiana University Health and Indianapolis, IN

Abstract

Background: Acute mesenteric ischemia carries a significant morbidity. Measures to improve blood flow parameters to the intestine may ameliorate the disease. Sildenafil, a phosphodiesterase 5 inhibitor, increases cyclic GMP and has been shown to prevent the effects of ischemia when given before injury. However, its effects as a rescue agent have not been established. We therefore hypothesized that sildenafil, when given as a rescue agent for intestinal ischemia, would improve mesenteric perfusion, limit intestinal epithelial injury, and decrease intestinal leukocyte chemoattractants.

Methods: Eight to twelve week old male C57BL/6J mice underwent laparotomy and temporary occlusion of the superior mesenteric artery for 60 minutes. Following ischemia, reperfusion was permitted and prior to closing the abdomen, sildenafil was injected intraperitoneally in a variety of concentrations. After 24 hours, reperfusion was reassessed. Animals were euthanized and intestines evaluated for histologic injury and leukocyte chemoattractants.

Results: Post-ischemic administration of sildenafil did not improve mesenteric perfusion following intestinal ischemia and reperfusion injury. However, sildenafil did improve histologic injury scores in dose ranges of 0.01 to 10mg/kg. No difference was noted in histological injury with 100 mg/kg dose, and all members of the 1000 mg/kg group died within 24 hours of injury. Epithelial protection was not facilitated by the leukocyte chemoattractants RANTES, Mip1a, MCP, KC, or GCSF.

Conclusion: Administration of sildenafil following intestinal ischemia may limit intestinal mucosal injury but does not appear to alter mesenteric perfusion or leukocyte chemoattractant influx.

Correspondence: Troy A. Markel, MD, Assistant Professor of Surgery, Indiana University School of Medicine, Riley Hospital for Children at IU Health, 705 Riley Hospital Dr. RI 2500, Indianapolis, IN 46202, Phone: 317-437-2506, tmarkel@iupui.edu. HMM performed animal I/R experiments and drafted the manuscript, BDH/WCS performed histological grading and statistical analysis, NAD performed protein isolation and biopex analysis, TAM contributed critical ideas, performed histological grading, as well as assistance and manuscript advice. All authors provided critical revisions to the manuscript and assisted with its final preparation.

Keywords

sildenafil; intestinal ischemia; injury; inflammation; endothelial; epithelial

1. INTRODUCTION

Intestinal ischemia occurs when the mesenteric vasculature becomes acutely occluded. Interrupted blood flow to the intestine leads to cellular damage and eventual bowel necrosis, with mortality rates as high as 55–80% (1, 2). Those patients that survive may require intestinal transplantation or intravenous nutrition secondary to short bowel syndrome. Intestinal ischemia can result from a number of etiologies in both pediatric and adult patients, including aortic thrombus, incarcerated hernias, and bowel obstructions (3, 4). Medical therapies to counteract the ischemic damage to the intestines are suboptimal, and therefore, the development of novel treatment modalities is needed.

In this regard, sildenafil has been observed to decrease the detrimental effects of intestinal ischemia and end organ injury when given prophylactically before an ischemic insult (5–7). Sildenafil is a phosphodiesterase type five (PDE5) inhibitor that works to decrease the breakdown of cyclic guanosine monophosphate (cGMP) to GMP. This effect works to promote smooth muscle relaxation and improved blood flow to organs via cGMP-dependent protein kinase-dependent activation of K channels (8).

It is often unclear which patients will develop intestinal ischemia until the insult happens. Although it is good to have preventative measures, there also needs to be appropriate rescue agents that can ameliorate injury or even rescue the intestines following injury. Given its vasodilatory properties, it is possible that the use of sildenafil could restore mesenteric perfusion following injury. Furthermore, it may be able to limit intestinal leukocyte influx as measured by Regulated on Activation, Normal T Cell Expressed and Secreted (RANTES), Macrophage Inflammatory Protein 1 alpha (Mip1a), Monocyte Chemoattractant Protein (MCP), Neutrophil Activating Protein (KC), and Granulocyte Colony Stimulating Factor (GCSF).

There are no existing data to corroborate or refute the use of sildenafil as a rescue agent following intestinal ischemia. However, it is likely that it functions in much the same manner as it does when given prophylactically before injury. We hypothesized that sildenafil would stabilize the mesenteric vasculature and improve intestinal mesenteric perfusion, decrease intestinal epithelial injury, and limit leukocyte chemoattractants in the small intestinal tissues when given as a rescue agent following intestinal ischemia.

2. METHODS**2.1 Animals**

Previous studies focusing on intestinal ischemia have shown that males tend to have a more robust inflammatory response with more rapid influx of leukocytes compared to females. In addition, males have higher apoptotic Paneth cells per crypt as well as higher levels of intestinal fatty acid binding protein following ischemia compared to females (9, 10). We did

not want the artifact of sex differences to impact our observation of the protective effects of sildenafil, and therefore only males were enlisted for this study.

The Indiana University Institutional Animal Care and Use Committee approved all experimental protocols and animal use (Protocol #18010). Male adult wild-type C57BL/6J mice weighing 25–30 grams underwent at least 48 hours of acclimation prior to any experimentation. Normal chow and water were provided and all mice were kept in 12-hour light/dark cycled housing. Animals were bred in house and treated in humane fashion according to the “Guide for the Care and Use of Laboratory Animals” (11).

2.2 Ischemia-Reperfusion Model

The murine intestinal ischemia and reperfusion (IR) protocol was performed as we previously described (12, 13). Briefly, mice were anesthetized using 3% isoflurane followed by maintenance at 1.5% isoflurane in oxygen. Temperature homeostasis was achieved through use of a heating pad and the abdomen was prepped through hair removal and sterile preparation with 70% ethanol followed by betadine. One milliliter of 0.9% normal saline was injected subcutaneously in all mice pre-operatively to account for intra-operative fluid losses. Post-operative pain was managed with subcutaneous administration of analgesia (1mg/kg buprenorphine and 5mg/kg carprofen) given immediately following surgery.

Under sterile conditions, a midline laparotomy was performed and the intestines were eviscerated. The superior mesenteric artery was identified and clamped using an atraumatic microvascular clamp. The intestines were then placed back into the abdominal cavity and the abdomen was temporarily closed using silk suture to prevent evaporative losses. Following 60 minutes of intestinal ischemia, the abdomen was reopened and the atraumatic clamp was removed. The abdominal fascia and skin were then closed in a two-layer fashion with suture. Following surgery, animals were placed in warm cage and allowed to recover. Once fully awake and alert, animals were returned to animal housing.

2.3 Drug Administration

Sildenafil was obtained through a generous donation from Pfizer (New York, NY). It was reconstituted from its lyophilized powder in PBS daily for experimentation. Following removal of the vascular clamp from the superior mesenteric artery, sildenafil in PBS vehicle (250ul) was administered intraperitoneally. Experimental groups were: 1) PBS vehicle, 2) 0.01 mg/kg sildenafil, 3) 1.0 mg/kg sildenafil, 4) 10 mg/kg sildenafil, 5) 100 mg/kg sildenafil, and 6) 1000 mg/kg sildenafil.

2.4 Perfusion Analysis

Intestinal mesenteric perfusion was analyzed using a Laser Doppler perfusion Imager (LDI; Moor Instruments, Wilmington, DE) as we have previously described (13). Perfusion images were acquired at baseline, at initial clamping of the superior mesenteric artery and at 24 hours following intestinal ischemia (N=8/group). Using images obtained, a region of interest was created around the entirety of exposed intestines. Using three images from each time point, a flux mean perfusion was acquired for the region of interest. Perfusion data was normally distributed and expressed as a percentage of baseline (mean±SEM). After the 24-

hour recovery analysis, mice were euthanized with isoflurane overdose and cervical dislocation. Intestinal tissues were explanted for further analyses.

2.5 Histology Injury Score

Following euthanasia of experimental groups, terminal ileums were harvested and fixed in 4% paraformaldehyde with subsequent dehydration in 70% ethanol (N=7–8/group). Paraffin-embedded sections were prepared and stained with hematoxylin and eosin. Histological scoring of the depth of tissue injury was performed as previously described: 0, no damage; 1, subepithelial space at the villous tip; 2, loss of mucosal lining of the villous tip; 3, loss of less than half of the villous structure; 4, loss of more than half of the villous structure; and 5, transmural necrosis (14, 15). Sections were evaluated blindly by three authors with experience in grading histological tissues. Data were not normally distributed and are presented as median and interquartile range.

2.6 Intestinal Chemokine Analysis

Mouse intestinal tissues designated for protein analysis were harvested, snap frozen in liquid nitrogen and stored at -80°C . Once ready to use, intestines were thawed and homogenized in RIPA buffer (Sigma, St. Louis, MO) with phosphatase and protease inhibitors (1:100 dilution, Sigma, St. Louis, MO) using a Bullet Blender tissue homogenizer (Next Advance, Averill Park, NY). Following homogenization, samples were centrifuged at 12,000 rpm to pellet extraneous tissue and supernatants were collected and placed into fresh Eppendorf tubes. Total protein concentration was quantified with the Bradford assay using a spectrophotometer (VersaMax microplate reader; Molecular Devices, Sunnyvale, CA).

Murine intestinal levels of Regulated on Activation, Normal T Cell Expressed and Secreted (RANTES), Macrophage Inflammatory Protein 1 alpha (Mip1a), Monocyte Chemoattractant Protein (MCP), Neutrophil Activating Protein (KC), and Granulocyte Colony Stimulating Factor (GCSF) were quantified using a Bio-Plex 200 multiplex beaded assay system (Bio-Rad, Hercules, Ca) with customizable multiplex plates for murine inflammatory cytokines (Millipore, Billerica, MA). Assays were performed at 1:25 dilution according to the manufacturer's instructions and are reported in nanograms of chemokine per gram of total intestinal protein. Data were not normally distributed, and so are expressed as median and interquartile range. Experiments were repeated to ensure accuracy (N=12–13/group).

2.7 Statistical Analysis

Data were assessed for normalcy by the Shapiro-Wilk and Kolmogorov-Smirnov normality tests. Normally distributed data were compared with Student's t test while nonparametric data were compared with Mann Whitney U test. All statistical analyses were performed using GraphPad Prism 7 (GraphPad Software, La Jolla, CA). Parametric data were expressed as mean \pm SEM while nonparametric data were reported as median and interquartile range. p-values less than 0.05 were considered statistically significant.

3. RESULTS

3.1 Survival and Perfusion

Nine animals died within the first twenty-four hours, and their data was not included in further analysis. 1000 mg/kg resulted in uniform fatality within 24 hours (Table 1). Mesenteric perfusion was noted to be depressed following clamping of the superior mesenteric artery. Once the clamp was removed, reperfusion was allowed (Figure 1). Sildenafil did not offer any significant improvements over vehicle when measuring mesenteric perfusion following intestinal IR (Figure 2).

3.2 Histologic Injury

Intestinal epithelial injury scores were significantly improved for the lower doses of sildenafil compared to vehicle (Vehicle: 3 (IQR 1.75), 0.01mg/kg: 2 (IQR 2), 1.0mg/kg: 2 (IQR 1.75), 10.0mg/kg: 3 (IQR 3), $p < 0.05$). There was no difference between vehicle and the 100 mg/kg dose (3 (IQR 2.75), $p = .309$, Figure 3).

3.3 Intestinal Chemokines

Intestinal lysates were normalized to total protein concentration. Sildenafil did not offer any significant improvements over vehicle with regard to the leukocyte chemoattractants RANTES, Mip1a, MCP, KC, or GCSF (Figure 4).

4. DISCUSSION

Sildenafil has previously been shown to confer intestinal protection when given prior to ischemic injury (5–7). Therefore, it seemed natural to expect that it would also provide protection when given following injury. Herein, we observed that sildenafil offered no improvements in mesenteric vascular perfusion, but did decrease the level of intestinal epithelial injury following ischemia. The highest dose of sildenafil was actually detrimental to animals as the 1000 mg/kg dose yielded 100% mortality at 24 hours following injury.

Protective effects have previously been appreciated in intestinal injury with pretreatment of sildenafil. In a study by Soydan et al., sildenafil pretreatment prevented ischemia induced impairment of acetylcholine responses which could lead to dysmotility and impairments in vascular tone (7). A 2005 study suggested that sildenafil releases endogenous mediators that work to increase nitric oxide production, which then activates guanylate cyclase to increase cyclic GMP levels. Elevations in these levels can then work to further vasodilate the end organ vascular bed (16). It is difficult to understand why sildenafil offered no improvements in mesenteric perfusion when used as a rescue agent following intestinal IR. Perhaps a longer period between ischemia and measurement of reperfusion (greater than 24 hours) would have yielded notable differences. However, other studies that we have performed in the past have shown measurable differences in both perfusion and histologic injury after only 24 hours of reperfusion (12, 13).

Previous studies have also suggested that the generation of oxygen free radicals interferes with cellular function through the disruption of ionic homeostasis (17). These radicals may exacerbate the injury seen following intestinal IR. Additionally, leukocytes have been

observed to infiltrate the injured intestine following injury (18), and therefore it would be expected that leukocyte chemoattractants would be elevated as well (19). However, herein, we did not see any alterations in common leukocyte chemoattractants following low to moderate dose sildenafil administration. This would suggest that the improvements observed in intestinal histology are more complex than simply limiting inflammation or leukocyte infiltration within the intestinal epithelium.

The discrepancy between sildenafil's ability to provide protection when given prior to injury versus its limited ability to facilitate rescue following injury is indeed perplexing. In our study we saw that sildenafil only decreased intestinal epithelial injury but did not appear to improve mesenteric perfusion. Given that the superior mesenteric artery was clamped for 60 minutes it is possible that vascular damage occurred in the mesenteric vessels. It is possible that this damage progressed beyond a state that would allow sildenafil to promote vasodilation and improved perfusion, although several other cellular and drug compounds have been shown to promote vasodilation in the post-ischemic period (12, 20). Therefore, it is likely something specific to the compound's bioavailability or to the length of time that it takes from drug delivery to onset of action.

Previous studies have also suggested that sildenafil has specific epithelial protective properties as well. A study of cardiomyocytes suggested that the preconditioning of these cells prior to hypoxia was able to decrease necrosis and apoptosis. When eNOS was pharmacologically inhibited or genetically ablated these effects were attenuated (21). Separate studies on acute lung injury have suggested that sildenafil can also decrease lung epithelial injury independent of vascular dilatation. In this model, sildenafil decreased epithelial leakiness, oxidative damage, and apoptosis (22). These data would confirm our findings of epithelial protection and suggest a role for sildenafil beyond its vasodilatory properties.

Multiple dose ranges from 0.01 mg/kg all the way up to 1000mg/kg were tested. 0.01, 1.0, and 10.0 mg/kg did not alter mesenteric perfusion or intestinal leukocyte infiltration, but did appear to limit intestinal epithelial damage. The typical dose for humans with erectile dysfunction is between 50–100 mg, which is approximately 0.7–1.5 mg/kg for a typical 70 kg male (23). This contrasts with the treatment of pulmonary hypertension in infants from the Sildenafil in Treatment-Naïve Children, Aged 1–17 Years, With Pulmonary Arterial Hypertension trials (STARTS-1 and STARTS-2) which used ranges from less than 1.5 mg/kg/day to greater than 7.5 mg/kg/day (24). We therefore felt that we had an appropriate range of therapy based on previous well-established human trials.

Given the lack of effectiveness of the lower doses to improve mesenteric perfusion, we also elected to try 100 and 1000 mg/kg, which would be considered supra-therapeutic, at nearly 10 to 100 times the doses used in the trials previously noted. 100 mg/kg had no effect compared to vehicle. It offered no improvement in perfusion, mucosal injury, or chemoattractant concentrations within the intestine. However, 1000 mg/kg resulted in cardiovascular collapse and prompt demise within the first 12–24 hours. Clearly this dose had a profound effect on homeostasis. It is unclear why the lower doses had no effect on the animal's perfusion, but a measurable difference in mucosal injury, while the largest dose had

a completely detrimental effect within the first 12–24 hours. It is likely that the distribution of specific isoforms of PDE5 are most pronounced in the lungs and central cardiovascular system, and less available in other end organ vascular beds (25). This would explain why sildenafil has an effect on lungs and erectile tissue, but minimal to no effect on the mesenteric vascular bed. However, this does not explain why sildenafil given prior to injury promotes improved intestinal blood flow while given following injury only appears to protect the epithelial tissue of the intestine.

This study may be limited by the animal model used to assess intestinal ischemia. In reality, most patients likely develop segmental areas of intestinal ischemia rather than pan-intestinal ischemia. Therefore, this model may be more severe than what is seen clinically. That being said, we feel that because it is more severe than what may be seen clinically, any benefit seen in the model should be translatable to the clinical setting.

5. CONCLUSIONS

Intestinal ischemia is a devastating clinical problem. Post-ischemic application of sildenafil does not appear to improve mesenteric perfusion but does appear to limit intestinal epithelial injury. This protection is not mediated by ameliorating leukocyte infiltration, as leukocyte chemoattractants were similar between vehicle and treated groups. Further studies are needed to explore the vascular and epithelial disparities associated with the post-ischemic application of sildenafil as a rescue agent following intestinal IR.

Disclosures:

TAM receives consultation fees from Scioto Biosciences and On-site LLC. This publication was made possible with support from: The National Institute of Diabetes and Digestive and Kidney Disease of the National Institutes of Health under Award Number K08DK113226 Koret Foundation Indiana University Department of Surgery

6. REFERENCES

1. Chang RW, Chang JB and Longo WE: Update in management of mesenteric ischemia. *World J Gastroenterol* 12(20):3243–7, 2006. [PubMed: 16718846]
2. Schoots IG, Koffeman GI, Legemate DA, Levi M and van Gulik TM: Systematic review of survival after acute mesenteric ischaemia according to disease aetiology. *Br J Surg* 91(1):17–27, 2004. [PubMed: 14716789]
3. Mehall JR, Chandler JC, Mehall RL, Jackson RJ, Wagner CW and Smith SD: Management of typical and atypical intestinal malrotation. *J Pediatr Surg* 37(8):1169–72, 2002. [PubMed: 12149695]
4. Jeican II, Ichim G and Gheban D: Intestinal ischemia in neonates and children. *Clujul Med* 89(3): 347–51, 2016. [PubMed: 27547054]
5. Inan M, Uz YH, Kizilay G, Topcu-Tarlacalisir Y, Sapmaz-Metin M, Akpolat M and Aydogdu N: Protective effect of sildenafil on liver injury induced by intestinal ischemia/reperfusion. *J Pediatr Surg* 48(8):1707–15, 2013. [PubMed: 23932610]
6. Soydan G, Cekic EG and Tuncer M: Endothelial dysfunction in the mesenteric artery and disturbed nonadrenergic noncholinergic relaxation of the ileum due to intestinal ischemia-reperfusion can be prevented by sildenafil. *Pharmacology* 84(2):61–7, 2009. [PubMed: 19546605]
7. Soydan G, Sokmensuer C, Kilinc K and Tuncer M: The effects of sildenafil on the functional and structural changes of ileum induced by intestinal ischemia-reperfusion in rats. *Eur J Pharmacol* 610(1–3):87–92, 2009. [PubMed: 19303867]

8. Archer SL, Huang JM, Hampl V, Nelson DP, Shultz PJ and Weir EK: Nitric oxide and cGMP cause vasorelaxation by activation of a charybdotoxin-sensitive K channel by cGMP-dependent protein kinase. *Proc Natl Acad Sci U S A* 91(16):7583–7, 1994. [PubMed: 7519783]
9. Szabo A, Vollmar B, Boros M and Menger MD: Gender differences in ischemia-reperfusion-induced microcirculatory and epithelial dysfunctions in the small intestine. *Life Sci* 78(26):3058–65, 2006. [PubMed: 16413039]
10. Hundscheid IHR, Schellekens D, Grootjans J, Derikx JPM, Buurman WA, Dejong CHC and Lenaerts K: Females Are More Resistant to Ischemia-Reperfusion-induced Intestinal Injury Than Males: A Human Study. *Ann Surg*, 2018.
11. Committee for the Update of the Guide for the Care and Use of Laboratory Animals IFLAR, Division on Earth and Life Studies: Guide for the Care and Use of Laboratory Animals. The National Academies Press, Washington, DC, p.^pp. 220, 2011.
12. Jensen AR, Doster DL, Hunsberger EB, Manning MM, Stokes SM, Barwinska D, March KL, Yoder MC and Markel TA: Human Adipose Stromal Cells Increase Survival and Mesenteric Perfusion Following Intestinal Ischemia and Reperfusion Injury. *Shock* 46(1):75–82, 2016. [PubMed: 26796571]
13. Jensen AR, Manning MM, Khaneki S, Drucker NA and Markel TA: Harvest tissue source does not alter the protective power of stromal cell therapy after intestinal ischemia and reperfusion injury. *J Surg Res* 204(2):361–70, 2016. [PubMed: 27565072]
14. Watkins DJ, Zhou Y, Matthews MA, Chen L and Besner GE: HB-EGF augments the ability of mesenchymal stem cells to attenuate intestinal injury. *J Pediatr Surg* 49(6):938–44; discussion 944, 2014. [PubMed: 24888839]
15. Markel TA, Crafts TD, Jensen AR, Hunsberger EB and Yoder MC: Human mesenchymal stromal cells decrease mortality after intestinal ischemia and reperfusion injury. *J Surg Res* 199(1):56–66, 2015. [PubMed: 26219205]
16. Kukreja RC, Salloum F, Das A, Ockaili R, Yin C, Bremer YA, Fisher PW, Wittkamp M, Hawkins J, Chou E, et al.: Pharmacological preconditioning with sildenafil: Basic mechanisms and clinical implications. *Vascul Pharmacol* 42(5–6):219–32, 2005. [PubMed: 15922255]
17. Takahashi A, Tomomasa T, Kaneko H, Watanabe T, Tabata M, Morikawa H, Tsuchida Y and Kuwano H: Intestinal motility in an in vivo rat model of intestinal ischemia-reperfusion with special reference to the effects of nitric oxide on the motility changes. *J Pediatr Gastroenterol Nutr* 33(3):283–8, 2001. [PubMed: 11593123]
18. Hashimoto S, Honda M, Takeichi T, Sakisaka M, Narita Y, Yoshii D, Uto K, Sakamoto S and Inomata Y: Intravital imaging of neutrophil recruitment in intestinal ischemia-reperfusion injury. *Biochem Biophys Res Commun* 495(3):2296–2302, 2018. [PubMed: 29287721]
19. Jawa RS, Quist E, Boyer CW, Shostrom VK and Mercer DW: Mesenteric ischemia-reperfusion injury up-regulates certain CC, CXC, and XC chemokines and results in multi-organ injury in a time-dependent manner. *Eur Cytokine Netw* 24(4):148–56, 2013. [PubMed: 24589386]
20. Drucker NA, Jensen AR, Te Winkel JP and Markel TA: Hydrogen Sulfide Donor GYY4137 Acts Through Endothelial Nitric Oxide to Protect Intestine in Murine Models of Necrotizing Enterocolitis and Intestinal Ischemia. *J Surg Res* 234:294–302, 2019. [PubMed: 30527488]
21. Das A, Xi L and Kukreja RC: Phosphodiesterase-5 inhibitor sildenafil preconditions adult cardiac myocytes against necrosis and apoptosis. Essential role of nitric oxide signaling. *J Biol Chem* 280(13):12944–55, 2005. [PubMed: 15668244]
22. Kosutova P, Mikolka P, Balentova S, Kolomaznik M, Adamkov M, Mokry J, Calkovska A and Mokra D: Effects of phosphodiesterase 5 inhibitor sildenafil on the respiratory parameters, inflammation and apoptosis in a saline lavage-induced model of acute lung injury. *J Physiol Pharmacol* 69(5), 2018.
23. Loran OB, Stroberg P, Lee SW, Park NC, Kim SW, Tseng LJ, Collins S and Stecher VJ: Sildenafil citrate 100 mg starting dose in men with erectile dysfunction in an international, double-blind, placebo-controlled study: effect on the sexual experience and reducing feelings of anxiety about the next intercourse attempt. *J Sex Med* 6(10):2826–35, 2009. [PubMed: 19817982]
24. De A, Shah P, Szmuszkovicz J, Bhombal S, Azen S and Kato RM: A Retrospective Review of Infants Receiving Sildenafil. *J Pediatr Pharmacol Ther* 23(2):100–105, 2018. [PubMed: 29720910]

25. Lin CS: Tissue expression, distribution, and regulation of PDE5. *Int J Impot Res* 16 Suppl 1:S8–S10, 2004. [PubMed: 15224128]

Author Manuscript

Author Manuscript

Author Manuscript

Author Manuscript

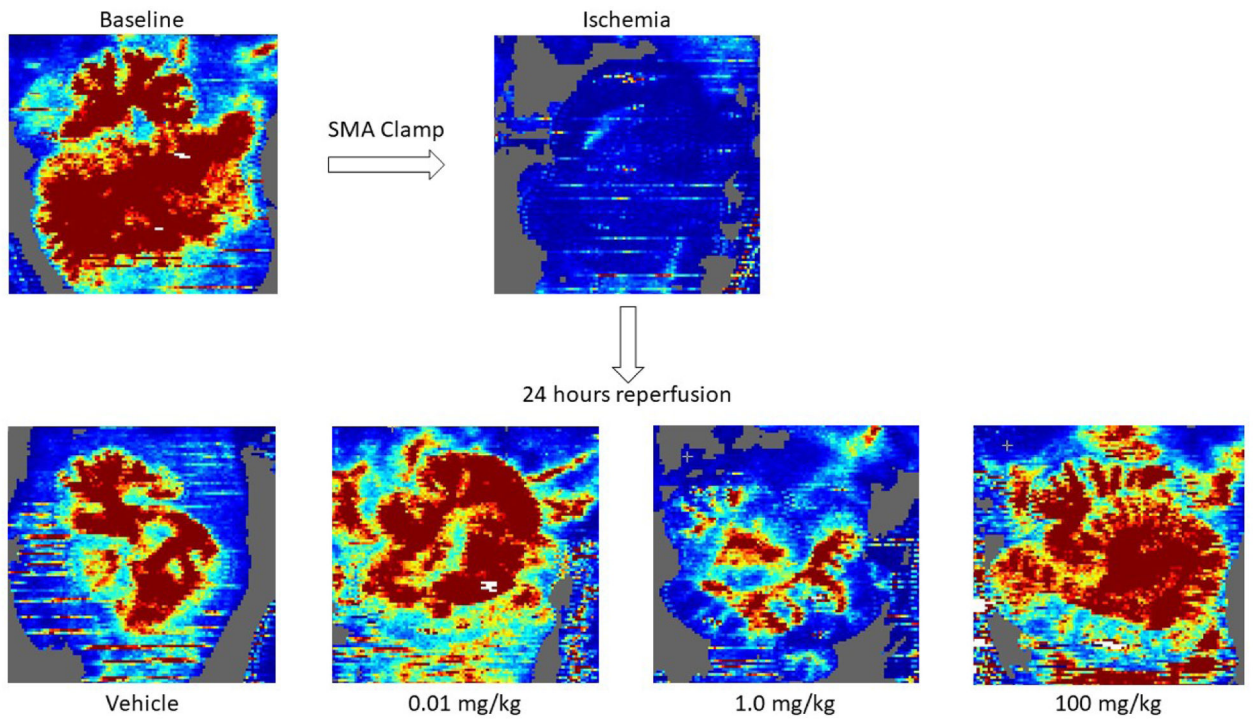


Figure 1: Mesenteric Perfusion.

Representative Laser Doppler images assessing mesenteric perfusion with varying doses of sildenafil.

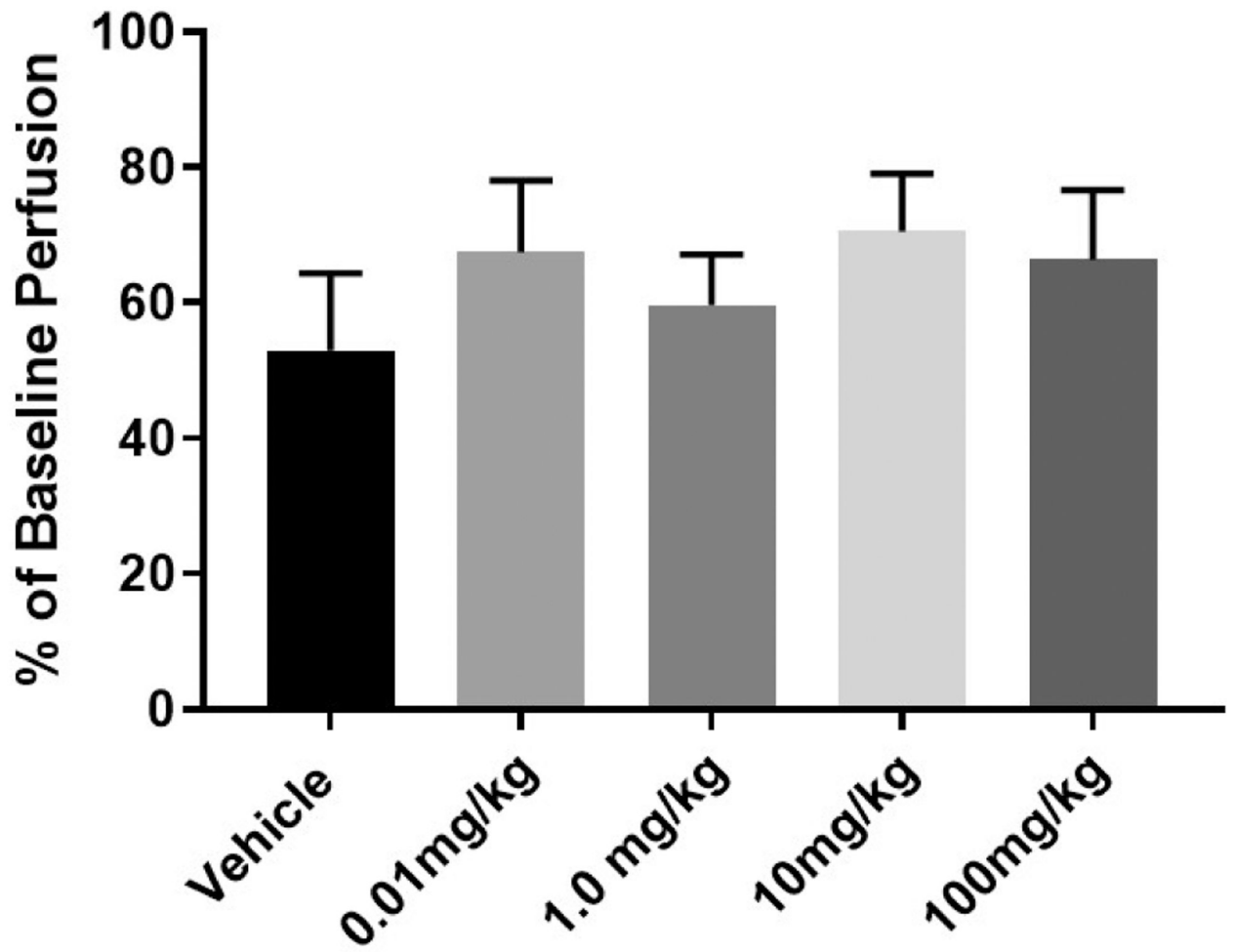


Figure 2: Sildenafil Did Not Improve Mesenteric Perfusion.

Post-ischemic mesenteric perfusion was not altered with the administration of sildenafil.

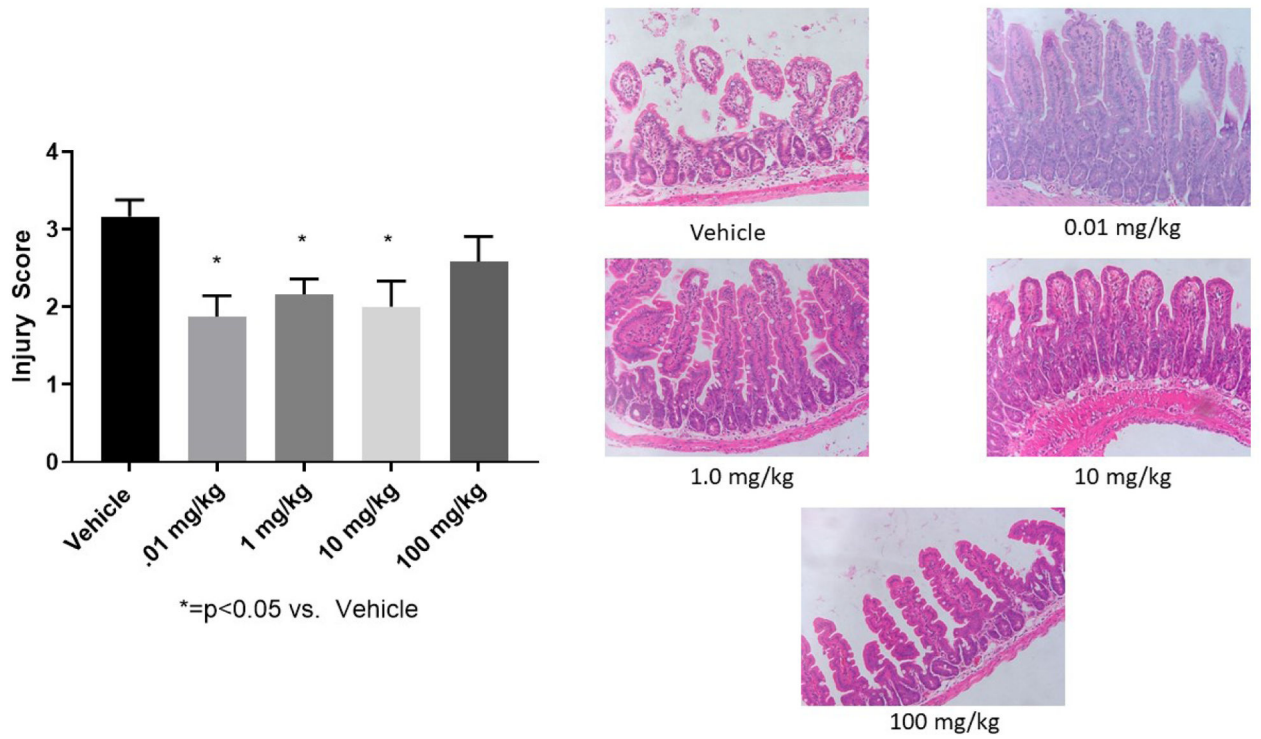


Figure 3: Intestinal Epithelial Injury.

Intestinal epithelium had significantly less injury for the majority of sildenafil doses tested compared to vehicle. The 100mg/kg dose showed no difference compared to vehicle (*=p<0.05 versus vehicle)

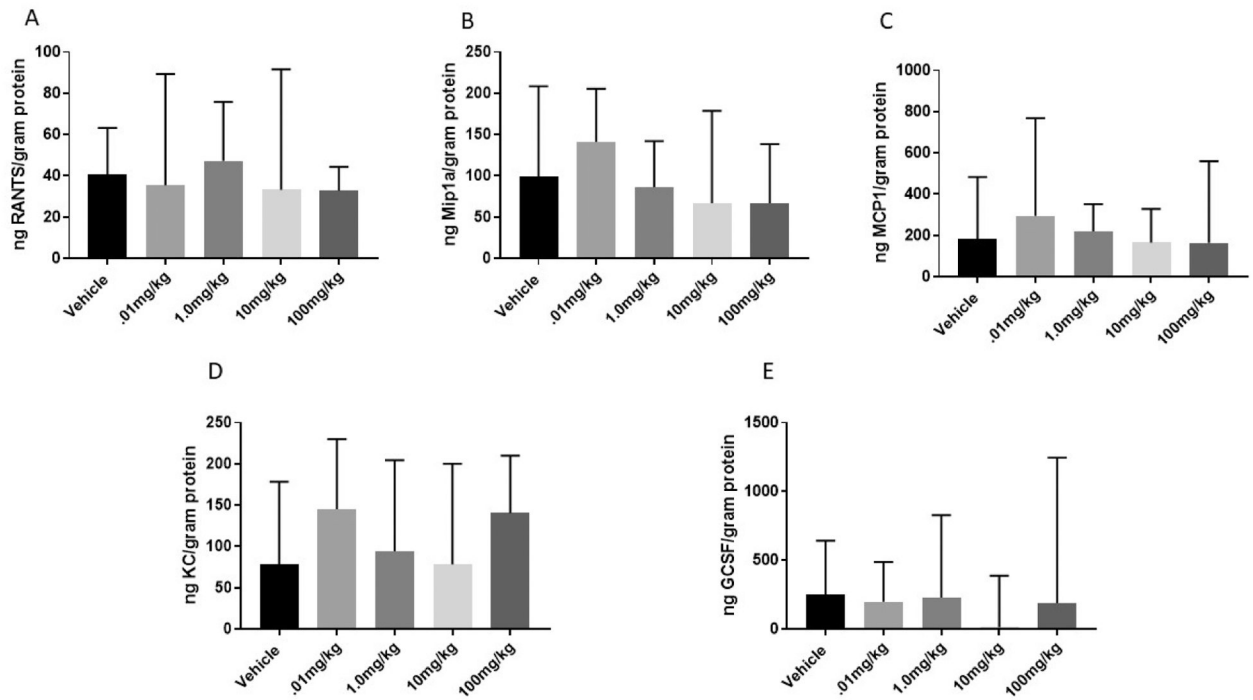


Figure 4. Leukocyte Chemokines.

Intestinal levels of (A) RANTES, (B) Mip1a, (C) MCP, (D) KC, and (E) GCSF were not significantly different between vehicle and sildenafil treated groups following intestinal IR injury.

Table 1:

Post-ischemic Mortality Associated with Sildenafil Administration

	Survived	Died Within 24h	% Mortality
Vehicle	7	1	14.3%
0.01 mg/kg	8	8	0 %
1 mg/kg	8	8	0 %
10 mg/kg	8	8	0 %
100 mg/kg	8	8	0 %
1000 mg/kg	0	8	100%

Author Manuscript

Author Manuscript

Author Manuscript

Author Manuscript