



Contents lists available at ScienceDirect

Indian Pacing and Electrophysiology Journal

journal homepage: www.elsevier.com/locate/IPEJ

Mechanical suppression of premature ventricular complexes during catheter ablation procedures

Rahul Jain ^{a, c}, Mamta Barmada ^{c, d, *}, Rohit Jain ^b, Jonathan Shirazi ^a, John M. Miller ^a^a Department of Cardiology, Indiana University School of Medicine, Indianapolis, IN, USA^b Pennsylvania State Health Milton S. Hershey Medical Center, Pennsylvania, USA^c Roudebush Veterans Affairs Medical Center, Indianapolis, IN, USA^d Indiana University Health, Indianapolis, IN, USA

ARTICLE INFO

Article history:

Received 11 August 2020

Received in revised form

23 October 2020

Accepted 5 November 2020

Available online 19 November 2020

Keywords:

Premature ventricular complex

Ventricular arrhythmias

Radiofrequency ablation

Mechanical suppression

ABSTRACT

Introduction: Mechanical suppression of premature ventricular complexes (PVCs) is not a well-known observation. We retrospectively reviewed this phenomenon in the Ventricular Arrhythmia (VA) ablation procedures performed at Richard L. Roudebush Veterans Health Administration (VHA) center.

Methods: Data from 40 consecutive patients who underwent VA ablation at VHA, Indianapolis, IN, with 44 VA was included in the study. Demographic and electrophysiological parameter data was collected.

Results: Overall the mean age of the population was 64 ± 11 years. The phenomenon of mechanical suppression was seen in 11 PVCs. The mean age was 59 ± 15 years in the group in which mechanical suppression was seen. Of the 11 cases, the site of earliest activation was seen in the coronary sinus in 8 and in the pulmonary artery in 3. In one case catheter ablation was not performed because of proximity to the left coronary artery system. However, sustained pressure at the site with earliest electrograms (-35 ms) and 95% pacematch resulted in long-term suppression of PVCs. In the cases in which mechanical suppression was seen, there was a statistically significant reduction in PVC burden compared to pre ablation PVC load ($1.1\% \pm 1.50\%$ (post ablation) versus $24.04\% \pm 13.07\%$ (pre ablation) versus $p < 0.05$). In all the 11 cases the site of mechanical suppression was also the site with earliest electrograms.

Conclusion: This case series illustrates phenomenon of mechanical suppression of PVCs as an indication for good site for successful ablation in unique veteran patient population.

Copyright © 2021, Indian Heart Rhythm Society. Production and hosting by Elsevier B.V. This is an open access article under the CC BY-NC-ND license (<http://creativecommons.org/licenses/by-nc-nd/4.0/>).

1. Introduction

It has long been recognized that mechanical forces on the myocardium can produce electrical responses. Bainbridge in 1915 [1] showed the phenomenon of mechanoelectric feedback in anaesthetized dogs. The heart rate was increased when injecting fluids into the right atrium distended the right atrium. Similar observations have been made in humans [2–5]. Conversely clinical electrophysiologists have observed mechanical forces on myocardium that inhibit impulse formation or conduction (“catheter induced trauma” or “catheter bump”), resulting in suppression of

arrhythmias. This phenomenon has been reported in the atrio-ventricular (AV) node [6], the His bundle [7], the right bundle branch [8], the atrium [9] and a case report in the ventricle [10]. In case of accessory pathways catheter induced trauma has shown negative effects on the results of accessory pathway ablation success rate [11].

The purpose of the current study is to report our observation of this phenomenon during catheter mapping and ablation of ventricular arrhythmia (VA), including ventricular tachycardia (VT) and premature ventricular complexes (PVC).

2. Study population

The study population included 40 patients who underwent cardiac electrophysiology (EP) study for evaluation and treatment of VA/PVCs at Roudebush Veterans Affairs Hospital, Indianapolis, IN from April 2015 until December 2018. In each case, the site of origin of the arrhythmia was validated by either successful ablation and/

Abbreviations: CS, coronary sinus; PVC, Premature ventricular complex; VA, Ventricular arrhythmia; VT, Ventricular tachycardia; EP, Electrophysiology; LVEF, Left ventricular ejection fraction.

*Corresponding author. Indiana University Health, Indianapolis, IN 46217, USA.

E-mail address: mbarmeda@iuhealth.org (M. Barmada).

Peer review under responsibility of Indian Heart Rhythm Society.

<https://doi.org/10.1016/j.ipej.2020.11.017>

0972-6292/Copyright © 2021, Indian Heart Rhythm Society. Production and hosting by Elsevier B.V. This is an open access article under the CC BY-NC-ND license (<http://creativecommons.org/licenses/by-nc-nd/4.0/>).

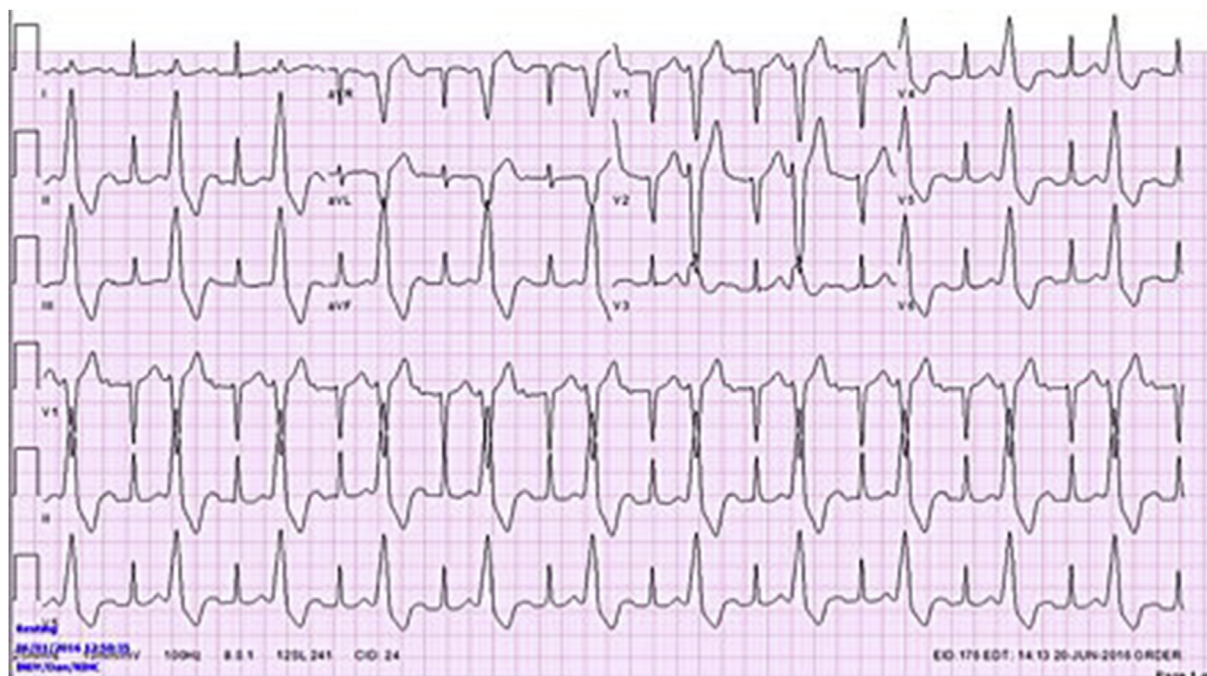


Fig. 1A. Twelve lead electrocardiogram showing left bundle branch block, inferior axis PVC in a bigeminal pattern.

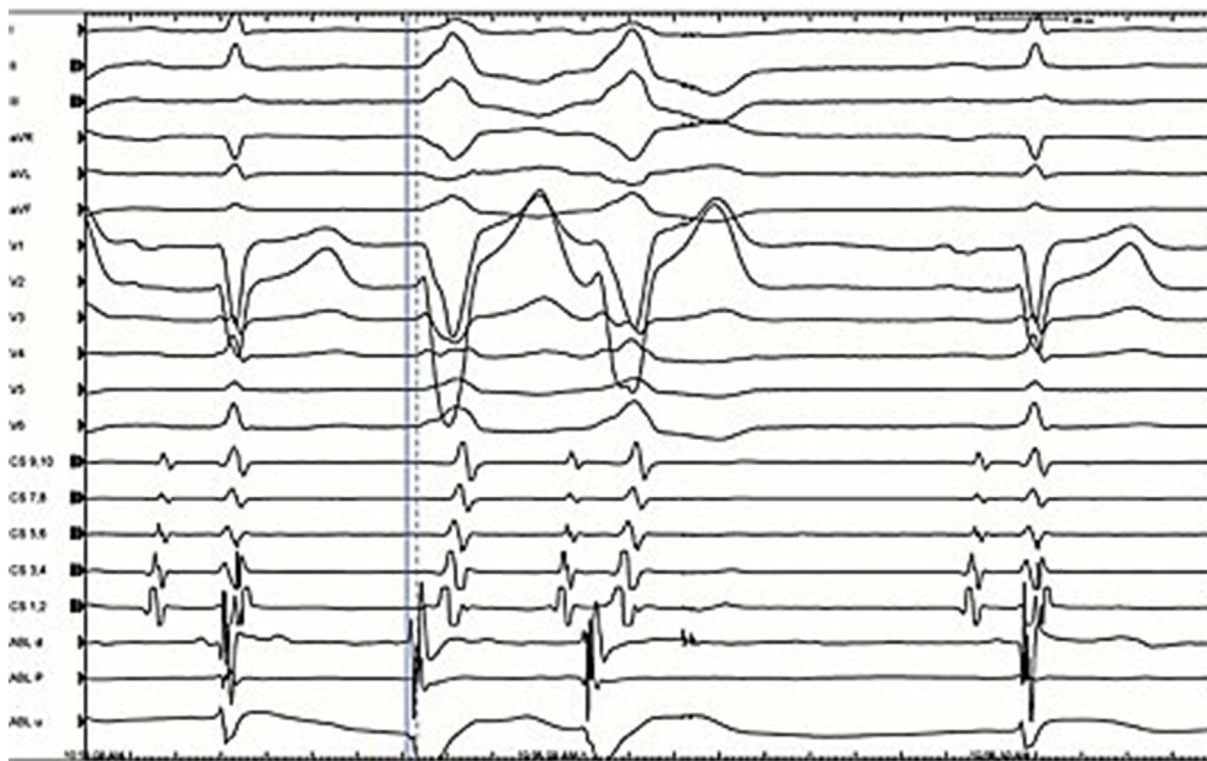

Fig. 1B. Fig. 1 B: Site just below pulmonary valve at septal RVOT had electrograms preceding PVC QRS by 22 ms.

or earliest electrograms with or without >95% pacematch. Of these, 4 had more than one morphology of PVC.

All patients had an echocardiogram with left ventricular ejection fraction (LVEF) estimation prior to the EP study. All but seven had an ambulatory (Holter) monitor done prior to the procedure for

quantification of PVC burden. Of the 7 patients who did not have a Holter monitor, 6 had ablation for VT and one for PVC-induced ventricular fibrillation. A post PVC ablation Holter was not done in 9 patients, of whom 6 did not have pre-procedure PVC quantification data. All patients were symptomatic from their arrhythmia.

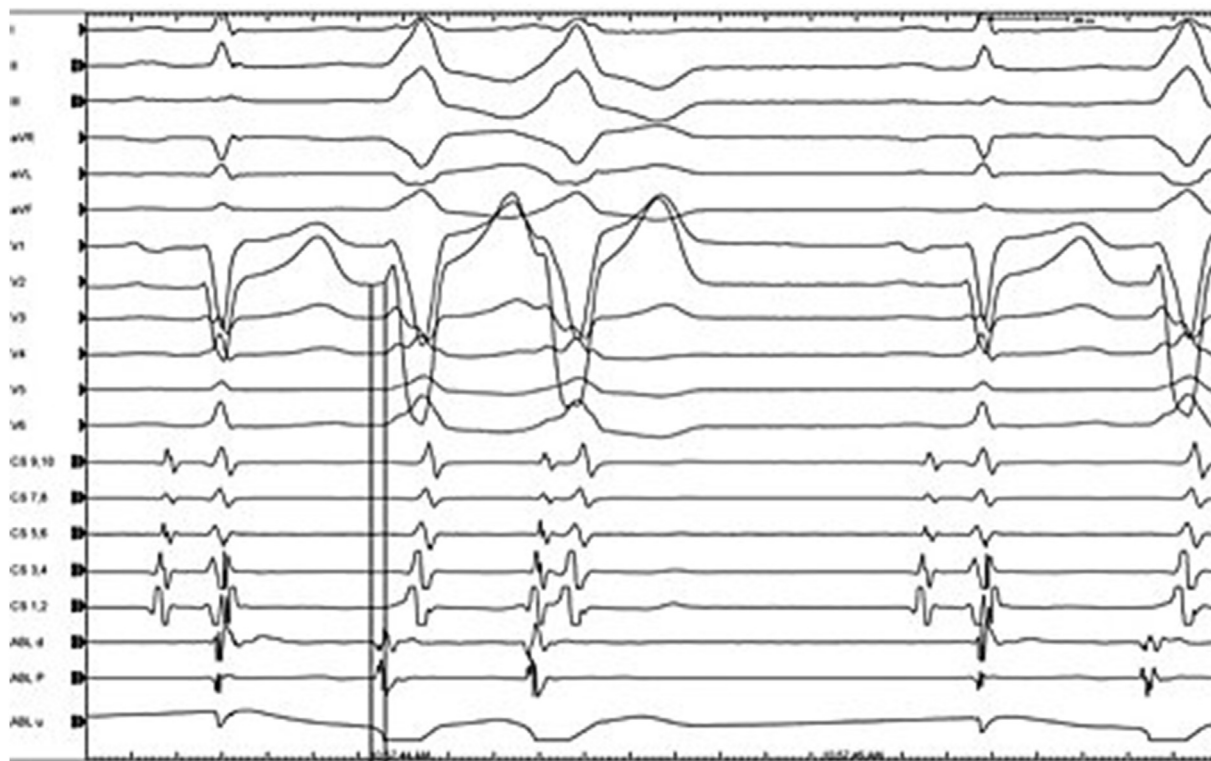


Fig. 1C. In pulmonary artery the site of earliest activation had electrograms preceding PVC QRS by 35 ms. CARTO Map showing the location of the ablation catheter. (Adapted with permission from Springer Nature: Springer, Cham [Cardiac Electrophysiology by Natale A., Wang P., Al-Ahmad A., Estes N. [copyright] (2020) [21]

3. Electrophysiological studies

The electrophysiological study was performed in patients in the fasting state and all antiarrhythmic medications were stopped at least 5 half-lives prior to the procedure (2–6 weeks in patients on amiodarone). Conscious sedation or general anesthesia was used based on patient's comfort level. The recording system was CardioLab™ (General Electric Medical Systems, Milwaukee, WI). A 3.5 mm ablation catheter (ThermoCool™, contact force sensing, Biosense-Webster, Irvine, CA, USA) was used for mapping and ablation. In selected cases a 7F PentaRay™ (Biosense-Webster, Irvine, CA, USA) catheter was also used for mapping. Three-dimensional activation mapping of VA was performed using the CARTO system (Biosense-Webster, Irvine, CA, USA). An 8Fr phased array, intracardiac echocardiography catheter (SOUNDSTAR, Biosense-Webster, Irvine, CA, USA) was used in all cases to assist in visualization of intracardiac structures. A 6Fr deflectable quadripolar catheter was placed in the right ventricle (RV) apical septum and another at the His position (both with 5 mm electrode spacing). A deflectable decapolar catheter was placed in the coronary sinus (CS). Surface electrocardiographic (ECG) leads were placed in the standard positions [12].

4. Ablation strategy

The earliest QRS onset on the simultaneously recorded 12-lead ECG was used as the reference for activation mapping. Activation timing was measured from the sharpest ventricular deflection of the catheter/electrode of interest to the VA QRS onset on the surface ECG. Pacemapping was performed by pacing at twice the capture threshold with pulse duration of 5 ms and a cycle length that was 80% of the R-R interval (in case of VT) or at the sinus complex-PVC

interval in a PVC only case. After insertion of diagnostic catheters, if an area of early activation and a pacematch of at least 10/12 surface ECG leads, > 95% on PASO [CARTO pace matching software] was observed in the CS, the ablation catheter was moved to that area to begin activation mapping. Otherwise, activation mapping was started in the RV, RV outflow tract (RVOT) and then moved to the aortic root, left ventricular (LV) outflow region, and LV body if no area of early activation was noted in the RV [12]. Heparin was administered intravenously as boluses. (ACT 250-300 s). Sites with earliest electrograms (more than 15 ms prior to VA QRS onset) and excellent pacematch (>90%) were used as sites for ablation. A coronary arteriogram was done as needed to evaluate proximity to a major coronary artery. Radiofrequency ablation (RF) ablation was carried out using an externally irrigated force-sensing catheter using 20–50 W. Mechanical suppression was defined as $\geq 80\%$ reduction in PVC burden without ablation seen transiently during the procedure or persisted post procedure too.

All patients had a post-operative ECG and were hospitalized overnight while monitored on telemetry. Antiarrhythmic drugs, (except beta blockers in patients with low EF), were not restarted at the time of discharge. No immediate or at the time of discharge, procedure-related complications were seen.

5. Statistical analysis

Variables were tested for normal distribution using Shapiro–Wilk normality test. Variables which were not normally distributed were tested using non-parametric methods. Mann-Whitney test was used to test difference between two independent groups. Medians and inter-quartile ranges (IQR, for skewness) were calculated for outcome variables if needed.

Continuous data are expressed as mean \pm SD, or median (IQR)

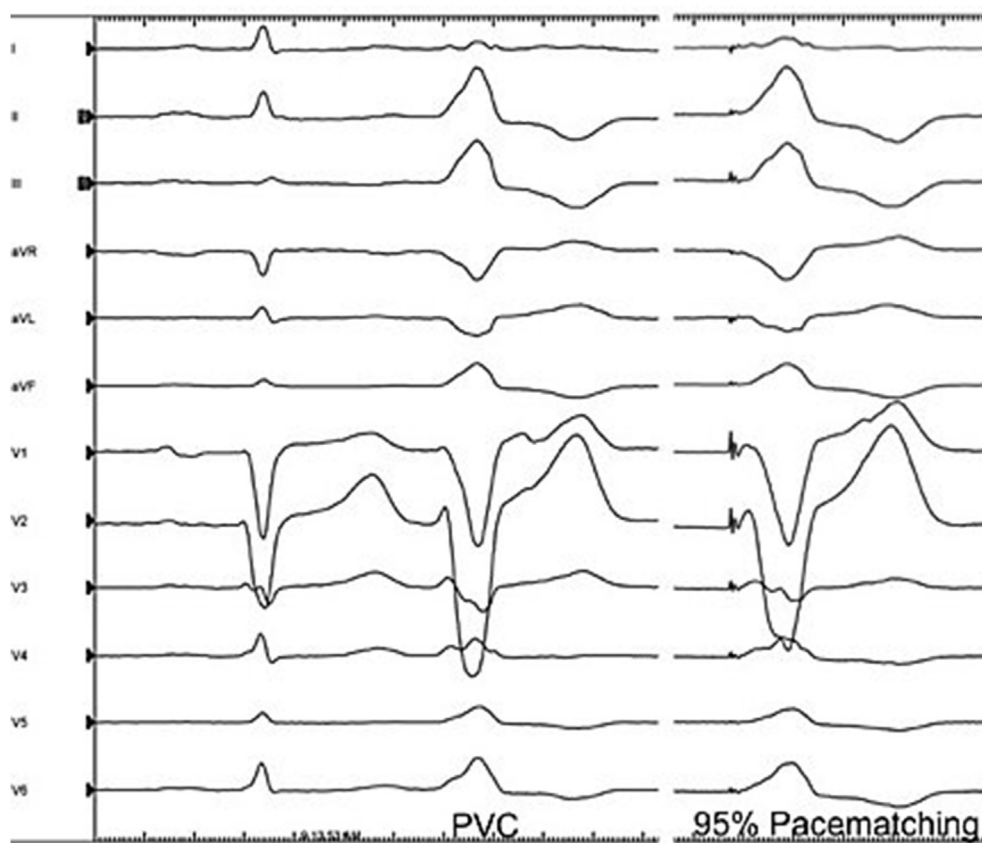


Fig. 1D. Pace mapping at the site of earliest activation in PA had 95% pace match. (Adapted with permission from Springer Nature: Springer, Cham [Cardiac Electrophysiology by Natale A., Wang P., Al-Ahmad A., Estes N. [copyright] (2020) [21]

when normality was suspect. Means were compared by use of Student's *t*-test for paired data and 1-way ANOVA when appropriate. Statistical analysis was performed with the STATA/IC 13.010.0 statistical package. A value of $p < 0.05$ was considered as significant.

6. Results

A total of 44 PVCs/VT in 40 patients were studied with patient's mean age of 64 ± 11 years. There were 37 men and 3 women in the study population. Sites of successful ablation was distributed as following: 11 epicardial (10 were mapped and ablated from within different venous structures accessed through CS, one through pericardial space), 6 in aortic sinuses of Valsalva, 3 parahisian, 5 papillary muscle, 1 aortic mitral continuity, 7 septal RV or LV, 6 endocardial LV besides septum, 2 RVOT and 3 in pulmonary artery (PA). In two cases no ablation was performed because the earliest site of activation during PVC was too close (<4 mm) to a major coronary artery. In one of these cases transient pressure at the earliest site resulted in suppression of PVCs. After transient pressure when the catheter was moved far back from the site, PVCs returned. However, sustained pressure with strong catheter deflection for 45 s at the earliest site resulted in a marked decrease in PVC prevalence acutely and during follow-up (reduction from 38% to $<4\%$ PVC burden on Holter). In the second case in which ablation was not done, the site with earliest electrograms had a pacematch of 95%. The earliest electrogram was seen on ablation catheter placed in the anterior interventricular vein.

Suppression of PVC was seen in 11 PVCs out of 44 VA cases. None of the 11 cases had sustained VT. In one as described above, long

term suppression of PVCs occurred after sustained pressure and friction rub was applied at the site with earliest electrograms and $>95\%$ pacematch. The reduction can be coincidental but an observation that cannot be ignored. However in the other 10 patients ablation was required at the site where transient suppression was seen. In these 10 cases, the sites where transient suppression was seen was also the site for successful ablation. In three patients the site for mechanical suppression was seen in PA [13].

In one of the PVCs ablated in the PA, the QRS duration of the PVC was 165 ms, with left bundle branch block, inferior axis (Fig. 1 A). [13] An electrogram from a site just below the pulmonary valve was 22 ms pre-QRS with a 85–92% pacematch (Fig. 1B). Earliest activation (35 ms pre-QRS) was seen at a site above the pulmonary valve, within the PA. (Fig. 1C), with a 95% pacematch (Fig. 1 D). Pressure from the ablation catheter at this site resulted in suppression of PVCs (Fig. 1E). No suppression of PVC was seen with similar catheter pressure at other sites. RF application at this site resulted in complete elimination of PVCs.

In 8 cases, the sites at which earliest electrograms were seen and also the site with transient suppression by catheter pressure were within different venous structures accessed through CS (Table 1). In one case the site was approached through the middle cardiac vein (MCV) (Fig. 2A–C). Early electrograms (32 ms early) were noted in it with $>95\%$ pacematch. A CS venogram and right coronary artery angiogram were done before ablation in the MCV, that resulted in reduction of PVC load from 20% to 1% in a follow-up holter (Table 1).

In another representative case the PVC site of origin was accessed through the great cardiac vein. This was in a 75 year old male with a history of myxomatous mitral valve (MV) disease, severe mitral regurgitation from a flail P2 segment with a

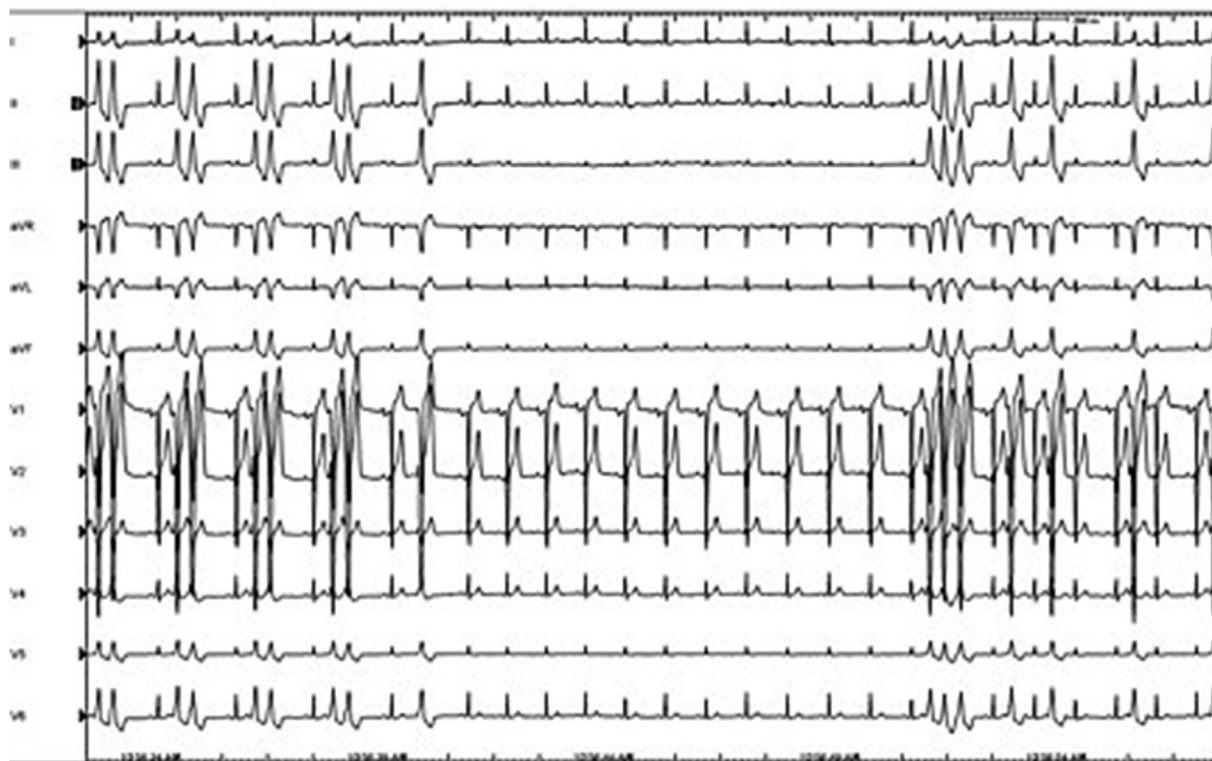


Fig. 1E. Pressure from ablation catheter at the site of earliest activation in pulmonary artery resulted in complete suppression of PVCs. The catheter was pulled back from the site with return of the PVCs. (Adapted with permission from Springer Nature: Springer, Cham [Cardiac Electrophysiology by Natale A., Wang P., Al-Ahmad A., Estes N. [copyright] (2020) [21]

Table 1
Demographics and electrophysiological parameters.

Age	Gender	Pre Ablation PVC burden	Post Ablation PVC burden	Pre Procedure LVEF	Post procedure LVEF	Earliest activation time (ms)	Site of successful ablation
58	Male	50%	0%	30%	45%	13	GCV
66	Male	39.5%	0%	28%	—	26	junction of AIV and GCV
75	Male	18%	2%	25%	66%	8	junction of AIV and GCV
69	Male	20%	1%	55%	55%	20	proximal MCV
67	Male	8.9%	0%	49%	50%	12	junction of AIV and GCV
46	Male	27%	5%	55%	55%	36	CS but ablation not done due to proximity to coronaries
68	Male	17.80%	0%	32.50%	33%	28	junction of AIV and GCV
72	Male	31%	—	35%	—	16	GCV
61	Male	25000/24 h	<1%	55%	—	35	Pulmonary artery
34	Male	13%	1%	61%	60%	22	Pulmonary artery
30	Male	22.2%	1%	63%	63%	9	Pulmonary artery

Abbreviations: PVC – premature ventricular complex; LVEF – left ventricular ejection fraction; GCV – great cardiac vein; AIV – anterior interventricular vein; MCV – middle cardiac vein; CS – coronary sinus.

bioprosthetic MV replacement. He initially presented with symptomatic PVC burden of 26% with left ventricular ejection fraction of 40–45%. Ablation was performed at the right-left aortic sinus commissure with electrograms that were 22 ms pre-QRS. His follow up holter showed a PVC load reduction to <1%. However, 6 months later he returned with symptomatic PVC burden of 18%. The site with earliest electrograms (18 ms pre-QRS) was noted at the junction of the great cardiac vein and anterior interventricular vein. The PVC morphology was different than the first visit. Mapping in aortic sinuses of Valsalva did not show any earlier electrograms. Pressure at the site in coronary sinus resulted in transient suppression of PVC (Fig. 3 A and 3 B). Ablation at the same site resulted in reduction of PVC burden from 18% to 2% in a follow-up Holter.

In cases in which mechanical suppression of PVC was seen, a statistically significant reduction in PVC burden was observed compared to preablation PVC load (1.1% ± 1.50% versus 24.04% ± 13.07% versus p < 0.05). In all cases mechanical suppression was seen with stable catheter position and not during catheter movement. In the second group too there was statistically significant reduction in PVC load.

Post procedure reduction in PVC load was more in mechanical suppression group compared to the other group. Mean post procedure PVC load in cases without mechanical suppression was 6 ± 6.53% compared to 5 ± 8.67% in those with mechanical suppression (p = non significant). Procedure time (193 ± 98.9 min versus 226 ± 97.43 min) and fluoro time (20 ± 12.11 min versus

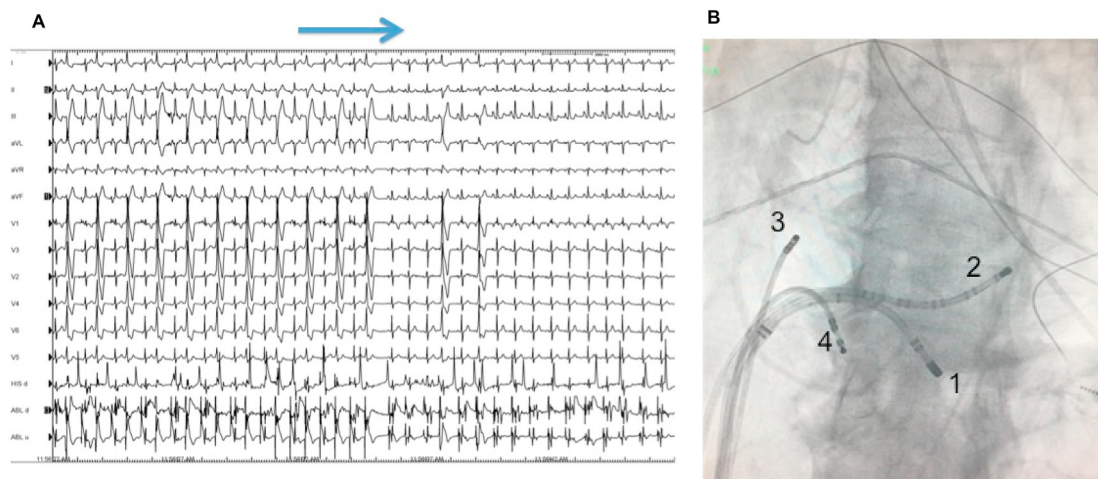


Fig. 2. A: Figure shows at the site with earliest electrograms, pressure with ablation catheter resulted in suppression of PVCs. This site was located in middle cardiac vein. **B:** Left anterior oblique fluoroscopic vein; ablation catheter is in the middle cardiac vein. It can also be appreciated a JR5 catheter is in the right coronary artery and right coronary angiogram is done.

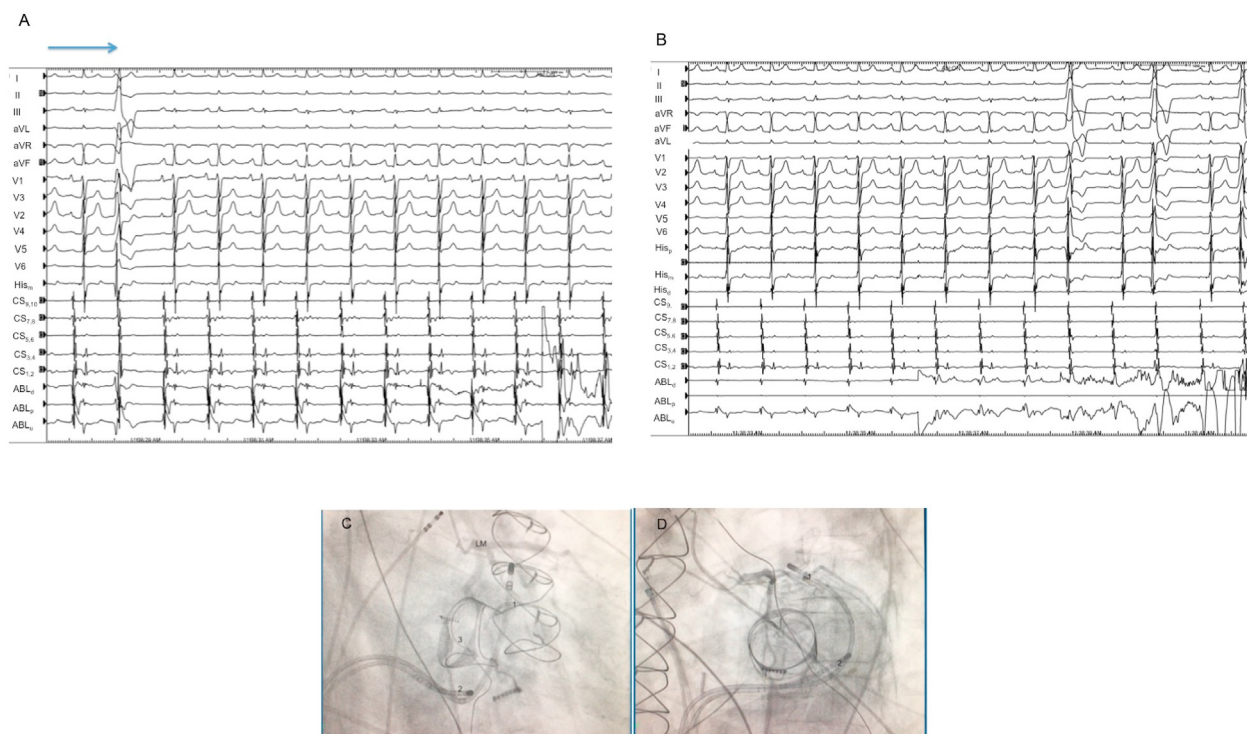


Fig. 3. 3A: Shows mechanical suppression of PVC at the site with earliest electrograms. Radiofrequency energy was given at the same site. **3B:** Application of radiofrequency application at this site resulted in flurry of PVCs. **Fig. 3C:** Right anterior oblique fluoroscopic view of left coronary angiogram showing the relationship of the ablation catheter to the left coronary system. The position of the ablation catheter is where suppression of PVCs was seen. **Fig. 3D** Left anterior oblique fluoroscopic view of left coronary angiogram.

23 ± 16.39 min) was lower in the mechanical suppression group compared to the other group. Fluoroscopy machines are set at 3 frames/sec in the EP lab. However these findings were not statistically significant. Mechanical suppression was not seen with pentary catheter.

7. Discussion

In this retrospective study involving 40 consecutive patients undergoing radiofrequency ablation for VA/PVCs, we identified catheter induced mechanical suppression in 11 (23.9%) PVC cases.

To our knowledge this series of mechanical suppression of PVC is the largest reported to date. Catheter induced trauma and mechanical suppression has been shown repeatedly in tachycardias involving accessory pathways [14–20]. In accessory pathways it has been shown that the catheter trauma is site-specific and affects the course and the success rate of ablation procedure [11]. Catheter-induced trauma is commonly seen in the electrophysiology laboratory during catheter manipulation with “bumping” of the right bundle causing transient right bundle branch block. However, there is little information on the effects of catheter-induced trauma in PVC cases.

In the current study, we observed catheter-induced suppression of PVCs when earliest electrograms were seen in the CS. In one case out of 44 VA, in which pericardial access was used for epicardial mapping, this phenomenon was not seen, but it was observed in all three cases in which the site of successful ablation was in the PA. This likely indicates a very superficial location of the arrhythmogenic focus resulting in mechanical suppression compared to other sites where the focus might be deep intramuscular. Alternately, the sites at which catheter-induced suppression was observed were in confined spaces (coronary veins, PA) where significant catheter pressure could be applied (as opposed to many endocardial RV or LV sites where contact is not as firm).

These observations have important clinical implications. First, during PVC ablation close observation of the ongoing rhythm is needed to note any catheter induced mechanical suppression. This may indicate that the catheter is located at site at which ablation will be successful. In only one case we saw long term reduction in PVC load with sustained pressure and friction rub with the ablation catheter. Prolonged catheter pressure was not attempted in other cases (rather, ablation was used).

Secondly, when mechanical suppression occurs one should evaluate the electrograms at the site and perform pace matching before moving the catheter to other sites, to corroborate whether this might be a reasonable site for ablation. In our experience (more so with mapping in ventricular chambers rather than PA or CS or its branches), large movements of catheters may apply adequate pressure to transiently block an accessory pathway or VA, but when the operator first notices this, the catheter at that time may be in a different location than it was when block occurred.

We didn't see any statistically significant difference in procedure time, fluoroscopy time or magnitude of PVC load reduction between the two groups, but this finding could be secondary to small sample size.

There is almost 25% mechanical suppression seen in the study (11 of 44 PVCs). This higher number could be secondary to the unique patient population and site of origin of PVCs.

7.1. Limitations

The observation, that suppression of PVC by catheter tip pressure, was made in a small sample size of patients. The duration and amount of catheter tip pressure was not prospectively chosen or titrated. The distribution of origin of the PVCs in the patient population is not what we see commonly. This could be secondary to the fact that these are veteran patients who are predominantly male, typically older and have more co-morbidities. They are considered as unique population.

8. Conclusion

This case series illustrates phenomenon of mechanical suppression of PVCs as an indication for good site for successful ablation in unique veteran patient population.

Declaration of competing interest

John M. Miller: He is a consultant for: Biosense-Webster; Medilynx; BioSig, Inc.; He gives lectures sponsored by: Biosense-Webster; Medtronic, Inc.; Abbott Electrophysiology; Boston Scientific Corp.; Biotronik, Inc.; He has received fellowship training grants from Biosense-Webster; Medtronic, Inc.; Boston Scientific

Corp.; Biotronik, Inc.

Rahul Jain: He has given lectures sponsored by Biosense Webster but none in the last two years.

No other authors have any conflict of interest related to this manuscript.

Acknowledgment

Acknowledgment of VA Research Support: This material is the result of work supported with resources and the use of facilities at the Richard L. Roudebush, VAMC, Indianapolis, IN, USA.

Disclaimer Requirement. The contents do not represent the views of the U.S. Department of Veterans Affairs or the United States Government.

References

- [1] Bainbridge FA. The influence of venous filling upon the rate of the heart. *J Physiol* 1915;50(2):65–84.
- [2] Reeves JT, et al. Operation Everest II: cardiac filling pressures during cycle exercise at sea level. *Respir Physiol* 1990;80(2–3):147–54.
- [3] Schotten U, Neuberger HR, Allesie MA. The role of atrial dilatation in the domestication of atrial fibrillation. *Prog Biophys Mol Biol* 2003;82(1–3): 151–62.
- [4] Hansen DE, Craig CS, Hondeghem LM. Stretch-induced arrhythmias in the isolated canine ventricle. Evidence for the importance of mechanoelectrical feedback. *Circulation* 1990;81(3):1094–105.
- [5] Trayanova NA, Constantino J, Gurev V. Models of stretch-activated ventricular arrhythmias. *J Electrocardiol* 2010;43(6):479–85.
- [6] King A, et al. Catheter-induced atrioventricular nodal block during radiofrequency ablation. *Am Heart J* 1996;132(5):979–85.
- [7] Jacobson LB, Scheinman M. Catheter-induced intra-Hisian and intrafascicular block during recording of His bundle electrograms. *Circulation* 1974;49(3): 579–84.
- [8] Wennevoold A, Christiansen I, Lindeneg O. Complications in 4,413 catheterizations of the right side of the heart. *Am Heart J* 1965;69:173–80.
- [9] Chiang CE, et al. Incidence, significance, and pharmacological responses of catheter-induced mechanical trauma in patients receiving radiofrequency ablation for supraventricular tachycardia. *Circulation* 1994;90(4):1847–54.
- [10] Blomstrom-Lundqvist C, Blomstrom P, Beckman-Suurkula M. Incessant ventricular tachycardia with a right bundle-branch block pattern and left axis deviation abolished by catheter manipulation. *Pacing Clin Electrophysiol* 1990;13(1):11–6.
- [11] Belhassen B, et al. Catheter-induced mechanical trauma to accessory pathways during radiofrequency ablation: incidence, predictors and clinical implications. *J Am Coll Cardiol* 1999;33(3):767–74.
- [12] Mar PL, et al. Unique features of epicardial ventricular arrhythmias/premature ventricular complexes ablated from coronary venous system in veteran population. *Indian Pacing Electrophysiol J* 2020;20(3):97–104.
- [13] Jain, R.M., Barmada, M., *Cardiac electrophysiology* (second ed.). in Press Springer.
- [14] Novick TL, et al. Temporary, catheter-induced block in accessory pathways. *Circulation* 1978;58(5):932–40.
- [15] Robinson K, Rowland E, Krikler DM. Wolff-Parkinson-White syndrome: inadvertent permanent ablation of the accessory pathway during electrophysiological study. *Br Heart J* 1988;59(1):75–6.
- [16] Tai YT, Lee KL, Lau CP. Catheter induced mechanical stunning of accessory pathway conduction: useful guide to successful transcatheter ablation of accessory pathways. *Pacing Clin Electrophysiol* 1994;17(1):31–6.
- [17] Schluter M, Kuck KH. Catheter ablation from right atrium of anteroseptal accessory pathways using radiofrequency current. *J Am Coll Cardiol* 1992;19(3):663–70.
- [18] Haissaguerre M, et al. Radiofrequency catheter ablation of accessory pathways: a contemporary review. *J Cardiovasc Electrophysiol* 1994;5(6):532–52.
- [19] McClelland JH, et al. Radiofrequency catheter ablation of right atriofascicular (Mahaim) accessory pathways guided by accessory pathway activation potentials. *Circulation* 1994;89(6):2655–66.
- [20] Cappato R, et al. Catheter-induced mechanical conduction block of right-sided accessory fibers with Mahaim-type preexcitation to guide radiofrequency ablation. *Circulation* 1994;90(1):282–90.
- [21] Jain R, Miller JM, Barmada M, Natale A., Wang P., Al-Ahmad A., Estes N. (eds). *Premature Ventricular Complexes from Pulmonary Artery*. *Cardiac Electrophysiology*. Springer, Cham; 2020.