

FROM THE DEPT. OF SURGICAL SEMIOTICS AND THE DIVISION  
OF THORACO-PULMONARY SURGERY OF THE UNIVERSITY OF MODENA,  
FACULTY OF MEDICINE AND SURGERY, MODENA, ITALY  
Director: Prof. R. LODI

ANATOMO-SURGICAL ASPECTS AND APPROACHES  
FOR THE TRANSPOSITION OF INTERCOSTAL NERVES  
TO THE BRACHIAL PLEXUS IN THE TREATMENT  
OF TRAUMATIC RADICULAR AVULSIONS (\*)

R. LODI  
L. BONATI

U. MORANDI  
G. TAZZIOLI

A. BONDIOLI  
J. J. BYRNES

RIASSUNTO

Gli autori descrivono le caratteristiche anatomico-chirurgiche e la via di accesso toracica antero-laterale usata per eseguire la trasposizione dei nervi intercostali al plesso brachiale nel trattamento delle avulsioni radicolari traumatiche.

In questa nota propongono una nuova via d'accesso toracica posteriore, già realizzata in alcuni casi, con vantaggi tecnici che rappresentano a tutt'oggi un miglioramento, rispetto alla metodica precedente, al fine di raggiungere risultati trofici e funzionali favorevoli con questa procedura.

INTRODUCTION

Radicular avulsions in traumatic lesions of the brachial plexus represent a dramatic event in which any possibility of surgical reconstruction of the damaged nerve is excluded. The only alternative to amputation of the limb in total avulsions, or palliative treatment in partial lesions, is an anastomosis between intercostal nerves and terminal branches of the plexus.

In 1961, Seddon was the first to perform a transposition of intercostal nerves to the brachial plexus, using the 3rd and 4th elongated with a graft from the Ulnar N. sutured then to the Musculocutaneous N.

SUMMARY

The Authors describe the anatomico-surgical characteristics of and the anterior approach used to carry out the transposition of intercostal nerves to the brachial plexus in the treatment of traumatic radicular avulsions.

They propose, moreover, a new posterior thoracic approach, already tested in several cases, with technical advantages and with results that represent an improvement in achieving the functional and trophic goals desired from this procedure.

In 1971, Allende and Mana proposed a technique that eliminated the intermediate nerve graft, and was based on the direct suturing of intercostal nerves to the damaged peripheral segment. This method, together with Seddon's method, is the most used, although both have undergone modifications and improvements guided by the many cases treated and the experiences of some other Authors (Millesi, Meissl and Katzer, 1973) and Millesi (1977).

The transposition procedure has given rise to many technical, re-educational, functional and also psychological problems not yet completely resolved, and not yet perfectly evaluated as to long term effects. Today, aside from the uncertainties and limitations pointed out, the reintegrative transposition of intercostal nerves represents for these patients, in light of the lack of other solutions, the last hope of recovering even partially the lost tropho-motor functions.

(\*) All work was done in collaboration with the Dept. of Orthopaedics of the University of Modena.

#### STUDY AND PREPARATION OF THE PATIENT

In every case, the cardio-circulatory and respiratory conditions, as well as hepatic and renal function and hematic coagulation, are thoroughly examined and evaluated. These are indispensable measures considering the length of the operation and time under anesthesia.

The functional studies on the traumatized segment of the plexus are performed as follows. neurologic examination, electromyometric and electromyographic examination. The time lapse between the traumatic event and the reintegrative procedure plays a very important role in the results of the surgery. In fact, when the extent of the injury and the indication of surgical treatment are determined with certainty, the procedure should be performed as soon as possible thereafter in order to avoid degeneration and scarring which would render more problematic the outcome of the surgery.

#### TECHNIQUES AND APPROACHES FOR TRANSPOSITION OF THE INTERCOSTAL NERVES

The first phase, regardless of the approach, is dedicated to the preparation of the entire plexus, from the neuronal foramina to the point of origin of the peripheral nerves, and serves to define the extent of the anatomic-functional damage.

##### THE ANTERO-LATERAL APPROACH (according to Seddon & Allende-Mana)

The patient in the supine position, the cutaneous incision is made from the posterior margin of the Sternocleidomastoid muscle running along the clavicle to its lateral third, and then turning caudad into the subclavicular region. The corresponding hemithorax is raised up from the operating table by a rubber roller (fig. 1).

If the initial evaluation of damage to the plexus indicates transposition of the intercostal nerves, the incision is prolonged obliquely from the subclavicular region to

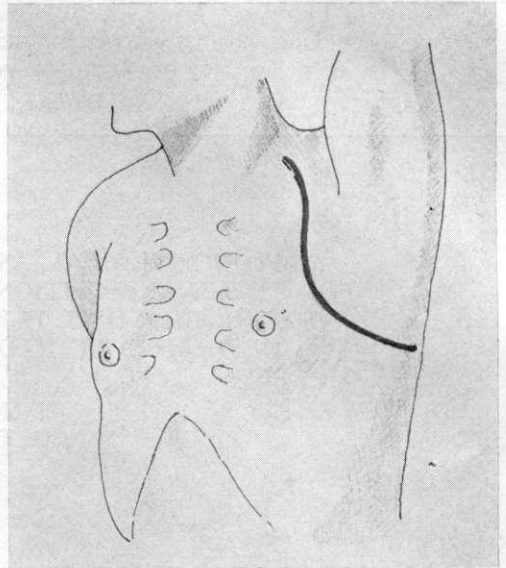


Fig. 1. — Seddon's anterior approach for the preparation and the transposition of the intercostal nerves to the brachial plexus.

the antero-lateral region of the thorax, continuing caudal and dorsally following the 5th intercostal space until it reaches the posterior axillary line. The musculotendinous insertions of the Pectoralis major and minor are then incised and spread, and, reaching the costal plane, one proceeds to isolate the intercostal nerves without costectomy. The periosteum is incised along the length of the rib and carefully pulled away from the infero-posterior costal border. In this way, the rib is freed from its ligamentous and muscular connections and can be easily lifted by one or more retractors. The retro- and subcostal neurovascular bundle is thereby exposed, and is visible in part of its length immediately in contact with the external face of the parietal pleura. The isolation of the nerve is done with care in order to avoid interrupting those motor branches that are distributed laterally to the intercostal muscles. The nerve must be isolated as far posteriorly as possible toward the posterior axillary line, where it presumably contains a greater number of motor fibers.

The group of nerves so isolated (generally the 2nd, 3rd, 4th, 5th), are passed via a subcostal extrapleural route into the corresponding axillary space in order to perform the desired anastomosis.

The approach described can present some disadvantages. For example, the anastomosis with peripheral trunks of the plexus is possible only with the interposition of autoplasmic grafts due to the impossibility of performing a direct end-to-end neurorrhaphy. The functional failures may be due to the transposition of an intercostal nerve segment that is primarily sensory in nature.

#### THE POSTERIOR THORACIC APPROACH

(our proposed technique; fig. 2)

The cutaneous incision is 'L-shaped' and is made in the interscapular-vertebral space with the patient in a lateral, slightly prone position. From the superior border of the Trapezius muscle, the incision descends to the 7th or 8th intercostal space and then skirts the inferior angle of the scapula to reach the mid-axillary line. By sectioning the full thickness of the Trapezius and Rhomboid, and part of the Latissimus dorsi and Serratus anterior, one enters the

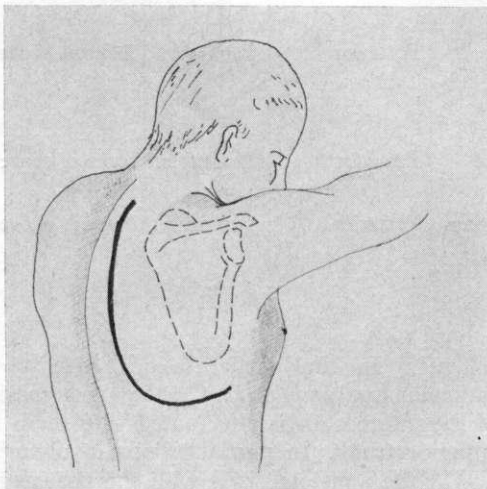


FIG. 2. — Proposed posterior approach. Cutaneous incision.

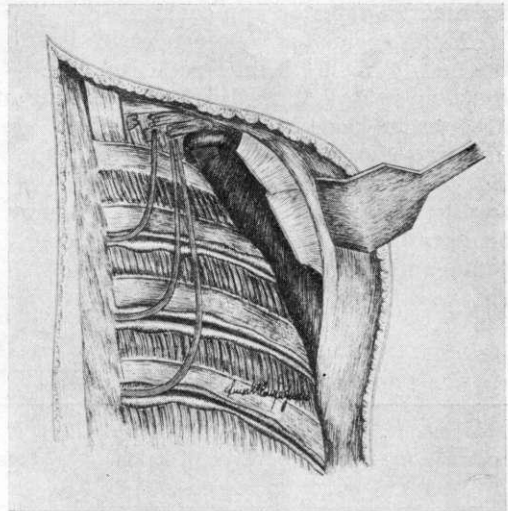


FIG. 3. — View of the posterior costal plane after raising the scapula and exposing the brachial plexus and the intercostal nerves in the transposition phase (in yellow).

supracostal space. The scapula is maintained in a raised position, thereby amply exposing the posterior and lateral costal planes. The three superior digitations of the Serratus anterior are sectioned, thus freeing the approach to the anterior costal plane. The vascular and nervous elements of the plexus are exposed by sectioning the Scalenus medius and posterior (fig. 3). Using the technique explained in the description of the anterior approach, one then proceeds to remove the periosteum from the inferior costal border, beginning at their costotransverse articulations and continuing to and surpassing the anterior axillary line. One takes care to loosen the parietal pleura from the internal face of the costal plane. Raising the rib permits the isolation of the neurovascular bundle, from which the nerve is then enucleated. The latter is then sectioned distally, on the anterior axillary line, and, according to the nerve in consideration, can measure from 15-20 cm or more in length. Generally speaking, the length of the intercostal bundle is such as to allow an easy transfer to the damaged nerve trunks of the plexus, prepared previously by

an anterior-superior approach.

With this technique, one can easily isolate the 2nd through 6th intercostal Nn. The function tests performed before sectioning of a nerve are done by electrostimulation in successive points.

The bundle of intercostal nerves is transferred to the retroclavicular region by an intrathoracic, retrocostal, extrapleural route, with a course that ascends from

with a greater contingent of motor fibers, because they are isolated and mobilized in all of their posterior part, which is much richer in such fibers.

The reconstruction of the costal and muscular plane is performed, subject to aspiration drainage of the subcostal and subscapular spaces.

The peripheral nerves for the anastomosis are chosen according to the following

TABLE I  
CASES OF TRANPOSITION OF INTERCOSTAL NERVES

Case	Age	Sex	Type of lesion	Treatment	Approach	Results	
						Short-term	Long-term
P.M.	17	M	Traumatic rupture of the Left Brachial Plexus	Anast. of branches of the plexus and transfer of intercostal nerves II, III, IV, V, VI to the Inferior branches of the plexus	Anterior	Favorable	Appearance of muscular tone; some contractility
S.G.	28	M	Traum. tearing of Rt. Br. Plexus	Transposition of Intercostal Nn. III, IV, V	Anterior - Autograft of Tibial Nerve	Favorable	Same as above
P.A.	18	M	Traum. tearing of Left Br. Plexus	Transp. of Intercostal Nn. III, IV, V	Anterior	Favorable	Same as above
B.C.	31	M	Radicular Avulsion of Rt. Br. Plexus	Transp. of 5 Intercostal Nn. II, III, IV, V, VI	Posterior	Favorable	Same as above
B.G.	29	M	Rad. Avulsion Rt. Br. Plexus	Same as above	Posterior	Favorable	Same as above
G.E.	22	M	Traum. tearing of Rt. Br. Plexus	Transp. of Intercostal Nn. II, III, IV, V	Posterior	Favorable	Same as above

behind forward, exiting at the level of the 2nd intercostal space. The anastomosis with the trunks of the plexus can be performed directly, without interposing autologous transplants, with the aid of the operating microscope. This technique therefore permits the transposition of nerves

schema: In the partial lesions with radicular avulsions of C<sub>5</sub>-C<sub>6</sub>, the anastomosis of the intercostals is effectuated with the superior trunk. In partial lesions involving C<sub>7</sub>-C<sub>8</sub>, the anastomosis is with the posterior and medial cords. In total lesions involving C<sub>5</sub>-C<sub>6</sub>-C<sub>7</sub>-C<sub>8</sub>, the anastomosis is

is preferably with the Circumflex, Musculocutaneous and Median Nerves. With this surgical program it may seem ambitious to hope for a complete recovery of the functions lost due to the trauma, but it is certainly useful to those who hope for at least a partial recovery that might favor future, more limited, palliative or corrective procedures.

In table I are presented the cases which underwent transposition of the intercostal nerves, with a description of the technique adopted, and the short-term and long-term results. Using the technical schema referred to, six patients have undergone surgical procedures.

#### CONCLUSIONS

The anterior approach adopted initially by us for the transposition of intercostal nerves to the brachial plexus seems unsatisfactory.

In fact, consideration of the necessity to interpose one or more autoplasmic segments

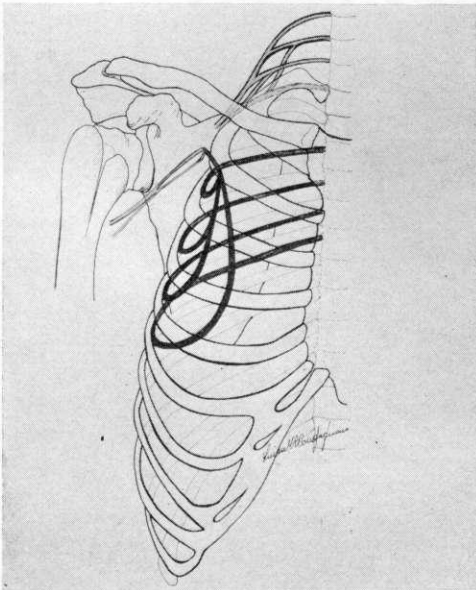


FIG. 4. — Schematic representation of the transposition of the intercostal nerves (in red) to the brachial plexus (in yellow) according to Seddon's anterior approach using an autotransplant of the trunk of the Tibial N. (in green).

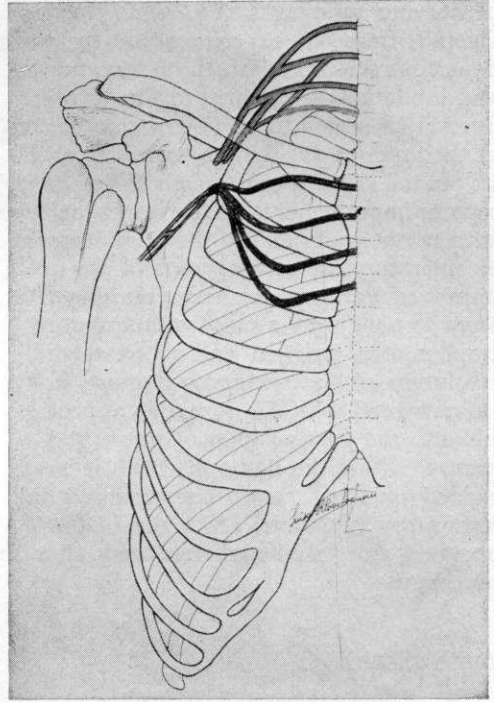


FIG. 5. — Schematic representation of the intercostal nerves (in red) for transposition to the brachial plexus (in yellow) according to our proposed approach. Note the Direct anastomosis between the intercostal nerves and the damaged branches of the brachial plexus.

of the Tibial N. in order to anastomose branches of the plexus to intercostal nerves (fig. 4), as well as the unreliability regarding the number of motor fibers transposed by the anterior approach, pressed us to improve on the Seddon and Allende-Mana techniques. The posterior approach for isolating and transposing intercostal nerves seems to us to offer some advantages over the anterior approach. Our technique probably allows us to increase the motor fiber entity because the anastomosis employs nerve segments that are of greater calibre and are more proximal to their origin where there is a predominance of motor over sensory fibers. Moreover, the proposed approach, by virtue of a shorter trajectory, permits a direct anastomosis with damaged trunks, eliminating the interposition

of nervous autografts (fig. 5).

Overall, from our experience and the work done thus far, and with the reservations and limitations mentioned in the Introduction, it seems to us that a comparison of the anterior vs. the posterior approach favors the latter, even though Millesi (1977) reports improvements in the results achieved with nerve grafts due to the development of microsurgical techniques and the improved technique of nerve grafting. We seem to note a more rapid resumption of trophomotor function and a greater resolution of the traumatic damage in the cases treated with the posterior approach. Finally, the transposition of intercostal nerves, within the limits in which it was carried out, has never compromised the respiratory functional efficiency of the operated side, studied before and after the procedure.

#### BIBLIOGRAPHY

ALLENDE B. T., MANA E.: *Transferencia de Nervios intercostales a plexo braquial. Tecnica*

*quirurgica*. Rev. de Ortopedia y Traumatologia Latino-Americana, 16, 79-82, 1971.

BEDESCHI P.: *Traumatic injuries of the peripheral nerves; Surgical treatment of nerve injuries at the wrist and hand; Evaluation of results*. Orthop. Ital., 1, 162-170, 1972.

CHIASSERINI A.: *L'anastomose intercosto-radicaire dans les traumatismes vertebraux avec section de la molle lombaire*. Journal de Chirurgie, 46, 54-58, 1935.

KOTANI G. T., TOYOSHOMA Y., MATSUDA H. et al.: *The postoperative results of nerve transfer for the brachial plexus injury with root avulsion*. Proc. 14 th Ann. Meet. Jap. Soc. Surg. of the Hand, Osaka, 1971.

MILLESII H., MEISSL G., KATZER H.: *Zur Behandlung der Verletzungen des plexus brachialis Vorschlag einer intergrierten therapie*. Bruns' Beitr. Klin. Chir., 220, 429-446, 1973.

MILLESII H.: *Surgical management of Brachial Plexus Injuries*. Journal of Hand Surgery, 2(5), 367-379, 1977.

SEDDON H. J.: *The use of autogenous grafts for the repair of large gaps in peripheral nerves*. Brit. J. Surg., 35, 151-167, 1947.

SEDDON H. J.: *Nerve Grafting*. Bone and Joint Surgery, 45-B, 447-461, 1963.

TSUJAMA N., SAKAGUCHI R., HARA T. et al.: *Reconstructive Surgery in brachial plexus injuries*. Proc. 11 th Ann. Meet. Jap. Soc. of the Hand, Hiroshima, p. 39-41, 1968.