

Successful treatment of *Fusarium* keratitis after photo refractive keratectomy

Gian Maria Cavallini, Pietro Ducange,
Veronica Volante, Caterina Benatti

A 39-year-old woman presented to our hospital with a history of photorefractive keratectomy (PRK), performed two weeks prior; slit-lamp examination revealed diffuse conjunctival congestion, corneal ulcer and stromal infiltration. After 5 days of antifungal and antibacteric treatment, the infiltrate progressively increased so that a therapeutic penetrating keratoplasty was necessary. The microbiological analyses revealed the presence of fungal filaments. Twenty days after surgery the patient had recurrent fungal infiltrate in the donor cornea with wound dehiscence. We performed a second penetrating keratoplasty. With the matrix-assisted-laser-desorption-ionization-time-of-flight analysis (MALDI-TOF) we identified a *Fusarium solani*. Intravenous amphotericine B, a combination of intracameral and intrastromal voriconazole and intracameral amphotericine B were administered. After 6 months from the last surgery the infection

was eradicated. The management of fungal keratitis after PRK depends on many factors: In our experience, a prompt keratoplasty and the use of intracameral antifungal medication proved to be very effective.

Key words: *Fusarium*, keratitis, photo refractive keratectomy

Fusarium species are common organisms that are present in soil, water and plants. These fungi are more frequent in tropical and temperate areas,^[1] and are the most well-known agents of fungal keratitis world-wide, causing up to 32% of reported infections;^[2] in USA *Fusarium* spp. are documented as the most common cause of keratitis.^[3]

Most infections are often preceded by trauma. Other risk factors include the use of antibiotics and corticosteroids, pre-existing eye diseases, foreign bodies' surgery and the use of contact lenses. Among *Fusarium* species, *F. solani*, *F. oxysporum* and *F. moniliforme* are the most frequently implicated in human infections.^[2]

Case Report

A 39-year-old woman presented to our hospital with a history of photorefractive keratectomy (PRK), performed two weeks prior. She complained severe visual loss, photophobia, redness and pain in right eye.

The patient was receiving therapy with topical steroids and antibiotic eye drops. The best corrected visual acuity (BCVA) of the affected eye was limited to hand motion. Slit lamp examinations revealed diffuse conjunctival congestion and a corneal ulcer with stromal infiltration [Fig. 1a].

The ulcer bed and edges were scraped and were sent for bacteriological and mycological examination analysis.

Treatment with corticosteroid eye drops was suspended and the patient was started on the following drugs: Topical fortified 5% vancomycin, tobramycin 0.3%, moxifloxacin 0.5%, amphotericin B 0.15% at 4 h intervals; systemic antifungal and antibacteric drugs consisted of oral itraconazole at a dose of 200 mg daily with oral ciprofloxacin 1g daily, and intramuscular ceftriaxone 1 g daily respectively.

After two days the cornea revealed a full thickness infiltrate with 1 mm hypopyon [Fig. 1b]. The infiltrate and the hypopyon

Access this article online	
Quick Response Code:	Website: www.ijo.in
	DOI: 10.4103/0301-4738.120213

Institute of Ophthalmology, University of Modena and Reggio Emilia, Modena, Italy

Correspondence to: Prof. Gian Maria Cavallini, Struttura Complessa di Oftalmologia, Azienda Ospedaliero-Universitaria di Modena Policlinico, Via del Pozzo 71, 41100, Modena, Italy. E-mail: cavallini.gianmaria@unimore.it

Manuscript received: 12.11.12; Revision accepted: 22.02.13

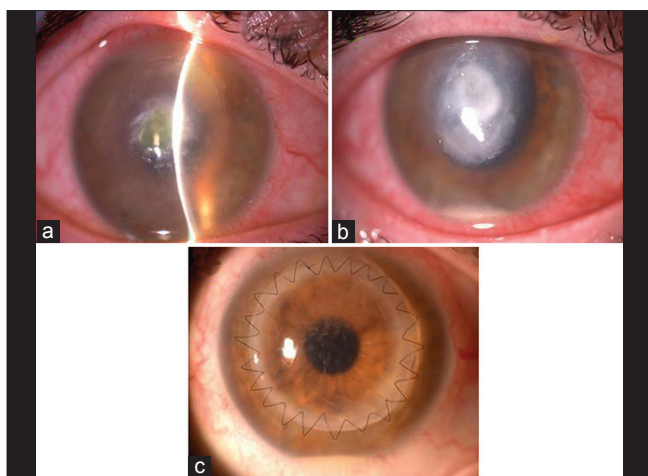


Figure 1: (a) Diffuse conjunctival congestion and corneal ulcer with stromal infiltration, (b) large full thickness infiltrate with 1 mm hypopyon, (c) endothelial dusting, aqueous flare and cells

progressively increased in size. After 5 days, the patient underwent a therapeutic penetrating keratoplasty with an 8-mm graft on a 7.75-mm bed using *Barron Corneal Trephine*. The explanted cornea was sent to the microbiology laboratory for further testing.

Post-surgery treatment consisted in topical norfloxacin 0.3% (6 times per day) and amphotericin B (4 times per day); systemic ciprofloxacin 1 g daily, ceftriaxone 1 g daily, itraconazole 200 mg daily and intramuscular methylprednisolone 20 mg daily [Fig. 1].

After 8 days, the culture of corneal scraping revealed the presence of fungal filaments. We decided in agreement with the infectious disease specialist, to add therapy with oral voriconazole, (800 mg per day on the first day, followed by 400 mg per day on successive days) and topical amphotericin B eye drops 6 times per day. The donor cornea and anterior chamber remained free from infiltrates until day 12, after keratoplasty, when the patient showed eye redness, pain, 1/50 of visual acuity, endothelial dusting and aqueous flare and cells [Figs. 1c and 2a]. Oral voriconazole was changed to intravenous formulation, 8 mg/Kg twice per day.

Twenty days after surgery the patient had recurrent fungal infiltrate in the donor cornea with wound dehiscence [Fig. 2b]. We decided to perform a second penetrating keratoplasty.

Results

Because of the high degree of homology in culture between *Fusarium solani* or *oxysporum*, it has been difficult to rule out the two similar opportunistic pathogens from the biopsies performed for microbiological analysis. In order to have a proven and rapid differential diagnosis we sent biopsy material to the Institute of Microbiology of Bellinzona (Switzerland), where a matrix-assisted laser desorption ionization-time-of-flight analysis (MALDI-TOF) has been performed.

The fungal isolate was identified as *Fusarium solani*, occurring in both the first and second explanted corneas. After specific antifungal sensitivity testing, we decided to start the patient on the following agents: 3 mg/Kg twice a day of

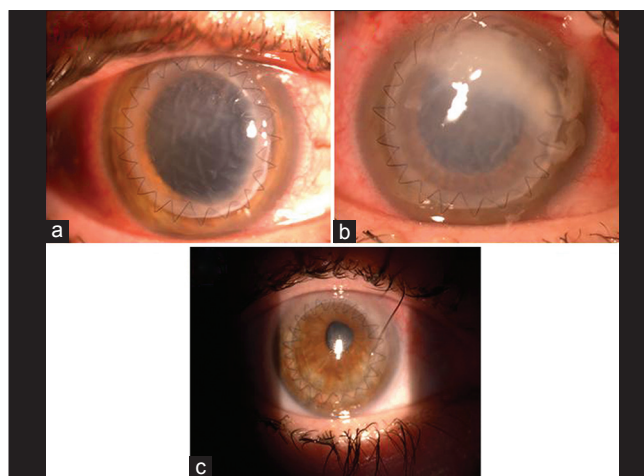


Figure 2: (a) Eye redness, endothelial dusting, aqueous flare and cells, (b) fungal infiltrate in with wound dehiscence, (c) eradication of infection

intravenous amphotericin pB; netilmycin 0.3%, moxifloxacin 0.5%, voriconazole 1% (drops every 2 h) and diclofenac 0.1% (drops every 8 h).

During the following days, we performed a combination of intracameral/intrastromal voriconazole (50 µg/0.1 ml) in addition to intracameral amphotericin B (10 microg/0.1 mL), in three different administrations.^[4,5]

After 6 m from the last surgery the infection was eradicated, the donor cornea was clear, and the BCVA was 7/10 [Fig. 2c].

Discussion

In this case report we describe the therapeutic management of fungal keratitis post PRK.

The incidence of infectious complications post PRK is relatively low and the pathogens primarily involved are Gram-positive organisms.^[6] To our knowledge, only few cases of fungal keratitis are reported.^[7,8]

The use of bandage contact lens (BCL) and topical steroid therapy, provided in the postoperative course of the PRK together with the breakdown of the barrier function of the corneal epithelium, may cause a predisposition to fungal corneal infection. A variety of factors can determine the course of a fungal keratitis such as early diagnosis, sensitivity to drug therapy and virulence of the fungus.

In our case, the natural history of the infection was influenced by appropriate timing of intervention; in fact, the choice to perform a penetrating keratoplasty proved to be effective in containing the infection and preventing corneal perforation. Our patient had a recurrence of the infection that can be explained by the delay in starting the specific therapy with voriconazole, [due to the time required for microbial culture (8 days)] and the need to perform the MALDI-TOF in order to identify the species of *Fusarium*.

The long use of topical steroid after PRK might be another cause of fungal infection recurrence after the first PRK, as reported in the literature.^[9] The presence of hypopyon before surgery has also been reported as a risk factor for recurrent fungal infection after PK.^[10]

Conclusion

The management of fungal keratitis after PRK depends on many factors: In our experience, the decision of performing a prompt keratoplasty was aimed at reducing the corneal infection in the first occurrence, and to solve it in the second manifestation. Finally the use of intracameral antifungal medication proved to be very effective in avoiding the recurrence of infection.

References

1. Klont RR, Eggink CA, Rijs AJ, Wesseling P, Verweij PE. Successful treatment of *Fusarium* keratitis with cornea transplantation and topical and systemic voriconazole. *Clin Infect Dis* 2005;15:40:110-2.
2. Dignani MC, Anaissie E. Human fusariosis. *Clin Microbiol Infect* 2004;10:67-75.
3. Jones DB, Forster FK, Rebell G. *Fusarium solani* keratitis treated with natamycin (pimaricin): Eighteen consecutive cases. *Arch Ophthalmol* 1972;88:147-54.
4. Yoon KC, Jeong IY, Im SK, Chae HJ, Yang SY. Therapeutic effect of intracameral amphotericin B injection in the treatment of fungal keratitis. *Cornea* 2007;26:814-8.
5. Haddad RS, El-Mollayess GM. Combination of intracameral and intrastromal voriconazole in the treatment of recalcitrant Acremonium fungal keratitis. *Middle East Afr J Ophthalmol* 2012;19:265-8.
6. Wroblewski KJ, Pasternak JF, Bower KS, Schallhorn SC, Hubickey WJ, Harrison CE, *et al.* Infectious keratitis after photorefractive keratectomy in the United States army and navy. *Ophthalmology* 2006;113:520-5.
7. Kouyoumdjian GA, Forstot SL, Durairaj VD, Damiano RE. Infectious keratitis after laser refractive surgery. *Ophthalmology* 2001;108:1266-8.
8. Periman LM, Harrison DA, Kim J. Fungal keratitis after photorefractive keratectomy: Delayed diagnosis and treatment in a comanaged setting. *J Refract Surg* 2003;19:364-6.
9. Sharma DP, Sharma S, Wilkins MR. Microbial keratitis after corneal laser refractive surgery. *Future Microbiol* 2011;6:819-31.
10. Shi W, Wang T, Xie L, Li S, Gao H, Liu J *et al.* Risk factors, clinical features, and outcomes of recurrent fungal keratitis after corneal transplantation. *Ophthalmology* 2010;117:890-6.

Cite this article as: Cavallini GM, Ducange P, Volante V, Benatti C. Successful treatment of *Fusarium* keratitis after photo refractive keratectomy. *Indian J Ophthalmol* 2013;61:669-71.

Source of Support: Nil. **Conflict of Interest:** None declared.