

Transperitoneal Laparoscopic Adrenalectomy in Children

Barbara Catellani, MD, Sara Acciuffi, MD, Diego Biondini, MD, Pier Luca Ceccarelli, MD, Alfredo Cacciari, MD, Roberta Gelmini, MD, PhD

ABSTRACT

Purpose: The use of a minimally invasive approach for adrenalectomy is poorly defined in pediatric patients, although laparoscopic adrenalectomy is considered a standard procedure in adults. The aim of our study was to describe the safety and feasibility of minimally invasive adrenalectomy in children on the basis of surgical skills and results.

Materials and Methods: This was a retrospective study of 4 pediatric laparoscopic adrenalectomies performed at our center between 2009 and 2012. All patients underwent transperitoneal lateral laparoscopic adrenalectomies (2 right and 2 left adrenalectomies).

Results: Four laparoscopic adrenalectomies were performed. Indications for surgery were neuroblastoma in 2 patients, secerment adrenocortical tumor in 1 patient, and adrenocortical nodular hyperplasia in 1 patient. Patients had a mean age of 87 months (range, 17–156 months) at diagnosis, and the average lesion size was 3.23 cm (range, 0.7–6.4 cm). All laparoscopic adrenalectomies were successful, no conversions to open surgery were required, and no postoperative complications or deaths occurred. The average operating time was 105 minutes (range, 80–130 minutes), blood loss during surgery was minimal, and the mean postoperative hospital stay was 3.75 days (range, 3–5 days). None of the patients showed signs of recurring disease at 15-month follow-up.

Conclusions: Laparoscopic adrenalectomy is a safe, feasible, and reproducible technique offering numerous advantages, including shortening of operating times and postoperative hospital stays, as well as reduction of blood

loss and complications. It also provides good visibility and easy access to other organs.

Key Words: Laparoscopic adrenalectomy, Children, Pediatric surgery, Adrenal tumors.

INTRODUCTION

In recent years, adrenal surgery has developed significantly because of progress in diagnostic tools, the growth of endocrinologic knowledge, and the advent of minimally invasive techniques. Because of their small size and their retroperitoneal location, the adrenal glands are suitable for laparoscopic excision.^{1,2} Since the first transperitoneal laparoscopic adrenalectomy, described by Gagner et al³ in 1992, minimally invasive surgery for the adrenal gland has progressively become an effective, feasible, reproducible, and safe procedure in adult patients.^{1,4–10} Many retrospective clinical studies have affirmed the role of laparoscopic adrenalectomy in adults, demonstrating its advantages in comparison with open surgery in terms of dissection of the soft tissue, blood loss, postoperative pain, complications, hospital stay, and cosmetic results.^{1,2,4,10–12} Therefore, minimally invasive adrenalectomy is presently considered the “gold-standard” procedure for the removal of benign and selected malignant adrenal pathologic masses in adult patients.^{11,13–15} Nevertheless, in the pediatric population, the experience with laparoscopic adrenalectomy is limited.^{1,2,11,13,15} The reasons are the infrequency of adrenal lesions in this population, a variable pathologic spectrum, and a higher incidence of malignancy in these patients.^{11,13,15} In addition, small body size and inexperience with smaller laparoscopic instrumentation make the procedure more technically challenging and may limit enthusiasm among surgeons for this approach.^{1,2,11,13} Moreover, in the case of neuroblastoma, the large size, the infiltrative nature of the tumor, and the theoretical risk for recurrence may further explain the lack of experience with laparoscopic adrenalectomy in children.^{1,2,11,14}

The aim of this study was to review our initial experience with laparoscopic adrenalectomy in children and

Department of Surgery (Drs B. Catellani, S. Acciuffi, and R. Gelmini) and Department of Pediatric Surgery (Drs D. Biondini, P.L. Ceccarelli, and A. Cacciari), University of Modena and Reggio Emilia, Policlinico of Modena, Modena, Italy.

Address correspondence to: Roberta Gelmini, MD, PhD, Department of Surgery, Policlinico of Modena, University of Modena and Reggio Emilia, Via del Pozzo, 71, 41124 Modena, Italy; Telephone: +39-0594223662, Fax: +39-0594224370, E-mail: roberta.gelmini@unimore.it.

DOI: 10.4293/JSL.2014.00388

© 2014 by JSL, *Journal of the Society of Laparoendoscopic Surgeons*. Published by the Society of Laparoendoscopic Surgeons, Inc.

verify its safety and feasibility in the pediatric population.

MATERIALS AND METHODS

This was a retrospective study of all laparoscopic adrenalectomies performed on pediatric patients at our institution between April 2009 and August 2012 by a single surgeon. In the same period, 5 open pediatric adrenalectomies were performed by the same operating team. Four transperitoneal lateral laparoscopic adrenalectomies were carried out. All patients underwent preoperative evaluations including endocrinologic investigation to determine secretory activity. Additionally, all patients were studied with ultrasonography, computed tomography, or magnetic resonance imaging to assess the side, the size, the local extent, and the operability of the primary lesion (**Figures 1–3**). When necessary, metaiodobenzylguanidine scintigraphy was performed. Intraoperative variables considered were operating time, blood loss, rate of conversion, and additional procedures. Postoperative end points were time of resumption of oral intake, return to bowel function, hospital stay, surgical and medical complications, histopathologic diagnosis, size of lesion at the pathologic examination, and cosmetic results. Follow-up focused on recurrence rate, onset of metastasis, overall survival, disease-free survival, and death.

Surgical Procedure

All patients underwent transperitoneal lateral laparoscopic adrenalectomy (2 right and 2 left adrenalectomies). No lymphadenectomies were performed, because the lesions were not associated with enlarged nodes on imaging. The patient was placed in a reverse Trendelenburg semilateral decubitus position (operative side upward) over a flank lift

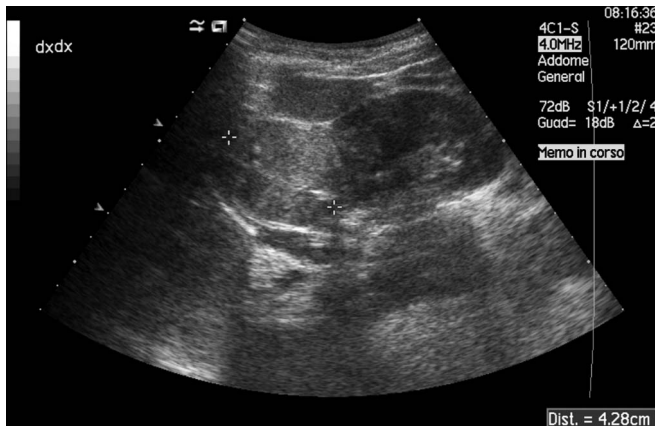


Figure 1. Left neuroblastoma on ultrasonography.

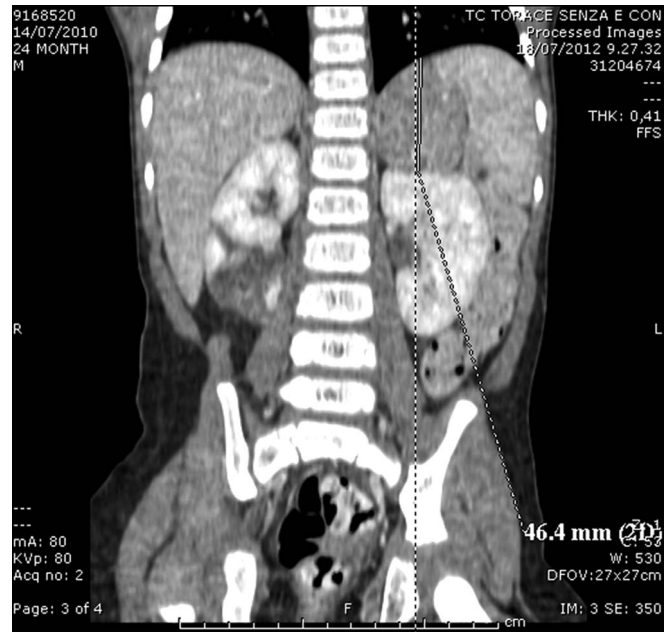


Figure 2. Left neuroblastoma on computed tomography: longitudinal section.

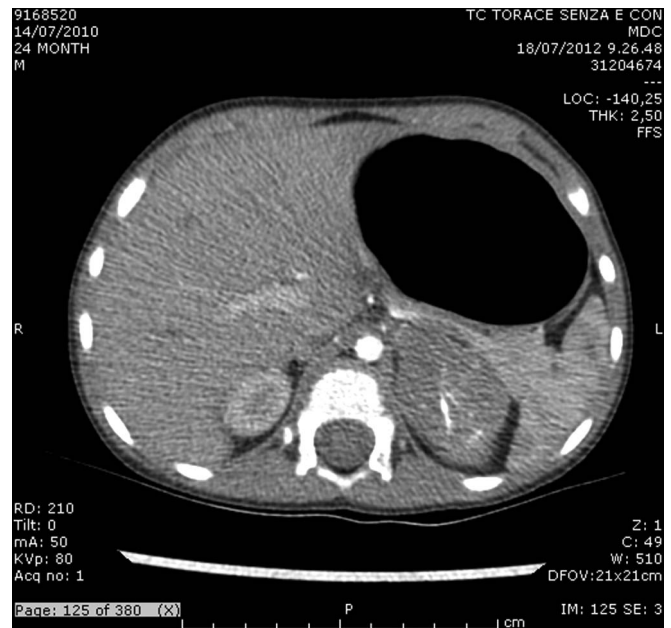

Figure 3. Left neuroblastoma on computed tomography: cross-section.

to laterally flex the spine and expose the space between the anterior-superior iliac crest and the costal margin. A 10-mm Hg pneumoperitoneum was created using a 10-mm to 12-mm Hasson's trocar. Afterward, three 5-mm trocars were

inserted under direct vision through a 30° optical device; their position depended on the side of the adrenalectomy, as shown in **Figure 4**.

Right Adrenalectomy

The liver was cranially retracted and the right lobe was mobilized, thus revealing the anterior surface of the adrenal gland and the lateral border of the inferior vena cava. The dissection began between the medial border of the adrenal gland and the lateral border of the inferior vena cava to isolate the gland. The direct manipulation and mobilization of the adrenal gland with graspers should be minimal to preserve its integrity and to avoid hemodynamic instability, which may occur in patients with pheochromocytoma. The inferior vena cava was isolated in the caudal-cranial direction and exposed to the confluence of the right renal vein to identify the right adrenal vein. The main adrenal vein was sectioned between metal clips or using an ultrasonic or radiofrequency scalpel (**Figure 5**). The dissection proceeded in a medial-to-lateral and superior-to-inferior direction until complete mobilization of the gland. Once the dissection was completed, the specimen was removed intact within an endosurgical bag, through an anterior axillary line port, enlarged when necessary. An abdominal drain was placed when necessary.

Left Adrenalectomy

A plane along the anterior surface of the kidney, lateral and dorsal to the spleen and tail of pancreas, was established, and the splenocolic and spleen's suspensory ligaments were divided to expose the adrenal gland. The dissection proceeded along the anterior surface of the kidney and adrenal gland until the inferior and medial border. Afterward, the splenic vein was identified and followed to identify the left renal vein, the left adrenal vein, and the left adrenal artery. The main adrenal vessels were isolated and sectioned with a vessel-sealing device (**Figure 6**). The dissection proceeded in a superior and lateral direction until the complete mobilization of the adrenal gland. The specimen was removed intact within an endosurgical bag, through a periumbilical port, enlarged when necessary. The surgery finished as on the right side.

RESULTS

Between April 2009 and August 2012, 4 unilateral laparoscopic adrenalectomies were carried out in 4 children. Demographic and anthropometric data are shown

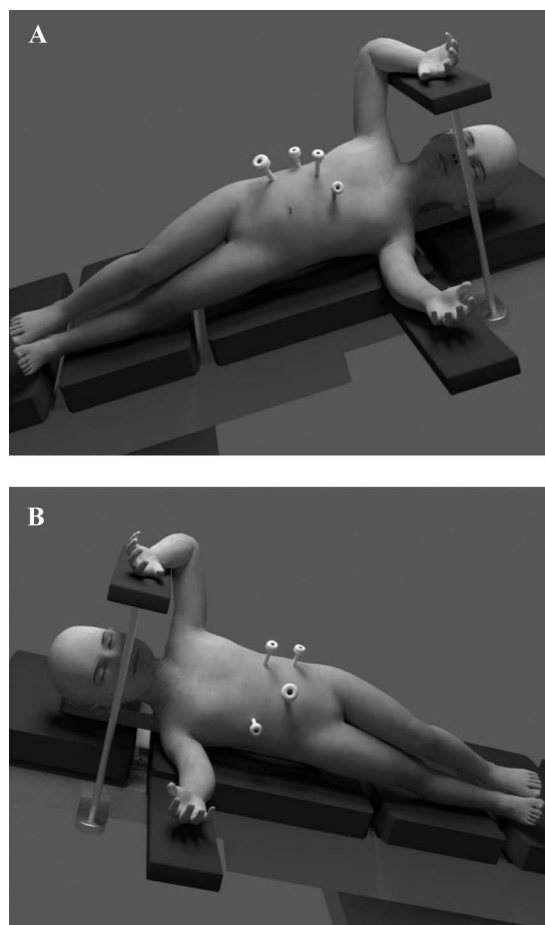


Figure 4. Position of the trocars for right adrenalectomy (a) and left adrenalectomy (b).

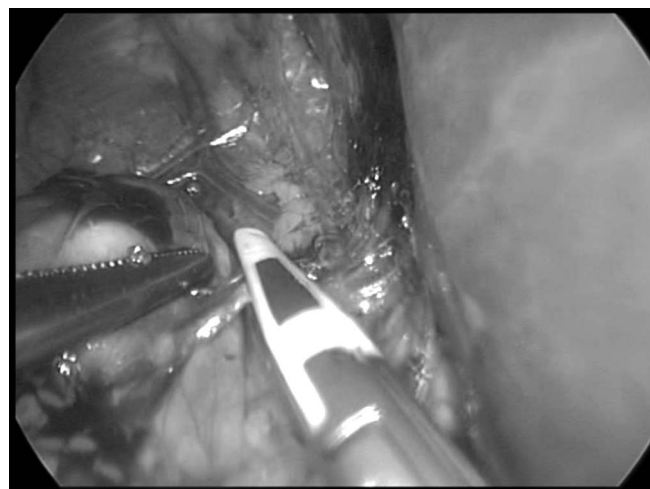


Figure 5. Dissection of the right adrenal vein.

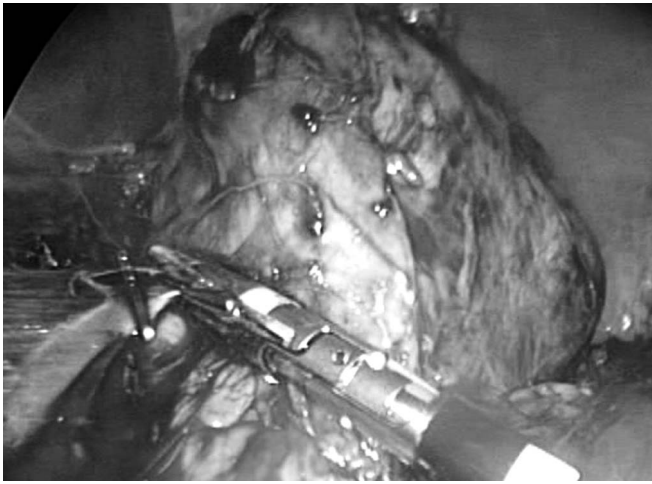


Figure 6. Dissection of the left adrenal vein.

in **Table 1**. None of the children had undergone previous abdominal surgery. The first patient was clinically manifest, with signs and symptoms attributable to Conn's syndrome. The other 3 cases were accidentally diagnosed (incidentalomas): the adrenal mass was identified by ultrasonography performed to study the possible presence of a polycystic ovary (second patient), a supernumerary testis (third patient), and a double kidney district with vesicoureteral reflux (fourth patient).

The pathologic lesions and the indications for surgery are described in **Table 2**. The mean size of the lesions was 2.93 cm (range, 1–4.8 cm) on the radiologic images and 3.23 cm (range, 0.7–6.4 cm) on pathologic examination. The patient with an aldosterone-secreting adrenocortical tumor underwent antialdosteronic and antihypertensive treatment before the adrenalectomy to minimize the risks of surgery and anesthesia.

All surgeries were successfully performed. As shown in **Table 3**, there was negligible blood loss (<100 mL) in all cases and no intraoperative complications or conversions to open surgery. In the third patient, a unilateral hernioplasty was performed in addition to the adrenalectomy. There was no intraoperative tumor rupture or mortality. None of the children needed intraoperative or postoperative blood transfusions. For right adrenalectomies, the mean operating time was 85 minutes (range, 80–90 minutes), and for left adrenalectomies, the mean operating time was 125 minutes (range, 120–130 minutes).

The early postoperative period was uneventful, with early resumption of oral intake (on the first postoperative day in all patients) and return to bowel function (on the second postoperative day in all patients). In addition, there were no surgical or

medical complications, and the hospital stays were short in all patients. All children had excellent cosmetic results, with very small incisions, enlarged only in the fourth patient.

Postoperatively, the patient with Conn's syndrome was treated with replacement steroid therapy (his clinical status significantly improved during follow-up), and the 2 patients with neuroblastoma (International Neuroblastoma Staging System stage 1) underwent adjuvant chemotherapy as per guidelines.

The mean follow-up duration was 35.25 months (range, 15–55 months). At 15-month follow-up, none of the children showed clinical or radiologic signs of local recurrence, port-site recurrence, or distant metastasis. The 2 children with neuroblastoma (International Neuroblastoma Staging System stage 1) are still under observation and continue to be symptom free.

DISCUSSION

Current experience with laparoscopic techniques in pediatric population is limited; there are only a few reports in the literature about this procedure in children, and the cohorts considered have been small.^{1,2,11,13–15} However, thanks to growing experience with pediatric minimal invasive surgery, this trend is changing, and the use of laparoscopic adrenalectomy in this age group is increasing.² Although the limited size of our cohort did not allow an accurate statistical analysis, the present report describes our initial experience with laparoscopic adrenalectomy in children.

Regarding technical considerations, the transperitoneal lateral approach has shown considerable benefits, as it provides a good view of the entire abdominal cavity, with excellent exposure of both adrenal gland and the surrounding structures.¹⁴ In this manner, the surgeon has a large working space and can easily explore, detect, and resect all suspect lymph nodes and eventual second lesions.^{14,16} The transperitoneal approach proved to be a rapid procedure: in previous studies, the retroperitoneal approach took longer than the transperitoneal technique, and our mean operating time was among the lowest reported, even though during the third operation, a unilateral hernioplasty was performed (**Table 4**).^{1,2,9,11,13,15,16–23} For these reasons, and because of the lower rate of conversion as described by Pampaloni et al,²⁴ the transperitoneal technique is widely considered the most accepted procedure for laparoscopic surgery of the adrenal glands, especially for large malignant tumors.¹⁴

As shown in **Table 4**, our rate of conversion is among the lowest described in the literature: we had no tumor ruptures

Table 1.
Demographic Data of Pediatric Patients Who Underwent Laparoscopic Adrenalectomy

| Patient No. | Sex | Age (mo) | Body Weight (kg) | Signs and Symptoms |
|-------------|--------|------------|------------------|--|
| 1 | Male | 156 | 45 | Hyperaldosteronism, low PRA, hypokalemia, hypertension |
| 2 | Female | 152 | 45 | — |
| 3 | Male | 17 | 11.8 | — |
| 4 | Male | 24 | 13 | — |
| Mean ± SD | | 87 ± 77.15 | 28.7 ± 18.83 | |

PRA, plasma renin activity.

Table 2.
Lesion Characteristics on Imaging and on Pathologic Investigation

| Patient No. | Diagnosis | Lesion Side | Lesion Size on Imaging (cm) | Lesion Size on Pathologic Investigation |
|-------------|--|-------------|-----------------------------|---|
| 1 | Aldosterone-secreting adrenocortical tumor | Left | 1 | 0.7 |
| 2 | Neuroblastoma (INSS stage 1) | Right | 4.7 | 4.5 |
| 3 | Adrenocortical nodular hyperplasia | Right | 1.2 | 1.3 |
| 4 | Neuroblastoma (INSS stage 1) | Left | 4.8 | 6.4 |
| Mean ± SD | | | 2.93 ± 2.11 | 3.23 ± 2.69 |

INSS, International Neuroblastoma Staging System.

Table 3.
Intraoperative and Postoperative Results of Laparoscopic Adrenalectomy

| Patient No. | Operating Time (min) | Removal of Drainage (d) | Resumption of Solid Oral Intake (d) | Recanalization (d) | Postoperative Hospital Stay (d) | Follow-up (mo) |
|-------------|----------------------|-------------------------|-------------------------------------|--------------------|---------------------------------|----------------|
| 1 | 130 | 2 | 1 | 2 | 5 | 55 |
| 2 | 90 | 1 | 1 | 2 | 3 | 42 |
| 3 | 80 | — | 1 | 2 | 3 | 29 |
| 4 | 120 | 2 | 1 | 2 | 4 | 15 |
| Mean ± SD | 105 ± 23.80 | 1.66 ± 0.57 | 1 ± 0 | 2 ± 0 | 3.75 ± 0.96 | 35.25 ± 17.17 |

or relevant bleeding, which are the most frequent reasons for conversion. In fact, the mild and expert manipulation of the adrenal gland prevented injury to the tumor, and hemostasis was well controlled. Blood loss was negligible (<100 mL) in all patients, without the necessity for blood transfusions, which may be ascribed to the excellent lighting and magnification of the laparoscope.⁶

Regarding the postoperative data, we had very satisfying results that are comparable with most results reported in the literature (Table 4). In addition, some studies have compared the laparoscopic and open procedures and observed that the time to resumption of diet, the time to

return of bowel function, and the length of hospital stay were shorter in the laparoscopic group, allowing postoperative chemotherapy to be started at the earliest time.^{12,25} Additional advantages demonstrated were a lower morbidity rate, easier pain control, greater mobility after surgery, and notably better cosmetic results.^{11,12,19,20,26}

Although all data reported suggest that laparoscopy could potentially offer great short-term benefits in the pediatric population, there are still doubts about the use of laparoscopic adrenalectomy for malignant tumors in terms of tumoral spillage and port-site disease recurrence. To reduce this risk, we found it important not to morcellate the

Table 4.
Literature Outcome Data for Laparoscopic Adrenalectomy in Children

| Study | No. of Patients | Technique | No. of Bilateral LAs | Operating Time (min) | Conversion (%) | Blood Transfusion (%) | Postoperative Complications (%) | Hospital Stay (d) |
|---------------------------------|-----------------|-----------|----------------------|----------------------|----------------|-----------------------|---------------------------------|-------------------|
| de Barros et al ¹⁷ | 7 | T | 0 | 138.6 | 14.3 | 14.3 | 0 | 2.9 |
| Lopes et al ² | 17 | T | 0 | 138.5 | 0 | 5 | 0 | 3.5 |
| St Peter et al ¹⁸ | 140 | NS | 5 | 130.2 [*] | 9.9 | 2.8 | 0.7 | NS |
| Sukumar et al ¹³ | 7 | T | 3 | 111 U-LAs, 263 B-LAs | 0 | 0 | 14.3 | 5,3 |
| Eassa et al ¹⁵ | 2 | R | 0 | 255 | 0 | 0 | 0 | 1.5 |
| Nerli et al ¹ | 18 | T | 0 | 95 | 0 | 0 | 0 | 2.1 |
| Lopez et al ¹⁹ | 5 | R | 1 | 154 [†] | 0 | — | — | — |
| Laje et al ²⁰ | 8 | T | 0 | 99 | 0 | 0 | 0 | 1.5 |
| Skarsgard et al ¹¹ | 20 | T | 0 | 101 | 5 | 0 | 0 | 1.5 |
| Saad et al ²¹ | 6 | T | 0 | 149.2 | 0 | — | — | 5.7 |
| Kadamba et al ²² | 10 | T | 1 | 141 U-LAs, 330 B-LAs | 20 | 0 | 0 | 5.5 |
| De Lagausie et al ¹⁶ | 9 | T | 0 | 85 | 11.1 | 0 | 11.1 | 4.5 |
| Miller et al ²³ | 17 | T | 0 | 120 | 7.7 | 0 | — | 1.5 |
| Castilho et al ⁹ | 13 | T | 1 | 107 U-LAs, 180 B-LAs | 15.4 | 7.7 | 0 | 5.5 |
| Our experience | 4 | T | 0 | 105 | 0 | 0 | 0 | 3.75 |

B-LA, bilateral laparoscopic adrenalectomy; NS, not specified; R, retroperitoneal approach; T, transperitoneal approach; U-LA, unilateral laparoscopic adrenalectomy.

^{*}The mean operative time for all cases, including combination procedures and B-LA, was 130.2 minutes (range, 43–406 minutes).

[†]The median operative time was 154 minutes (range, 110–186 minutes), including the bilateral case (160 minutes).

adrenal gland and to use an endosurgical bag to remove the specimen. In our patients, we did not observe neoplastic relapse, and the 2 children with malignant tumors (neuroblastoma; International Neuroblastoma Staging System stage 1) continue to be symptom free at 42 months and at 15 months after surgery.

Furthermore, most endocrine surgeons recommend an open approach in case of large adrenal masses with characteristics of malignancy, because of the risk for dissemination. To choose the correct approach, we followed the International Pediatric Endosurgery Group guidelines, which state that lesions without vascular encasement and adjacent organ involvement and with the greatest dimension <6 cm on preoperative imaging are eligible for the laparoscopic approach.²⁷ As shown in Table 2, on imaging, the malignant lesions measured 4.7 and 4.8 cm. However, the neuroblastoma that previously measured 4.8 cm turned out to have a length of 6.4 cm on postoperative pathologic examination. Nevertheless, this patient had no recurrence of disease at 15-month follow-up. Considering that the median time to relapse in neuroblastoma is approximately 13 months,²⁸ our

experience suggests that laparoscopic adrenalectomy, if performed by a highly skilled laparoscopic surgeon, may be feasible and safe even for the treatment of large, malignant adrenal lesions. Therefore, we suggest that further studies be conducted to define new dimensional criteria for malignant adrenal masses eligible for laparoscopic resection. For now, it is important to remember that the laparoscopic approach should be reserved only for patients with well-circumscribed adrenal lesions, without invasive and infiltrative disease.

CONCLUSIONS

Although the patient cohort was very limited, the present study highlights the safety, feasibility, and advantages of the laparoscopic approach for the treatment of both benign and malignant adrenal masses in children. In fact, all surgeries were successfully performed with excellent intraoperative and postoperative results, without procedure-related morbidity or mortality, and with excellent follow-up outcomes. In addition, laparoscopic adrenalectomy showed good results in the resection of malignant

lesions >6 cm, suggesting that the dimensional cutoff for the eligibility for laparoscopy should be revised.

Moreover, we found the lateral transperitoneal approach to be the best procedure, because it offers a large working space with a clear view of the structure, permitting a controlled resection with a short operative time.

It is clear that more studies are necessary to obtain significant results, and we believe that prospective multicenter studies may resolve the problem of the representativeness of the sample of patients.

References:

1. Nerli RB, Reddy MN, Guntaka A, et al. Laparoscopic adrenalectomy for adrenal masses in children. *J Pediatr Urol.* 2011;7(2):182–186.
2. Lopes RI, Dénes FT, Bissoli J, et al. Laparoscopic adrenalectomy in children. *J Pediatr Urol.* 2012;8(4):379–385.
3. Gagner M, Lacroix A, Bolte E. Laparoscopic adrenalectomy in Cushing's syndrome and pheochromocytoma. *N Engl J Med.* 1992;327(14):1033.
4. Vargas HI, Kavoussi LR, Bartlett DL, et al. Laparoscopic adrenalectomy: a new standard of care. *Urology.* 1997;49:673–678.
5. de Canniere L, Michel L, Hamoir E, et al. Multicentric experience of the Belgian group for Endoscopic Surgery (BGES) with endoscopic adrenalectomy. *Surg Endosc.* 1997;11:1065–1067.
6. Filippini S, Guerreiri M, Arnaldi G, et al. Laparoscopic adrenalectomy: a report on 50 operations. *Eur J Endocrinol.* 1998;138:548–553.
7. Bendinelli C, Materazzi G, Puccini M, et al. Laparoscopic adrenalectomy. A retrospective comparison with traditional methods. *Minerva Chir.* 1998;53:871–875.
8. Acosta E, Pantoja JP, Gamino R, et al. Laparoscopic versus open adrenalectomy in Cushing's syndrome and disease. *Surgery.* 1999;126:1111–1116.
9. Castilho LN, Castillo OA, Denes FT, et al. Laparoscopic adrenal surgery in children. *J Urol.* 2002;168:221–224.
10. Gil-Cardenas A, Cordon C, Gamino R, et al. Laparoscopic adrenalectomy: lessons learned from an initial series of 100 patients. *Surg Endosc.* 2008;22:991–994.
11. Skarsgard ED, Albanese CT. The safety and efficacy of laparoscopic adrenalectomy in children. *Arch Surg.* 2005;140:905–908.
12. Stanford A, Upperman JS, Nguyen N, et al. Surgical management of open vs. laparoscopic adrenalectomy: outcome analysis. *J Pediatr Surg.* 2002;37:1027–1029.
13. Sukumar S, Jadhav S, Nair B, et al. Laparoscopic adrenal surgery in children: lessons from a single centre experience. *J Minim Access Surg.* 2011;7(2):141–144.
14. Heloury Y, Muthucumaru M, Panabokke G, et al. Minimally invasive adrenalectomy in children. *J Pediatr Surg.* 2012;47(2):415–421.
15. Eassa W, El-Sherbiny M, Jednak R, et al. The anterior approach to retroperitoneoscopic adrenalectomy in children: technique. *J Pediatr Urol.* 2012;8(1):35–39.
16. De Lagausie P, Berrebi D, Michon J, et al. Laparoscopic adrenal surgery for neuroblastomas in children. *J Urol.* 2003;170(3):932–935.
17. De Barros F, Romão RL, de Pinho-Apezato ML, et al. Laparoscopic adrenalectomy in children for neuroblastoma: report of case series. *Surg Laparosc Endosc Percutan Tech.* 2012;22(1):79–81.
18. St Peter SD, Valusek PA, Hill S, et al. Laparoscopic adrenalectomy in children: a multicenter experience. *J Laparoendosc Adv Surg Tech A.* 2011;21(7):647–649.
19. Lopez PJ, Pierro A, Curry JI, et al. Retroperitoneoscopic adrenalectomy: an early institutional experience. *J Pediatr Urol.* 2007;3:96–99.
20. Laje P, Mattei PA. Laparoscopic adrenalectomy for adrenal tumors in children: a case series. *J Laparoendosc Adv Surg Tech A.* 2009;19(Suppl 1):S27–S29.
21. Saad DF, Gow KW, Milas Z, et al. Laparoscopic adrenalectomy for neuroblastoma in children: a report of 6 cases. *J Pediatr Surg.* 2005;40(12):1948–1950.
22. Kadamba P, Habib Z, Rossi L. Experience with laparoscopic adrenalectomy in children. *J Pediatr Surg.* 2004;39(5):764–767.
23. Miller KA, Albanese C, Harrison M, et al. Experience with laparoscopic adrenalectomy in pediatric patients. *J Pediatr Surg.* 2002;37(7):979–982.
24. Pampaloni E, Valeri A, Mattei R, et al. Initial experience with laparoscopic adrenal surgery in children: is endoscopic surgery recommended and safe for the treatment of adrenocortical neoplasms? *Pediatr Med Chir.* 2004;26(6):450–459.
25. Kelleher CM, Smithson L, Nguyen LL, et al. Clinical outcomes in children with adrenal neuroblastoma undergoing open versus laparoscopic adrenalectomy. *J Pediatr Surg.* 2013;48(8):1727–1732.
26. Al-Shanafey S, Habib Z. Feasibility and safety of laparoscopic adrenalectomy in children: special emphasis on neoplastic lesions. *J Laparoendosc Adv Surg Tech A.* 2008;18(2):306–309.
27. International Pediatric Endosurgery Group. IPEG guidelines for the surgical treatment of adrenal masses in children. *J Laparoendosc Adv Surg Tech A.* 2010;20(2):vii–ix.
28. London WB, Castel V, Monclair T, et al. Clinical and biologic features predictive of survival after relapse of neuroblastoma: a report from the International Neuroblastoma Risk Group project. *J Clin Oncol.* 2011;29(24):3286–3292.