

Application of Belarusian-Made Self-Expanding Ti-Ni Stents in the Treatment of Obstructing Colorectal Cancer

VL Denisenko^{1,6*}, YM Gain², VV Rubanik^{3,4}, EV Denisenko⁶, VV Rubanik Jr^{3,4}, AV Erushevich⁵, GM Shappo⁶, EI Veremei⁷ and VA Jurba⁷

¹Vitebsk Regional Clinical Specialized Centre, Belarus

²The Belarusian Medical Academy of Postgraduate Education, Minsk, Belarus

³The Institute of Technical Acoustics of the National Academy of Sciences of Belarus, Belarus

⁴Vitebsk State Technological University, Belarus

⁵Vitebsk Regional Clinical Oncological Centre, Belarus

⁶Vitebsk State Medical University, Belarus

⁷Vitebsk State Academy of Veterinary Medicine, Vitebsk, Belarus

***Corresponding Author:** VL Denisenko, Vitebsk Regional Clinical Specialized Centre, Belarus.

Received: March 09, 2020; **Published:** January 18, 2021

Abstract

Introduction: A Belarusian-made self-expanding titanium nickelide stent has been successfully used in the treatment of patients with obstructing colorectal cancer.

The Purpose of the Study: The study aims at determining the effectiveness of Belarusian-made stents in the treatment of patients with obstructing colorectal cancer.

Materials and Methods: Under the Import Substitution Programme, Belarusian researchers (the Joint Laboratory of Advanced Materials and Technologies of the Institute of Technical Acoustics of the National Academy of Sciences of Belarus and Vitebsk State Technological University) and employees of Vitebsk Regional Clinical Specialized Centre, Vitebsk Regional Clinical Oncological Centre and the Belarusian Medical Academy of Postgraduate Education developed a technology for manufacturing self-expanding titanium nickelide colonic stents that are designed to serve as a wire frame for holding open the bowel lumen and for further stenting of the narrowing when inserted into the narrowed part of the tumor. These stents successfully underwent all preclinical studies. Their clinical trial was conducted at Vitebsk Regional Clinical Specialized Centre where they were used for symptomatic treatment of a patient presenting with complicated colorectal cancer.

Results and Discussion: Given that the estimated cost of the Belarusian-made product for medical purposes in case of its mass manufacturing would be lower than that of imported counterparts, the first application of a self-expanding titanium nickelide stent made by the Joint Laboratory of Advanced Materials and Technologies of the Institute of Technical Acoustics and Vitebsk State Technological University holds out a hope of successful implementation of the National Import Substitution Programme in this area.

Conclusion: The development of the first Belarusian self-expanding titanium nickelide colonic stent and its first successful clinical application in the setting of urgent surgery suggest that further implementation of minimally invasive surgery for colon stenotic lesions caused by malignancy is possible both with regard to temporary restoration of colonic patency (as a preparatory measure for radical intervention) and with regard to permanent colonic stenting in the tumor area (in order to improve the quality of life for patients with inoperable colonic disease).

Keywords: Stenting; Colorectal Cancer; Stent; Titanium Nickelide

Introduction

Colorectal cancer (CRC) is one of the most frequent forms of malignancy in most developed countries [1,2]. The most common colorectal cancer complication is bowel obstruction. Left-sided colon cancer predominantly develops. Surgical interventions in this group of patients are associated with high mortality rates (10 - 36%) [3-5]. Interventions in the setting of colonic ileus of tumoral genesis considerably differ from one another both with regard to their extent and extremity. 70% of patients presenting with complicated left-sided colon cancer undergo Hartmann's procedure with stoma formation from the proximal section of the bowel [6,7]. At present, more than a half of malignant tumors are diagnosed in patients aged 65 or over, with the annual morbidity rate showing steady growth approximately by 15% overall in the last 30 years with up to 450 incidence cases per 100,000 people [1-8]. According to the Association of Coloproctology of Great Britain and Ireland (ACPGBI), the mortality rate due to colonic cancer is rising, with a 1.8-time higher mortality risk in patients aged 65 - 74, a 3.5-fold risk increase in patients aged 75 - 84, and five-fold mortality risk increase in those over 85 years of age after elective colorectal resection [9-12]. Emergency situations requiring urgent actions (first and foremost, obstruction and/or bowel perforation) occur more often in 40 - 50% of elderly patients. In this setting, a palliative surgical procedure is much more likely to be performed leading to a long (at times indefinite) delay in radical surgery [13-20].

In the setting of colorectal cancer complicated by bowel obstruction, the most common type of radical intervention used in emergency surgery is bowel resection with formation of an end colostomy (so called "obstructive resection"). However, good immediate outcomes of extended and combined resection with primary anastomosis in patients with left-sided large bowel obstruction have been reported [2,3,5,7]. Over the recent years, along with conventional approaches most developed countries have been introducing new methods to treat colorectal cancer complicated by bowel obstruction. These methods are based on colonic stenting in a malignant area (with US, South Korean or Chinese stents being used). In many countries, this technology is deployed to resolve colonic obstruction in inoperable patients as an alternative to conventional colostomy and to prepare a patient for radical surgery avoiding a two-stage surgical procedure. WL Law, *et al.* (2004) deployed South Korean self-expanding metallic stents in patients presenting with advanced colorectal cancer complicated by bowel obstruction. The surgical intervention was associated with considerable morbidity (25%), in 13% of cases protective colostomy was required [21].

IE Hat'kov, *et al.* (2009) analyzed the outcomes of stent placement in 4 patients presenting with obturation of the bowel lumen by malignant tumor (2 patients) and non-malignant stricture of entero-enteric anastomosis (2 patients). In all cases successful decompression was achieved using self-expanding nitinol stents of various designs from different manufacturers under X-ray television and endoscopy guidance. The authors assessed the effectiveness of stents on the basis of their first application both as a preoperative stage before radical surgery and as palliative treatment. authors are increasingly using stents in selective and emergency colorectal surgery; however, these stents are foreign-made [22].

A promising area for deployment of self-expanding metallic stents for medical purposes is their use for treatment of complicated colorectal cancer. In 1991, M Dohmoto, *et al.* presented the first use of metallic stents as palliative treatment to manage malignant colonic obstruction [23].

In 1992, RR Keen and CP Orsay and in 1994, E Tejero, *et al.* published first reports on endoscopic colonic stenting in patients with tumor-induced stenosis as the first stage before a radical surgical intervention [26]. Since then, colonic endoprotheses have been gradually gaining wider clinical use for treatment of complicated colorectal cancer and corrosive strictures of colonic anastomoses [24-27].

In many cases, stent placement allows avoiding emergency surgical interventions, decreasing postoperative mortality rate, and reducing intensive care unit stay, which gives a number of authors the possibility to consider this approach to be palliative treatment for malignant colonic obstruction [24,26,28- 30].

To a great extent, the progress in development of minimally invasive treatment methods for advanced colorectal cancer is related to improved endoscopic equipment (in particular, flexible endoscopes). Specifically, AG Fedorov, *et al.* (2011) developed and put into practice a new laparoscopic-assisted colostomy procedure to decrease postoperative complications in patients with obturation bowel obstruction that made it possible to reduce postoperative morbidity. However, this procedure doesn't allow for fewer interventions nor does it improve a patient's quality of life. Over the last decade, endosurgical procedures have gained a wider use for restoring the passage of intestinal contents. They can be applied as a complimentary measure as well as an alternative to surgical treatment of malignant colonic obstruction. These are the minimally invasive bowel decompression procedures that video-assisted placement of self-expanding metallic stents into the narrowed area of the colon belongs to.

In 2009, IE Hat'kov, *et al.* presented the results of treatment provided to 4 patients with severe stenosis of the bowel lumen caused by malignant tumor and benign strictures of interintestinal anastomosis (2 patients for each medical condition). In all cases, successful bowel decompression was achieved by means of endoscopic placement of nitinol self-expanding stents of various designs for palliation [31].

In line with the national principles of urgent medical care for patients with obturation bowel obstruction caused by right-sided tumor, the overwhelming majority of surgeons perform right-sided hemicolectomy with formation of primary ileotransversoanastomosis (in case of evident ileus, it is supplemented with nasogastrintestinal decompression using a probe) [27]. Two types of urgent interventions are used in patients with left-sided colon obstruction (most common):

- 1) Without formation of anastomosis (double-barrel colostomy and Hartmann's procedure with exteriorization of the proximal end colostomy);
- 2) Bowel resection with formation of primary anastomosis (with proximal protective entero- or colostomy or with nasogastrintestinal decompression using a probe) [27]. Herewith, the number of surgical interventions and the character of the surgical intervention completion in this category of patients often differ which still remains the subject of heated discussions [25,27,28].

Taking into account the serious general condition of most patients with obturation bowel obstruction and the risk of severe complications after radical and primary reconstructive surgical procedures, a number of authors consider it reasonable to perform two- or three-stage interventions in these patients, as a rule, starting with formation of proximal colostomy. 1 - 2 months after the elimination of obstruction, the bowel with tumor is resected and anastomosis is performed (2d stage) and subsequently, the colostomy is closed (3d stage) [27]. The comparison of the two abovementioned approaches doesn't show any significant differences in terms of morbidity and mortality, chances of recurrence, and tumor-specific survival [27]. Meanwhile, most surgeons prefer Hartmann's procedure the main advantages of which are removal of the source of tumor growth and elimination of bowel obstruction [6].

A five-year survival rate of 38% is observed in patients who underwent Hartmann's procedure in the setting of obstruction which is slightly lower than in patients after primary reconstructive surgery (41 - 45%) [32]. In any case, colostomy formation is by itself a traumatizing intervention that considerably worsens patients' quality of life; and in 40 - 72% of cases a reintervention aimed at restoration of intestinal continuity may become impossible [27]. In this regard, a number of authors consider it reasonable to perform a single-stage radical removal of tumor with formation of Y-type anastomosis in patients with serious general condition during emergency surgery. This surgery has the following advantages: firstly, a tumor is removed and bowel obstruction is eliminated in a single-stage operation; secondly, a single-stage restoration of colon continuity is performed; thirdly, a formed colostomy to a great extent reduces the risk of an anastomotic leakage; and, fourthly, stoma in this setting is closed using an extraperitoneal technique thus mitigating the risk of intra-abdominal complications. In light of this, practicing surgeons are in need of a minimally invasive technology for malignant colonic obstruction enabling them to perform a follow-up radical intervention with primary restoration of gastro-intestinal tract continuity in critical patients. Endoscopic placement of a self-expanding nitinol stent may serve as such a technique for eliminating colonic obstruction [25-28,31,33].

Along with that, this technique has not been widely used so far; and colorectal SEMS deployment is mainly performed in distal parts of the colon and predominately for palliation in order to provide advanced cancer patients with a better quality of life [30,32,33] as well as to remove postoperative corrosive strictures of anastomoses [32].

Under the Fast-Track Recovery Strategy, Belarusian authors (Denisenko., *et al.*) have started to implement an urgent endoscopic recanalization technique to remove colonic obstruction for the treatment of obstructing colorectal cancer. While remaining in hospital, after the restoration of motor-evacuation function and clinical metabolic compensation a patient undergoes radical intervention with primary restoration of the bowel continuity. It should be noted that for recanalization the authors use Mediola Endo laser (FOTEK, Belarus) and a technology of placing Belarusian self-expanding covered nitinol stents that serve as a wire frame for holding open the bowel lumen in the area of tumor stenosis [26,28,29].

One of the ways to apply the fast-track recovery approach in treating patients with colonic ileus of tumoral genesis is recanalization of the tumor area stenosis using self-expanding metallic stents (to date, stents made in the USA, South Korea, China or the Czech Republic have been used, with their cost starting from 1.1 thousand euros). Furthermore, stenting can be used as a preparation stage before radical surgery as well as for symptom-relieving purposes to provide the long-term natural passage of intestinal contents and motor-evacuation function of the gastro-intestinal tract (without formation of a protective stoma). Under the Import Substitution Programme, Belarusian researchers (the Joint Laboratory of Advanced Materials and Technologies of the Institute of Technical Acoustics of the National Academy of Sciences of Belarus and Vitebsk State Technological University) and employees of Vitebsk Regional Clinical Specialized Centre, Vitebsk Regional Clinical Oncological Centre and the Belarusian Medical Academy of Postgraduate Education developed a technology for manufacturing self-expanding titanium nickelide colonic stents of 18 - 30 mm in diameter and 60 - 160 mm in length that serve as a wire frame for holding open the bowel lumen and for further stenting of the narrowing when inserted into the narrowed part of the tumor.

These stents successfully underwent all preclinical studies [29]. Experimental studies were conducted using 10 rabbits aged 2 - 2.5, with 2.0 - 3.0 kg of bodyweight, of medium finish. At the time of the study all animals were clinically healthy and kept in individual cages with unique numbers. Housing conditions met sanitation and hygiene requirements for this animal species. Under sedation all rabbits underwent placement of self-expanding stents in the shape of a cylindrical frame of 0.8 ÷ 0.9 cm in diameter. To make the stents titanium nickelide (Ti-Ni) was used because of its special physical characteristics: biocompatibility, corrosion resistance, shape memory effect, and super elasticity. The stent is elastic in the initially martensitic state and can be easily compressed at room temperature, which makes it easy to load it into the delivery system. When delivered, the stent warms up to 33°C inside a rabbit's rectum and gradually expands regaining its original shape.

On the 4th day five rabbits were withdrawn from the experiment under anesthesia by means of euthanasia; a macroscopic morphological examination of their internal organs was performed and material for microscopic examination was collected. On the 42^d day, 5 animals were withdrawn from the experiment under anesthesia by means of euthanasia; material for microscopic examination was collected.

Microscopic examination of the colon, paraproctium, liver and kidneys was performed at the Pathological Anatomy Chair of Vitebsk State Medical University. Hematoxylin and eosin were used to stain the tissue specimens.

When self-expanding TiNi stents are deployed, the intestine diameter should be taken into account in order to avoid bowel rupture due to responsive tension of a stent as well as to avoid stent migration and falling out. The obtained experimental data suggest that these stents can be used for restoration of colonic patency [34,35].

To date, surgical tactics for obturation bowel obstruction in the setting of cancer continues to be discussable. No common approaches to the choice of surgical techniques and surgical intervention completion are available which requires further scientific inquiry and search for new ways to solve the problem.

Materials and Methods

One remaining challenge in emergency surgery is treatment of obstructing colorectal cancer complicated by bowel obstruction in aged patients with severe comorbidities. In contemporary medicine (surgery, coloproctology and oncology) the fast-track recovery or fast-track surgery concept is gaining momentum. The idea is based on the use of state-of-the-art advanced approaches including effective utilization of major achievements of the V and VI technological paradigm enabling to reduce the invasiveness of interventions, provide high quality treatment, minimize its duration, decrease the cost of treatment, and as a result achieve as favourable final outcomes as possible. This approach in surgery for complicated colorectal cancer allows performing low traumatic recanalization of the tumor stenosis area and bowel decompression, in a short time (with the patient remaining in hospital) restoring the motor-evacuation function of the bowel (with fast involution of inflammatory and microcirculatory disorders of the intestinal wall), compensating for the function of vital life-support systems, and on a practical level in selective surgery performing radical intervention with primary restoration of gastro-intestinal tract continuity. Such approach makes it possible to reduce mortality and postoperative complications, decrease the total time period of treatment and rehabilitation. It contributes to a considerable reduction in the economic costs of treatment and has an important social impact as a result of a faster and more significant restoration of a patient’s life quality.

Colorectal Ti-Ni stents manufactured at the Institute of Technical Acoustics of the National Academy of Sciences of Belarus underwent successful clinical trials at Vitebsk Regional Clinical Specialized Centre and Vitebsk Regional Clinical Oncological Centre. They can be effectively used to treat malignant tumors of the colon and rectum in order to restore the patency of a stenosed organ.

A colorectal stent is a special elastic metallic or plastic device in the shape of a cylindrical frame (Figure 1) that is inserted into the lumen of hollow organs to hold open the area narrowed by a pathologic process. The stent permits the flow of body fluids widening the lumen of a hollow organ (esophagus, bowel, bile ducts). Stenting is more effective and has a long-term impact than balloon dilatation, whilst the risk of recurrent stenosis or perforation is lower.




Figure 1: A colorectal stent (a) and the weaving direction of nitinol threads (b).

Titanium nickelide TN1 wire of 0.36 mm in diameter for medical purposes manufactured by OOO Promyshlennyj tsentr MATEK-SPF (Russia) was used to make the colorectal stent. The yield strength of the material is 650 - 700 MPa, the tensile set value after the first loading-unloading cycle is 0.3%. The alloy shows the super elastic effect when strained up to 5% (Figure 2).

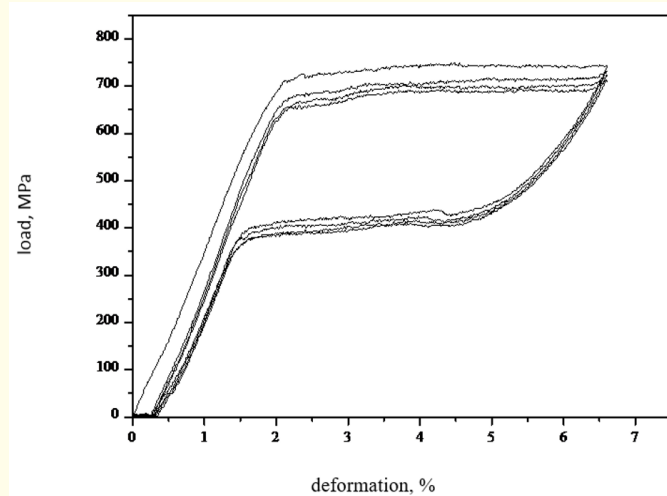


Figure 2: The Ti-Ni wire stress-strain curve during loading-unloading.

The most advantageous self-expanding stent design of a spiral wire mesh was used (Figure 1) [36,37]. The deployed stent body diameter was 30 mm and the flare diameter was 36 mm, the length was 135 mm, the mesh size was 4 x 4 mm. The special design of the implant made the patient feel comfortable after its deployment. The elastic stent ends don't have sharp edges ensuring that the intestinal walls are not damaged when the stent is inserted or removed. The developed equipment allows for manufacturing stents of various lengths, diameters and design and their successful implementation to eliminate rectum obstruction.

The wire was woven onto specially designed equipment with further heat treatment in an inert gas atmosphere thus modelling the stent at temperature above 36°C, i.e. at the temperature of the human body [39]. The surface of this stent is formed of hard but flexible and elastic elements forming multithreaded helical coils. The monofilament ends are connected in the central part of the stent.

The slope of elastic elements changes with small axial loads but owing to the woven monofilament the general shape of the mesh prosthesis mainly remains the same when the stent diameter is reduced. Such design of the woven stent enables to reduce the diameter to a relatively large extent in a contracted configuration whilst its length is changed relatively little [36,38].

The colorectal stent delivery system (Figure 3) consists of a shaft (guide member) with an olive tip on the distal end; a pusher on the proximal end of the internal part; an external sheath coaxial to the internal part; a handle with a locking device in the form of a clamp made fast on the tube heel; and a handle fixed on the proximal end of the pusher. The internal and external parts have distal and proximal ends. The shaft (guide member) contacts the internal stent diameter. Before the stent expands it is held in the internal diameter of the external sheath. When the stent expands the shaft (guide member) can move longwise along the internal part allowing the stent to move distally in the external sheath, while the external sheath is drawn off to allow expansion of the stent. Several stent delivery device configurations have been developed. They differ in clamp and handle design.

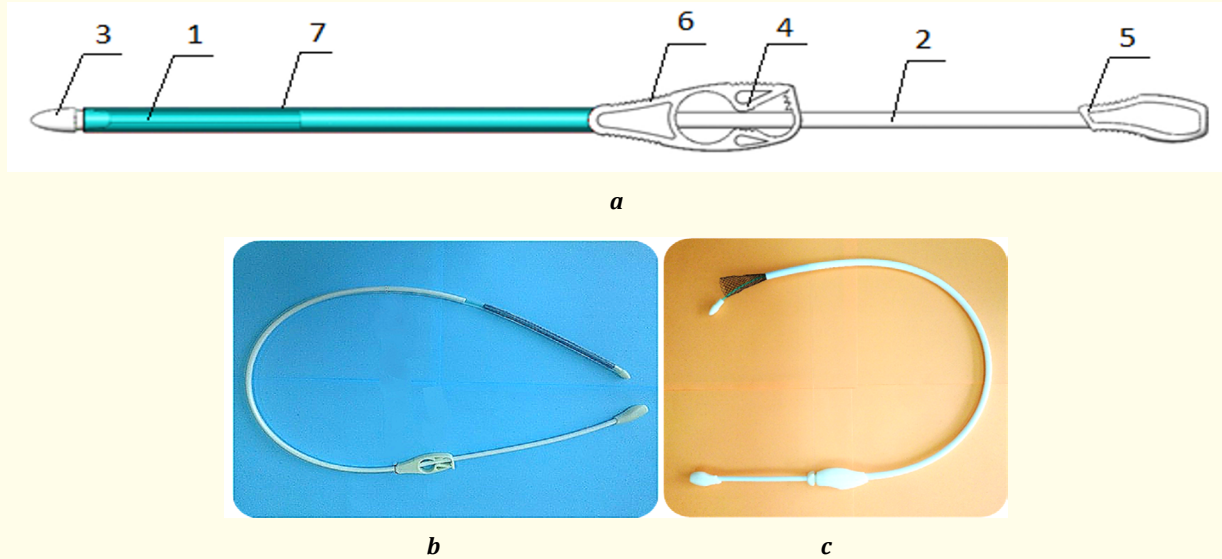


Figure 3: The delivery device: a - the general view in the original state; b - preloaded; c - when the stent is released. 1 - shaft; 2 - pusher; 3 - olive tip; 4 - locking device; 5, 6 - handle; 7 - external sheath.

The comparative analysis of calorimetric dependencies (Figure 4) shows that the manufactured stent is as good as South Korean stents produced by M.I.Tech Co., Ltd. It underwent clinical trials at Vitebsk Regional Clinical Specialized Centre and Vitebsk Regional Clinical Oncological Centre where it was used for symptomatic treatment of 6 patients. After the Technical Specifications are registered, Belarusian stents can be introduced into the Belarusian market (Figure 5).

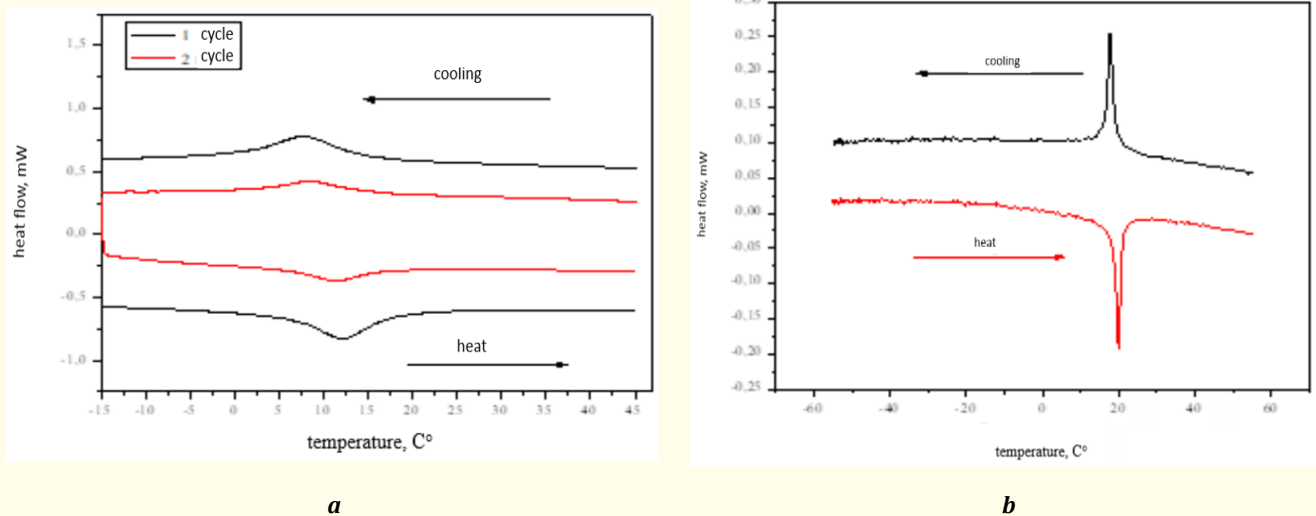


Figure 4: Calorimetric dependencies of colorectal stents: a - HANAROSTENT, b - ITA of the NAS of Belarus.




Figure 5: The external view of the finished product: a colorectal TiNi stent and a delivery system.

It is clear that thermomechanical properties of TiNi wire should provide the necessary elastic and load bearing characteristics of the stent itself, and these characteristics should be as good as those of foreign counterparts.

The dynamometer IP 5158-5 was used to study the elastic and load bearing properties of the colorectal stent under different strain conditions: lateral and longitudinal contraction, three-point bending at 18°C and 25°C - the temperature range of stent loading into the delivery system; 36°C and 42°C is the temperature range at which the stent is inside the human body.

At present, no common standard for stent trials are available and every manufacturer tests their products according to their own guidelines. Most of them are based on measuring the elastic and load bearing properties of stents under different strain schemes and at different temperatures (Figure 6-8). In our case the stent was subjected to 50-percent lateral and longitudinal contraction from its initial condition. The error of the force measurement was $\pm 0.1\text{N}$. To test the three-point bending the stent was placed between three supporting members, where after the central support element was repositioned by 30 mm and the force was measured (Figure 8). As can be seen, the force developed by the stent is $3 \div 4\text{N}$ at the temperature of its loading into the delivery system and $6 \div 6.4\text{N}$ at the operating temperature.

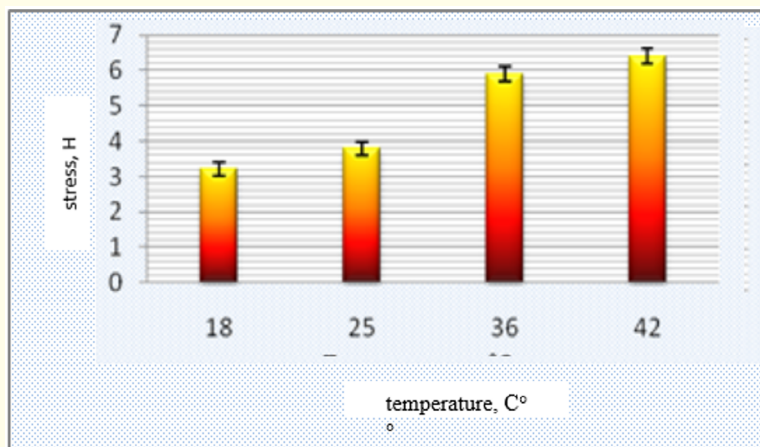


Figure 6: Diagram of the stent elastic and load bearing properties under lateral contraction.

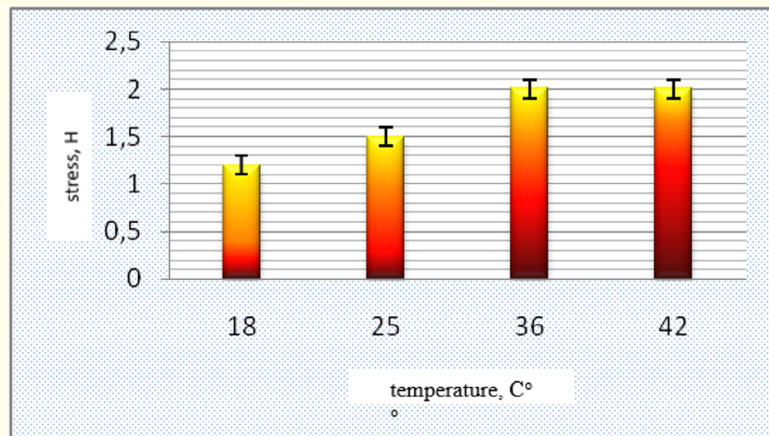


Figure 7: Diagram of the stent elastic and load bearing properties under longitudinal contraction.

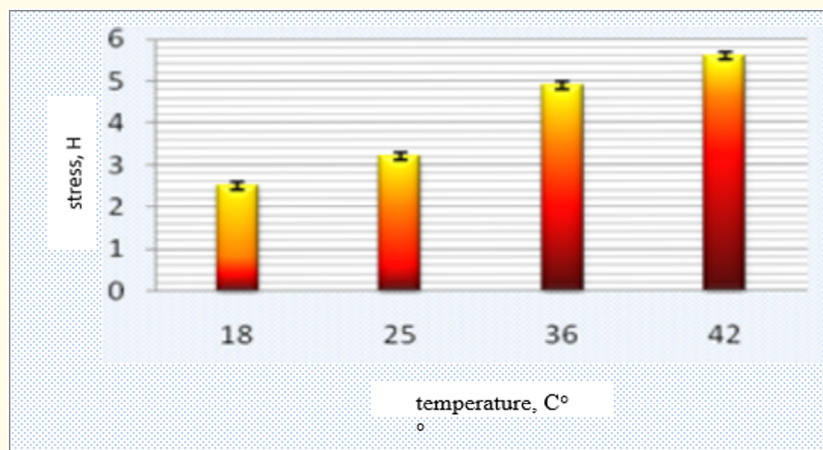


Figure 8: Diagram of the stent elastic and load bearing properties under three-point bending.

The finished stent was placed into an individual plastic package that protects the stent from biological and mechanical effects during its transportation (Figure 9) and together with the packed delivery system it was exposed to sterilization.



Figure 9: The view of packed colorectal stents.

It should be noted that the developed technology enables to manufacture stents with patient-specific characteristics varying in wire diameter, stent geometry, and heat treatment schedules.

Test stent lots underwent technical and sanitary trials. Technical specifications BY 300229851.006-2016 were obtained for production of self-expanding colorectal stents made of TiNi shape memory alloys in the Republic of Belarus.

Results and Discussion

Six patients with severe comorbidities (CHD, grade II angina of effort, persistent atrial fibrillation, chronic bronchitis, lung emphysema, pneumosclerosis, respiratory failure 2, liver metastases) fell into the IV category of the surgical risk score in accordance with the American Society of Anesthesiologists' physical status system.

The patients were admitted to the Proctology Unit of Vitebsk Regional Clinical Specialized Centre from 23.03.2016 to 25.07.2016 and the Abdominal Unit of Vitebsk Regional Clinical Oncological Centre with complains of abdominal bloating, nausea, failure to pass gas and stool for 3 days.

Vishnevsky's diagnostic maneuver had no effect. After a short-term (2-hour) preparation including transfusion of potassium polarizing solution, crystalloid and colloid solutions, emergency fibrocolonoscopy was performed. In 3 cases it confirmed obstructing tumor in the rectosigmoid colon, in 2 cases - sigmoid cancer and in one case - descending colon cancer. Fibrocolonoscopy revealed that the tumor blocked 73% - 83% of the bowel lumen. In 3 cases before deploying the Belarusian self-expanding Ti-Ni stent laser recanalization was performed using high-intensity pulsed laser radiation with the wavelength of 1.06 μm and the power of 20 - 25W. A Fotek LK-50 solid state pulsed laser for endoscopic purposes was used (Mediola Endo, FOTEK, Belarus) in assembly with an endoscopic rack to examine the colon (the wavelength is 1.064 μm , the pulse repetition frequency at maximum radiation power doesn't exceed 50 Hz, the laser hazard class is IV, the maximum pulse energy is 1.2J, the maximum average power is 60W, the pulse length is 300 ms, the maximum power consumption is 2.5 kW). The delivery device for the self-expanding tube-shaped prosthesis was inserted through the stenosis area. Through the catheter opening, the guide-wire was introduced into the colon 10 cm more proximal of the stenosis upper edge. Over the guide-wire the Belarusian Ti-Ni self-expanding colorectal stent of 30 mm in diameter and 135 mm in length was deployed. The position of the stent in the colon was checked. The whole colonoscopy procedure with the stent placement took 32 - 40 minutes. No complications after the procedure were recorded. A follow-up abdominal X-ray was performed (Figure 10). After the stent placement the siphon enema was used and that allowed for stool and flatus profuse discharge. The patients were prescribed with Epson salt and liquid petrolatum orally. Infusion therapy with the administration of polyelectrolyte solutions, cardiac glycosides, medication with rheological effects was performed. Cefazolin 1.0g 3 times a day and Fragmin 2.5g once a day subcutaneously were prescribed. The comorbidity was addressed. The signs of bowel obstruction were clinically resolved within 5 hours after the stent placement. Starting from day two the patient received enteral nutrition feeding.

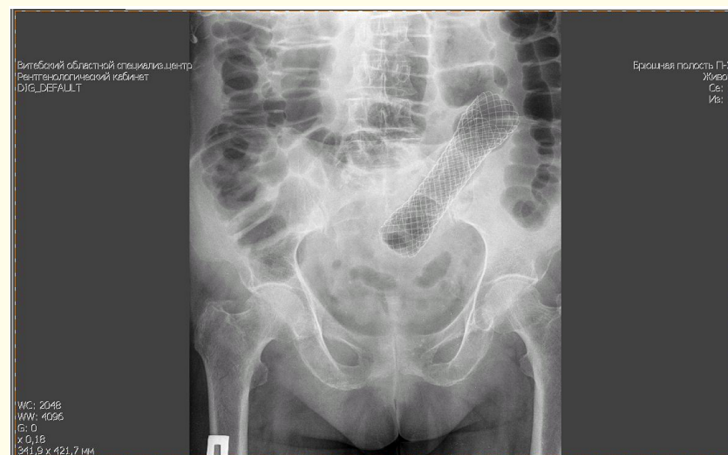

Figure 10: A survey radiograph of the abdominal cavity after the self-expanding stent placement into the sigmoid colon.

No postoperative complications were recorded. The duration of treatment was 7 ± 3.2 in patient days.

The patients were examined 2 weeks after the stent placement. The position of the stents didn't change. No failure of the contents to pass through the bowel, no local bowel wall complications, no tumor in-growth were observed.

Given that the estimated cost of the Belarusian-made product for medical purposes in case of its mass manufacturing would be lower than that of imported counterparts, the first application of a self-expanding titanium nickelide stent developed by the Joint Laboratory of Advanced Materials and Technologies of the Institute of Technical Acoustics and Vitebsk State Technological University, together with the employees of Vitebsk Regional Clinical Specialized Centre, Vitebsk Regional Clinical Oncological Centre and the Belarusian Medical Academy of Postgraduate Education, holds out a hope of successful implementation of the National Import Substitution Programme in this area.

Conclusion

1. Endoscopic placement of a self-expanding metallic colorectal stent made of titanium nickelide allows performing early ante-grade decompression of the gastro-intestinal tract with fast-track restoration of motor-evacuation function and clinical metabolic compensation of the patient (without laparotomy and formation of intestinal fistula) in the setting of obstructing colorectal cancer complicated by bowel obstruction through minimally invasive intervention.
2. The development of the first Belarusian self-expanding Ti-Ni colorectal stent and its first successful clinical application in the setting of urgent surgery suggest that further development of minimally invasive surgery for colon stenotic lesions caused by malignancy is possible both with regard to temporary restoration of colonic patency (as a preparatory measure for radical intervention) and with regard to permanent colonic stenting in the tumor area (in order to improve the quality of life for patients with inoperable colonic disease).

Bibliography

1. Kajzer A. "Kolorektal'naja hirurgija [Colorectal surgery]". Moscow: BINOM (2011).
2. Sukonko O and Krasnogo S. "Algoritmy diagnostiki i lechenija zlokachestvennyh novoobrazovanij [Algorithms for the diagnosis and treatment of malignancies]". Moscow: Professional'nye izdaniya (2012).
3. WHO Mortality Database (1999): 1994-1997.
4. Bazin I. "Rak tolstoj kishki – sostojanie problemy [Colon cancer - the state of the problem]". *Russkij medicinskij zhurnal* 11.11 (2003): 8-15.
5. Hanevich M. "Kolorektal'nyj rak. Vybor hirurgicheskogo lechenija pri tolstokishečnoj neprohodimosti [Colorectal cancer. The choice of surgical treatment of colonic obstruction]". St. Petersburg: Agraf (2008).
6. Dunlop M. "Colorectal cancer". *British Medical Journal* 314 (1997): 1882-1885.
7. Kohnjuk V. "Kolorektal'nyj rak [Colorectal cancer]". Minsk: Harvest (2005).
8. Lee K. "Comparison of uncovered stent with covered stent for treatment of malignant colorectal obstruction". *Gastrointestinal Endoscopy* 66 (2007): 931-936.
9. Davidson R and Sweeney W. "Endoluminal stenting for benign colonic obstruction". *Surgical Endoscopy* 12 (1998): 353-354.

10. Ivoghli A. "Der Stellenwert minimal-invasiver Operationstechniken im Fast-track-Konzept für die Gefäßmedizin". *Gefässchirurgie* 15.3 (2010): 176-182.
11. Recart A. "Efficacy and Safety of Fast-Track Recovery Strategy for Patients Undergoing Laparoscopic Nephrectomy". *Journal of Endourology* 19.10 (2005): 1165-1169.
12. Geiger TM., et al. "Stent placement for benign colorectal stenosis: case report, review of the literature and animal pilot data". *The International Journal of Colorectal Disease* 23.10 (2008): 1007-1012.
13. Goligher I and Hafner CD. "The treatment of acute obstruction or perforation with carcinoma of the colon and rectum". *British Journal of Surgery* 450 (1957): 270-274.
14. Choi J., et al. "Interventional management of malignant colorectal obstruction: use of covered and uncovered stents". *Korean Journal of Radiology* 8 (2007): 57-63.
15. Francis N., et al. "Manual of Fast Track Recovery for Colorectal Surgery". Toronto: Springer (2011).
16. Soto S., et al. "Endoscopic treatment of acute colorectal obstruction with self-expandable metallic stents". *Surgical Endoscopy* 20 (2006): 1072-1076.
17. Ptok H., et al. "Palliative stent implantation in the treatment of malignant colorectal obstruction". *Surgical Endoscopy* 20 (2006): 909-914.
18. Tsurumaru D., et al. "Self-expandable metallic stents as palliative treatment for malignant colorectal obstruction". *Abdom. Im*, 32 (2007): 619-623.
19. Small A., et al. "Expandable metal stent placement for benign colorectal obstruction: outcomes for 23 cases". *Surgical Endoscopy* 22 (2008): 454-462.
20. Garcia-Cano J., et al. "Use of self-expanding metal stents to treat malignant colorectal obstruction in general endoscopic practice". *Gastrointestinal Endoscopy* 64 (2006): 914-920.
21. Law W., et al. "Palliation for advanced malignant colorectal obstruction by self-expanding metallic stents: prospective evaluation of outcomes". *Diseases of the Colon and Rectum* 47.1 (2004): 39-43.
22. Hat'kov I., et al. "Pervyj opyt kolorektal'nogo stentirovaniya [The first experience of colorectal stenting]". *Jendoskopicheskaja Hirurgija* 6 (2009): 17-22.
23. Dohmoto M. "New method: endoscopic implantation of rectal stent in palliation of malignant stenosis". *Endoscopia Digestiva* 35 (1991): 912-913.
24. Kozarek R and Baron T. "Self-Expandable Stents in the Gastro-intestinal Tract". New York, Heidelberg, Dordrecht, London: Song Springer (2013).
25. Fedorov AG. "Vosstanovlenie passazha sodержimogo tolstoj kishki pri opuholevoj neprohodimosti [Recovery passage content in colon tumor obstruction]". *Tihookeanskij Medicinskij Zhurnal* 4 (2011): 7-13.

26. Denisenko VL and Gain JuM. "Lechenie kolorektal'nogo raka, oslozhnjonnogo kishechnoj neprohodimost'ju, s ispol'zovaniem meto-
diki uskoren'nogo vyzdorovlenija [Treatment of colorectal cancer complicated by intestinal obstruction, with fast-track recovery
procedure]". *Vestnik hirurgii im. I. I. Grekova* 171.5 (2012): 69-72.
27. Kalinin AE and Kalinin EV. "Vybor metoda ustraneniya obturacii tolstokishechnoj neprohodivosti [The choice of method to
eliminate obstructive bowel obstruction]". *Klinicheskaja Onkologija* 11.3 (2013): 1-6.
28. Denisenko VL and Gain JuM. "Oslozhnenija kolorektal'nogo raka: problemy i perspektivy [Complications of colorectal cancer: prob-
lems and prospects]". *Novosti hirurgii* 10.1 (2011): 103-111.
29. Denisenko VL, et al. "Ispol'zovanie tehnologii bystrogo vyzdorovlenija («Fast-Track Recovery Surgery») v hirurgicheskom lechenii
oslozhnjonnogo kolorektal'nogo raka [Using the quick recovery technology («Fast-Track Recovery Surgery») in the surgical treat-
ment of the complicated colorectal cancer]". *Jekstrennaja Medicina*, 1 (2012): 67-75.
30. Pirlet I, et al. "Emergency preoperative stenting versus surgery for acute left-sided malignant colonic obstruction: a multicenter
randomized controlled trial". *Surgical Endoscopy* 25 (2011): 1814-1821.
31. Hat'kov IE. "Pervyj opyt kolorektal'nogo stentirovaniya [The first experience of colorectal stenting]". *Jendoskopicheskaja Hirurgija* 6
(2009): 17-22.
32. Repici A, et al. "A retrospective analysis of early and late outcome of biodegradable stent placement in the management of re-fractory
anastomotic colorectal strictures". *Surgical Endoscopy* 27 (2013): 2487-2491.
33. Keränen I, et al. "Stenting for malignant colorectal obstruction: a single-center experience with 101 patients". *Surgical Endoscopy* 26
(2012): 423-430.
34. Denisenko VL, et al. "Vlijanie metallicheskogo samorasshirjajushhegosja TiNi stenta na organizm zhivotnyh v jeksperimente [Effect
of self-expanding metal stent TiNi on animals in experiments]". *Nauka Molodyh* 1 (2015): 6-17.
35. Denisenko VL, et al. "Pervyj opyt uspeshnogo primenenija samorasshirjajushhegosja nikelid-titanovogo stenta belorusskogo proiz-
vodstva v lechenii stenozirujushhego kolorektal'nogo raka [The first experience of the successful application of a self-expanding
stent titanium-nickel alloy produced in Belarus in the treatment of stenosis of colorectal cancer]". *Hirurgija Vostochnaja Evropa* 18.2
(2012): 282-289.
36. Stent: pat. 2089131 Ross. Federacija, A61F2/06, A61F2/01/ S.A. Pulnev, A.V. Karev, S.V. Schukin, № 93058166/14; zajavl. 28.12.93;
opubl. 10.09.1997.
37. Karev AV. "Ispol'zovanie stenta iz mononiti nitinola [The use of nitinol stent monofilament]". Sankt-Peterburg (2008).
38. Rubanik VV, et al. "Kolonoskopicheskij TiNi stent. Proceedings of the Mezhdunarodnaja nauchno-tehnicheskaja konferencija «Novye
tehnologii i materialy, avtomatizacija proizvodstva»". Br GTU, Brest (2014,): 111-113.
39. Otsuka K and Wayman CM. "Shape memory materials". Cambridge University Press (1998).

Volume 8 Issue 2 February 2021

©All rights reserved by VL Denisenko, et al.