

Original Research Article

A six-year study of leiomyomata with emphasis on lipoleiomyoma

C. P. Manjula, Naina Mary Simon, Kusuma Venkatesh*, Fazeela Muneer,
M. Hemalata, Rangaswamy R.

Department of Pathology, KIMS, Bengaluru, Karnataka, India

Received: 29 October 2018

Accepted: 30 November 2018

***Correspondence:**

Dr. Kusuma Venkatesh,

E-mail: kusumav28@gmail.com

Copyright: © the author(s), publisher and licensee Medip Academy. This is an open-access article distributed under the terms of the Creative Commons Attribution Non-Commercial License, which permits unrestricted non-commercial use, distribution, and reproduction in any medium, provided the original work is properly cited.

ABSTRACT

Background: Leiomyoma is the most common benign neoplasm of the uterus. Lipoleiomyoma is a rare variant usually affecting women in the postmenopausal age group. Incidence of lipoleiomyoma varies from 0.59% - 2.1%. This study was undertaken to analyse the different variants, degenerative changes and to determine the incidence, clinical and morphological features of lipoleiomyoma amongst all the leiomyomas studied.

Methods: This study was done in the Department of Pathology over a period of 6 years. Authors studied 575 patients with leiomyoma constituting a total of 1122 leiomyomata as some patients presented with multiple leiomyomata. Further clinicopathological correlation was done.

Results: In the present study 98.03% of leiomyomata were uterine in location, 1.06% were cervical, 0.62% were in broad ligament and 0.26 % were in ovary. Among the 1122 leiomyomata studied, degenerative changes were noted in 19.6% of which hyaline degeneration was the most common. Leiomyoma variants constituted 5.27% of all leiomyomata. The incidence of lipoleiomyoma was 0.71% with size ranging from 3-10cm.

Conclusions: Leiomyoma is a common tumor of the uterus and lipoleiomyoma variant is very uncommon with unknown etiology. They occur in postmenopausal as well as reproductive age group. The site of lipoleiomyoma can be uterine or extrauterine location such as broad ligament. Coexistence of metabolic derangement is an observation that may have a role in development of lipoleiomyoma.

Keywords: Degenerations in leiomyoma, Leiomyoma, Lipoleiomyoma

INTRODUCTION

Leiomyomata are the commonest neoplasms of the uterus and usually affect women in their fourth and fifth decade of life. The variant forms account for approximately 10% of all leiomyomata which include cellular leiomyoma, mitotically active leiomyoma, hydropic leiomyoma, lipoleiomyoma, epithelioid leiomyoma, myxoid leiomyoma, symplastic leiomyoma and intravenous leiomyomatosis.¹

The overall incidence is between 4% and 11% of all the neoplasms in women, but it rises to nearly 40% over the age of 50 years.² Lipoleiomyomata were first described

by Lobstein in the year 1816.³ They were earlier known by several names such as fatty metamorphosis, lipomatous degeneration and adipose metaplasia in leiomyomas.³ Lipoleiomyomata are now considered to be true neoplasms comprising of variable admixture of smooth muscle and adipose tissue.⁴

The present study was conducted to note the types of degenerations and variants of leiomyomas with emphasis on lipoleiomyomas as it is even more uncommon type. There is very little information available about lipoleiomyoma regarding its incidence and etiopathogenesis in literature.

METHODS

This study was done in the Department of Pathology, in a Tertiary Medical Care Centre. The study was carried out over a period of six years from January 2012 to December 2017. All the patients who underwent surgery for fibroids were included in the study as well as patients who had undergone surgery for complaints such as prolapse of uterus or dysfunctional uterine bleeding in whom leiomyoma was an incidental finding.

Relevant clinical details of the patients such as age, presenting complaints, menstrual history, menopausal status and history of previous surgeries were collected from the case records. The specimens received included hysterectomy with or without salphingo-oophorectomy and myomectomy. All the specimens were received in 10% formalin. Gross specimens were weighed, measurements were noted along with the details of leiomyomas with respect to number, size, location and morphology. The specimens were kept in formalin for fixation up to 24hours.

Representative bits were taken from the endometrium, myometrium, cervix, adnexae and from the leiomyomata. One bit from each leiomyoma and multiple bits in cases of large leiomyomata were processed. Extra bits were given from the abnormal appearing areas. All the bits were processed routinely and embedded in paraffin blocks. Sections of 5µ thickness were cut and stained with haematoxylin and eosin (H & E) stain. Special stains such as Periodic Acid Schiff (PAS) and Masson’s trichrome were used wherever required. Detailed microscopic examination was carried out. Histopathological features such as cellular and nuclear features, different patterns of cellular arrangement and mitotic counts were recorded. Degenerative changes such as myxoid, mucoid areas, calcifications and cystic degenerations were noted. Different variants of leiomyoma were categorized.

In cases of lipoleiomyoma, the parameters studied included assessment of percentage involved by adipocytes in comparison to smooth muscle cells, presence of atypia and mitotic rate. The margins of lipoleiomyoma were studied carefully to rule out any infiltration into the adjacent tissue. All the malignant neoplasms diagnosed on histopathology were excluded from the study. Descriptive statistics were used for the data collected.

RESULTS

The present study included 575 patients with leiomyoma, in the age group of 30-60 years with an average of 45 years. Out of these, 210 patients had solitary leiomyoma and 365 patients presented with multiple leiomyomata varying from 2 to 6 in number. In total 1122 leiomyomas were studied.

Common presenting complaints were menorrhagia, dysmenorrhea, lower abdominal fullness and irregular cycles. Sixty-two percentage of the patients were postmenopausal and 38% were premenopausal. Total abdominal hysterectomy with bilateral salpingo-oophorectomy was the most common type of surgery done (64%) (Table 1).

Table 1: Types of surgeries performed for leiomyoma.

Type of surgery	No. of patients	% of patients
Total abdominal hysterectomy with bilateral salpingo-oophorectomy	368	64%
Total abdominal hysterectomy with unilateral salpingo-oophorectomy	133	23.13%
Total abdominal hysterectomy	55	9.56%
Myomectomy	11	1.9%
Vaginal hysterectomy	8	1.39%

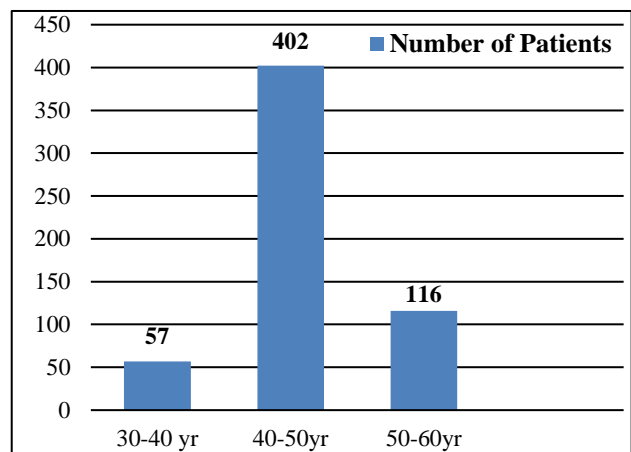


Figure 1: Age distribution of the cases.

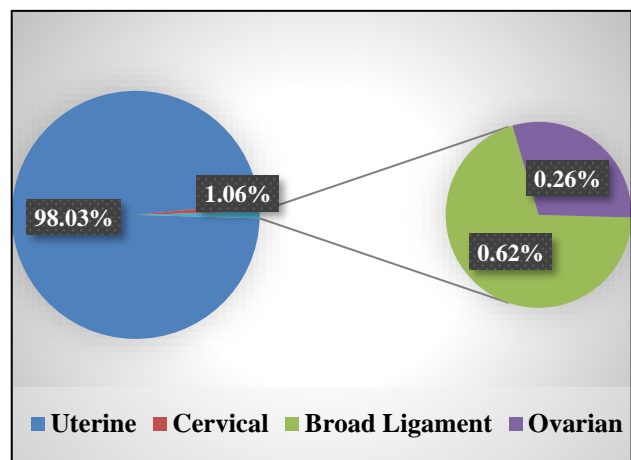


Figure 2: Distribution of leiomyomata in different locations.

Out of 1122 leiomyomata studied, 98.03% were uterine in location, 1.06% were cervical, 0.62% were broad ligament and 0.26% were ovarian (Figure 2).

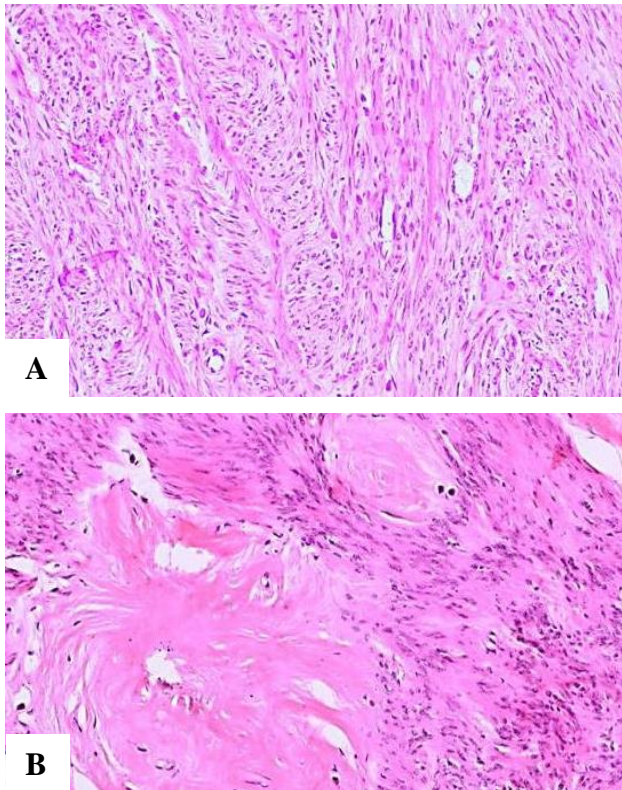


Figure 3: Microphotographs, (A): Conventional leiomyoma with interlacing bundles of smooth muscle cells (H&E; 40x), (B): Leiomyoma with hyaline change and cellular arrangement resembling Schwannoma (H&E; 100x).

Grossly, majority of the uteri received were asymmetrically enlarged. Size of the leiomyomata ranged from 0.5 to 16cm. Among the uterine leiomyomata, 860 (78.18%) were intramural, 213 (19.36%) were subserosal and 27 (2.45%) were submucosal. Also seen were submucosal leiomyomas presenting as polypoidal lesions projecting into endometrial cavity.

Cut section of conventional leiomyoma was solid, firm, grey white and with a whorled appearance. Few showed grey- tan areas, mucinous and an occasional one had cystic areas.

On microscopic examination, all cases of conventional leiomyoma showed smooth muscle bundles in interlacing fascicles, bundles and whorled pattern. The individual cells were spindle shaped with elongated nuclei having blunted ends. Schwannoma like areas with nuclear palisading were noted in many of the leiomyomata (Figure 3).

A variety of degenerative changes were noted. Of the 1122 leiomyomata studied, 220 (19.6%) showed

degenerative changes of which hyaline degeneration was the commonest (16.57%). The other changes noted were calcification, hydropic with cystic change, myxoid change and red degeneration (Table 2).

Leiomyoma variants constituted 5.27%. The variants noted in this study were, cellular leiomyoma (2.8%), mitotically active leiomyoma (1.42%) lipoleiomyoma (0.71%), myxoid leiomyoma (0.44%), epithelioid leiomyoma (0.27%) and symplastic leiomyoma (0.17%) (Figure 4). Histological criteria for their diagnosis were followed as per WHO classification of tumors.¹

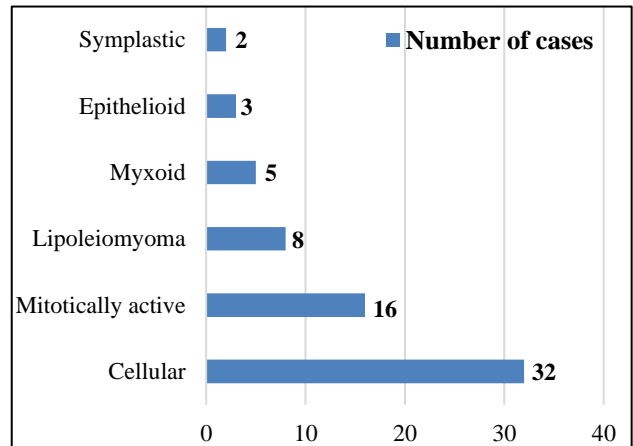


Figure 4: Variants of leiomyoma.

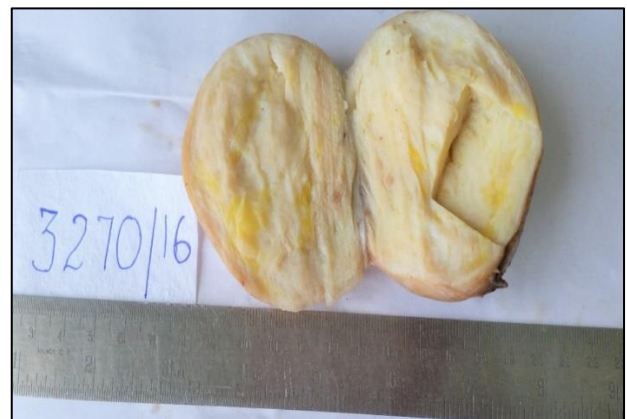

Figure 5: Gross specimen of broad ligament lipoleiomyoma with grey white and yellow areas on cut surface.

There were eight cases of lipoleiomyoma in the present study, constituting 0.71% of all the leiomyomas. These patients were in the age group of 32-55years. Five of these patients were premenopausal and three were postmenopausal. Three patients sought medical attention for menorrhagia, one for pelvic pain, two for dysmenorrhea and two presented with postmenopausal bleeding. Two patients were diabetic and three had hypertriglyceridemia.

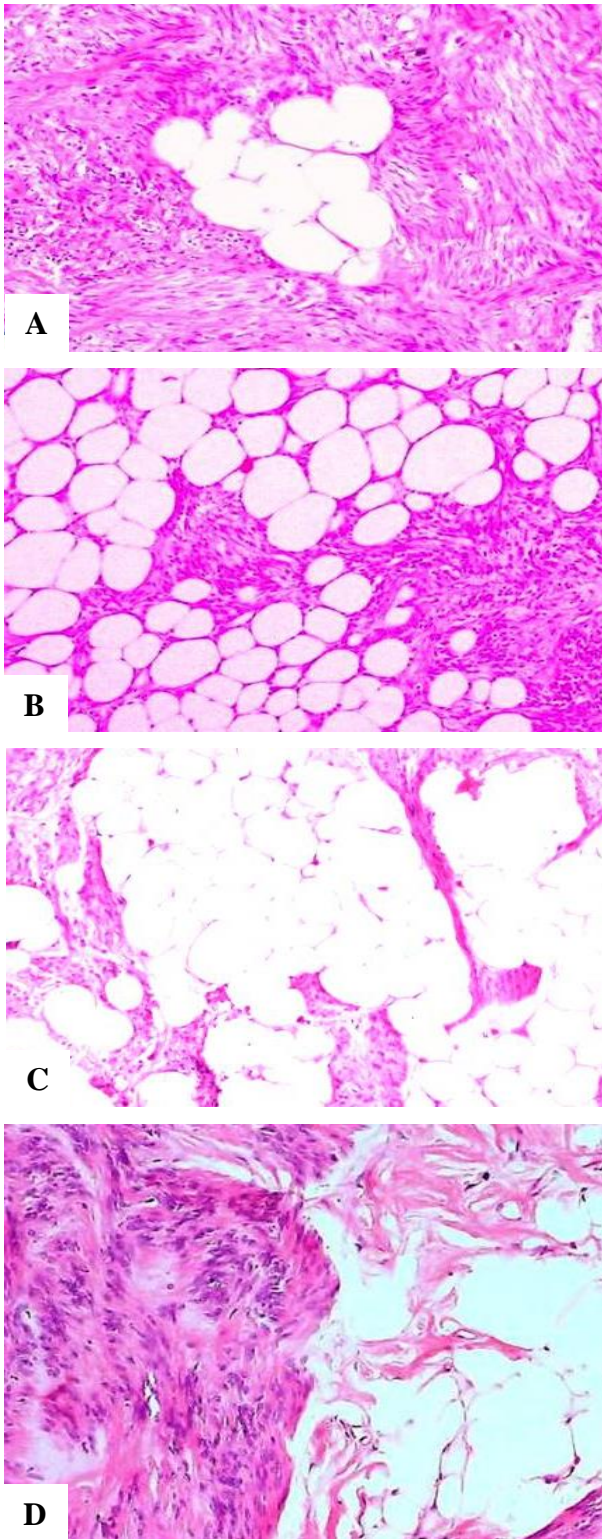


Figure 6: Microphotographs of Lipoleiomyoma. (A), (B) and (C): Variable amount of adipocytes, (D): Schwannoma like areas and hyaline degeneration (H&E;100x).

Seven patients underwent total abdominal hysterectomy and myomectomy was done for one patient. Among these eight cases, five cases showed intramural lipoleiomyoma, two were in broad ligament and one was subserosal in

location. The size varied from 3cm to 10cm. Grossly, they were well circumscribed and cut surface showed whorled appearance with variable amounts of grey yellow areas. No myxoid or cystic areas were noted (Figure 5).

On microscopic examination, all the eight cases showed smooth muscle bundles admixed with variable amounts of adipose tissue varying from 10% - 60% of the tumor mass. Also seen were many vascular channels of varying sizes. Two cases showed associated hyaline degeneration. One case showed focal Schwannoma like areas. Cytological atypia, lipoblasts, necrosis and calcification were not seen. Mitotic rate was zero. None of the tumors had infiltrative margins (Figure 6).

DISCUSSION

Leiomyoma is the most common benign mesenchymal neoplasm of the uterus arising from the smooth muscle cells. Most of the cases (69.9%) in present study were noted in the 4th decade followed by 20.17% in the 5th decade and 9.9% in 3rd decade.

In present study, 36.5% showed solitary leiomyoma and 63.47% of the patients showed multiple leiomyomata. Begum et.al also noted that multiple leiomyomas were common in their study.⁵ In contrast, Sushama et al, noted that 80.95% of the cases in their study showed solitary leiomyomas.⁶

The most common location of uterine leiomyoma in our study was intramural (78.18%) compared to 51.2% of intramural leiomyoma in the study by Sushama et al.⁶ In this study, 19.6% of the leiomyomas showed different types of degeneration. The most common degeneration was hyaline degeneration followed by calcific degeneration which was similar to other studies. The degenerative changes are said to occur due to inadequate blood supply which depends on the rapidity and degree of vascular insufficiency.⁶

Lipoleiomyoma is a rare benign variant of uterine leiomyoma composed of admixture of smooth muscle cells and mature adipocytes. The tumor was described as myolipoma of the soft tissue by Meiss and Enzinger in 1991.⁷ The incidence in present study was 0.71%. This is in accordance with other studies which recorded variable incidence of 0.59% to 2.1%.^{6,8} In 90% of cases, lipoleiomyomas were seen in patients over 40 years of age, usually between 50-70years.⁹ Kelecki et al, and Oh SR et al, noted that lipoleiomyomas were seen in postmenopausal group.^{10,11} However, in present study, the age group ranged from 32-55years, of these five were premenopausal and three were postmenopausal.

The most common sites of lipoleiomyomata are uterine corpus but rarely may be found in cervix, ovary, broad ligament and retroperitoneum.¹² In present study, six lipoleiomyomas were noted in uterine corpus and two in

broad ligament. A case of ovarian lipoleiomyoma has been reported from our institution, which clinically presented as a large retroperitoneal mass suspected to be sarcoma on computed tomography.¹³ Oh SR et al, studied a total of six lipoleiomyomas of which five occurred in uterine corpus and one in broad ligament.¹¹ Among the uterine lipoleiomyomas, we noted intramural as the most common site of occurrence which was similar to the study by Sharma et al, and Abraham et al (Table 3).^{3,14}

The amount of adipose tissue in the lipoleiomyoma varies from 5%-95% of the tumor mass in the study by Bolat et al.⁴ In present study, amount of adipose tissue varied from 10%-60% of the tumor mass. Several hypotheses have been postulated for the pathogenesis of lipoleiomyomas. Sieinski summarized the different proposed theories as follows: 1) misplaced embryonal mesodermal rests with a potential for lipoblastic differentiation, 2) lipoblasts or pluripotential cells migrating along uterine arteries and nerves and 3) adipose metaplasia of stromal or smooth muscle cells in a leiomyoma. Immunohistochemical studies by Bolat et al, have demonstrated adipocytes reacting for vimentin and desmin, thus confirming the hypothesis of direct transformation of smooth muscle cells into adipocytes.⁴ Association with metabolic disorders like hyperlipidemia, hypothyroidism and diabetes mellitus has been postulated by many authors. One hypothesis states that following menopause, estrogen deficiency leads to abnormal lipid metabolism and that may play a role in development of lipoleiomyoma.^{15,16}

Though, lipoleiomyoma has a benign course, sarcomatous change has been noted in two studies.^{17,18} In a series of seventy six lipoleiomyomas by Akbulut et al, 17% were associated with malignancies such as endometrial carcinoma, endometrial carcinosarcoma, serous carcinoma of ovary, carcinoma breast, carcinoma stomach and carcinoma rectum. In 10% of the lipoleiomyomas, association with benign neoplasms such as ovarian teratoma, fibrothecoma and serous cystadenoma were noted.¹² Therefore it is important to investigate for neoplasms in other sites in all the cases of uterine lipoleiomyoma.

CONCLUSION

Leiomyoma is the commonest benign neoplasm of the uterus and lipoleiomyoma is a rare variant. Lipoleiomyoma is a benign tumor with an elusive etiology and has to be differentiated from a malignant tumor when it attains a large size. It is seen in both reproductive and postmenopausal age groups. Association with metabolic disorders like diabetes mellitus, hypertriglyceridemia and other clinical conditions may have a role in the pathogenesis of lipoleiomyoma. Hence further studies with clinicopathological correlation are required for validation.

Funding: No funding sources

Conflict of interest: None declared

Ethical approval: Not required

REFERENCES

1. Kurman RJ, Carcangiu ML, Herrington CS, Young RH, eds. WHO Classification of Tumors of Female Reproductive Organs. 2014;135-148.
2. Gilks. Uterine corpus. In: Goldblum JR, Lamps LW, McKenney KK, Myers JL. Rosai and Ackerman's surgical pathology. 11th ed. Philadelphia: Mosby; 2018:323-1327.
3. Abraham J, Saldanha P. Lipoleiomyoma-A rare tumor of the uterus. *Int J Biomed Adv Res.* 2014;5(2):112-3
4. Bolat F, Kayaselcuk F, Canpolat T, Erkanli S, Tuncer I. Histogenesis of lipomatous component in uterine lipoleiomyomas. *Turkish J Pathol.* 2007 Jan 1;23(2):82-6.
5. Begum S, Khan S. Audit of leiomyoma uterus at Khyber teaching hospital Peshawar. *J Ayub Med Coll Abbottabad.* 2004;16(2):46-9.
6. Sushama B, Sunita B, Prasad O B. Histopathological study of uterine leiomyoma in hysterectomy specimens. *Ann Clin Chem Lab Med.* 2017;3(2):16-20.
7. Meis JM, Enzinger FM. Myolipoma of soft tissue. *Am J Surg Pathol.* 1991;15:121-5.
8. Wang X, Kumar D, Seidman JD. Uterine lipoleiomyomas: a clinicopathologic study of 50 cases. *Int J Gynecol Pathol.* 2006;25:239-42.
9. Manimaran D, Khan DM, Yasmin S, Anuradha S. Lipoleiomyoma: a rare variant of uterine leiomyoma. *Int J Health Allied Sci.* 2014 Oct 1;3(4):255-8.
10. Kelekci S, Eris S, Demirel E, Aydogmus S, Ekinci N. Lipoleiomyoma of the uterus and primary ovarian leiomyoma in a postmenopausal woman: two rare entities in the same individual. *Case Reports Pathol.* 2015;2015.
11. Oh SR, Cho YJ, Han M, Bae JW, Park JW, Rha SH. Uterine lipoleiomyoma in peri or postmenopausal women. *J Menopausal Med.* 2015 Dec 1;21(3):165-70.
12. Akbulut M, Gündoğan M, Yörükoğlu A. Clinical and pathological features of lipoleiomyoma of the uterine corpus: a review of 76 cases. *Balkan Med J.* 2014 Sep;31(3):224.
13. Hemalata M, Kusuma V, Sruthi P. Ovarian lipoleiomyoma: a rare benign tumour. *J Clin Pathol.* 2007 Aug 1;60(8):939-40.
14. Sharma S, Mandal AK. Uterine Lipoleiomyoma: A five year clinicopathological study. *Ann Woman Child Health.* 2016 May 12;2(2):A22-26.
15. Narchal S, Patil SB, Purohit PV, More SS. Lipoleiomyoma of uterus: A case report with review of literature. *Int J Health Allied Sci.* 2013;2:209-11.

16. Salman MC, Atak Z, Usubutun A, Yuce K. Lipoleiomyoma of broad ligament mimicking ovarian cancer in a postmenopausal patient: case report and literature review. *J Gynecol Oncol.* 2010 Mar 1;21(1):62-4.
17. McDonald AG, Dal Cin P, Ganguly A, Campbell S, Imai Y, Rosenberg AE, Oliva E. Liposarcoma arising in uterine lipoleiomyoma: a report of 3 cases and review of the literature. *Am J Surgical Pathol.* 2011 Feb 1;35(2):221-7.
18. Manjunatha HK, Ramaswamy AS, Kumar BS, Kumar SP, Krishna L. Lipoleiomyoma of uterus in a postmenopausal woman. *J Midlife Health.* 2010;1:86-88.

Cite this article as: Manjula CP, Simon NM, Venkatesh K, Muneer F, Hemalata M Rangaswamy R. A six year study of leiomyomata with emphasis on lipoleiomyoma. *Int J Res Med Sci* 2019;7:199-204.