

Case Report

Parasite helminthes, class cestode, diagnosed by hooklets on FNAC

Nidhi Verma, Bhavna Sharma*, Chhaviraj Singh, S. P. Sharma

Department of Pathology, LLRM Medical College, Meerut, Uttar Pradesh, India

Received: 29 April 2018

Accepted: 31 May 2018

***Correspondence:**

Dr. Bhavna Sharma,

E-mail: dr.bhavnaa@gmail.com

Copyright: © the author(s), publisher and licensee Medip Academy. This is an open-access article distributed under the terms of the Creative Commons Attribution Non-Commercial License, which permits unrestricted non-commercial use, distribution, and reproduction in any medium, provided the original work is properly cited.

ABSTRACT

Parasitic infestation is a common cause of morbidity in several parts of the world. Helminthes constitute a significant number of parasitic diseases, out of which large number of cases are due to cestodes. Cestodes can affect various organs, including skin, subcutaneous tissue, liver, brain, spinal cord, orbit, muscle, gastrointestinal tract and heart. Parasites are routinely diagnosed by histopathology, serology, radiology and stool examination however FNAC can also serve as low cost out-patient procedure for diagnosis of certain parasites especially in cases of sub cutaneous nodules. Subcutaneous nodule is a relatively uncommon presentation and is often misdiagnosed clinically. This study includes case series of five cases of subcutaneous parasitic infestation by cestodes that were diagnosed by FNAC.

Keywords: FNAC, Helminthes, Hooklets, Parasite

INTRODUCTION

Helminthic parasites comprise of intestinal worms, tissue parasites as well as many free-living species. Helminths, which occur as parasite in humans belong to 2 phyla. Phylum Platyhelminthes (flatworms)-It includes 2 classes:

- Class-Cestoda (tapeworms)
- Class-Trematoda (flukes or digeneans)
- Phylum nemathelminthes-It includes class nematoda and 2 subclasses:
 - Subclass-Adenophorea (Aphasmidia)
 - Subclass-Secernentea (Phasmidia).

Tapeworms or cestodes are segmented helminths that cause illness in humans in either of the two stages of their life cycle: the adult stage, which causes signs and symptoms referable to the gastrointestinal (GI) tract, where the adult tapeworm resides, and the larval stage, which causes signs and symptoms secondary to enlarging larval cysts in various tissues of the mammalian host, including the soft tissue, eye and the brain. These worms

have been recognized since the beginning of recorded history because of the impressive length of the adult (up to 30 feet) and because of the fluid-filled cysts in the larval state. Humans are the definitive host for some cestodes, such as *Taenia solium*, the cause of cysticercosis, whereas humans can only support the larval or intermediate stage of other cestodes, such as *Echinococcus granulosus*, the cause of echinococcosis. Various Cestodes (tapeworms) and diseases caused by them are:

- *Coenurus cerebralis* (coenurosis)
- *Diphyllobothrium latum* and *nihonkaiense* (diphyllobothriasis)
- *Echinococcus granulosus* and *multilocularis* (echinococcosis, hydatidosis)
- *Spirometra* species (sparganosis)
- *Taenia solium* (cysticercosis).¹

Cestodes have tape-like, dorsoventrally flattened, segmented bodies. They possess scolex, neck, and proglottids. Their head carries suckers and some also have hooks.² FNAC of five patients with subcutaneous

swellings showed negatively stained hooklets which led to diagnosis of parasitic infestation by cestodes.

CASE REPORT

Case 1

There were 21 years old female patient presented in out-patient department of ENT, SVBP hospital, Meerut with superficial nodule over left sub mandibular region since 8 months. Patient was sent to pathology department of L.L.R.M. Medical College, Meerut attached to S.V.B.P. Hospital, Meerut for FNAC of the swelling. On examination the nodule measured 1.5*1.5cm in size, non-tender and soft to firm in consistency. FNA yielded 2 ml clear fluid and smears were made after centrifugation and stained with May-Grunwald Giemsa (MGG) stain; wet mount preparation (Figure 1) was also examined. On microscopic examination body and hooklets (Figure 2) of parasite were seen. Diagnosis of helminthic infection, class cestode was made and patient was put on anti-helminthic treatment.



Figure 1: Wet mount showing hooklet.

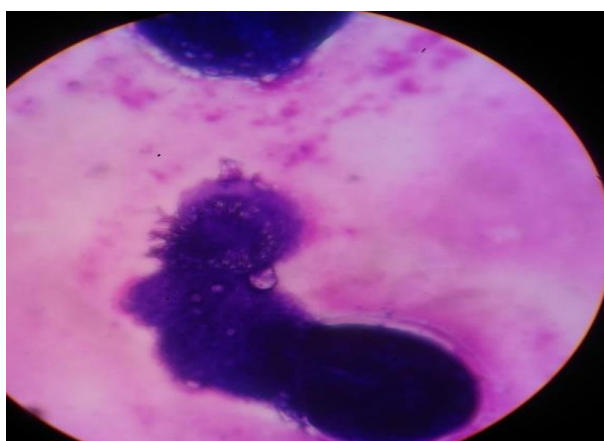


Figure 2: Body and hooklets of parasite.

Case 2

A 45 years old male presented in out-patient department of Surgery, SVBP hospital, Meerut with left upper chest

wall swelling since 5 months. The patient was sent to pathology department of L.L.R.M. Medical college, Meerut attached to S.V.B.P. Hospital, Meerut for FNAC. On examination, the swelling measured 2*2cm and firm in consistency. On aspiration, blood mixed material came out. On microscopy, hooklets along with mixed inflammatory infiltrate were seen. Diagnosis of helminthic infection, class cestode was made and patient was put on anti-helminthic treatment.

Case 3

There were 28 years male presented in out-patient department of Surgery, SVBP hospital, Meerut with right lower chest wall swelling measuring 1.5*1.5cm and soft to firm in consistency. The patient was sent to pathology department of L.L.R.M. Medical college, Meerut attached to S.V.B.P. Hospital, Meerut for FNAC. On aspiration, pus mixed material came out. On microscopy hooklets were seen along with few mixed inflammatory cells. Diagnosis of helminthic infection, class cestode was made and patient was put on anti-helminthic treatment.

Case 4

In this study a 32 years old female presented in out-patient department of ENT, SVBP hospital, Meerut with pre-auricular swelling for 10 months. The patient was sent to pathology department of L.L.R.M. Medical college, Meerut attached to S.V.B.P. Hospital, Meerut for FNAC. On examination, the swelling measured 1*1cm and soft to firm in consistency. On aspiration, clear fluid came out. Microscopic examination of wet mount smear and MGG stained smear showed hooklets of parasite (Figure 3). Diagnosis of helminthic infection, class cestode was made and patient was put on anti-helminthic treatment.

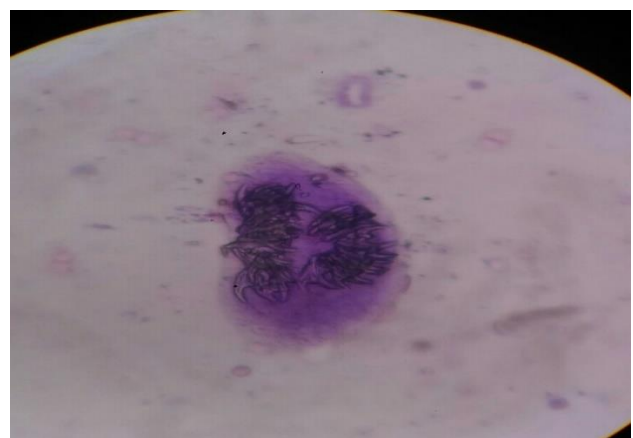


Figure 3: Hooklets of parasite, MGG stain, 400x.

Case 5

There were 18 years old male presented in out-patient department of Surgery, SVBP hospital, Meerut with

swelling in anterior abdominal wall since 2 months. The patient was sent to pathology department of L.L.R.M. Medical college, Meerut attached to S.V.B.P. Hospital, Meerut for FNAC. On examination, the swelling measured 1.5*1.5cm and soft to firm in consistency. On aspiration, clear fluid came out. Microscopic examination of wet mount smear showed hooklets (Figure 4) and scolices (Figure 5) and MGG stained smear showed many hooklets.

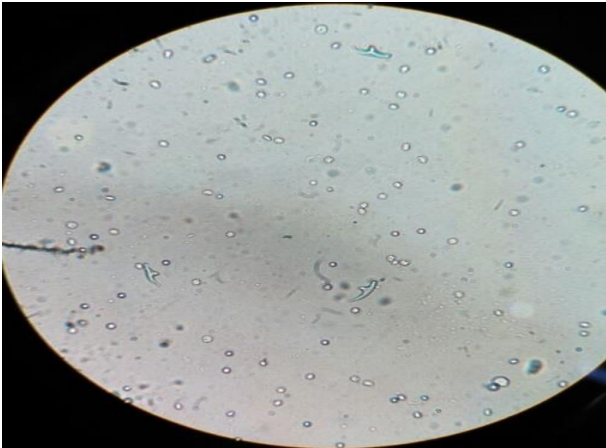


Figure 4: Wet mount smear showing hooklets.

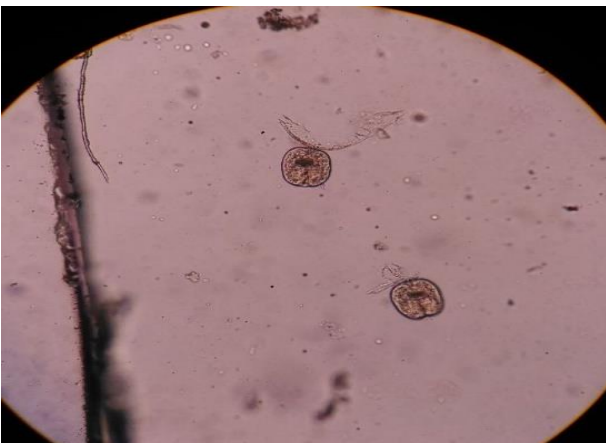

Figure 5: Wet mount smear showing scolices.

In all these cases, umbrella diagnosis of parasitic infestation by helminthes (class-cestode) was given on the basis of hooklets identification specific species identification was not done owing to common anti helminthic treatment for all cestodes. Patients were put on anti-helminthic therapy and responded well to treatment.

DISCUSSION

Cestodes, or tapeworms, are segmented worms. The adults reside in the gastrointestinal tract, but the larvae can be found in almost any organ. The ribbon-shaped tapeworm attaches to the intestinal mucosa by means of sucking cups or hooks located on the scolex.³

Although humans can be definitive hosts for cestodes (tapeworms), major pathologic conditions occur during cestode larval stages when humans serve as the intermediate host for these parasites. The most relevant forms of human disease caused by cestode larvae are echinococcosis, caused by *Echinococcus granulosus* and *Echinococcus multilocularis*, and cysticercosis, caused by *Taenia solium*. These infections occur worldwide, but their relevance is particularly high in developing countries, where poor hygiene conditions facilitate the transmission of the parasites.⁴

FNAC is low cost outpatient procedure for pre-operative diagnosis of parasitic swellings and may even obviate the need for open biopsy.⁵ The cytological diagnosis is quite clear cut and undemanding in cases where actual parasite structure is identified in the smear. The cytomorphological identification of larval forms in FNAC smear by different workers has widened the utility of FNAC in skin nodules. The diagnosis of cestode infection is made when fragments of larval cuticle, parenchyma or scolex are identified.⁶ The viable cyst and the necrotic and calcified lesions all have distinctive cytomorphological pattern. The viable cyst yields clear fluid and show fragments of bladder wall in a clear acellular background. Single and detached hooklets may be the only recognisable remnants in aspirates of calcified cysts.⁷

Aspirates of necrotic and degenerated lesions may contain fragments of bladder wall including calcareous corpuscles, detached single hooklets and an infiltration of inflammatory cells associated with development of foreign body granulomas. A careful search for hooklets is indicated whenever there is clear fluid aspiration, as single and detached hooklets maybe only recognizable remnants in aspirates of calcified cysts.⁷ A wet mount preparation should be examined microscopically, as it shows hooklets and sometimes this may be the only evidence of parasite and there may be no evidence on MGG stained smear.

FNAC has emerged as a widely acceptable method for the diagnosis of sub-cutaneous parasitic swellings. Specific species identification can be done by histopathological examination and by serology. However, treatment modality for most helminthic infections remains the same, therefore a broad umbrella diagnosis of helminthic infection, class cestode may be rendered on identification of hooklets on FNAC in economically limited settings. Thus, this article helps to spread the awareness about the usefulness of FNAC in diagnosis of parasitic infestation and reaching a broad umbrella diagnosis of cestodes.

CONCLUSION

FNAC is a useful diagnostic modality in the diagnosis of parasitic infestation and reaching a broad umbrella diagnosis of cestodes. In resource limited places Anti

helminthic treatment maybe started on the basis of FNAC finding of hooklet, without specific serological investigations due to common treatment regime for all cestodes.

Funding: No funding sources

Conflict of interest: None declared

Ethical approval: Not required

REFERENCES

1. Odel JG, Moazami G. Diseases caused by helminths. Walsh and Hoyt's Clinical Neuro-ophthalmology. 1997;4:4460-79.
2. Paniker CJ. Paniker's textbook of medical parasitology. JP Medical Ltd; 2013:113-137.
3. White AC, Weller PF. Harrison's Principles of Internal Medicine. Cestode Infections. 2008:1430-1435.
4. Brunetti E, White AC. Cestode infestations: hydatid disease and cysticercosis. Infectious Disease Clinics. 2012 Jun 1;26(2):421-35.
5. Adhikari RC, Aryal G, Jha A, Pant AD, Sayami G. Diagnosis of subcutaneous cysticercosis in fine needle aspirates: a study of 10 cases. Nepal Medical College J. 2007;9(4):234-8.
6. Rajwanshi A, Radhika S, Das A, Jayaram N, Banerjee CK. Fine-needle aspiration cytology in the diagnosis of cysticercosis presenting as palpable nodules. Diagnostic cytopathology. 1991 Sep 1;7(5):517-9.
7. Nanjeevan S, Vinod KA, Arati B. Are all subcutaneous parasitic cysts cysticercosis. Acta Cytologica. 1991;7:223-4.

Cite this article as: Verma N, Sharma B, Singh C, Sharma SP. Parasite helminthes, class cestode, diagnosed by hooklets on FNAC. Int J Res Med Sci 2018;6:2540-3.