

Case Report

Incomplete development of second sacral lamina: a case report

Renu Chauhan*, Jugesh Khanna

Department of Anatomy, UCMS and GTB Hospital, Dilshad Garden, Delhi-110095, India

Received: 30 April 2013

Accepted: 11 May 2013

***Correspondence:**

Dr. Renu Chauhan,

E-mail: renuchauhan@yahoo.com

© 2013 Chauhan R et al. This is an open-access article distributed under the terms of the Creative Commons Attribution Non-Commercial License, which permits unrestricted non-commercial use, distribution, and reproduction in any medium, provided the original work is properly cited.

ABSTRACT

Sacrum is made up of large fused 5 sacral vertebra forming posterior wall of pelvis. On routine examination of the bones present in the bone bank of our department we noticed a sacrum in which sacral canal was incompletely formed due to imperfect formation of second sacral laminae. Knowledge of such type of variation may be of importance to the clinicians in dealing with patients presenting with bladder and or bowel disturbances or presenting with some neurological deficit of the lower limb. Orthopaedic surgeons should also be aware of this anomaly while operating in the sacral region.

Keywords: Middle sacral crest, Sacral Lamina, Sacral canal, Sacrum

INTRODUCTION

Sacrum is a triangular bone located at the posterosuperior part of the pelvic cavity, inserted like a wedge between the two innominate bones. Its base projects upwards and forwards and articulates with the last lumbar vertebra to form a prominent sacrovertebral angle while truncated apex points downwards and articulates with the coccyx. It usually consists of five unfused vertebrae which begin to fuse between 16-18 years of ages and are usually completely fused to form a single piece of bone by 34 years of age. Its dorsal surface is convex and narrower than the pelvic surface. In the midline is the middle sacral crest, surmounted by three or four tubercles representing the spinous processes of the upper three or four sacral vertebrae (Figure 1). On the sides of middle sacral crest is a shallow groove which gives origin to the Multifidus. The floor of the groove is formed by the united laminae of the corresponding sacral vertebrae. The laminae and spinous process of the fifth and /or fourth sacral vertebrae fail to meet in the mid line creating a deficiency known as the hiatus in the posterior wall of the sacral canal.¹⁻⁵

While we were examining the bones of our bone bank we came across a sacrum in which the laminae of second sacral vertebrae were not formed. Relevant clinical implications concerning this deformity have been discussed in the paper.

CASE REPORT

The bones in the bone bank of the Department of Anatomy, U.C.M.S and G.T.B. Hospital were being routinely examined. By chance, we came across a sacrum in which laminae of the second sacral vertebra were deficient (Figure 2). No other abnormality was observed in this sacrum.

DISCUSSION

The spine which is formed due to fusion of laminae of the vertebrae is a complex and vital structure. Its function includes not only structural support of the body as a whole, but it also serves as a conduit for safe passage of the neural elements while allowing proper interaction with the brain. Anatomically, a variety of tissue types are

represented in the spine. Embryologically, a detailed cascade of events must occur to result in the proper formation of both the musculoskeletal and neural elements of the spine.

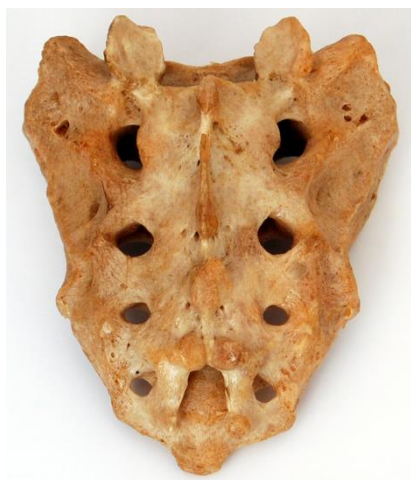

Figure 1: Showing large triangular bone, the sacrum, formed by fusion of five sacral vertebrae. Sacral canal completely formed posteriorly by fusion of upper four sacral laminae. The fifth sacral lamina is deficient in the midline posteriorly resulting in sacral hiatus.

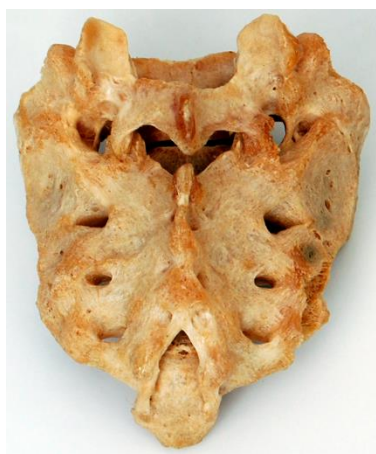


Figure 2: Dorsal aspect of sacrum showing incompletely formed sacral canal as a result of non fusion of the laminae of second sacral vertebra.

Alterations in these embryologic steps can result in one or more congenital abnormalities.⁶

The median sacral crest is primarily formed from the spinous processes of the upper three to four sacral vertebrae. The laminae of fifth sacral and sometimes fourth sacral vertebrae do not fuse in the midline. As a consequence, the resultant opening formed is termed the sacral hiatus. The laminae on either side of the median sacral crest form the sacral grooves. Number of muscular attachments reside along this groove of the sacrum. Multifidus, sacrospinalis, and erector spinae muscles originate from these sacral grooves.⁷ The second sacral

laminae are incompletely formed in the present case so the muscles multifidus, sacrospinalis, and erector spinae would fail to get proper attachment on the dorsal aspect of sacrum.

The deficiency in the bony posterior wall of the sacral canal at the level of second sacral vertebra may predispose the meninges to protrude out of the defect resulting in spina bifida occulta. The sacral and coccygeal nerve roots may also get tethered to the meninges at that level. Spina bifida occulta is usually found in the lower part of the back.⁸ It is the most common neural tube defect, resulting from the failure of the fusion of the embryonic vertebral arches. The type of spina bifida is determined by the pattern of involvement of the vertebral arch, spinal cord, meninges and overlying dermis.⁹ The spinal cord defect may be present at any vertebral level with the most common being the lumbosacral region, which is associated with the final component of neural tube closure.¹⁰ There are different severities of spina bifida occulta. In minor form of spina bifida occulta, the laminae that form the spinal arch fail to fuse completely. This type of deformity generally, only affects one vertebra, particularly the vertebra lying lowest in the small of the back.⁸ Frequently, anatomical variations occur in the sacral region. The present anomaly seen is in accordance to Esses and Botsford.¹¹

Knowledge of this type of variation may be helpful to the radiologists in interpreting the radiographs of sacral spine. This variation may also benefit orthopaedicians in diagnosing the exact cause of low backache. Awareness of such type of developmental anomaly is of utmost importance to physicians in diagnosing the cause of neurological involvement of bladder, rectum and lower limbs. Orthopaedic surgeons and neurosurgeons may find this piece of information useful while operating in the sacral region.

Funding: None

Competing interests: None declared

Ethical approval: Not required

REFERENCES

1. Standring S. The Back. In: Gray's Anatomy's Sacrum. 40th ed. Edinburgh, UK: Churchill Livingstone; 2008:724.
2. Keith L M, Anne MRA, Arthur FD. Back. In: Essential Clinical Anatomy's Sacrum and coccyx. 4th ed. Baltimore, Philadelphia: Lippincott Williams & Wilkins, Wolter Kluwer; 2011:283.
3. Keith L M, Arthur FD, Anne M R A. Back. In: Clinically Oriented Anatomy's Sacrum. 6th ed. Baltimore, Philadelphia: Lippincott Williams & Wilkins, Wolter Kluwer; 2009:451.
4. Snell RS. The pelvis: Part I- The pelvic walls. In: Clinical Anatomy by Regions' Sacrum. 9th ed. Baltimore, Philadelphia: Lippincott Williams & Wilkins, Wolter Kluwer; 2012:244.

5. Snell RS. Bones and cartilage. In: *Clinical Anatomy by Systems' Sacrum*. 1st ed. Baltimore, Philadelphia: Lippincott Williams & Wilkins, Wolter Kluwer; 2007:317.
6. Kevin M K, Jeffrey M S, John A B. Embryology of the spine and associated congenital abnormalities. *The Spine Journal* 2005;5:564-76.
7. Joseph SC, John KS. Anatomy of the Sacrum. *Neurosurg Focus*. 2003;15(2):1-4.
8. Available at [http:// www.sbhac.ca/OCCULTA](http://www.sbhac.ca/OCCULTA). Accessed 27 April 2013.
9. Keim H. The adolescent spine. New York: Grune & Stratton; 1976 :460.
10. Bendo J, Spivak J, Cally D, Letko L. Congenital Spinal Deformity. In: Spivak JM, DiCesare P, Feldman D, Koval K, Rokito A, Zuckerman JD, eds. *Orthopaedics' A Study Guide*. New York: McGraw-Hill; 1999: 397-402.
11. Esses SE, Botsford DJ. Surgical Anatomy and Operative Approaches to the Sacrum. In : Frymoyer JW, Ducker TB, Hadler NM, et al, eds. *Principles and Practice's The Adult Spine*. 2nd ed. Philadelphia: Lippincott-Raven; 1997: Vol 2- 2329-41.

DOI: 10.5455/2320-6012.ijrms20130823

Cite this article as: Chauhan R, Khanna J. Incomplete development of second sacral lamina: a case report. *Int J Res Med Sci* 2013;1:278-80.