

Original Research Article

Removal of entrapped rings from swollen fingers by a nondestructive technique

Richard C. Echem*, Phillip D. Eyimina, Vincent U. E. Adiela

Department of Orthopaedic Surgery, University of Port Harcourt Teaching Hospital, Port Harcourt, Rivers state, Nigeria

Received: 04 June 2019

Revised: 17 June 2019

Accepted: 03 July 2019

***Correspondence:**

Dr. Richard C. Echem,

E-mail: richy1870@yahoo.co.uk

Copyright: © the author(s), publisher and licensee Medip Academy. This is an open-access article distributed under the terms of the Creative Commons Attribution Non-Commercial License, which permits unrestricted non-commercial use, distribution, and reproduction in any medium, provided the original work is properly cited.

ABSTRACT

Background: Ring entrapment is uncommon in our environment. It is necessary to remove entrapped rings and the removal techniques could be either destructive or non-destructive. The aim of this study is to present a non-destructive method of entrapped ring removal.

Methods: A prospective study of patients who presented to the University of Port Harcourt Teaching Hospital, Port Harcourt between 1st October 2007 and 30th September 2018, with entrapped finger ring(s). The authors developed a non-destructive technique of entrapped ring removal utilizing 1.5-2.5 mm electric cables. The cables are passed under the ring and looped over it. The surgeon and his first assistant applies traction towards the distal aspect of the finger through the cables while moving the cables from side to side around the finger, with the second assistant maintaining a counter-traction. Data obtained was analyzed using IBM's Statistical Package for Social Sciences (SPSS) version 23.

Results: During the period, there were 25 patients who had entrapped ring(s) in their fingers. Mean age was 22.92±9.33 years. There were 10 males and 15 females. Mean duration of ring entrapment was 5.72±4.57 days. Mean duration of ring removal was 63.6±46.58 seconds. Abrasion was the most common complication following initial removal attempts as well as this technique. The entrapped rings were all successfully removed.

Conclusion: The electric cable technique is a simple, inexpensive and readily available method of entrapped ring removal.

Keywords: Electric cables, Entrapment, Finger, Ring Non-destructive, Technique

INTRODUCTION

Finger rings have been used for decorations and symbols as well as to signify social status, treaties and covenants including marriage.¹ The materials used could range from soft materials such as gold and silver to very hard materials like titanium alloy and tungsten carbide.¹⁻³ Despite the beauty of these rings, complications could

occur in the course of wearing finger rings. One of such complication is entrapment of the ring.

Ring entrapment in a finger could be due to trauma, tissue fluid retention, infection, skin disorder, allergic reaction or a too tight ring.^{4,5} Although ring entrapment has been described as a common presentation to the emergency department in some parts of the world,^{4,6-8} it is uncommon in Nigeria.⁹

In the event of a ring entrapment, removal will be indicated. Ring removal is indicated to manage or prevent tourniquet effect of the entrapped ring or to assist procedural management of specific injuries or conditions.⁷ The tourniquet effect of the entrapped ring leads to lymphatic obstruction, venous and ultimately arterial compromise.^{4,5} This gives rise to ischaemia, nerve damage and eventually finger gangrene.

Various techniques of entrapped ring removal have been described and includes both non-destructive and destructive techniques. The non-destructive techniques preserve the rings but in the destructive techniques the rings are destroyed and cannot be utilized afterwards.

The aim of this paper is to present a non-destructive technique of entrapped ring removal utilizing electric cables.

METHODS

This was a prospective study of patients who presented to the University of Port Harcourt Teaching Hospital, Port Harcourt between 1st October 2007 and 30th September 2018, with entrapped finger ring(s).

The authors developed a non-destructive technique of entrapped ring removal utilizing 1.5-2.5mm electric cables (Curtix Plc, Nnewi, Nigeria) (Figure 1). Figure 2 shows an entrapped ring in the right thumb.



Figure 1: The electric cables.



Figure 2: Entrapped finger ring in the right thumb of a patient.




Figure 3: A): The electric cable being passed under the entrapped ring, B): The electric cables being passed under the entrapped ring, C): The electric cables looped over the entrapped ring, D): Removed entrapped ring.

Technique

The electric cables are sterilized with methylated spirit. After skin preparation, a digital block with lignocaine without adrenaline (1%) is given to the affected finger. The patient is also sedated with injection diazepam. A petroleum jelly lubricant is copiously applied to the finger. Three or four electric cables, depending on the number that can conveniently be contained, are passed under the ring from the palmar surface and looped over the ring (Figures 3 A,B,C) and secured at the sides of both the palmar and dorsal surfaces of the finger. Note that only two of the originally three cables remained at the end of the procedure. The surgeon holds two of the looped cables while his first assistant holds one or two depending on how many cables could be passed under the ring.

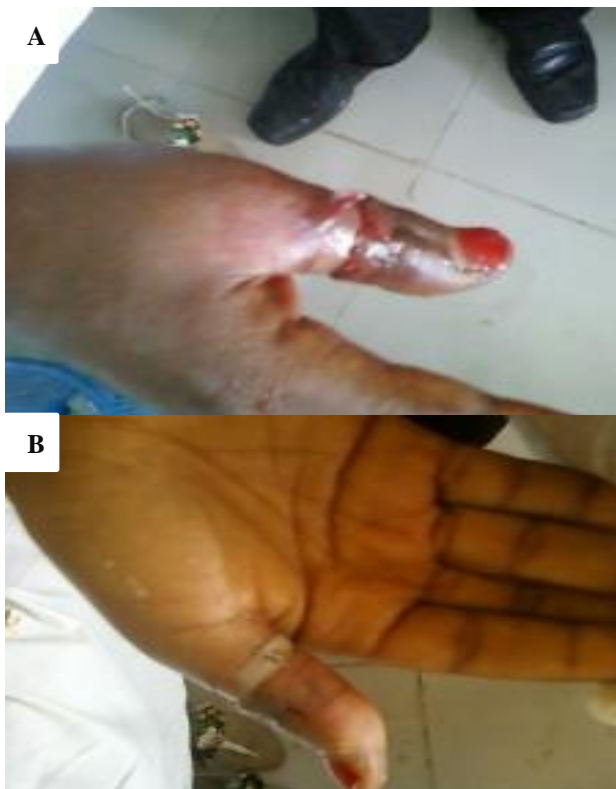

Figure 4: A): The finger after ring removal; dorsal surface, B): The finger after ring removal palmar surface.

The surgeon and his first assistant applies traction towards the distal aspect of the finger through the cables while moving the cables from side to side around the finger, with the second assistant maintaining a pull in the opposite direction of the finger. This is continued until the ring is removed. The looped cables exert pressure on the soft tissues and the ring rolls on the cables out of the finger. Figure 3D shows the removed ring with two cables intact; one of the cables had cut in the course of

the removal. The finger after the ring removal is shown in Figure 4A and 4B (dorsal and palmar surfaces). Note abrasion on the dorsal surface. The time taken for the entrapped ring removal was measured from the time the first cable was passed under the ring to the time the ring was removed from the finger using a stopwatch. Data obtained included their age, sex, marital status, duration the ring(s) had been worn, duration of ring entrapment, number of rings in the affected finger, side of the hand and finger involved, number of initial attempts at removal, duration of ring removal, complications from initial removal attempts, complications from current technique and the number of electric cables at the start and end of the procedure. Data was analyzed using IBM's Statistical Package for Social Sciences (SPSS) version 23 (IBM Inc, Armonk, NY, USA). Mean, standard deviation and median where applicable were used for descriptive statistics while categorical variables were expressed in absolute frequencies.

Ethical approval was obtained from the Research and Ethics Committee of the University of Port Harcourt Teaching Hospital as well as informed consent from the study participants.

RESULTS

During the period, there were 25 patients who had entrapped ring finger and were managed by this technique. Their mean age was 22.92 ± 9.33 years (6-40 years). There were 10 males and 15 females. The demographic and ring characteristics are shown in Table 1. Eleven were single and 10 were married and there were four primary school pupils. The median duration the ring was worn was 4 days. The mean duration of ring entrapment was 5.72 ± 4.57 days. Majority (21) of the patients had one ring in the affected finger. Majority (17) of the entrapped rings were in the left ring finger. All the patients had attempted severally to remove the entrapped ring before presentation but without success. The mean duration of ring removal was 63.60 ± 46.58 seconds (25-240 seconds), with a median of 45 seconds. The most common complication following the initial removal attempts was abrasion. Abrasion was also the most common complication following this technique. The entrapped finger rings were of different makes. While some had sharp edges, others had rounded edges. The abrasions/lacerations were noticed in entrapped rings with sharp edges.

Table 2 shows the number of cables at the beginning and the end of the procedure. For those where four cables were used to start the procedure, in three of them one of the cables cut. For those where three cables were used to start the procedure (this formed the majority), in three of them one of the cables cut. All the entrapped rings were successfully removed utilizing the electric cables.

Table 1: Demographic and ring characteristics.

| Variables | |
|---------------------------------------------------|------------------------------|
| Mean Age (Range) (Years) | 22.92±9.33 (6-40) years |
| Sex (n=25) | |
| Males | 10 |
| Females | 15 |
| Number of rings in the affected finger | |
| One | 21 |
| Two | 4 |
| Mean duration (Range) of ring entrapment (Days) | 5.72±4.57 (1-22) days |
| Median (Range) duration ring was worn | 4 days (1 day-5 years) |
| Finger involved | |
| Right thumb | 1 |
| Right index finger | 1 |
| Right ring finger | 2 |
| Left index finger | 2 |
| Left ring finger | 17 |
| Left middle finger | 2 |
| Mean duration (Range) of ring removal (Seconds) | 63.60±46.58 (25-240) seconds |
| Complications from initial removal attempt | |
| Abrasion | 3 |
| Abrasion+Laceration | 1 |
| Abrasion+Blisters | 1 |
| Laceration | 1 |
| Complications of electric cable technique | |
| Abrasion | 2 |
| Laceration | 1 |

Table 2: Electric cable technique characteristics.

| Number of cables at beginning of procedure | Frequency | Number of cables at the end of the procedure | Frequency |
|--------------------------------------------|-----------|----------------------------------------------|-----------|
| 4 | 4 | 4 | 1 |
| | | 3 | 3 |
| 3 | 21 | 3 | 18 |
| | | 2 | 3 |

DISCUSSION

Our report describes a nondestructive method of entrapped ring removal utilizing electric cables. All the entrapped rings were successfully removed by this technique with few complications. These electric cables are readily available especially where construction works are going on. Several nondestructive methods of entrapped ring removal have been reported. These include the use of vegetable oil, margarine, soap, cooling with ice packs, petroleum jelly or other lubricants, string, suture, suture reign technique, nylon ribbon tape, compression bandage, surgical glove, rubber band, Penrose drains, umbilical tape, arterial tourniquet, and ribbon gauze and paper clip. A ‘caterpillar technique’ which utilizes sequential upward and downward pressure with swinging of the ring has also been described.¹⁰⁻²⁸

Fingers are ellipsoidal in cross-section and not circular and the soft tissues that overlies the structure of the finger are deformable.²⁹ The widest point of the finger is usually the proximal interphalangeal joint,^{4,30} and once the ring goes beyond this point, it is easily removed. The nondestructive techniques have been classified into winding, compression, caterpillar, twin threads and the glove techniques.³¹ Other authors have classified them into string wrap, elastic pull and the glove techniques.¹¹ The current technique being described is a traction technique of entrapped ring removal. This technique using electric cables requires that the finger is well lubricated with a lubricant (petroleum jelly). Traction is steadily applied towards the distal part of the finger with the looped electric cables while moving the cables from side to side around the finger. The looped cables exert pressure on the soft tissues and the entrapped ring rolls on

the cables out of the finger. Traction technique for entrapped ring removal had been described by several authors. The traction can be applied with thin and strong thread, suture or rubber band.^{8,23,24,30,31} Some authors have described the traction technique using thread or suture as the twin threads technique³¹ and others described the technique with the use of the rubber band as elastic pull technique.¹¹ After adequate lubrication of the finger two threads or sutures are attached to the ring on opposite sides of the ring, being parallel to each other and the finger. In the technique described by Chandra and Muchedzi, traction is applied after looping two pieces of suture at opposite sides of the ring. In the technique described by Burbridge and Ritter, the suture is passed under the ring and a loop is tied around one side of the ring.^{8,30} The same suture is passed under the contralateral aspect of the ring and another loop is tied. This makes the suture hang reign-like on opposite sides of the ring.⁸ The assistant puts a moderate amount of tension continuously toward the tip of the finger and the physician holds the ring between the thumb and index fingers from the dorsal and volar aspects.^{8,31} The index finger provides a fulcrum and the ring is advanced toward the proximal interphalangeal joint by controlled outward pressure. Once the ring has advanced, the thumb becomes the fulcrum and the ring is advanced towards the proximal interphalangeal joint. Once the proximal interphalangeal joint has been surmounted, the ring can be easily removed by continuing the alternating leverage.⁸ The moderate tension applied through the suture 'reigns' serve to stabilize the ring, prevents it from turning back or from shifting side-to-side, provides a pivot point and maintains the mechanical advantage needed to leverage the ring over the proximal interphalangeal joint and towards the tip of the finger.^{8,31} The alternating leverage movements have some similarity to the movements in the 'caterpillar' technique. In the traction technique with rubber band, after lubrication of the fingers, two rubber bands are passed underneath the ring and looped over the ring. The looped bands are held with separate hands and distal traction is applied toward the tip of the finger while moving the rubber band around and around the finger.^{23,24}

The duration for the removal of the entrapped ring by a number of the nondestructive traction techniques were not stated. The rubber band technique as described by Kingston et al., indicated a mean removal time of 10.7 seconds (range 2-60 seconds). However, the participants in this study were those who presented for reasons not linked to ring removal and had ring(s) which could not be easily removed (mechanically or with lubrication). These were not typical 'trauma settings'. The current technique had a mean duration of 63.60 seconds, with a median of 45 seconds (range 25-240 seconds) for entrapped ring removal.²⁴ Complications from various nondestructive traction techniques were not highlighted by a number of the publications. Kingston et al. did not document any injury to any of the participants in their study. In the present study, complications of initial attempts of ring removal were mostly abrasions and lacerations. The

electric cable technique also caused abrasions in two patients and laceration in one patient. These patients already had abrasions/lacerations from earlier removal attempts. The abrasions/lacerations were noted in entrapped rings with sharp edges. It is worthwhile to note that the proximal interphalangeal joint is the most difficult point to negotiate and the ring passing over it could cause superficial abrasions and discomfort.^{4,12,24,30} In the course of the use of the current technique, some of the cables utilized cut in the process. This was noticed when the edge of the entrapped ring was sharp. Hence, in some instances the number of cables at the end of the procedure may be less than what it was at the commencement of the procedure. The electric cable traction technique successfully removed all the entrapped rings. The technique can thus be utilized whenever such situations are encountered with few complications. The present study had a number of limitations. The entrapped rings were not uniform. Some of the ring edges were sharp while others were rounded. Also, the study did not compare the electric cable traction technique to other nondestructive ring removal techniques. The number of patients in the present study is small and this can constitute a limitation in generalization of the findings. However, the small number does not undermine the fact that the technique was successful.

CONCLUSION

The electric cable traction technique is a simple technique that is inexpensive and the materials required are readily available. The technique was 100% successful and few complications were encountered.

ACKNOWLEDGEMENTS

The authors acknowledge the assistance of Anderson Ikeokwu in the data analysis.

Funding: No funding sources

Conflict of interest: None declared

Ethical approval: The study was approved by the Institutional Ethics Committee of the University of Port Harcourt Teaching Hospital

REFERENCES

1. Kapickis M, Kutz JE. Titanium alloy ring crush injury. *Am J Emerg Med.* 2007;25(9):1084.e3-5.
2. Allen KA, Rizzo M, Sadosty AT. A method for the removal of tungsten carbide rings. *J Emerg Med.* 2012;43(1):93-6.
3. Hajduk SV. Emergency removal of hard metal or ceramic finger rings. *Ann Emerg Med.* 2001;37(6):736.
4. Chiu TF, Chu SJ, Chen SG, Chen SL, Chen TM. Use of a Penrose drain to remove an entrapped ring from a finger under emergent conditions. *Am J Emerg Med.* 2007;25(6):722-3.

5. Shamsuddin SR, Hashim AA, Berahim N, Fauzi H, Wahab SF, Noh AY. The use of dental drill in removing entrapped finger by metal ring in emergency department. *Med J Malaysia.* 2012;67(3):349-50.
6. Thilagarajah M. An improved method of ring removal. *J Hand Surg Br.* 1999;24(1):118-9.
7. Taylor SP, Boyd MJ. Unusually difficult ring removal from a finger solved using a dental instrument. *Emerg Med Australas.* 2005;17(3):285-7.
8. Burbridge MT, Ritter SE. An alternative method to remove a ring from an edematous finger. *Am J Emerg Med.* 2009;27(9):1165-6.
9. Ramyil VM, Dakum NK, Ayuba LN, Iya D. Ring entrapment of the finger in a psychiatric patient. *Niger J Surg Res.* 2001;3(1):37-40.
10. Ostergaard LJ, Friis ML, Strabo S. Digital strangulation-released by the use of a dentist's drill. *Ugeskr Laeger.* 1995;157(5):594.
11. Baker A, Rylance K, Giles S. The occasional ring removal. *Can J Rural Med.* 2010;15(1): 26-8.
12. Ramponi DR. Don't get uptight about ring removal. *Nursing.* 2002;32(12):56-7.
13. Kates SL. A novel method of ring removal from the aging finger. *Geriatr Orthop Surg Rehabil.* 2010;1(2):78-9.
14. Mizrahi S, Lunski I. A simplified method for ring removal from an edematous finger. *Am J Surg.* 1986;151(3):412-3.
15. Leider M. Removal of a ring from a swollen finger without injuring the finger. *J Dermatol Surg Oncol.* 1980;6(4):298-9.
16. Belliappa PP. A technique for removal of a tight ring. *J Hand Surg Br.* 1989;14(1):127.
17. Berens N, Hamm H, Weyandt GH. Removal of a finger ring with a suture technique. *J Dtsch Dermatol Ges.* 2008;6(5):408-9.
18. Hiew LY, Juma A. A novel method of ring removal from a swollen finger. *Br J Plast Surg.* 2000;53(2):173-4.
19. Mullett ST. Ring removal from the oedematous finger. An alternative method. *J Hand Surg Br.* 1995;20(4):496.
20. Cresap CR. Removal of a hardened steel ring from an extremely swollen finger. *Am J Emerg Med.* 1995;13(3):318-20.
21. Inoue S, Akazawa S, Fukuda H, Shimizu R. Another simple method for ring removal. *Anesthesiol.* 1995;83(5):1133-4.
22. Clarke AC, Spencer RF. Ring removal from the injured or swollen finger. *J R Coll Surg Edinb.* 1991;36(1):59.
23. McElfresh EC, Peterson-Elijah RC. Removal of a tight ring by the rubber band. *J Hand Surg Br.* 1991;16(2):225-6.
24. Kingston D, Bopf D, Dhanjee U, McLean A. Evaluation of a two rubber band technique for finger ring removal. *Ann R Coll Surg Engl.* 2016;98(5):300-2.
25. Venters WB. Ring removal from a swollen finger: a refined technique. *J Surg Orthop Adv.* 2006;15(3):181-3.
26. Gardiner CL, Handyside K, Mazzillo J, Hill MJ, Reichman EF, Chathampally Y, et al. A comparison of two techniques for tungsten carbide ring removal. *Am J Emerg Med.* 2013;31(10):1516-9.
27. Nancarrow JD. A simple technique for removing stubborn rings prior to hand surgery. *J Hand Surg Br.* 1993;18(4):544.
28. St Laurent C. The caterpillar technique for removal of a tight ring. *Anesth Analg.* 2006;103(4):1060-1.
29. Porter ML. Getting stuck-the anthropometry of young children's fingers. In: *Contemporary Ergonomics (Annual Conference of Ergonomics Society, 2001)*. London: Taylor & Francis, 2001: 59-64.
30. Chandra A, Muchedzi T. Ujuzi: Ring removal: a critical emergency procedure (Practical Pearl/ Perle Pratique). *Afr J Emerg Med.* 2012;2(3):127-8.
31. Kalkan A, Kose O, Tas M, Meric G. Review of techniques for the removal of trapped rings on fingers with a proposed new algorithm. *Am J Emerg Med.* 2013;31(11):1605-11.

Cite this article as: Echem RC, Eyimina PD, Adiela VU. Removal of entrapped rings from swollen fingers by a non-destructive technique. *Int J Res Med Sci* 2019;7:3162-7.