

Research Article

Fixed drug eruptions: causing drugs, pattern of distribution and causality assessment in a leading tertiary care hospital

Rahul Saini*, Bhawana Sharma, Prem Kumar Verma, Seema Rani, Garima Bhutani

Department of Pharmacology, BPS, GMC, Khanpur Kalan, University of Health Sciences, Rohtak, Haryana, India

Received: 23 July 2016

Accepted: 30 August 2016

***Correspondence:**

Dr. Rahul Saini,

E-mail: drrahulnanu@gmail.com

Copyright: © the author(s), publisher and licensee Medip Academy. This is an open-access article distributed under the terms of the Creative Commons Attribution Non-Commercial License, which permits unrestricted non-commercial use, distribution, and reproduction in any medium, provided the original work is properly cited.

ABSTRACT

Background: It is bitter truth that there is no drug in this world which is without an adverse drug reaction (ADR). After the clinical trials when the drug comes in market or when it is taken by variety of population then actual reality of the drug comes out about its efficacy and adverse drug reactions. Fixed drug eruption is also one such type of ADR in which a specific type of lesions occurs over the skin after the drug is taken.

Methods: We have conducted a clinical, observational study, in BPS Government Medical College, Khanpur Kalan, Sonapat, Haryana, India over a period of eight months. In that period we have found 159 patients having adverse drug reactions. Patients of both genders, under all age group were included in the study.

Results: Out of 159 adverse drug reactions reports 69 (43.39%) were cutaneous adverse drug reaction report, 45 (28.30%) cases were of fixed drug eruption (FDE). Out of these 45 cases seen, there were 4 males (8.88%) and 41 females (91.11%). Flouroquinolone antibiotics like ciprofloxacin, ofloxacin and norfloxacin were the most common drugs causing fixed drug eruption followed by nitroimidazole antibiotic like metronidazole, tinidazole and NSAIDS like diclofenac, paracetamol and meftal spas in our study. FDE are more common in upper limbs extremities followed by lower limb extremities than face and trunk. Causality assessment was done with the help of WHO UMC scale and we found that association was possible in all the cases.

Conclusions: Fixed drug eruptions are one of the major types of adverse drug reactions and should be assessed and reported.

Keywords: Pharmacovigilance, FDE, ADR

INTRODUCTION

Adverse drug reactions are very common nowadays or we can say that with emerging pharmacovigilance it is being reported frequently now days. Adverse drug reaction (ADR) is defined as "A noxious response to a drug which occurs at doses normally used for the prophylaxis, diagnosis and treatment of disease."

Among the various adverse drug reactions, cutaneous drug reactions are the most common one. Various types of cutaneous adverse drug reactions are rashes, steven Johnson Syndrome, hyperpigmentation, fixed drug

eruptions, pruritis, erythema, urticaria and so on. Fixed drug eruption (FDE) is a unique type of reaction that is responsible for about 10% of all adverse drug reactions.¹ FDE is the formation of one or more annular or oval, erythematous patches because of systemic exposure to a drug and most of times it resolves with a residual hyperpigmentation.²

Characteristic of the lesion is the recurrence at the same site with each exposure to a particular medication. There is typical history of occurring of sharply demarcated macule, round or oval in shape, within minutes to hours after ingestion of the culprit drug. The lesions after some

time become edematous which may evolve to become a bulla and then erosion and heals with pigmentation.³ Common sites for FDE are on the lips, trunk, hands and genitals. Main pathology behind its recurrence is local reactivation of memory T cell lymphocytes in skin due to drugs.⁴ The most common agents causing FDE are antibiotics (trimethoprim-sulfamethoxazole, tetracycline, penicillin, and erythromycin), followed by nonsteroidal anti-inflammatory drugs (diclofenac sodium, aspirin, naproxen, and ibuprofen).⁵

Physician should be aware of specific reactions to stop the offending drug and initiate appropriate treatment. So knowledge regarding particular pattern, severity and drugs responsible for causation of these reactions is an important step in controlling of FDE. The diagnosis of FDE is clinical and also it has number of differential diagnosis, if we know that the particular drug is causing fixed drug eruption and its pattern of distribution of lesions over skin, it will help in reaching the actual diagnosis at earliest.

This study was carried to observe the different drugs causing fixed drug eruption over a period of eight months in a tertiary care hospital. Location and nature of fixed drug eruption was also identified in this study so that awareness could be created regarding FDE inducing drugs.

METHODS

This was a clinical, observational study, conducted in the BPS Government Medical College, Khanpur Kalan, Sonapat, Haryana, India over a period of eight months (April 2015 – December 2015). Patients of both genders, under all age group were included in the study. Other cutaneous eruptions caused by drugs (Steven Jonson syndrome, Toxic epidermal necrolysis) were excluded.

After the patients come in hospital proper history of drug intake, route of administration, reason for taking drugs, time of start of reaction, temporal correlation with drug intake, improvement of lesions on withdrawal of the drug and recurrence of the lesions on rechallenge were also observed. In this study drugs causing FDE was taken as the Primary end point and no of cases, area affected, nature of the lesion – bullous / non-bullous were taken as the secondary end point. The WHO-UMC causality assessment system causality assessment scale regarding drug reaction was also done.⁶

RESULTS

Out of 159 adverse drug reactions reports 69 (43.39%) were cutaneous adverse drug reaction report, 45 (28.30%) cases were of fixed drug eruption. Of the 45 cases seen, there were 4 males (8.88%) and 41 females (91.11%).The age of the patients ranged between 10 years and 48 years (mean=29). All the drugs causing FDE were taken orally by the patients. The drugs were taken commonly for pain,

fever and infections(diarrohea,tinea,tuberculosis,sore throat). The incubation period varied between 3 hours to 2 days.

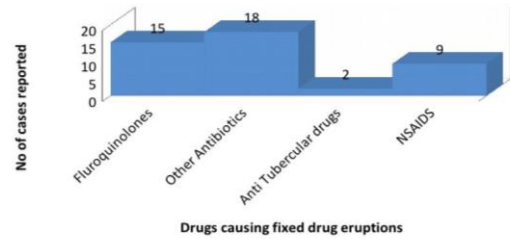


Figure 1: Different group of drugs casuing fde in the number of cases.

Flouroquinolone antibiotics like ciprofloxacin, ofloxacin and norfloxacin were the most common drugs causing fixed drug eruption followed by nitroimidazole antibiotic like metronidazole, tinidazole and NSAIDS like diclofenac, paracetamol and meftal spas in our study. Three cases of amoxicillin, fluconazole and two cases of antitubercular drugs causing fixed drug eruption were also reported (Figure 1).

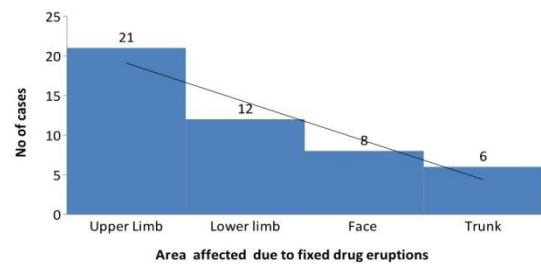


Figure 2: Area affected due to FDE in number of cases.

FDE are more common in upper limbs extremities followed by lower limb extremities than face and trunk in our study. In face mainly lips are involve which are mainly due to NSAIDS (Figure 2).

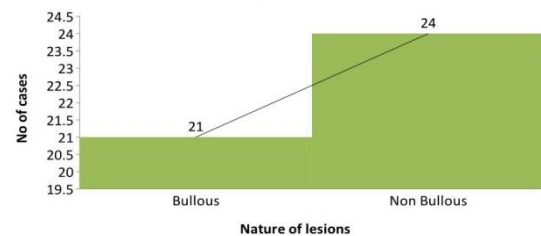


Figure 3: Nature of lesions (bullous/non bullous) in number of cases.

As far as natures of lesions are concerned non bullous lesions are more common as compared to bullous type in our study (Figure 3). Causality assessment was done with

the help of WHO UMC scale and we found that association was possible in all the cases means repeated intake of drug causes lesions to occur at same anatomic sites.

DISCUSSION

In present study it was observed that flouroquinolones (33.3%) were the major etiological agent in causing FDE followed by nitroimidazole antibiotics (26.6%), NSAID's (24.4%), penicillin and antifungal (6.7%) and anti-tubercular drugs (2.2%). In studies performed before 2000, the most common causative agent of FDE was trimethoprim-sulfamethoxazole.⁷

In the past, FDEs caused by NSAIDs and acetaminophen were known to be rare, but in reports after 2000, NSAIDs (16%-35%) were the second most common factor after antibiotics (39%-65%), and followed by anticonvulsant drugs (16%-30%).⁸

Actually now a days cotrimoxazole is not used so frequently as before, so that may be the reason for decrease in its frequency of causing FDE. As per the study by Kavoussi et al, number of females suffering from FDE was more than number of males. In our study also numbers of females suffering from FDE are much more than number of males.

A slight male preponderance was also observed in of the study (M:F=1.4:1). In concordance with the previous studies, NSAID induced FDE were located on the trunk and extremities. In our study FDE due to NSAIDS are on the upper limbs and on lips. As per the study by Thilagam et al, Amoxicillin induced FDE were confined to the palms and soles which is same as found in our study. Other drugs like ciprofloxacin and metronidazole had induced FDE on the extremities.

In present study out of 45 cases observed, bullous lesions were observed in among 21 patients. Therefore reporting of adverse drug reaction is very important to safeguard the health of patients. If the healthcare professionals have sufficient literature and data regarding the drugs causing fixed drug eruptions along with the pattern of distribution, they can make the diagnosis easily. Early diagnosis leads to start of treatment at earliest which reduces the cost of treatment.

So to conclude we have reported the fixed drug eruptions due to certain drugs, no doubt these drugs are only like a few drops in large sea, but continuous addition of few drops would resulting in formation of large sea.

CONCLUSION

Fixed drug eruptions are one of the major types of adverse drug reactions and should be assessed and reported.

Funding: No funding sources

Conflict of interest: None declared

Ethical approval: Not required

REFERENCES

1. Patro N, Panda M, Jena M, Mishra S. Multifocal Fixed Drug Eruptions: A Case Series. Int. J. Pharm. Sci. Rev. Res., 2013;23(1):63-6.
2. Wolff K, AJ Richard, Surmond D. Colour atlas and synopsis of Clinical Dermatology: 5th edition. McGraw Hill: 2005:556.
3. Kavoussi H, Rezaei M, Derakhshandeh K, Moradi A, Ebrahimi A, Rashidian H, et al. Clinical Features and Drug Characteristics of Patients with Generalized Fixed Drug Eruption in the West of Iran (2005–2014). Derm Res Prac. 2015;15:4 .
4. Mehta TK, Marquis L, Shetty JN. A Study of seventy cases of drug eruptions. Ind J Derm, Vene Lep. 1971;37:1-5.
5. Sharma VK, Dhar S, Gill AN. Drug related involvement of specific sites in fixed eruptions: a statistical evaluation. J Dermatol. 1996;23:530-4.
6. Sharma VK, Sethuraman G, Kumar B. Cutaneous Adverse drug reaction patterns to Antimicrobial drugs in North- India. J Assoc Physicians India. 1998;46:1012.
7. Gowri Thilagam T, Parameswari R, Shanthi M, Uma D, Mathivani M. A study of drugs causing fixed drug eruptions in a Tertiary Care Hospital. Int J Phar Life Sci. 2013;4(10): 3018-22.
8. Bertram G.K, Susan B.M, Anthony JT. Basic and clinical pharmacology. 11th edition. 2009:73.

Cite this article as: Saini R, Sharma B, Verma PK, Rani S, Bhutani G. Fixed drug eruptions: causing drugs, pattern of distribution and causality assessment in a leading tertiary care hospital. Int J Res Med Sci 2016;4:4356-8.